Commentary | Open Access

Rare Disease and Orphan Drugs Journal

Gilheeney. *Rare Dis Orphan Drugs J.* 2026;5:15 **DOI:**10.20517/rdodj.2025.38

Concerns for inclusive comprehensive neurofibromatosis care - looking at the LGBTQ+ community

Stephen W. Gilheeney

Citation: Gilheeney SW. Concerns for inclusive comprehensive neurofibromatosis care - looking at the LGBTQ+ community. *Rare Dis Orphan Drugs J.* 2026;5:15. https://dx.doi.org/10.20517/rdodj.2025.38

Received: 12 Jun 2025
First Decision: 28 Nov 2025
Revised: 23 Feb 2026
Accepted: 20 Mar 2026
Published: 27 May 2026

Academic Editor: Daniel Scherman
Copy Editor: Ping Zhang
Production Editor: Ping Zhang

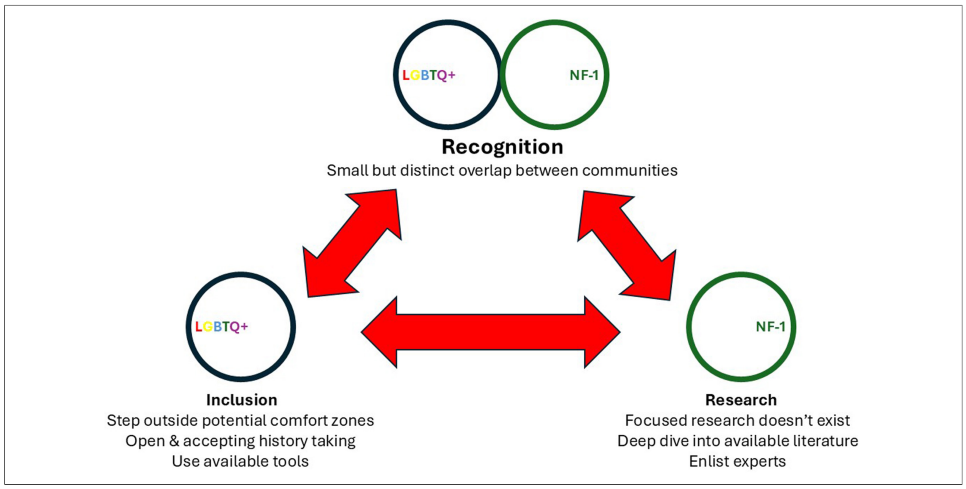

As will happen more often than not, a patient gets added to your schedule. A preliminary review of the chart shows you that the patient is a 20-year-old male with a diagnosis of neurofibromatosis type 1 (NF-1). The specific reason for the visit is to discuss results of recent imaging - specifically a left orbital optic pathway glioma as well as a thoracolumbar paraspinal plexiform neurofibroma. Fortunately, the patient recently saw his ophthalmologist, who noted stable visual fields and a moderate refractive error, easily corrected with glasses. Even more luck - neither the magnetic resonance imaging (MRI) brain/orbits nor the MRI thoracolumbar spine show evidence of radiographic progression. You meet the patient, and throughout the course of the history and examination, open-ended questioning reveals that though he was assigned the sex of female at birth, he identifies as a transgender male and is interested in pursuing gender-affirming therapy to transition to male. He asks you about what effects that may have on NF-1 related care, specifically as related to the optic pathway glioma and the plexiform neurofibroma.

Check for updates

Department of Pediatrics, Division of Hematology/Oncology, Icahn School of Medicine at Mount Sinai/Kravis Children's Hospital, New York, NY 10029, USA.

Correspondence to: Assoc. Prof. Stephen W. Gilheeney, Department of Pediatrics, Division of Hematology/Oncology, Icahn School of Medicine at Mount Sinai/Kravis Children's Hospital, New York, NY 10029, USA. E-mail: stephen.gilheeney@mssm.edu

So how do you answer? Truthfully, you have questions of your own to answer first. Your own chart review led you to believe the patient was a 20-year-old male. Where in the history is sex assigned at birth documented? Do we even know the data pertinent to this situation? Do you need more information from the patient's history, further testing, or review? Perhaps you then find yourself somewhat "stuck".

The diagnosis of a chronic health condition has ramifications in multiple spheres: physical, emotional, social, and financial. As physicians and providers, we almost always feel more comfortable with the physical. Yet the objective data and observations we gather are often paired with subjective reports, but we can quantify them, order tests, and try interventions. However, these interventions need to be initiated for the patient in the setting of social and emotional factors. This requires empathy, understanding, and compassion. The latter of those is perhaps the most recent development when one considers the case of physicians and practitioners taking care of patients who identify within the lesbian/gay/bisexual/transgender+ (LGBTQ+) population.

A Gallup Poll published in February 2025 showed that 9.3% of adults in the US consider themselves to be included in the LGBTQ+ population[1]. That data simply does not exist for the population of American physicians in the current published peer-reviewed literature and most certainly does not include reports of this type of socio-cultural diversity from a geographic standpoint. One might then ask a question such as, "How then does a male heterosexual doctor who identifies with his gender assigned at birth advise a female lesbian patient with NF-1 about carrying a pregnancy to term and what that means about starting a MEK [mitogen-activated protein kinase (MAPK) kinase] inhibitor?"

Inclusivity as an idea is generally somewhat easier to take on intellectually than in practice. That is probably because practicing inclusivity in the healthcare setting requires knowing your patients in a way that some practitioners might not think even applies to their practice or field. Many practitioners may firmly believe that knowing a patient's sexual orientation or gender identity has no relevance to their specialty or subspecialty. For some, we were not trained to inquire as to how best to pose these questions.

In truth, that is for our patients to decide and not us. Sexual history has long been included as an integral part of a patient's history and physical examination, and there are multiple publications that provide students and professionals with tips and guidance on how to frame these questions in open-ended and supportive ways. Some of us, admittedly, are more facile with this than others. However, this information can also be garnered from forms and/or questionnaires provided to patients at their initial visit. Regular updating of this information can also be helpful. The important part of all of this is that a patient can feel free to express their answers in a way that is professional, courteous and taken as important by their healthcare practitioner.

Garnering this information in one way or another can also help prevent a bias that can be especially damaging to the doctor-patient relationship. Through our daily interaction with people, we can often (though clearly not always) find ourselves coming to assumptions about people. In this sphere, one can assume a particular person is gay or straight. One can assume a patient is cis or trans. However, experience for many physicians and practitioners has shown that our assumptions can be wrong just as often - if not more often - than they are correct. Furthermore, these assumptions can reveal our own internal biases toward our patients in ways that can be off-putting or even damaging and hurtful to our patients. In cases such as these, there are references and tools that exist that allow patients to express this information. These include sexual health questionnaires and organ inventories. These invaluable resources can help guide counseling as well as curative treatments and preventative strategies.

Turning back to our initial patient, then….. So what do we know? First and foremost, it must be made exceptionally clear that this invited commentary cannot and will not include an in-depth discussion as to the particulars of gender-affirming hormonal therapy. A broad but decidedly correct statement to make is that

when gender-affirming therapy is initiated, the dose of the hormonal therapy is adjusted to gradually bring the levels of either estradiol or testosterone into the range of the affirmed gender. The goal is to mimic changes associated with puberty over a period of 2-3 years while minimizing and avoiding supraphysiologic dosing and any potential related side-effects[2]. The classical teaching is that childhood through puberty is a vulnerable period of growth for neurofibromas[3]. Of note, Dagalakis *et al.* reviewed data in adolescents with NF-1 progressing through puberty, noting that while correlations between dermal neurofibroma growth and puberty are present, the same data for plexiform neurofibromas had been previously non-existent. Their analysis did not demonstrate any relationship between hormonal markers of puberty and changes in tumor burden[4]. Notably, they are quick to note that their study population differs significantly from the general NF-1 population due to some of their patients receiving tumor-directed treatment. While they note an absence of significant difference in patients receiving treatment versus those not receiving treatment, the sample size in this single-institution study limits our ability to draw solid inferences.

The 2017 Clinical Practice Guidelines for the Endocrine Treatment of Gender-Dysphoric/Gender Incongruent Persons does state that "concomitant medical issues that could interfere with treatment… have been addressed"[5]. Understandably and correctly, their guidelines do not identify any specific medical concerns. These same guidelines suggest an in-treatment monitoring frequency of every 3-6 months. Again understandably, such guidelines cannot and therefore do not take into account the type of patient we present here. Thus, what would appropriate monitoring be? Is imaging of a greater frequency appropriate? Attention must also be paid to the fact that hormone levels can have wide intra- and inter-institution variability[6]. What does appropriate patient monitoring entail in this situation?

Of further note, the preponderance of the literature available for review in reference to this topic discusses plexiform neurofibromas and their biology. In vitro studies have shown that the proliferation of Schwann cells of the NF1 -/- genotype is increased when treated with testosterone at levels similar to those targeted and achieved in gender-affirming care[7]. What are the other tumor types seen in patients with NF-1. Similar data for optic pathway glioma in the NF-1 population does not appear to exist in the published literature. As it relates to other types of fibromas, there is at least one case report of a transgender male patient assigned female at birth with a history of multiple endocrine neoplasia type 1 who developed growth of angiofibroma while receiving gender-affirming care with testosterone[8]. Nonetheless, this represents an entirely different tumor biology.

The most recent published data estimate that 0.6% of people over the age of 13 identify as transgender[9]. With 1/2000 live births presenting with NF-1, it is possible that a controlled study of these patients would be difficult at best. Nonetheless, counseling a patient such as this would require an inclusive atmosphere for discussion with a clinician to determine the best course of action. In conclusion, an inclusive approach to care for the LGBTQ+ population is integral to good patient care, both as it relates to the doctor-patient relationship and to medical care itself. Further research regarding the intersection of this population with that of patients with chronic conditions, including neurofibromatosis, is needed.

DECLARATIONS

Authors' contributions

The author contributed solely to the article.

Availability of data and materials

Not applicable.

AI and AI-assisted tools statement

Not applicable.

Financial support and sponsorship

None.

Conflicts of interest

The author declared that there are no conflicts of interest.

Ethical approval and consent to participate

Not applicable.

Consent for publication

Not applicable.

Copyright

© The Author(s) 2026.

REFERENCES

1. Jones JM. LGBTQ+ Identification in U.S. Rises to 9.3%. Gallup. Available from: https://news.gallup.com/poll/656708/lgbtq-identification-rises.aspx [Last accessed on 30 Apr 2026].
2. Endocrine society. Dosing standards for pubertal suppression and sex steroid hormones in transgender youth. 2020. Available from: https://www.endocrine.org/-/media/endocrine/files/practice/gender_dosing_standards_transgender_youth.pdf [Last accessed on 22 Apr 2026].
3. Rosser T, Packer RJ. Neurofibromas in children with neurofibromatosis 1. *J Child Neurol.* 2002;17:585-91. DOI
4. Dagalakis U, Lodish M, Dombi E, et al. Puberty and plexiform neurofibroma tumor growth in patients with neurofibromatosis type I. *J Pediatr.* 2014;164:620-4. DOI
5. Hembree WC, Cohen-Kettenis PT, Gooren L, et al. Endocrine treatment of gender-dysphoric/gender-incongruent persons: an endocrine society clinical practice guideline. *J Clin Endocrinol Metab.* 2017;102:3869-903. DOI
6. Deutsch MB. Overview of masculinizing hormone therapy. UCSF Transgender Care & Treatment Guidelines. Available from: https://transcare.ucsf.edu/guidelines/masculinizing-therapy [Last accessed on 22 Apr 2026].
7. Pennanen P, Peltonen S, Kallionpää RA, Peltonen J. The effect of estradiol, testosterone, and human chorionic gonadotropin on the proliferation of Schwann cells with *NF1*$^{+/-}$ or *NF1*$^{-/-}$ genotype derived from human cutaneous neurofibromas. *Mol Cell Biochem.* 2018;444:27-33. DOI
8. Bubley JA, Yeung H, Cole E, Amin M, Parker D, Arbiser JL. Angiofibroma stimulation in a transgender person receiving gender-affirming testosterone. *JAAD Case Rep.* 2020;6:1101-3. DOI
9. Herman JL, Flores AR, O'Neill KK. How many adults and youth identify as transgender in the United States? The Williams Institute, UCLA School of Law. 2022. Available from: https://williamsinstitute.law.ucla.edu/wp-content/uploads/Trans-Pop-Update-Jun-2022.pdf [Last accessed on 22 Apr 2026].

Disclaimer/Publisher's Note: All statements, opinions, and data contained in this publication are solely those of the individual author(s) and contributor(s) and do not necessarily reflect those of OAE and/or the editor(s). OAE and/or the editor(s) disclaim any responsibility for harm to persons or property resulting from the use of any ideas, methods, instructions, or products mentioned in the content.

© The Author(s) 2026. Open Access This article is licensed under a Creative Commons Attribution 4.0 International License (https://creativecommons.org/licenses/by/4.0/), which permits unrestricted use, sharing, adaptation, distribution and reproduction in any medium or format, for any purpose, even commercially, as long as you give appropriate credit to the original author(s) and the source, provide a link to the Creative Commons license, and indicate if changes were made.