

Review

Open Access



Percutaneous mitral valve repair in patients with secondary mitral regurgitation and advanced heart failure

Andrea Scotti¹, Alberto Margonato², Cosmo Godino²

¹Department of Cardiac Thoracic Vascular Sciences and Public Health, University of Padua Medical School, Padua 35128, Italy.

²Cardio-Thoracic-Vascular Department, San Raffaele Scientific Institute, Milan 20132, Italy.

Correspondence to: Dr. Cosmo Godino, Cardio-Thoracic-Vascular Department, San Raffaele Scientific Institute, Via Olgettina 60, Milan 20132, Italy. E-mail: godino.cosmo@hsr.it

How to cite this article: Scotti A, Margonato A, Godino C. Percutaneous mitral valve repair in patients with secondary mitral regurgitation and advanced heart failure. *Mini-invasive Surg* 2020;4:49. <http://dx.doi.org/10.20517/2574-1225.2020.38>

Received: 19 Apr 2020 **First Decision:** 18 Jun 2020 **Revised:** 23 Jun 2020 **Accepted:** 6 Jul 2020 **Published:** 7 Aug 2020

Academic Editor: Giulio Belli **Copy Editor:** Cai-Hong Wang **Production Editor:** Tian Zhang

Abstract

Advanced heart failure (HF) prevalence is increasing and ranges between 1% and 10% of the overall HF population, due to the growing number of patients with HF and their better treatment and survival in the last 20 years. The best treatment for these patients is represented by heart transplantation, which, unfortunately, is only available for a minority of them. A significant portion of patients with advanced HF has concomitant severe mitral regurgitation, which acts as a driving force in inducing and maintaining this end-stage condition in a vicious cycle. Percutaneous mitral valve repair with MitraClip is a treatment option to stop this vicious cycle, providing safer outcomes and clinical benefits in some of these patients. Preliminary clinical observations show a possible selective role for percutaneous mitral valve treatment with MitraClip as a bridge to transplantation, candidacy or recovery. Further evidence will be necessary to confirm these preliminary data and support this new treatment framework of patients with advanced HF.

Keywords: Mitral regurgitation, secondary mitral regurgitation, percutaneous mitral valve repair, advanced heart failure, heart transplantation, bridge therapy

INTRODUCTION

Mitral regurgitation (MR) is the most common valve disease worldwide, affecting at least 20% of patients aged > 65 years^[1]. Secondary MR (SMR) is the predominant and most clinically relevant form. Indeed, SMR, even when mild, correlates with higher adverse outcomes^[2]. While the ischemic vs. non-ischemic etiologies do not impact on these findings^[3], higher grades of SMR severity are associated with reduced



© The Author(s) 2020. **Open Access** This article is licensed under a Creative Commons Attribution 4.0 International License (<https://creativecommons.org/licenses/by/4.0/>), which permits unrestricted use, sharing, adaptation, distribution and reproduction in any medium or format, for any purpose, even commercially, as long as you give appropriate credit to the original author(s) and the source, provide a link to the Creative Commons license, and indicate if changes were made.



Table 1. 2018 HFA-ESC criteria for defining advanced heart failure

Presence of all of the following criteria despite optimal guideline-directed treatment
1. Severe and persistent symptoms of heart failure [NYHA class III (advanced) or IV]
2. Severe cardiac dysfunction (LVEF \leq 30%), isolated RV failure (e.g., ARVC) or non-operable severe valve abnormalities or congenital abnormalities or persistently high (or increasing) BNP or NT-proBNP values and severe diastolic dysfunction or LV structural abnormalities according to HFpEF and HFmrEF ESC definitions
3. Episodes of pulmonary or systemic congestion requiring high-dose intravenous diuretics (or diuretic combinations) or episodes of low output requiring inotropes or vasoactive drugs or malignant arrhythmias causing > 1 unplanned visit or hospitalization in the last 12 months
4. Severe impairment of exercise capacity of cardiac origin: 6 MWTD (< 300 m) or pVO ₂ (< 12-14 mL/kg/min)

ARVC: arrhythmogenic right ventricular cardiomyopathy; BNP: B-type natriuretic peptide; ESC: European Society of Cardiology; HFA: Heart Failure Association; HFmrEF: heart failure with mid-range ejection fraction; HFpEF: heart failure with preserved ejection fraction; LV: left ventricular; LVEF: left ventricular ejection fraction; NT-proBNP: N-terminal pro-B-type natriuretic peptide; NYHA: New York Heart Association; pVO₂: peak exercise oxygen consumption; RV: right ventricular; 6MWTD: 6-min walk test distance.

survival and progressive worsening of left ventricle (LV) dysfunction^[4,5]. Therefore, it is crucial to treat MR in a useful time window before these changes become irreversible^[5-7]. Among all the percutaneous treatment options for MR, MitraClip (Abbott, Illinois, USA) is the most adopted device with > 100,000 procedures performed worldwide. The first two randomized clinical trials on edge-to-edge transcatheter mitral valve repair (TMVR) vs. guideline-directed medical therapy (GDMT) in patients with heart failure (HF) and severe MR (COAPT^[8] and MITRA-FR^[9]) reported contrasting yet complimentary results. The resultant effect is a growing interest in finding those who can benefit the most from this procedure. On the contrary, little is known about those patients with advanced HF and poor prognosis treated with MitraClip implantation. Although this procedure may be considered futile in some of these cases, it can act as bridging therapy for further invasive treatments in others. The aim of this review is to analyze the impact of SMR and its percutaneous treatment in this unconventional setting.

ADVANCED HEART FAILURE

The clinical course of HF is characterized by gradual worsening of cardiac function and symptoms. This process may lead to a clinical phase where traditional treatments (e.g., GDMT, devices and surgery) are no longer effective, and advanced therapies [e.g., mechanical circulatory support (MCS) and heart transplantation (HTx)] or palliative care are needed. This clinical condition is called advanced HF. The Interagency Registry for Mechanically Assisted Circulatory Support (INTERMACS) profiles were previously used to classify these patients based on the presence of HF with reduced ejection fraction (HFrEF) and need for long-term MCS device implantation. To be more inclusive by extending this group also to patients affected by HF with preserved ejection fraction (HFpEF), an updated definition of the European Society of Cardiology has been released^[10] [Table 1].

Prevalence of advanced HF ranges between 1% and 10% of the overall HF population. This percentage is growing because of better treatment and longer survival of these patients. Once these patients have been identified, it is of utmost importance to acknowledge the appropriate timing for referring them to tertiary care centers where advanced therapies can be adopted. A useful mnemonic ("I Need Help") has been proposed to verify the eligibility to immediate management and transfer based on the need for inotropic therapy, end-organ dysfunction, poor ejection fraction, consistently low blood pressure and poor or intolerance to GDMT^[11] [Table 2].

Despite the efforts spent to categorize this stage of disease, we must recognize the extreme variability that exists between patients who are part of this group. In one extreme, there are young patients with idiopathic heart disease or non-ischemic cardiomyopathies (chemotherapy-induced, myocarditis-related, etc.) in the absence of further comorbidities. On the opposite side, we can find elderly people mainly affected by ischemic heart disease and numerous concomitant co-pathologies [chronic kidney disease (CKD), diabetes mellitus (DM), atrial fibrillation (AF), chronic obstructive pulmonary disease (COPD), peripheral vascular

Table 2. "I Need Help" - Markers of advanced heart failure

I	Inotropes	Previous or ongoing requirement for dobutamine, milrinone, dopamine, or levosimendan
N	NYHA/Natriuretic peptide	Persisting NYHA class III/IV and/or persistently high BNP/NT-proBNP
E	End-organ dysfunction	Worsening renal or liver dysfunction in the setting of heart failure
E	Ejection fraction	Very low ejection fraction < 20%
D	Defibrillator shocks	Recurrent appropriate defibrillator shocks
H	Hospitalizations	More than 1 hospitalization with heart failure in the last 12 months
E	Edema/Escalating diuretics	Persisting fluid overload and/or increasing diuretic requirement
L	Low blood pressure	Consistently low BP with systolic < 90-100 mmHg
P	Prognostic medication	Inability to up-titrate (or need to decrease/cease) ACEI, beta-blockers, ARNIs, or MRAs

ACEI: angiotensin-converting enzyme inhibitor; ARNI: angiotensin-receptor neprilysin inhibitor; BNP: B-type natriuretic peptide; BP: blood pressure; MRA: mineralocorticoid receptor antagonist; NT-ProBNP: N-terminal pro-b-type natriuretic peptide; NYHA: New York Heart Association

disease (PVD), *etc.*]. We must take this heterogeneity into consideration when examining the outcomes of the therapies adopted.

MANAGEMENT STRATEGIES IN ADVANCED HEART FAILURE

HTx remains the best option for most patients with advanced HF. The developments in recipient and donor selection, immunosuppression and management of infectious complications have led to considerable improvements in survival, exercise capacity, quality of life and return to work. However, the number of transplants seems to have reached a plateau in the last years, because of the limited availability of donor hearts. The marked imbalance between demand and supply results in continuous expansion of waiting lists and prolonged waiting times (over 12 months). Patients on "waiting list" are characterized by high mortality rate, ranging between 14% at 1 year and 20% at up to 3 years^[12]. HTx candidates in the current era are also more complex: older, antigen-sensitized and on MCS at the time of listing and transplantation. In this setting, our goal must be to allocate the limited resources available in the best possible way and, at the same time, achieve better outcomes.

Left ventricular assist device (LVAD) implantation is an established treatment for long-term MCS. First introduced for transplant-ineligible patients with advanced HF, its technology has been developed enough to make it a valid alternative as destination therapy. The Risk Assessment and Comparative Effectiveness of Left Ventricular Assist Device and Medical Management in Ambulatory Heart Failure Patients (ROADMAP) study demonstrated higher survival with improved functional status, improved quality of life and reduced depression in the LVAD group compared to OMT, at the expense of more hospitalizations and greater rate of major adverse events (e.g., bleedings, stroke, driveline infections, pump thrombi, ventricular arrhythmias and right HF)^[13].

Several percutaneous and paracorporeal devices are available for short term MCS. Their simple implantation and safety make them suitable for advanced HF patients until LVAD, HTx or candidacy to LVAD/HTx. For the latter purpose, the International Society for Heart Lung Transplantation suggests application of MCS in the case of potentially reversible or treatable comorbidities such as cancer, obesity, renal failure, tobacco use and pharmacologically irreversible pulmonary hypertension, with subsequent re-evaluation to establish candidacy (Class IIb; Level of Evidence: C)^[14]. Despite huge developments in technology, a significant portion of advanced HF patients decline MCS implantation for a variety of personal reasons or are not eligible for this therapy due to prohibitive operative risk, limited life expectancy, irreversible renal or hepatic dysfunction and severe psychosocial limitations. For these reasons, we have to consider the use of other devices, among which the MitraClip can play a leading role in case of advanced HF with concomitant severe MR.

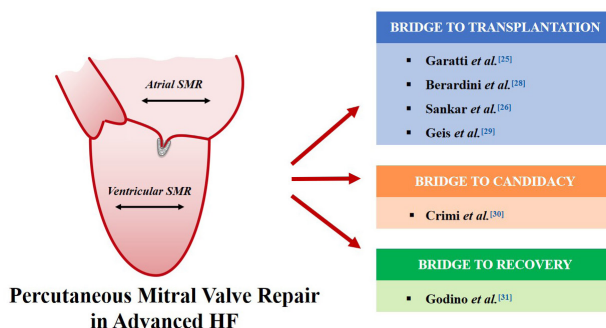


Figure 1. Published clinical evidence of MitraClip implantation in advanced HF patients with concomitant atrial or ventricular secondary mitral regurgitation pursuing the following strategies: bridge to heart transplantation, bridge to candidacy to heart transplantation and bridge to recovery. HF: heart failure; SMR: secondary mitral regurgitation

PROGNOSTIC ROLE OF MITRAL REGURGITATION ON ADVANCED HEART FAILURE

PATIENTS

A significant proportion of patients with advanced HF have concomitant MR: severe or moderate-severe MR is present in about 15% of them and moderate or worse MR in about 40%^[15]. Different etiological mechanisms underlie SMR. In HFpEF, SMR is mainly generated by an “atrial-secondary mechanism”: high left atrial pressure induces atrial and mitral annulus dilatation, with eventual atrial fibrillation [Figure 1]^[16]. In HFrEF, SMR is associated with a “ventricular-secondary” mechanism: dilatation and remodeling of LV cause mitral annulus dilation and papillary displacement tethering the valve leaflets and avoiding a competent coaptation [Figure 1]^[16]. This definition does not discern the two casual pathways of MR in the case of LV dysfunction: displacement and tenting of papillary muscles can be symmetrical as a consequence of marked LV dilatation (“true secondary” MR) or asymmetrical if caused by unequal or disordinated activation or contraction of the papillary muscles (e.g., left bundle branch block or inferior-posterior myocardial infarction).

From a purely pathophysiological point of view, it is important to understand that SMR can represent either a “primum movens” or an epiphenomenon of disease progression (“true secondary” MR), depending on the etiological mechanisms of MR and the clinical condition of patients [Figure 2]. It is not easy to discriminate in each patient the role of MR in the disease process. Recently, a conceptual framework that would allow physicians to distinguish between these two possibilities has been proposed^[17-19].

According to this concept, we can estimate the contribution of global LV function to the severity of MR by measuring the LV end-diastolic volume (LVEDV). When MR is completely secondary (“true secondary” MR) and it is just a biomarker of LV dysfunction and remodeling, the magnitude of MR flow would be “proportionate” to and thus explicable by the LVEDV. Conversely, if MR is the “primum movens” (primary cause of the disease), the magnitude of MR would be “disproportionate” and greatly exceed that predicted by LV volumes. The ratio between effective regurgitant orifice area (EROA) and LVEDV is helpful in defining the degree of MR as proportionate ($EROA/LVEDV \leq 0.14$) or disproportionate ($EROA/LVEDV > 0.14$) with the extent of LV dysfunction^[17,20].

Consequently, the response to therapeutic intervention (TMVR on top of GDMT) will be more relevant in patients in which MR is the “primum movens” of the disease and less beneficial when MR is the consequence of LV dilatation and remodeling. The validity of this theory was tested by analyzing the outcome after MitraClip procedure of MITRA-FR and COAPT populations^[17]. Accordingly, we can try to identify four cohorts of patients with specific clinical phenotypes and different goals which can be achieved with TMVR:

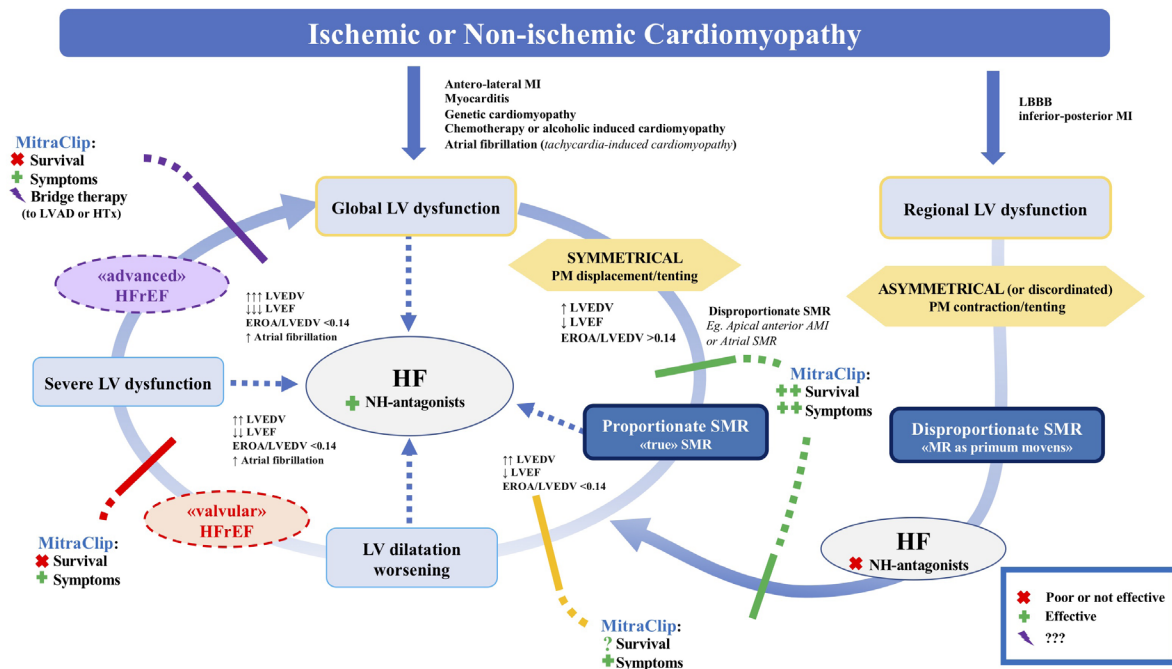


Figure 2. Prognostic role of secondary mitral regurgitation and impact of transcatheter mitral valve repair. The impact of transcatheter mitral valve repair on four cohorts of patients with specific clinical phenotypes: (1) The green line indicates patients with disproportionate MR (MR is the “primum movens”) exhibiting both symptoms and mortality reduction (5 COAPT subgroups, 492 patients), including patients with disproportionate MR, symmetrical LV dysfunction, and PM displacement/tenting (e.g., apical anterior AMI); (2) The yellow line indicates patients with proportionate MR reporting unclear prognostic benefit (COAPT subgroup, 56 patients); (3) The red line indicates patients with proportionate MR exhibiting only symptoms reduction (MITRA-FR patients, 304 patients); (4) The purple line indicates advanced HF patients with proportionate MR showing clinical and hemodynamic stabilization (or improvement) as bridge therapy. AMI: acute myocardial infarction; HF: heart failure; HFref: heart failure with reduced ejection fraction; HTx: heart transplantation; LBBB: left bundle branch block; LV: left ventricle; LVAD: left ventricular assist device; LVEDV: left ventricle end diastolic volume; LVEF: left ventricular ejection fraction; MI: myocardial infarction; NH: neurohormonal antagonist (beta-blockers, ACE-inhibitors, RAAS blockers, Nephilysin, *etc.*); PM: papillary muscle; SMR: secondary mitral regurgitation. Adapted and modified from Godino *et al.*^[7]

1. Patients with disproportionate MR (in which MR is the “primum movens”) exhibiting both symptoms and mortality reduction (COAPT subgroups, 492 patients); patients with disproportionate MR caused by PM displacement/tenting in a symmetrical LV dysfunction (e.g., apical-anterior acute myocardial infarction); and patients with HFpEF and/or AF causing *disproportionate* MR due to mitral annulus dilatation (atrial-secondary MR) (the green line in [Figure 2](#)).
2. Patients with proportionate MR (“true secondary” MR) exhibiting only symptoms reduction (304 MITRA-FR patients) (the red line in [Figure 2](#)).
3. Patients with proportionate MR reporting unclear prognostic benefit (COAPT subgroup, 56 patients) with “MITRA-FR like” survival at 1 year and “COAPT-like” survival at 2 years (the yellow line in [Figure 2](#))^[21]

The latter group is underrepresented but suggests that a significant benefit cannot be excluded also for patients with “true secondary MR” treated in an early phase of the HF process, before progression to severe LV dilation and before AF onset. All these considerations should be appraised as preliminary and, in any case, not absolute, because they are derived from the post hoc analysis of the COAPT trial and based on relatively small numbers of patients. This theory was tested in a “real-world” population; however, the absence of significant differences may have been undermined by the presence of few patients with proportionate MR (according to Grayburn’s cut-off)^[22]. Therefore, this conceptual framework of proportionate/disproportionate MR needs to be weighed and confirmed on larger patient series before being considered as a definitive risk-benefit threshold^[17].

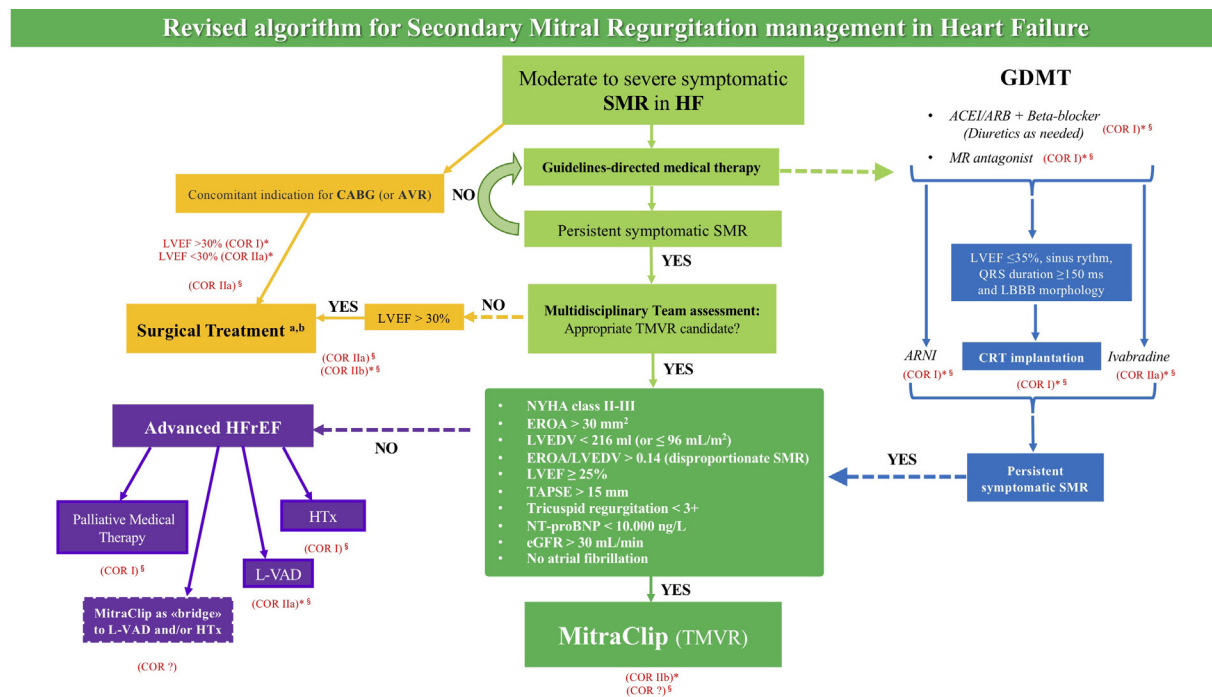


Figure 3. Revised algorithm for secondary mitral regurgitation management in heart failure. Symptomatic, NYHA Class II-IV. Evaluation of clinical context, symptomatology, etiology of MR, and MR severity using a multiparametric approach. *ESC/EACTS/HFA Guidelines; §ACC/AHA/HFSA Guidelines. a: in patients undergoing CABG or AVR, ACC/AHA/HFSA Guidelines do not consider baseline LVEF in the therapeutic decision-making process for concomitant valvular surgery; b: according to ACC/AHA/HFSA Guidelines, it is reasonable to choose chordal-sparing mitral valve replacement for chronic severe ischemic SMR (COR IIa), whereas mitral valve repair or replacement may be considered for chronic severe secondary MR (COR IIb) in patients undergoing isolated mitral surgery. ACEI: angiotensin-converting enzyme inhibitor; ARB: angiotensin receptor blocker; ARNI: angiotensin receptor neprilysin inhibitor; AVR: aortic valve replacement; CABG: coronary artery by-pass graft; CHF: chronic heart failure; COPD: chronic obstructive pulmonary disease; COR: class of recommendation; CRT: cardiac resynchronization therapy; eGFR: estimated glomerular filtration rate; EROA: effective regurgitant orifice area; GDMT: guideline-directed medical therapy; HF: heart failure; HFrEF: heart failure with reduced ejection fraction; HTx: heart transplantation; LBBB: left bundle branch block; Log EuroSCORE: Logistic European System for Cardiac Operative Risk Evaluation; L-VAD: left ventricular assist device; LVEDV: left ventricular end-diastolic volume; LVEF: left ventricular ejection fraction; MR: mineralocorticoid receptor; NT-proBNP: N-terminal pro-B type natriuretic peptide; NYHA: New York Heart Association; SMR: secondary mitral regurgitation; TAPSE: tricuspid annular plane systolic excursion. Adapted and modified from Godino *et al.*^[7]

Despite these limitations, we can reasonably assume that most of patients with advanced HF exhibit the classic pathophysiologic features of “true secondary” MR (proportionate MR) together with other unfavorable co-pathologies (CKD, DM, AF, PVD and severe COPD). In these cases, a less favorable response is to be expected after TMVR with MitraClip, because the underlying advanced cardiomyopathy and the co-pathologies are not the direct target of the intervention. However, even the mere symptoms reduction and the hemodynamic stabilization can be important goals for most of these patients and can be achieved with the combination of GDMT and TMVR:

- Advanced HF patients with proportionate MR aim for clinical and hemodynamic stabilization (or improvement) as bridge therapy (the purple line in Figure 2).

To combine the current guideline recommendations based on available evidence together with the recently published frameworks for MR and the unexplored setting of advanced HF, we propose a revised algorithm for SMR management in HF patients [Figure 3]^[7,23].

MITRACLIP THERAPY IN ADVANCED HF PATIENTS

The aforementioned analysis of MITRA-FR and COAPT patients in conjunction with further investigations will guide us towards the identification of who will benefit the most from TMVR and which is the proper

timing of intervention. On the contrary, limited data are available regarding advanced HF patients who are excluded from randomized clinical trials and for which the only available evidence derives from observational studies.

Clinical evidence

We can identify the following strategies in performing percutaneous mitral valve repair in advanced HF patients [Figure 1]:

1. Bridge to heart transplantation (BTT)
2. Bridge to HTx candidacy (BTC)
3. Bridge to recovery (BTR)

One of the first papers on MitraClip procedure, reported by Franzen *et al.*^[24] in 2011, showed for the first time that MitraClip implantation was safe and significantly improved the New York Heart Association (NYHA) class of patients with end-stage/advanced HF, especially of those who had significant reduction of MR grade after the procedure. In 2015, Garatti and colleagues described a case report in which the percutaneous mitral valve repair was effective as a BTT^[25]. Similarly, Sankar *et al.*^[26] implanted a MitraClip and a Carillon device (Cardiac Dimensions, Kirkland, WA, USA) in the same patient with the aim of BTT, replicating the surgical counterpart known as “Alfieri technique”^[27]. In a larger cohort of 75 advanced HF patients, the following were observed: symptoms improvement, re-hospitalizations reduction and lower pro-BNP levels after percutaneous mitral valve repair with MitraClip, despite the lack of LV reverse remodeling^[28].

Further evidence derives from a German^[29] proof of concept case series showing that MitraClip is not only feasible in advanced HF patients listed for HTx, but also leads to favorable hemodynamic effects such as lower pulmonary artery pressures. Similar results were described by an Italian^[30] group in which the reduction of pulmonary vascular resistances led to the absence of further hospital admissions for HF and reclassification of these patients who became eligible for HTx. The goal in the latter study was to make use of the percutaneous device as BTC. Another report published in 2017 proved that the MitraClip can promote such a benefit as leading to HTx delisting following an optimal clinical and echocardiographic recovery^[31]: an initial BTT strategy turned into a BTR.

MitraBridge study registry

The ongoing “MitraBridge” registry, presented at EuroPCR 2019, was conducted with the aim of better understanding the outcome after MitraClip in this extreme setting of patients^[32]. This international, multicenter registry collected data for nearly 100 end-stage HF patients treated with the percutaneous device as bridge strategy. Baseline characteristics were clearly different from those belonging to MITRA-FR and COAPT populations: despite a younger age [57.5 years (50-63), median and interquartile range], there were reported lower values of mean ejection fraction (27%), higher percentage of NYHA Classes III-IV (96%), higher mean left ventricular end diastolic volumes indexed (134 mL/m²), elevated mean systolic pulmonary artery pressures (sPAP, 51 mmHg) and mean pulmonary capillary wedge pressures (25 mmHg) and the majority (43%) had an INTERMACS profile of 5-6. At 1 year, two thirds of the cases achieved a primary composite endpoint of elective HTx, entering (or remaining) in HTx list and delisting for clinical improvement; the rest of the patients who did not reach those events were death, implanted with LVAD, transplanted urgently or still waiting for HTx listing. The patients who were delisted exhibited significant clinical improvement represented by marked reductions in NYHA class, sPAP and MR grade, which allowed a BTR.

At present, there is still little knowledge about the real effectiveness and applicability of the MitraClip procedure in the case of advanced HF. Although this procedure is almost ineffective for some of the patients

with advanced HF, it can act as a “bridge” for further invasive treatments (e.g., HTx or MCS) for others. It must be clear that the final goal to perform such interventions in this setting of patients is no longer reducing mortality of course, but to enhance and/or stabilize the clinical status (mainly by reductions of sPAP) and thus the quality of life while awaiting HTx. Consequently, obtaining a symptomatic benefit increases the chances of reaching HTx in a good enough clinical status. More research efforts need to be spent to understand who will more likely benefit from percutaneous mitral valve repair at this stage of the HF. Currently, it is recommended to early refer patients affected by advanced HF to tertiary care centers that can best individualize treatment options (HTx, MCS and bridging solutions) and assure the proper timing for their application.

CONCLUSION

MitraClip implantation in advanced HF patients with concomitant severe MR is safe and can provide significant clinical improvement. Available evidence describes the favorable outcomes obtained with this device resulting in BTT, BTC or BTR. Further studies are needed to investigate the predictors of success for this procedure in this extreme setting of patients in order to provide solid basis for treatment recommendations.

DECLARATIONS

Authors' contributions

Made substantial contributions to conception and design of the study and performed data analysis and interpretation: Scotti A, Godino C

Provided final revision and administrative support: Margonato A

Availability of data and materials

Not applicable.

Financial support and sponsorship

None.

Conflicts of interest

All authors declared that there are no conflicts of interest.

Ethical approval and consent to participate

Not applicable.

Consent for publication

Not applicable.

Copyright

© The Author(s) 2020.

REFERENCES

1. Iung B, Vahanian A. Epidemiology of valvular heart disease in the adult. *Nat Rev Cardiol* 2011;8:162-72.
2. Sannino A, Smith RL, Schiattarella GG, Trimarco B, Esposito G, et al. Survival and cardiovascular outcomes of patients with secondary mitral regurgitation: a systematic review and meta-analysis. *JAMA Cardiol* 2017;2:1130-9.
3. Godino C, Scotti A, Taramasso M, Adamo M, Russo M, et al. Two-year cardiac mortality after MitraClip treatment of functional mitral regurgitation in ischemic and non-ischemic dilated cardiomyopathy. *Int J Cardiol* 2018;269:33-9.
4. Goliash G, Bartko PE, Pavo N, Neuhold S, Wurm R, et al. Refining the prognostic impact of functional mitral regurgitation in chronic heart failure. *Eur Heart J* 2018;39:39-46.
5. Adamo M, Godino C, Giannini C, Scotti A, Liga R, et al. Left ventricular reverse remodelling predicts long-term outcomes in patients

- with functional mitral regurgitation undergoing MitraClip therapy: results from a multicentre registry. *Eur J Heart Fail* 2018;21:196-204.
6. Godino C, Salerno A, Cera M, Agricola E, Fragasso G, et al. Impact and evolution of right ventricular dysfunction after successful MitraClip implantation in patients with functional mitral regurgitation. *IJC Hear Vasc* 2016;11:90-8.
7. Godino C, Munafò A, Sisinni A, Margonato A, Saia F, et al. MitraClip treatment of secondary mitral regurgitation in heart failure with reduced ejection fraction: lessons and implications from trials and registries. *Structural Heart* 2020;1-7.
8. Stone GW, Lindenfeld JA, Abraham WT, Kar S, Lim DS, et al. Transcatheter mitral-valve repair in patients with heart failure. *N Engl J Med* 2018;379:2307-18.
9. Obadia JF, Messika-Zeitoun D, Leurent G, Iung B, Bonnet G, et al. Percutaneous repair or medical treatment for secondary mitral regurgitation. *N Engl J Med* 2018;379:2297-306.
10. Crespo-Leiro MG, Metra M, Lund LH, Milicic D, Costanzo MR, et al. Advanced heart failure: a position statement of the Heart Failure Association of the European Society of Cardiology. *Eur J Heart Fail* 2018;20:1505-35.
11. Baumwol J. "I Need Help" - A mnemonic to aid timely referral in advanced heart failure. *J Hear Lung Transplant* 2017;36:593-4.
12. Eurotransplant International Foundation. Annual Report 2018. Vol. 4. AIMS Mathematics; 2019. pp. 166-9. Available from: https://www.eurotransplant.org/wp-content/uploads/2020/05/ET_Jaarverslag_2018.pdf [Last accessed on 13 Jul 2020]
13. Starling RC, Estep JD, Horstmanshof DA, Milano CA, Stehlik J, et al. Risk assessment and comparative effectiveness of left ventricular assist device and medical management in ambulatory heart failure patients: the ROADMAP study 2-year results. *JACC Hear Fail* 2017;5:518-27.
14. Mehra MR, Canter CE, Hannan MM, Semigran MJ, Uber PA, et al. The 2016 international society for heart lung transplantation listing criteria for heart transplantation: a 10-year update. *J Hear Lung Transplant* 2016;35:1-23.
15. Patel JB, Borgeson DD, Barnes ME, Rihal CS, Daly RC, et al. Mitral regurgitation in patients with advanced systolic heart failure. *J Card Fail* 2004;10:285-91.
16. Lancellotti P, Garbi M. Progression of secondary mitral regurgitation: From heart failure to valvular heart failure. *Eur Heart J Cardiovasc Imaging* 2018;19:613-4.
17. Packer M, Grayburn PA. New evidence supporting a novel conceptual framework for distinguishing proportionate and disproportionate functional mitral regurgitation. *JAMA Cardiol* 2020; doi: 10.1001/jamacardio.2019.5971.
18. Packer M, Grayburn PA. Neurohormonal and transcatheter repair strategies for proportionate and disproportionate functional mitral regurgitation in heart failure. *JACC Heart Fail* 2019;7:518-21.
19. Packer M, Grayburn PA. Contrasting effects of pharmacological, procedural, and surgical interventions on proportionate and disproportionate functional mitral regurgitation in chronic heart failure. *Circulation* 2019;140:779-89.
20. Grayburn PA, Sannino A, Packer M. Proportionate and disproportionate functional mitral regurgitation: a new conceptual framework that reconciles the results of the MITRA-FR and COAPT trials. *JACC Cardiovasc Imaging* 2019;12:353-62.
21. Food and Drug Administration. Summary of safety and effectiveness (SSED): MitraClip NT Clip Delivery System, MitraClip NTR/XTR Clip Delivery System. Available from: https://www.accessdata.fda.gov/cdrh_docs/pdf10/P100009S028B.pdf [Last accessed on 10 Jul 2020]
22. Adamo M, Cani DS, Gavazzoni M, Taramasso M, Lupi L, et al. Impact of disproportionate secondary mitral regurgitation in patients undergoing edge-to-edge percutaneous mitral valve repair. *EuroIntervention* 2020; doi: 10.4244/EIJ-D-19-01114.
23. Bonow RO, O'Gara PT, Adams DH, Badhwar V, Bavaria JE, et al. 2020 focused update of the 2017 ACC expert consensus decision pathway on the management of mitral regurgitation: a report of the American college of cardiology solution set oversight committee. *J Am Coll Cardiol* 2020;75:2236-70.
24. Franzen O, van der Heyden J, Baldus S, Schlüter M, Schillinger W, et al. MitraClip® therapy in patients with end-stage systolic heart failure. *Eur J Heart Fail* 2011;13:569-76.
25. Garatti A, Castelvécchio S, Bandera F, Medda M, Menicanti L. Mitraclip procedure as a bridge therapy in a patient with heart failure listed for heart transplantation. *Ann Thorac Surg* 2015;99:1796-9.
26. Sankar NM, Ramani SS, Anantharaman R, Cherian KM. MitraClip and mitral annuloplasty device as a bridge to transplantation. *Asian Cardiovasc Thorac Ann* 2018;26:57-9.
27. Alfieri O, Maisano F, De Bonis M, Stefano PL, Torracca L, et al. The double-orifice technique in mitral valve repair: a simple solution for complex problems. *J Thorac Cardiovasc Surg* 2001;122:674-81.
28. Berardini A, Biagini E, Saia F, Stolfo D, Previtali M, et al. Percutaneous mitral valve repair: The last chance for symptoms improvement in advanced refractory chronic heart failure? *Int J Cardiol* 2017;228:191-7.
29. Geis NA, Plegier ST, Bekeredjian R, Chorianopoulos E, Kreusser MM, et al. Haemodynamic effects of percutaneous mitral valve edge-to-edge repair in patients with end-stage heart failure awaiting heart transplantation. *ESC Hear Fail* 2018;5:892-901.
30. Crimi G, Gritti V, Ghio S, Crescio V, Magrini G, et al. MitraClip procedure as 'bridge to list', the ultimate therapeutic option for end-stage heart failure patients not eligible for heart transplantation due to severe pulmonary hypertension. *Pulm Circ* 2018;8:2045894018791871.
31. Godino C, Scotti A, Agricola E, Pivato CA, Chiarito M, et al. Young patient with advanced heart failure no longer a candidate for heart transplantation after MitraClip® procedure. *J Heart Valve Dis* 2017;26:234-6.
32. Godino C, Munafò A, Scotti A, Estévez-Loureiro R, Portolés Hernández A, et al. Transcatheter mitral valve repair with MitraClip as bridge therapy for heart transplantation: one-year outcome from the international MitraBridge registry. *EuroPCR - Late Breaking Trials* 2019. Available from: [https://media.pcronline.com/diapos/EuroPCR2019/3333-20190521_1600_Room_342A_Godino_Cosmo_1111_\(7448\)/Godino_Cosmo_20190521_1530_Room_342A.pdf](https://media.pcronline.com/diapos/EuroPCR2019/3333-20190521_1600_Room_342A_Godino_Cosmo_1111_(7448)/Godino_Cosmo_20190521_1530_Room_342A.pdf) [Last accessed on 13 Jul 2020]