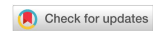

Review

Open Access



Magnetic-assisted surgery: the road from laparoscopy to robotics

Gustavo Romero-Velez¹, Dana Portenier², Jay Roberts³, Rodolfo J. Oviedo^{4,6,7}, Alberto Rodriguez-Navarro⁵, Matthew D. Kroh⁸

¹Endocrine and Metabolism Institute, Cleveland Clinic, Cleveland, OH 44195, USA.

²Metabolic and Weight Loss Surgery Division, Duke University, Durham, NC 27710, USA.

³Department of Surgery, University of North Texas Health Science Center, Fort Worth, TX 76107, USA.

⁴Department of Surgery, Houston Methodist, Houston, TX 77030, USA.

⁵Levita Magnetics Corporation, Menlo Park, CA 94402, USA.

⁶Weill Cornell Medical College, Cornell University, Ithaca, NY 14850, USA.

⁷Texas A&M College of Medicine, Bryan, TX 77807, USA.

⁸Digestive Disease and Surgery Institute. Cleveland Clinic, Cleveland, OH 44195, USA.

Correspondence to: Prof. Matthew D. Kroh, Digestive Disease and Surgery Institute, Cleveland Clinic, 9500 Euclid Avenue, Mail Code A-100, Cleveland, OH 44195, USA. E-mail: krohm@ccf.org

How to cite this article: Romero-Velez G, Portenier D, Roberts J, Oviedo RJ, Rodriguez-Navarro A, Kroh MD. Magnetic-assisted surgery: the road from laparoscopy to robotics. *Mini-invasive Surg* 2022;6:56. <https://dx.doi.org/10.20517/2574-1225.2022.51>

Received: 19 May 2022 **First Decision:** 29 Aug 2022 **Revised:** 7 Sep 2022 **Accepted:** 30 Sep 2022 **Published:** 2 Nov 2022

Academic Editor: Giulio Belli **Copy Editor:** Jia-Xin Zhang **Production Editor:** Jia-Xin Zhang

Abstract

The incorporation of magnetic fields into surgery to reduce the invasiveness of minimally invasive surgery led to the creation of magnetic-assisted surgery. External magnets coupled with their internal counterparts assist during surgical procedures, avoiding the need for additional trocars. Multiple advances have been made in this field in the past 15 years, with new promising technologies being developed. This review centers on the history of magnetic-assisted surgery and the available evidence of its safety, benefits and discusses the very promising combination of this new paradigm-shift technology with robotics.

Keywords: Minimally invasive surgery, magnetic-assisted surgery, magnet, remote-controlling

INTRODUCTION

The beginnings of minimally invasive surgery (MIS) can be traced back to the twentieth century^[1]. The first MIS procedures were an appendectomy by Semm in 1982 and a cholecystectomy by Muhe in 1985^[2].



© The Author(s) 2022. **Open Access** This article is licensed under a Creative Commons Attribution 4.0 International License (<https://creativecommons.org/licenses/by/4.0/>), which permits unrestricted use, sharing, adaptation, distribution and reproduction in any medium or format, for any purpose, even commercially, as long as you give appropriate credit to the original author(s) and the source, provide a link to the Creative Commons license, and indicate if changes were made.



Although there was not much attention or acceptance during the first years, they turned out to be the standard of care in the following decades^[3,4]. Over time, MIS has demonstrated good surgical outcomes and a quicker recovery^[5]. MIS is an evolving field with emerging techniques and technologies in an attempt to decrease the traumatic insult to the body that surgery represents. Based on these principles, the field of magnetic-assisted laparoscopic surgery was first established^[6,7].

Magnetism is a physical property of certain metals which produces either a pulling or a pushing force between two objects. The existence of natural magnets (Fe_3O_4) has been known to humankind for thousands of years^[8]. However, the most primitive records show that the application of these electrical properties into medicine was likely introduced by the ancient Hindus, who used them to remove foreign bodies beneath the skin^[9]. Since then, the inclusion of magnetic fields in medicine has expanded with multiple diagnostic and therapeutic uses^[10]. In fact, magnetic surgery includes but is not limited to magnetic compression anastomosis (Magnamosis), magnetic anchoring technique, magnetic navigation technique, magnetic sphincter augmentation, self-assembling magnets for endoscopic intestinal bypass, magnetic compression ostomy, and correction of congenital deformities^[11]. For the purpose of the current manuscript, magnetic-assisted surgery will be used in relation to magnetic anchoring technique.

Looking at the long history of magnetism in medicine and surgery, its incorporation into MIS is relatively new. While MIS has already proven to decrease pain, given its relatively small incisions compared to open surgery, it still involves an insult to the body. Motivated to further decrease the transgression to the body, researchers have developed the concept of magnetic-assisted surgery in the past years. The advantage of this technology is to provide the same traction and counter-retraction necessary during surgery without making additional incisions. This review will describe the timed development of the technology through the different studies summarized in [Table 1](#).

IN-VIVO ANIMAL MODELS

In 2007, Park and Cadeddu, described the “magnetic anchoring and guidance system” (MAGS), which was tested in a porcine laparoscopic surgery model^[6]. Their prototype consisted of a stack of neodymium-iron-boron ($\text{Nd}_2\text{Fe}_{14}\text{B}$) permanent magnets with a 5.7 cm external device and a 0.95 cm internal device. MAGS allowed surgeons to control the instruments and complete a laparoscopic nephrectomy without complications or losing the coupling of the magnets. The authors brought up two important points to consider in magnetic-assisted surgery. One was the decreased coupling strength with increasing distance between the magnets, which needs to be accounted for in thicker abdominal walls. The other was the minimum distance of 3 cm between magnets to avoid interference when using more than one pair simultaneously.

The same investigators later employed MAGS to perform transvaginal cholecystectomies in porcine models^[12]. Due to instrumentation shortcomings, two of their four procedures had to be ended prematurely. The authors mentioned that there was suboptimal retraction and inadvertent magnetic coupling between the instruments, which were solved by the learning curve in later cases. Nevertheless, they concluded that MAGS platform facilitated tissue triangulation, making magnetic-assisted surgery feasible but under development.

An independent group in Japan used an outer 3.9 cm coupled with an inner 1.0 cm $\text{Nd}_2\text{Fe}_{14}\text{B}$ magnet to complete a porcine laparoscopic cholecystectomy and a laparoscopic anterior resection^[13,14]. In their experiment, the extracorporeal magnet was moved on the abdominal wall, changing the position of the intra-peritoneal magnet and providing variable traction of the gallbladder. Importantly, the study describes

Table 1. Current publications of magnetic surgery

Author	Year	Country	Surgery	Design	n	Conclusion
Park <i>et al.</i> ^[6]	2007	USA	Laparoscopic nephrectomy	Porcine model	2	Trocar-less laparoscopy using magnetically anchored instruments is feasible
Dominguez ^[7]	2007	Argentina	Laparoscopic cholecystectomy	Case report	1	Magnetic instruments can provide traction and counter traction
Scott <i>et al.</i> ^[12]	2007	USA	Transvaginal cholecystectomy	Porcine model	4	Magnetic surgery is under development but feasible.
Kume <i>et al.</i> ^[13]	2008	Japan	Laparoscopic cholecystectomy	Porcine model	1	Magnet-retracting forceps provide port-less access to the abdominal cavity
Kume <i>et al.</i> ^[14]	2008	Japan	Laparoscopic anterior resection	Porcine model	1	Endoluminal magnetic anchors provide effective retraction
Dominguez <i>et al.</i> ^[15]	2009	Argentina	Laparoscopic cholecystectomy	Case series	40	Triangulation with forceps controlled by magnetic fields appears to be feasible and safe
Morales-Conde <i>et al.</i> ^[16]	2011	Spain	Laparoscopic sleeve gastrectomy	Case report	1	Single-port approach with the aid of magnetic forceps is feasible and safe in expert hands
Martinez-Ferro <i>et al.</i> ^[17]	2012	Argentina	Laparoscopic Nissen	Case report	1	Nissen fundoplication with magnetic guidance is a feasible procedure
Rivas <i>et al.</i> ^[18]	2016	Chile	Laparoscopic cholecystectomy	Prospective single arm	50	Safe and feasible
Haskins <i>et al.</i> ^[19]	2017	USA	Laparoscopic cholecystectomy	Case series	10	Safe, feasible and reduces the number of trocars
Guerron <i>et al.</i> ^[20]	2017	USA	Robotic-assisted cholecystectomy	Case report	1	Combination of robot and magnetic surgery is feasible
Davalos <i>et al.</i> ^[21]	2019	USA	Laparoscopic right colectomy Laparoscopic sigmoidectomy Laparoscopic rectopexy	Case series	10	Safe, dynamic and incision-less
Davis <i>et al.</i> ^[22]	2019	USA	Laparoscopic sleeve gastrectomy Laparoscopic RYGB Laparoscopic BPD-DS Laparoscopic revision Laparoscopic band removal	Retrospective	73	Device successfully permitted optimal liver retraction while decreasing the number of abdominal incisions
Steinberg <i>et al.</i> ^[25]	2018	USA	Robot-assisted radical prostatectomy	Case series	3	Safe and effective retraction Reduce the number of ports
Steinberg <i>et al.</i> ^[26]	2019	USA	Reduced port robotic-assisted radical prostatectomy	Case series	16	Magnetic system avoids the need for a 4 th robotic arm Safe and effective
Steinberg <i>et al.</i> ^[27]	2019	USA	Single port robotic-assisted radical prostatectomy	Retrospective	15	Magnetic retractor facilitates tissue exposure and improves procedure ergonomics mimicking multiport technique
Luengas <i>et al.</i> ^[23]	2020	Chile	Laparoscopic sleeve gastrectomy Laparoscopic RYGB Laparoscopic BPD-DS Laparoscopic Revision	Prospective single arm	50	Adequate retraction, well tolerated and avoids epigastric incision
Barajas-Gamboa <i>et al.</i> ^[35]	2020	Chile	Laparoscopic cholecystectomy	Case series	10	Novel combination of magnetic and robotic technologies is safe and feasible
Ganesan <i>et al.</i> ^[29]	2020	USA	Robotic-assisted sacrocolpopexy	Case series	3	Magnet eliminates the need for an additional trocar
Fulla <i>et al.</i> ^[30]	2020	USA	Robotic partial nephrectomy Robotic radical nephrectomy Robotic pyeloplasty Laparoscopic donor nephrectomy Laparoscopic radical nephrectomy	Prospective single arm	10	Safe and feasible. Useful to expose the renal hilum
Huang <i>et al.</i> ^[28]	2020	USA	Robotic-assisted prostatectomy	Retrospective	39	Safe and reproducible tissue retraction while not requiring additional incisions
Roberts <i>et al.</i> ^[24]	2020	USA	Laparoscopic sleeve gastrectomy	Retrospective	50	Same-day discharge magnetic sleeve gastrectomy is safe and feasible
Welsh <i>et al.</i> ^[34]	2021	USA	Laparoscopic sleeve	Retrospective	100	Lower pain score at 12 h

			gastrectomy Laparoscopic RYGB Laparoscopic BPD-DS	case-control		Lower length of stay Higher OR supply cost
Chen <i>et al.</i> ^[31]	2021	China	Thoracoscopic Esophagectomy	Porcine model	10	Magnetic anchoring and traction system is safe and feasible
Fu <i>et al.</i> ^[32]	2022	China	Thoracoscopic Esophagectomy	Prospective single arm	10	Magnetic anchoring and traction system can improve the exposure of RLN

RYGB: Roux-en-Y gastric bypass; BPD-DS: biliopancreatic diversion duodenal switch; OR: operating room; RLN: recurrent laryngeal nerve.

that the magnet did not interfere with the vital signs monitoring of the pig nor with the electro-surgical instruments. The shortcomings of this technology raised by the authors were the susceptibility of neodymium to corrosion, which could pose a risk to the human body, and the potential interactions between magnets and other surgical instruments.

FIRST CLINICAL APPLICATION

The first reported clinical application of magnetic-assisted surgery in the literature was by Dominguez in 2007^[7]. In this original report, a series of Nd₂Fe₁₄B magnets attached to an alligator grasper (TD-magnet) were used to retract the gallbladder fundus and infundibulum during a laparoscopic cholecystectomy. The inner magnets are controlled with external magnets to achieve triangulation. The surgery was done in 90 min, and the patient was discharged within 24 h without complications. Later on, the author reported 40 consecutive cases of laparoscopic cholecystectomy using TD-magnets^[15]. Their technique involved a single 12 mm trocar in patients with a mean body mass index (BMI) of 28 kg/m² without acute cholecystitis or pacemakers. In this study, the authors completed all procedures laparoscopically without the need for extra ports in a mean time of 93 min. There were no interactions between the TD-magnet and the vital signs monitoring or the other devices in the operating room. However, the magnet fell in two cases, requiring x-rays to localize it.

Further on, Morales-Conde *et al.* reported the first case of a single-port laparoscopic sleeve gastrectomy using the TD-magnet for retraction^[16]. The case involved a 51-year-old female with a BMI of 45 kg/m². Using a 2.5 cm transverse incision with the assistance of the magnets for proper traction and triangulation, the authors were able to complete the surgery in 120 min without the need for additional trocars. No perioperative or postoperative complications were reported. The authors concluded that surgery using magnetic forceps is feasible and safe in the hands of experienced laparoscopic surgeons. In a similar fashion and without complications, a laparoscopic Nissen fundoplication was performed using a single incision with the adjunct of magnetic forceps^[17].

FIRST PROSPECTIVE CLINICAL TRIAL

These prototypes established the initial basis of magnetic-assisted surgery, but more adjustments were still to come. The first clinical trial of the Magnetic Surgical System (MSS) [Figure 1] by Levita Magnetics Corp. (Menlo Park, CA) took place from January 2014 to March 2015^[18]. MSS consists of an external reusable magnet and a single-use grasper with a detachable magnetic tip that provides dynamic retraction. The instrument is compatible with a 10 mm trocar, and once it is attached to the target organ, the tip is released and coupled with the external magnet providing traction for the desired intervention. In a study by Rivas *et al.*, the safety and feasibility of the device were investigated using a prospective, multicenter, single-arm, open-label study^[18].



Figure 1. Magnetic surgical system (Levita Magnetics, Menlo Park, CA). (A) Magnetic grasper. (B) Magnetic controller. Reproduced with permission of Levita Magnetics.

A total of 50 patients with a mean BMI of 27 kg/m² underwent a 3-port laparoscopic cholecystectomy with the assistance of the MSS at three different hospitals. The average procedure time was 63 min, with 90% of the surgeons reporting “excellent” exposure. There were no device malfunctions, major complications, or serious adverse events related to the device. Although no external abdominal wall abnormalities were noted, in 38% of the patients, internal petechiae were noted and presumed to be related to the magnetic device without clinical significance. The authors concluded that MSS is safe and feasible as the study met the outlined endpoint criteria^[18].

FIRST APPLICATION IN THE UNITED STATES

In 2017 the Food and Drug Administration (FDA) cleared the use of the Levita MSS for laparoscopic cholecystectomy in patients with a BMI range of 20 to 34 kg/m² (DEN150007/K171429). After that, the first case series in the US was reported by Haskins and Kroh^[19]. A total of ten patients with a mean BMI of 27.6 kg/m² underwent the procedures on an average of 64.4 min without perioperative complications. In addition, all surgeons in the study reported that the system was easy to learn and simple to manipulate, providing adequate tissue retraction.

Guerron *et al.* employed for the first time the MSS in conjunction with the *da Vinci* Single-Port platform (Intuitive Surgical, Sunnyvale, CA)^[20]. In their case report, a 48-year-old patient with a BMI of 33 kg/m² underwent a robotic-assisted cholecystectomy in 58 min. No operative complications were reported and the patient was discharged home the same day. The authors concluded that the combination of technologies was feasible, and the addition of the magnetic retractor helped overcome the challenges of single-port robotic surgery by incorporating shaftless interaction and collision.

These first reports using MSS in the US noted some limitations of this new technology that prompted further studies in the area. One of them was the narrow criteria for using the magnetic retractor^[19]. The second disadvantage in cholecystectomy was associated with a higher BMI and related increased abdominal wall thickness, as well as the known decreased coupling strength with increasing distance from prior studies^[6,20].

SHIFTING BEYOND GALLBLADDER

Davalos *et al.* reported a case series of laparoscopic colorectal procedures where the MSS was used^[21]. Four single-port right colectomies, one sigmoidectomy, and five rectopexies were done consecutively using the

magnetic grasper. The device successfully assisted with the retraction of the colon, uterus and mesentery. For the first time, two patients in the series had a BMI > 34 kg/m²; in one of them, the surgery was converted to open due to dense adhesions. Although the operative time was marginally longer, the authors attributed this to the learning curve inherent to a new technology.

A retrospective study by Davis *et al.* evaluated the use of MSS in bariatric surgery^[22]. A total of 63 primary surgeries and 10 revisions were included, with a mean BMI of 43.6 kg/m². The magnetic device was used to retract the liver. The surgeons were able to set up the device with adequate liver retraction in less than 5 min. The authors acknowledged the need for comparative studies against other retractors. However, they consider magnetic retraction a viable option in patients with severe obesity, and other authors subsequently confirmed this finding^[22-24].

Urology is another field that has incorporated MSS into its practice. Four studies reported the adjunct use of magnetic-assisted surgery during robotic-assisted radical prostatectomies^[25-28]. A total of 31 patients from two institutions underwent the procedures without associated adverse outcomes or compromise of the fundamental steps of the procedure. MSS allowed the sparing of the 4th robotic arm in all of the surgeries. The magnetic retractor was used to retract the colon, bladder, and seminal vesicles, with no crush injuries noted on the tissues^[27]. Nevertheless, the surgeons reported weaker magnetic coupling related to an increased body wall thickness in two patients with BMI > 35 kg/m²^[25].

Other applications of magnetic retraction using MSS include robotic-assisted laparoscopic sacrocolpopexy, robotic-assisted partial nephrectomies, robotic-assisted pyeloplasty, laparoscopic radical nephrectomy and laparoscopic donor nephrectomy^[29,30]. In these studies, no adverse events have been reported and the authors recognized adequate exposure during dissection.

As the field of magnetic-assisted surgery has evolved, newer adaptations have emerged. These evolutions have expanded beyond the field of abdominal surgery. In fact, its use in thoracic surgery has also been described. Chen *et al.* described the use of the magnetic anchoring and traction system (MATS) to facilitate esophageal dissection in a porcine model^[31]. This system is composed of an external unit of Nd₂Fe₁₄B covered with nickel and an internal stainless steel cylinder. In their study, the use of MATS allowed them to perform the intended procedures safely with the advantage of decreasing the number of trocars used, avoiding the chopstick effect and reducing the damage to the thoracic wall.

A follow-up study by the same group proved the safety and feasibility of MATS *in vivo*^[32]. In a prospective way, ten patients undergoing thoracoscopic esophagectomy were enrolled. All of the patients underwent surgery with MATS, providing retraction of the proximal esophagus. The authors report that the traction provided by MATS allowed them to identify the recurrent laryngeal nerve adequately. This study provided further evidence that the use of magnetic-assisted surgery reduces the trauma to the chest wall. However, certain limitations including the possibility of magnetization of the internal cylinder and the loss of coupling were noted, which warrant further improvements of this novel system.

FOLLOW-UP CLINICAL TRIALS

The increased use and applicability of the MSS provoked further controlled studies to evaluate the safety and effectiveness of the device in different populations. A prospective, single-arm study included 50 patients undergoing bariatric surgery at two centers^[23]. The mean BMI of the study population was 40.7 kg/m², with the majority of them undergoing sleeve gastrectomy. In all of the cases, MSS provided adequate liver mobilization with an average time of 1 min to be deployed. A total of 22 mild adverse events were reported

related to the device, including peritoneal petechiae and a minor liver capsule abrasion. Two major events occurred during the study unrelated to the subject device. In April 2020, the FDA approved the use of MSS in patients with BMI 20-60 kg/m²^[33].

While the safety and feasibility of magnetic-assisted surgery been studied in different procedures, the question of its sustained benefit is still a matter of debate. A retrospective case-matched comparison between MSS and an external retractor was made by Welsh *et al.*^[34]. In this study, 100 patients operated with MSS were compared to 196 matched historical controls using the Nathanson retractor. The former had lower pain scores at 12 h (2.9 vs. 3.8; $P = 0.004$) and lower length of stay (LOS) (1.5 vs. 1.8 days; $P = 0.0051$). The results of this study are the first data confirming the clinical benefit of the use of magnetic-assisted surgery in terms of pain reduction and its link to decreased LOS.

FUTURE DIRECTIONS AND LIMITATIONS

One of the main limitations of magnetic-assisted surgery is the fact that the coupling strength of the magnets decreases as a decaying exponential with respect to the distance between the source magnet and its target^[6]. Although this inconvenience was first noted during the animal trials, other groups have accounted for it when used in patients with higher BMI as they tend to have thicker abdominal walls^[25]. Interestingly, in the studies of MATS, the attraction force measured (in Newtons) was compared to the distance between the magnets in millimeters^[31,32]. In the study graphs, it can be seen that with a distance of 80 mm, the force of the magnets is minimal, which can account for the loss of coupling seen in patients with thicker abdominal walls. However, in the study by Luengas *et al.*, the device was able to be used in patients with a BMI up to 58 kg/m²^[23]. These differences might be explained by different strengths of the magnets employed in each study. Set this limitation and the fact that using the same energy for all patients could then, on the other hand, predispose to excessive trauma to the tissues; future technologies may allow applying a tailored force to the distance between the magnets.

The combination of magnetic technologies in robotic cases has decreased the need for extra robotic arms in standard robotic procedures and assisted in the performance of single-port robotic surgery^[25,29,30]. Nevertheless, the MSS still requires manipulation by an assistant at the bedside. This limitation further pushed the development of an integrated system. Barajas-Gamboa *et al.* published the first 10 case series using a Magnetic-Robotic Controller (Levita Magnetix, Menlo Park, CA)^[35]. This system incorporates one robotic arm to control the external magnet to manipulate tissue in real time without the need for an additional assistant. The device is in the sterile field and controlled by the operating surgeon. In this study, all patients successfully underwent a reduced ports laparoscopic cholecystectomy (3 ports avoiding the epigastric incision) in addition to the robotically controlled magnetic grasper. No adverse events were reported and no unintentionally decoupling of the magnets occurred. The authors concluded that the integration of magnetic and robotic surgery was feasible as a proof of concept.

As a next step, a fully robotic magnetic platform was developed by Levita Magnetix [Figure 2]. The concept behind this is to empower the surgeon to perform the surgeries without any other assistant than the robot while providing a less invasive procedure with magnetic-assisted surgery. This disruptive approach to robotics is under evaluation in clinical trials (ClinicalTrials.gov Identifier: NCT05353777) and is expected to be ready for clinical use soon. The motivation is to bring benefits to the patients with a reduced incision technique, increase control and visualization to the surgeon and increase the efficiency of the providers.

CONCLUSIONS

Magnetic-assisted surgery is an extremely promising technology that will further decrease the invasiveness

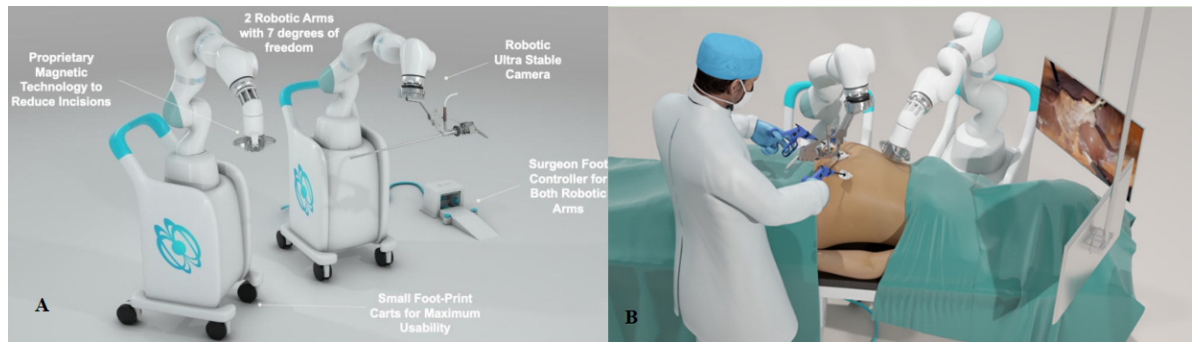


Figure 2. Magnetic-Robotic Controller (Levita Magnetics, Menlo Park, CA). (A) Console with robotic magnetic arms. (B) Schematization of the use of the platform. Reproduced with permission of Levita Magnetics.

of minimally invasive surgery. Although most studies have shown its safety and feasibility, future studies should be aimed to confirm its wider clinical benefits compared to standard treatments in different procedures. Therefore, the combination of robotics and magnetic-assisted surgery is a very logical next step to bring benefits to patients, surgeons and providers.

DECLARATIONS

Author's contributions

Performed the literature review and draft the manuscript: Romero-Velez G, Portenier D

Reviewed the manuscript: Rodriguez-Navarro A, Roberts J, Oviedo RJ

Reviewed, edited the manuscript and guarantor the article: Kroh M

Availability of data materials

Not applicable.

Financial support and sponsorship

None.

Conflicts of interest

Rodriguez-Navarro A: Founder of Levita Magnetics. Other authors declared that there are no conflicts of interest.

Ethical approval and consent to participate

Not applicable.

Consent for publication

Not applicable.

Copyright

© The Author(s) 2022.

REFERENCES

1. Vecchio R, MacFayden BV, Palazzo F. History of laparoscopic surgery. *Panminerva Med* 2000;42:87-90. [PubMed](#)
2. Litynski GS. Erich Mühe and the rejection of laparoscopic cholecystectomy (1985): a surgeon ahead of his time. *JLS* 1998;2:341-6. [PubMed](#) [PMC](#)
3. Minné L, Varner D, Burnell A, Ratzler E, Clark J, Haun W. Laparoscopic vs open appendectomy. Prospective randomized study of outcomes. *Arch Surg* 1997;132:708-11; discussion 712. [DOI](#) [PubMed](#)

4. Southgate E, Vousden N, Karthikesalingam A, Markar SR, Black S, Zaidi A. Laparoscopic vs open appendectomy in older patients. *Arch Surg* 2012;147:557-62. [DOI](#) [PubMed](#)
5. Epstein AJ, Groeneveld PW, Harhay MO, Yang F, Polsky D. Impact of minimally invasive surgery on medical spending and employee absenteeism. *JAMA Surg* 2013;148:641-7. [DOI](#) [PubMed](#)
6. Park S, Bergs RA, Eberhart R, Baker L, Fernandez R, Cadeddu JA. Trocar-less instrumentation for laparoscopy: magnetic positioning of intra-abdominal camera and retractor. *Ann Surg* 2007;245:379-84. [DOI](#) [PubMed](#) [PMC](#)
7. Dominguez GM. Colectistomía con un trócar asistida por imanes de neodimio. Reporte de un caso. Available from: <https://media2.supermagnete.hu/projects/pu450.pdf> [Last accessed on 17 Oct 2022]
8. Keeler R, Singh AD, Dua AD. Eye, magnetism and magnets. *Br J Ophthalmol* 2014;98:425-6. [DOI](#) [PubMed](#)
9. McCasiil MF. An improved hand electromagnet for eye surgery. *Trans Am Ophthalmol Soc* 1958;56:571-605. [PubMed](#) [PMC](#)
10. Yuksel C, Ankarali S, Yuksel NA. The use of neodymium magnets in healthcare and their effects on health. *North Clin Istanb* 2018;5:268-73. [DOI](#) [PubMed](#) [PMC](#)
11. Lv Y, Shi Y; Scientific Committee of the First International Conference of Magnetic Surgery*. Xi'an consensus on magnetic surgery. *Hepatobiliary Surg Nutr* 2019;8:177-8. [DOI](#) [PubMed](#) [PMC](#)
12. Scott DJ, Tang SJ, Fernandez R, et al. Completely transvaginal NOTES cholecystectomy using magnetically anchored instruments. *Surg Endosc* 2007;21:2308-16. [DOI](#) [PubMed](#)
13. Kume M, Miyazawa H, Abe F, et al. A newly designed magnet-retracting forceps for laparoscopic cholecystectomy in a swine model. *Minim Invasive Ther Allied Technol* 2008;17:251-4. [DOI](#) [PubMed](#)
14. Kume M, Miyazawa H, Iwasaki W, Abe F, Uchinami H, Yamamoto Y. The use of magnetic anchors in the bowel lumen for laparoscopic anterior resection of rectosigmoid colon in pigs: with video. *World J Surg* 2008;32:2425-8. [DOI](#) [PubMed](#)
15. Dominguez G, Durand L, De Rosa J, Danguise E, Arozamena C, Ferraina PA. Retraction and triangulation with neodymium magnetic forceps for single-port laparoscopic cholecystectomy. *Surg Endosc* 2009;23:1660-6. [DOI](#) [PubMed](#)
16. Morales-Conde S, Dominguez G, Gomez JC, et al. Magnetic-assisted single-port sleeve gastrectomy. *Surg Innov* 2013;20:NP9-11. [DOI](#) [PubMed](#)
17. Martinez-ferro M, Dominguez G, Millán C. Single-incision laparoscopic nissen fundoplication with adjunctive magnetic guidance. *J Laparoendosc Adv Surg Tech Part B Videoscop* 2012;22:6. [DOI](#)
18. Rivas H, Robles I, Riquelme F, et al. Magnetic surgery: results from first prospective clinical trial in 50 patients. *Ann Surg* 2018;267:88-93. [DOI](#) [PubMed](#) [PMC](#)
19. Haskins IN, Strong AT, Allemang MT, Bencsath KP, Rodriguez JH, Kroh MD. Magnetic surgery: first U.S. experience with a novel device. *Surg Endosc* 2018;32:895-9. [DOI](#) [PubMed](#)
20. Guerron AD, Ortega CB, Park C, Portenier D. Magnetic robot-assisted single-incision cholecystectomy. Available from: <https://crsls.sls.org/wp-content/uploads/2018/09/jls101183674001.pdf> [Last accessed on 17 Oct 2022]
21. Davalos G, Lan BY, Diaz R, et al. Single-center experience with magnetic retraction in colorectal surgery. *J Laparoendosc Adv Surg Tech A* 2019;29:1033-7. [DOI](#) [PubMed](#)
22. Davis M, Davalos G, Ortega C, et al. Magnetic liver retraction: an incision-less approach for less invasive bariatric surgery. *Obes Surg* 2019;29:1068-73. [DOI](#) [PubMed](#)
23. Luengas R, Galindo J, Castro M, et al. First prospective clinical trial of reduced incision bariatric procedures using magnetic liver retraction. *Surg Obes Relat Dis* 2021;17:147-52. [DOI](#) [PubMed](#)
24. Roberts J, Snow R, Novack R, Hall A, Smith A. Same day discharge magnetic sleeve gastrectomy: first 50 cases. *Obesity* 2020;28:40-187. [DOI](#)
25. Steinberg RL, Johnson BA, Cadeddu JA. Magnetic-assisted robotic surgery: initial case series of reduced-port robotic prostatectomy. *J Robot Surg* 2019;13:599-603. [DOI](#) [PubMed](#)
26. Steinberg RL, Johnson BA, Cadeddu JA. Magnetic-assisted robotic surgery to facilitate reduced-port radical prostatectomy. *Urology* 2019;126:237. [DOI](#) [PubMed](#)
27. Steinberg RL, Johnson BA, Meskawi M, Gettman MT, Cadeddu JA. Magnet-assisted robotic prostatectomy using the da VINCI SP robot: an initial case series. *J Endourol* 2019;33:829-34. [DOI](#) [PubMed](#)
28. Huang SF, Welsh LK, Davalos G, Houser RE, Rothman JR, Guerron DA. Robotic assisted prostatectomy with magnetic retraction. *Urol Pract* 2020;7:391-6. [DOI](#)
29. Ganesan V, Goueli R, Rodriguez D, Hess D, Carmel M. Single-port robotic-assisted laparoscopic sacrocolpopexy with magnetic retraction: first experience using the SP da Vinci platform. *J Robot Surg* 2020;14:753-8. [DOI](#) [PubMed](#)
30. Fulla J, Small A, Kaplan-Marans E, Palese M. Magnetic-assisted robotic and laparoscopic renal surgery: initial clinical experience with the Levita magnetic surgical system. *J Endourol* 2020;34:1242-6. [DOI](#) [PubMed](#) [PMC](#)
31. Chen W, Li Y, Qian R, et al. Application of a novel magnetic anchoring and traction technique in thoracoscopic esophagectomy: a swine experiment. *Ann Transl Med* 2021;9:1663. [DOI](#) [PubMed](#) [PMC](#)
32. Fu J, Li Y, Wang Z, et al. The role of magnetic anchoring and traction technique in thoracoscopic lymphadenectomy along the left recurrent laryngeal nerve. *Surg Endosc* 2022;36:3653-62. [DOI](#) [PubMed](#)
33. Chen LH. 510(k) premarket notification. Available from: https://www.accessdata.fda.gov/cdrh_docs/pdf19/K191762.pdf [Last accessed on 17 Oct 2022].
34. Welsh LK, Davalos G, Diaz R, et al. Magnetic liver retraction decreases postoperative pain and length of stay in bariatric surgery

- compared to NATHANSON device. *J Laparoendosc Adv Surg Tech A* 2021;31:194-202. DOI PubMed PMC
35. Barajas-Gamboa JS, Huidobro F, Jensen J, et al. First in-human experience with a novel robotic platform and magnetic surgery system. *Int J Med Robot* 2021;17:1-7. DOI PubMed