

Review

Open Access



Patient selection for trans-catheter mitral valve repair vs. replacement: ongoing indications and glimpse to the future

Andrea Scotti¹, Michele Galasso², Alberto Margonato², Cosmo Godino²

¹Department of Cardiac Thoracic Vascular Sciences and Public Health, University of Padua Medical School, Padua 35128, Italy.
²Cardio-Thoracic-Vascular Department, San Raffaele Scientific Institute, Milan 20132, Italy.

Correspondence to: Dr. Cosmo Godino, Cardio-Thoracic-Vascular Department, San Raffaele Scientific Institute. Via Olgettina 60, Milan 20132, Italy. E-mail: godino.cosmo@hsr.it

How to cite this article: Scotti A, Galasso M, Margonato A, Godino C. Patient selection for trans-catheter mitral valve Repair versus Replacement: ongoing indications and glimpse to the future. *Vessel Plus* 2020;5:6.
<http://dx.doi.org/10.20517/2574-1209.2020.68>

Received: 7 Nov 2020 **First Decision:** 3 Dec 2020 **Revised:** 3 Dec 2020 **Accepted:** 9 Dec 2020 **Published:** 21 Jan 2021

Academic Editor: Manel Sabate **Copy Editor:** Monica Wang **Production Editor:** Jing Yu

Abstract

Transcatheter therapies for patients with severe mitral regurgitation are increasingly performed in recent years. While transcatheter mitral valve repair (TMVR) is now a consolidated intervention with > 100,000 procedures performed worldwide, TMV replacement (TMVRpl) is in its early stages and can only be offered by a few centers. The complexity of mitral valve anatomy requires careful evaluation when selecting the best approach and the most suitable device. At present, the clinical experience with TMVRpl is still in a preliminary phase. Most of the patients treated with this approach thus far are high-risk candidates who have undergone a very restrictive clinical and anatomical selection. Therefore, it is difficult to correctly define which patients might benefit more from TMVRpl than from TMVR. We review the clinical, pathophysiological, and technical factors to suggest when to prefer TMVR instead of a replacement technique.

Keywords: Mitral regurgitation, transcatheter mitral valve repair, transcatheter mitral valve replacement

INTRODUCTION

Percutaneous procedures can be considered a safe alternative to surgical approaches in most patients affected by severe mitral regurgitation (MR). Although transcatheter mitral valve repair (TMVR) is



© The Author(s) 2021. **Open Access** This article is licensed under a Creative Commons Attribution 4.0 International License (<https://creativecommons.org/licenses/by/4.0/>), which permits unrestricted use, sharing, adaptation, distribution and reproduction in any medium or format, for any purpose, even commercially, as long as you give appropriate credit to the original author(s) and the source, provide a link to the Creative Commons license, and indicate if changes were made.



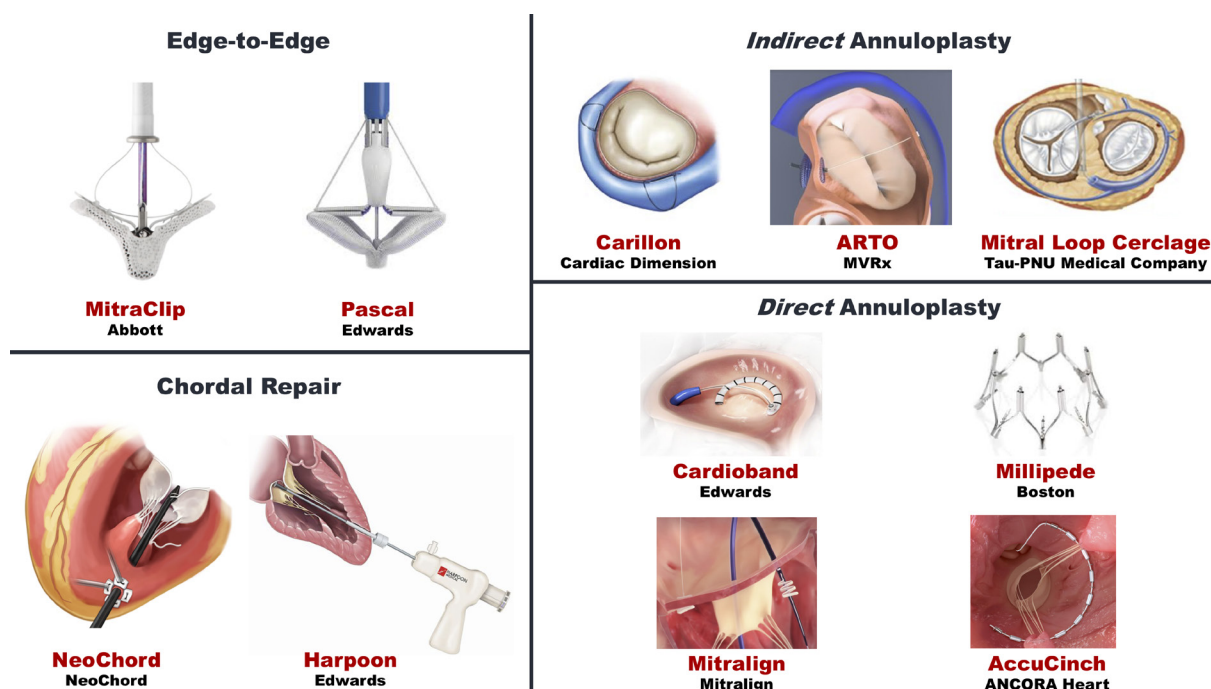


Figure 1. Transcatheter mitral valve repair devices

currently the first choice in most clinical settings, transcatheter mitral valve replacement (TMVRpl) will increasingly be a complementary technique in the near future. Several devices have been approved or are under investigation, permitting a customized strategy based on clinical and anatomical factors.

TRANSCATHETER MITRAL VALVE REPAIR

Taking inspiration from the surgical counterpart, we can classify percutaneous repair techniques [Figure 1] as follows:

- Edge-to-edge (Alfieri-stich) repair: MitraClip and PASCAL
- Percutaneous annuloplasty: Carillon, Cardioband, Millipede, Mitralign, ARTO, AccuCinch, and Mitral Loop Cerclage
- Chordal repair: NeoChord and HarpoonCords

The MitraClip (Abbott Laboratories, Menlo Park, California, USA) is a cobalt–chromium clip with two arms used to grasp and suture together the anterior and posterior valvular leaflets. It is the device with the widest clinical use (> 100,000 procedures worldwide) and proved to be safe and effective in both primary MR (PMR) and secondary MR (SMR)^[1-3]. The PASCAL (Edwards Lifesciences, Irvine, CA) TMVR system is newer and differs from the previous one by an easy steerability, a larger implant size, and broader paddles that can be controlled individually^[4].

Percutaneous annuloplasty can be performed through the coronary sinus (indirect) or reaching the mitral valve from transseptal or retrograde LV access (direct). The indirect approach (Carillon, ARTO, Mitral Loop Cerclage Catheter System) feasibility is limited by unfavorable anatomy of the coronary sinus and its branch veins in a significant proportion of patients. Direct annuloplasty (Cardioband, Millipede, Mitralign, AccuCinch) involves the implantation of anchors around the mitral annulus tethered by the delivery system.



Others: - Braile - Direct Flow - MitrAssist - MitralHeal - ValveXchange - Transcat. Tech. - Lutter - Mehr - Mitralix - MitralTech - Mitracath - Mitralix - Nakostech - St George ATLAS - Venus - Verso - Transmural Systems

Figure 2. Transcatheter mitral valve replacement devices

Chordal repair (NeoChord, HarpoonCords) is obtained through a surgical transapical off-pump approach; no transarterial or transvenous systems are currently available. It is most commonly adopted in high-risk patients with PMR.

TRANSCATHETER MITRAL VALVE REPLACEMENT

TMVRpl is in its early stages and can only be offered by a few centers. This technology has the potential of obtaining predictable and reproducible results, and it is expected to grow rapidly as more clinical data become available.

A transcatheter aortic or pulmonary prosthesis, SAPIEN-XT (Edwards Lifesciences, Irvine, CA) or Melody valve (Medtronic, Minneapolis, MN), can be implanted in patients with severe MR and previous mitral surgery (bioprosthesis or annuloplasty) with valve-in-valve or valve-in-ring procedures or severe mitral annular calcification (valve-in-MAC) in selected individuals who are at too high risk for surgery.

In the case of native mitral valve, the worldwide experience regarding TMVRpl is still limited to slightly more than 500 procedures. All the available devices consist of a self-expanding frame that reproduces a trileaflet biological valve with xenogenic leaflets [Figure 2]. At the moment, the transapical access through anterolateral minithoracotomy is the most used approach: it establishes a great coaxiality with the mitral ring and permits the use of introducers large enough to deliver a much larger valve than the aortic ones. Some valves are built with a characteristic D-shape to conform to the physiological mitral anatomy. The peculiar conformation of the native valve undermines a successful deployment; the radial force is not uniform (as opposed to the aortic devices) and the risks of paravalvular leakage and prosthesis migration are real. For this purpose, different anchoring systems have been envisioned to hold the valve in place by attaching the anchors to the annulus, the subvalvular apparatus, or the left ventricular apex.

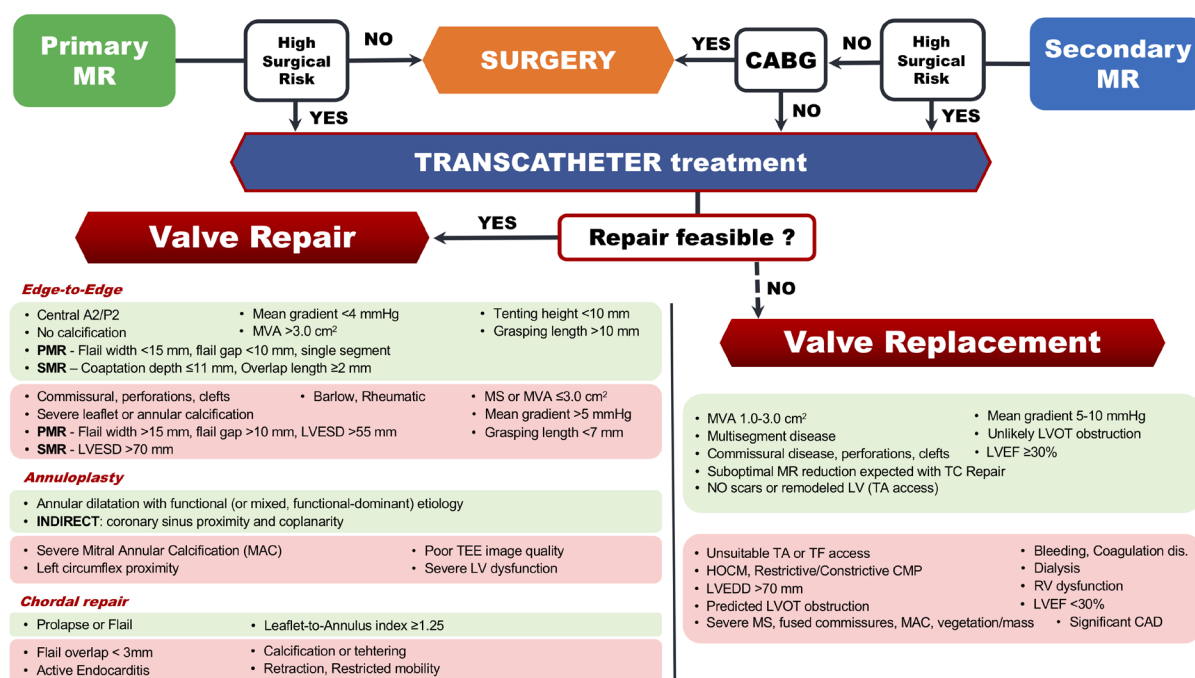


Figure 3. Interventional algorithm for mitral regurgitation. Light green box: favorable feature; light red box: less favorable features or unfeasibility; CABG: coronary artery bypass grafting; CAD: coronary artery disease; CMP: cardiomyopathy; HOCM: hypertrophic obstructive cardiomyopathy; LV: left ventricle; LVEDD: left ventricular end-diastolic diameter; LVEF: left ventricular ejection fraction; LVESD: left ventricular end-systolic diameter; LVOT: left ventricular outflow tract; MS: mitral stenosis; MVA: mitral valve area; PMR: primary mitral regurgitation; RV: right ventricle; SMR: secondary mitral regurgitation; TA: transapical; TC: transcatheter; TEE: transesophageal echocardiography; TF: transfemoral

CLINICAL FACTORS

Primary mitral regurgitation (PMR)

Surgical mitral valve repair, also through minimally invasive access, is effective, with excellent results at long-term follow-up, and represents the gold standard in the case of PMR [Figure 3]. Transcatheter therapies should be reserved for patients at high surgical risk, with reasonable life expectancy, and a considerable symptomatic burden (New York Heart Association class III or IV). These recommendations were driven mainly by analysis of the EVEREST (Endovascular Valve Edge-to-Edge REpair Study) trials and outcomes reported in the REALISM (Real World Expanded Multicenter Study of the MitraClip System) Registry (technical success 95%, stroke 2.4%, unplanned mitral valve surgery 0.8%, and 30-day mortality 6.3%)^[5,6]. Edge-to-edge repair and chordal replacement can be offered to the patients who satisfy those criteria. In this setting, TMVRpl may actually be considered in the absence of favorable anatomy for TMVR techniques.

Secondary mitral regurgitation (SMR)

SMR is by definition associated with a certain degree of atrial or left ventricle (LV) abnormality. Annulus dilation is the main mechanism of atrial SMR and is induced by elevated atrial pressures and eventual atrial fibrillation^[7]. A ventricular-secondary mechanism can be found when the LV is dilated and remodeled to the extent that causes mitral annulus widening and papillary muscles' displacement, which in turn tether the valve leaflets and avoid a competent coaptation. Whether MR is the "primum movens" or an epiphenomenon of LV disease may be assumed by estimating the contribution of LV function to the severity of MR. The ratio between effective regurgitant orifice area and LV end diastolic volume has been proposed as a discriminatory tool to identify proportionate ("true secondary") and disproportionate ("primum movens") MR^[8].

High morbidity/mortality and suboptimal results undermine the surgical treatment (both repair and replacement) of SMR. The surgical approach is clearly indicated in the limited setting of patients with LV ejection fraction (LVEF) > 30% and needing concomitant coronary revascularization through coronary artery bypass grafting (class of recommendation = I for LVEF > 30%, IIa for LVEF ≤ 30%) [Figure 3]^[9]. Therefore, transcatheter therapies are widely used for SMR (technical success 97% and 95.8%, stroke 0.7% and 1.4%, unplanned mitral valve surgery 1% and 0%, and 30-day mortality 2.3% and 3.3%, in COAPT and MITRA-FR trials, respectively^[10,11]).

Edge-to-edge clips, annuloplasty devices, and TMVRpl valves can be used to treat patients with SMR after careful multi-disciplinary assessment^[12]. The contrasting yet complementary results of the two available randomized trials on MitraClip implantation (COAPT and MITRA-FR)^[10,11] make it clear that careful evaluation of clinical and anatomical factors are of primary importance. The response to transcatheter techniques is expected to be less beneficial in the case of severe LV dilatation, long-standing pulmonary hypertension, concomitant atrial fibrillation, and severe chronic kidney disease^[13].

Optimal timing is crucial to obtain the best results in terms of survival and symptomatic benefit. However, a recent international registry has proved that TMVR may extend its therapeutic window even to patients affected by advanced heart failure^[14]. This end-stage population can benefit the most from hemodynamic stabilization, symptomatic relief, and recovery from pulmonary hypertension. These factors can lead these patients to receiving elective heart transplantation in a good clinical status or even being delisted, no longer needing this advanced therapy.

ANATOMICAL AND TECHNICAL FEATURES

Transcatheter mitral valve repair

Criteria defining the optimal candidates for TMVR were initially derived from the EVEREST studies^[15], and subsequently validated and expanded from trials and large real-world registries [Figure 3]. From an anatomical point of view, a flail width ≤ 15 mm, a flail gap < 10 mm, and a single diseased segment are ideal for successful MitraClip placement in PMR. On the contrary, severely and diffusely thickened (5 mm in diastole) and retracted (rheumatic disease) or redundant leaflets (Barlow's type valve) contraindicate TMVR for PMR. The most important factors to be evaluated for SMR treatment are a sufficient leaflet tissue (grasping length > 10 mm), a coaptation length ≥ 2 mm, and a coaptation depth ≤ 11 mm. Leaflets containing perforations, calcifications on the grasping zone, or deep cleft-like indentations are less likely to return good results. Multivariate logistic regression identified preprocedural mitral valve area ≤ 3 cm² and mean mitral valve gradient > 4 mmHg as independent predictors of overall procedural failure^[16].

Severe annular dilation should guide toward a direct or indirect annuloplasty device as first choice or complementary tool. In this case, an angio-CT scan should evaluate the proper size of the mitral valve annulus, the presence of calcifications, and the relations with the circumflex artery.

Transcatheter mitral valve replacement

The complexity of mitral anatomy with its D-shape and well-represented subvalvular apparatus makes TMVRpl much more challenging than its counterpart on aortic valve position.

A meticulous angio-CT study is mandatory in the screening phase and should evaluate:

(1) the functional anatomy of the left ventricular outflow tract (LVOT) with the presence of a mitral aortic angle > 120° and the absence of severe septal hypertrophy to avoid a neo-LVOT obstruction, the most dreaded complication;

- (2) an adequate annular size, which must not be too small not to allow safe anchoring and not too wide to increase the risk of LVOT obstruction;
- (3) the LV function, which could be greatly reduced after TMVRpl;
- (4) the native leaflets and the eventual annular calcifications to find the best implant site, which should be as atrial as possible.

As the transfemoral approach is under development, the patients to be screened must be able to tolerate transapical access. This condition may constitute a great limitation, especially in patients with SMR who have remodeled LVs or ischemic scars.

Structural valve deterioration is a great concern for TMVRpl. The systolic pressure gradient generates a significant mechanical stress on the bioprosthetic mitral valve, resulting in a more frequent degeneration if compared to the aortic counterpart. This rate is increased even more by the young age of the patients (~ 10 years younger than recipients of aortic valves)^[17]. Indeed, greater hemodynamic shear stress, differences in calcium deposition, and residual leaflet antigenicity contribute to a higher tendency of valve degeneration in younger patients^[18].

Another factor to be considered is the feasibility of anticoagulation treatment to avoid device thrombosis. This complication was reported in 3% of patients in TMVRpl studies^[19], which adopted a minimum regimen of three months of anticoagulation mimicking the recommendations from current guidelines regarding conventional surgical mitral valve replacement.

A careful analysis of the enrollment criteria of the TMVRpl trials allows us to identify the patient to be denied or offered this therapy [Table 1]. The presence of a LV (LV end diastolic diameter > 70 mm, LVEF < 30%) or right ventricle (RV) dysfunction, hypertrophic obstructive cardiomyopathy, and restrictive or constrictive cardiomyopathy represent common exclusion criteria [Figure 3]. Comorbidities such as severe chronic kidney disease requiring dialysis, significant coronary artery disease, and bleeding or thrombotic disorders are further unfavorable factors. Regarding the valve apparatus, predicted LVOT obstruction, severe mitral stenosis, fused commissures, prohibitive mitral annulus calcifications, and vegetations or valvular masses have to be avoided. The most important features that favor TMVRpl over TMVR are represented by the prediction of a suboptimal MR reduction with the latter technique and some of the TMVR exclusion criteria such as multisegment or commissural disease, perforations, or clefts. For the reasons outlined above, the ideal patient should have a good LV function (LVEF > 30%) in the absence of scars or remodeled LV walls that could be irreversibly damaged by a transapical access.

FUTURE PERSPECTIVES

Currently, a repair-first strategy is the transcatheter way to go for patients with severe MR. The lessons learned from the surgical experience and the paucity of data on TMVRpl make this approach a second choice^[20]. A percutaneous repair respects the complex anatomy and physiology of the mitral valve. The preservation of the valvular and subvalvular apparatus leads to LV and RV reverse remodeling with improved functional performance^[21,22]. However, the technological progress in transcatheter valves could increase the appeal of TMVRpl therapy if a valve capable of adapting to such variable anatomies was found. This hoped-for result would mean having a device less technically demanding, with great versatility and more predictable results in terms of MR reduction.

Transseptal delivery systems for TMVRpl are emerging and will replace the current transapical approach, which is burdened by an increased risk of peri-procedural complications.

Table 1. Ongoing active clinical trials investigating transcatheter mitral valve replacement devices*

Device (Access)	Status (patients)	Primary Outcome (Primary Completion)	Inclusion Criteria	Exclusion Criteria
Cardiovalve (TS)	Recruiting (30) NCT03339115	Mortality, MACE, hospitalization, and device or procedural serious adverse events (15 December 2020)	Age ≥ 18 years; NYHA II, III or amb. IV; MR 3-4 +; GDMT and/or CRT; high surgical risk; TEE feasible; anatomical eligibility; suitable for femoral access procedure and TS catheterization	Stroke/TIA (3 months) or Modified Rankin Scale ≥ 4 disability; AMI (30 days); heart valve surgery or TC MV intervention; percutaneous CV intervention, CV surgery, or carotid surgery (30 days); rheumatic heart disease or endocarditis (3 months); hypertrophic/restrictive cardiomyopathy; constrictive pericarditis, or any HF cause other than dilated cardiomyopathy; inferior vena cava filter or atrial septal device; clinically significant CAD requiring revascularization; tricuspid valve disease requiring surgery or severe tricuspid regurgitation; aortic or pulmonary valve disease requiring surgery; CRT/ICD (30 days); anatomical exclusion criteria; EF < 30%; LVEDD > 70 mm; severe MV annular or leaflets calcification; left atrial or LV thrombus or vegetation; severe RV dysfunction; severe tricuspid or aortic valve disease; hemodynamic instability; contrast agent hypersensitivity; allergy to nitinol alloys (nickel and titanium), or intolerance to antiplatelet, anticoagulant, or thrombolytic drugs; bleeding or coagulation disorders; active peptic ulcer or active gastrointestinal bleeding; pulmonary hypertension > 70 mmHg; creatinine > 2.5 mg/dL; emergent or urgent surgery or planned cardiac surgery (12 months); hepatic insufficiency; life expectancy < 1 year; active infection; pregnancy, breastfeeding, or planning to become pregnant (1 year) Specific to NCT03813524: Primary MR; severe mitral annular calcification; EROA < 0.3 cm ² ; LVEDD > 75 mm; Elevated creatine kinase MB; eGFR < 30 mL/min/1.73 m ²
	Recruiting (15) NCT03813524	Technical success and major device related adverse events (30 days) (April 2022)	NCT03813524 and NCT03958773: 85 > age	
	Recruiting (10) NCT03958773	Major device related adverse events (30 days) (12 September 2020)	≥ 18 years; severe MR; Cardiac Index > 2.0; EF ≥ 30%; NYHA II, III or amb. IV; GDMT (30 days); high surgical risk	
HighLife (TS)	Recruiting (50) NCT02974881	MACE at 30 days (July 2021)	Age ≥ 18 years; MR ≥ 3 +; NYHA II, III, amb. IV; GDMT; surgical high-risk; anatomical eligibility; DMR: EROA ≥ 40 mm ² or regurgitant Vol. ≥ 60 mL; SMR: EROA > 30 mm ² or regurgitant Vol. > 45 mL	Stroke/TIA (30 days); symptomatic carotid stenosis > 70%; active infections; active GI bleeding (3 months); bleeding/coagulopathy or refusal of BT; TEE not feasible; pregnant or lactating; allergies (device/contrast medium); anticoagulation or APT unfeasibility; life expectancy < 1 year; PM (3 months)
	Not yet recruiting (15) NCT04029337	MACE and device safety at 30 days (April 2021)		
	Recruiting (50) NCT04029363	Major adverse events at 30 days (July 2021)		
Tiara (TA)	Active, not recruiting (115) NCT03039855	MACE, all-cause mortality, and optimal/acceptable MR reduction at 30 days (January 2021)	Age ≥ 18 years; severe MR; high surgical risk; anatomical eligibility	Previous cardiac procedures; unsuitable cardiac structure; clinically significant untreated CAD; subjects on chronic dialysis; pregnant or planning pregnancy within next 12 months; documented bleeding or coagulation disorders; active infections requiring antibiotic therapy; life expectancy < 12 months
	Active, not recruiting (30) NCT02276547	MACE and all-cause mortality at 30 days (6 January 2020)	Age > 18 years; severe MR; high surgical risk; anatomical eligibility; NYHA III or IV HF	Surgical candidate; prohibitive risk; frail or listed for cardiac transplant; unsuitable anatomy
Caisson (TS)	Active, not recruiting (20) NCT02768402	MACE at 30 days (September 2023)	Age ≥ 18 years; severe MR; NYHA II, III, IVa or HF; high surgical risk	Excessive calcification or thickened MV annulus; severe MS, fused commissures, or MV vegetation/mass; LVEDD > 7 cm; LVOT obstruction; severe RV dysfunction; stroke (90 days), transient ischemic attack, or MI (30 days)
	Active, not recruiting (75) NCT03661398	MACE and surgical reintervention at 30 days (August 2025)		
Twelve (TA)	Active, not recruiting (10) NCT02428010	Adverse events at 30 days (December 2020)	Age > 18; severe MR 3-4 +; NYHA II-IV; TA access feasible; native and suitable MV anatomy	EF < 20%; intracardiac mass, thrombus, or vegetation; prior MV surgery or need for other valve surgery; stroke (4 weeks); need for CABG; history or active endocarditis; creatinine > 2.5 mg/dL

Evolve/ Fortis (TS)	Recruiting (58) NCT02718001	Device or Procedural adverse events at 30 days (December 2024)	Significant symptomatic MR; high surgical risk; anatomical eligibility	Unsuitable anatomy; inoperable patient
AltaValve (TA)	Recruiting (15) NCT03997305	MACE at 30 days (October 2020)	Age \geq 18 years; NYHA II-IV; severe MR; high surgical risk	History of any cognitive or mental health status; pregnant or planning pregnancy; hypersensitivity/contraindication to aspirin, heparin, or Warfarin; hypersensitivity to nitinol or contrast media that cannot be adequately medicated; EF \leq 25%; life expectancy < 12 months; prior MV intervention (excluding prior surgical MV repair, annuloplasty, or MitraClip not interfering with AltaValve placement)
Mi-thos (TA)	Not yet recruiting (122) NCT04195984	Mortality at 1 year (January 2021)	Age \geq 65; MR \geq 3+; high surgical risk; Life expectancy > 12 months; not eligible for surgery	MV surgery; active infections; clinically significant untreated CAD; pulmonary hypertension; severe RV HF; EF < 25%; hypertrophic cardiomyopathy; restrictive cardiomyopathy, or constrictive pericarditis; dialysis; severe coagulopathy; contraindications to anticoagulants; stroke or TIA (30 days); intracardiac mass, LV or atrial thrombus; previous intervention on valves; severe macrovascular disease requiring surgery; carotid stenosis > 70%; allergy to contrast agents, nickel-titanium memory alloys, or bovine-derived products; severe neurological disorders affecting cognitive ability, severe thoracic deformities
SATURN (TA)	Recruiting (20) NCT04464876	Device or procedural major adverse events, MR reduction, and technical success at 30 days (December 2021)	Age \geq 18 years; SMR \geq 3+; NYHA \geq II, amb. IV; GDMT; high surgical risk; suitable for quality-of-life assessment (KCCCQ)	Frailty or comorbidities; life expectancy < 1 year; active endocarditis or systemic infection; Modified Rankin Scale \geq 4 disability; hemodialysis/eGFR < 35 mL/min/m ² ; pulmonary hypertension; COPD on home oxygen; refuses BT; bleeding or coagulation disorders; severe connective tissue disease under chronic immunosuppressive or cortisone therapy; pregnant/lactating or not willing to take contraceptives; MI (30 days); stroke or TIA (30 days); severe extracardiac arteriopathy; prior MV treatment; mechanical aortic valve or TAVR; need for CV surgery (30 days); CRT or ICD (30 days); hemodynamic instability, CABG or PCI (30 days); need for revascularization; prior or planned heart transplantation; RV HF; unsuitable TA access; hypersensitivity to nickel or titanium; EF \leq 30%; severe mitral annular calcification; severe MS; MV vegetation or mass; extensive MV flail leaflets; LV thrombus, mass, or vegetation; LV end-diastolic diameter > 7.5 cm; severe RV dysfunction; significant intracardiac shunt; anatomic ineligibility
Tendyne (TA)	Active, not recruiting (350) NCT02321514	Device or procedural adverse events and device malfunction at 30 days (July 2020)	Age \geq 18 years; severe MR; NYHA \geq II, amb. IV; high surgical risk	Severe mitral calcification or MS; unsuitable TA access; prior surgical or interventional treatment of mitral or aortic valves
	Recruiting (958) NCT03433274	HF hospitalization, mortality, CV hospitalization, stroke, and MV reintervention	MR \geq 3+; NYHA \geq II, amb. IV; not a member of a vulnerable population	MV vegetation or mass; EF < 25%; LVEDD > 7 cm; surgical or interventional MV treatment (prosthetic device); aortic valve disease requiring surgery or TC intervention; severe tricuspid regurgitation or needed tricuspid surgery or TC intervention; planned surgical/interventional procedure (60 days); hemodialysis; anatomic unsuitable; life expectancy < 12 months
Intrepid (TA)	Recruiting (1600) NCT03242642	Mortality, disabling stroke, reintervention, and CV hospitalization (October 2021)	MR \geq 3+; candidate to TMVR	Prior TC MV procedure with device currently implanted; anatomic contraindications; prohibitive mitral annular calcification; EF < 25%; need for emergent or urgent surgery; hemodynamic instability

*TMVR on native mitral valves (e.g., excluding valve in mitral annular calcification); data retrieved from ClinicalTrials.gov (11/01/2020). BT: blood transfusion; CAD: coronary artery disease; CABG: coronary artery bypass grafting; COPD: chronic obstructive pulmonary disease; CRT: Cardiac resynchronization therapy; CV: cardiovascular; DMR: Degenerative Mitral Regurgitation; EF: ejection fraction; eGFR: estimated glomerular filtration rate; EROA: effective regurgitant orifice area; GDMT: guideline directed medical therapy; GI: gastrointestinal; HF: heart failure; ICD: implantable cardioverter defibrillator; KCCCQ: Kansas City Cardiomyopathy Questionnaire; MACE: major adverse cardiovascular events; MI: myocardial infarction; MS: mitral stenosis; MV: Mitral Valve; NYHA: New York Heart Association; PCI: percutaneous coronary intervention; PM: pacemaker; SMR: Secondary Mitral Regurgitation; TA: Trans-Apical; TAVR: transcatheter aortic valve replacement; TC: transcatheter; TIA: transient ischemic attack; TEE: transesophageal echocardiography; TMVR: transcatheter mitral valve replacement; TS: Trans-Septal

Similar to aortic bioprosthetic valves, TMVRpl devices need an assessment of the rates of structural degeneration, prosthesis-related endocarditis, and thromboembolic/hemorrhagic events. Studies on long-term clinical outcomes and trials on optimal antithrombotic therapy will provide these data.

While evidence on the use of TMVR for advanced HF is being published^[13,14], whether TMVRpl may play a role in this setting has yet to be proved. Complete and more reproducible reductions in MR may allow for an uptitration of heart failure medical therapies, and this gain could lead to even greater clinical benefits.

Studies on TMVRpl available thus far are promising in terms of feasibility and efficacy, but they report high rates of peri-procedural complications and all-cause mortality (technical success 91.7%, stroke 2.9%, unplanned mitral valve surgery 4%, and 30-day mortality 13.6%)^[19]. For this reason, the clinical applicability of these procedures is limited and finds room when TMVR is contraindicated. These data are influenced by two critical factors:

- (1) The patients enrolled in TMVRpl studies are elderly, have a relevant comorbidity burden and very high operative risks, or are considered inoperable (compassionate use)^[19].
- (2) A quite selective process limits the anatomical eligibility to TMVRpl and consequently the enrollment rate; screening failure is reported as up to 70%^[23,24].

The great potential of these procedures and their theoretical applicability will be proved in the coming years when more scientific data become available.

CONCLUSION

Technical and more so technological advances have forged a vast armamentarium of transcatheter mitral valve therapies. While some TMVR devices (e.g., MitraClip) have large supporting studies, TMVRpl devices need more evidence. Clinical investigations, in the form of randomized trials, will define the specific role and the ideal target population of TMVRpl. At the moment, for patients with severe MR, a repair-first strategy is the preferable choice, and a replacement technique finds applicability in highly selected cases. As soon as TMVRpl obtains the necessary confirmations to be considered a complementary strategy to TMVR, a substantial number of transcatheter options will be available to handle mitral valve disease. A one-device-for-all paradigm is not realistic; having a complete mitral toolbox will be fundamental to address all the different pathologies, mechanisms, and patients to allow specific patient-tailored approaches.

DECLARATIONS

Authors' contributions

Conceived and designed the study, performed data interpretation, and were involved in all the phases of the writing process: Scotti A, Galasso M, Margonato A, Godino C

Availability of data and materials

Not applicable.

Financial support and sponsorship

None.

Conflicts of interest

All authors declared that there are no conflicts of interest.

Ethical approval and consent to participate

Not applicable.

Consent for publication

Not applicable.

Copyright

© The Author(s) 2021.

REFERENCES

1. Feldman T., Wasserman HS., Herrmann HC., et al. Percutaneous mitral valve repair using the edge-to-edge technique: six-month results of the EVEREST Phase I Clinical Trial. *J Am Coll Cardiol* 2005;46:2134–40.
2. Puls M., Lubos E., Boekstegers P., et al. One-year outcomes and predictors of mortality after MitraClip therapy in contemporary clinical practice: Results from the German transcatheter mitral valve interventions registry. *Eur Heart J* 2016;37:703–12.
3. Maisano F., Franzen O., Baldus S., et al. Percutaneous mitral valve interventions in the real world: early and 1-year results from the ACCESS-EU, a prospective, multicenter, nonrandomized post-approval study of the Mitraclip therapy in Europe. *J Am Coll Cardiol* 2013;62(12):1052–61.
4. Praz F., Spargias K., Chrissoheris M., et al. Compassionate use of the PASCAL transcatheter mitral valve repair system for patients with severe mitral regurgitation: a multicentre, prospective, observational, first-in-man study. *Lancet* 2017;390:773–80.
5. Glower DD., Kar S., Trento A., et al. Percutaneous mitral valve repair for mitral regurgitation in high-risk patients: Results of the EVEREST II study. *J Am Coll Cardiol* 2014;64:172–81.
6. Lim DS., Reynolds MR., Feldman T., et al. Improved functional status and quality of life in prohibitive surgical risk patients with degenerative mitral regurgitation after transcatheter mitral valve repair. *J Am Coll Cardiol* 2014;64:182–92.
7. Deferm S., Bertrand PB., Verbrugge FH., et al. Atrial functional mitral regurgitation: JACC review topic of the week. *J Am Coll Cardiol* 2019;73:2465–76.
8. Packer M., Grayburn PA. New evidence supporting a novel conceptual framework for distinguishing proportionate and disproportionate functional mitral regurgitation. *JAMA Cardiol* 2020: 469-75.
9. Baumgartner H., Falk V., Bax JJ., et al. 2017 ESC/EACTS Guidelines for the management of valvular heart disease. *Eur Heart J* 2017;38:2739–86.
10. Stone GW., Lindenfeld JA., Abraham WT., et al. Transcatheter mitral-valve repair in patients with heart failure. *N Engl J Med* 2018;379:2307–18.
11. Obadia JF., Messika-Zeitoun D., Leurent G., et al. Percutaneous repair or medical treatment for secondary mitral regurgitation. *N Engl J Med* 2018;379:2297–306.
12. Bonow RO., O’Gara PT., Adams DH., et al. 2020 focused update of the 2017 ACC expert consensus decision pathway on the management of mitral regurgitation: a report of the American College of Cardiology Solution Set Oversight Committee. *J Am Coll Cardiol* 2020;75:2236–70.
13. Scotti A., Margonato A., Godino C. Percutaneous mitral valve repair in patients with secondary mitral regurgitation and advanced heart failure. *Mini-Invasive Surg* 2020;4:49.
14. Godino C., Munafò A., Scotti A., et al. MitraClip in secondary mitral regurgitation as a bridge to heart transplantation: 1-year outcomes from the International MitraBridge Registry. *J Hear Lung Transplant* 2020;39:1353–62.
15. Feldman T., Cilingiroglu M. Percutaneous leaflet repair and annuloplasty for mitral regurgitation. *J Am Coll Cardiol* 2011:529–37.
16. Lubos E., Schlüter M., Vettorazzi E., et al. MitraClip therapy in surgical high-risk patients: Identification of echocardiographic variables affecting acute procedural outcome. *JACC Cardiovasc Interv* 2014;7:394–402.
17. Brown JM., O’Brien SM., Wu C., Sikora JAH., Griffith BP., Gammie JS. Isolated aortic valve replacement in North America comprising 108,687 patients in 10 years: changes in risks, valve types, and outcomes in the Society of Thoracic Surgeons National Database. *J Thorac Cardiovasc Surg* 2009;137:82–90.
18. Mylotte D., Andalib A., Thériault-Lauzier P., et al. Transcatheter heart valve failure: a systematic review. *Eur Heart J* 2015;36:1306–27.
19. Del Val D., Ferreira-Neto AN., Wintzer-Wehekind J., et al. Early experience with transcatheter mitral valve replacement: a systematic review. *J Am Heart Assoc* 2019;8:e013332.
20. Taramasso M., Gavazzoni M., Nickenig G., Maisano F. Transcatheter mitral repair and replacement: which procedure for which patient? *EuroIntervention* 2019;15:867–74.
21. Adamo M., Godino C., Giannini C., et al. Left ventricular reverse remodelling predicts long-term outcomes in patients with functional mitral regurgitation undergoing MitraClip therapy: results from a multicentre registry. *Eur J Heart Fail* 2018;21:ejhf.1343.
22. Godino C., Salerno A., Cera M., et al. Impact and evolution of right ventricular dysfunction after successful MitraClip implantation in patients with functional mitral regurgitation. *IJC Hear Vasc* 2016;11:90–8.
23. Bapat V., Rajagopal V., Meduri C., et al. Early experience with new transcatheter mitral valve replacement. *J Am Coll Cardiol* 2018;71:12–21.
24. Sorajja P., Moat N., Badhwar V., et al. Initial feasibility study of a new transcatheter mitral prosthesis: the first 100 patients. *J Am Coll Cardiol* 2019;73(11):1250–60.