

Review

Open Access



Surgery for hepatocellular carcinoma and intrahepatic cholangiocarcinoma: milestone changes in the last two decades potentially affecting current guidelines

Federica Cipriani¹ , Gianluca Fornoni¹, Margherita Rimini^{2,3}, Federica Pedica⁴, Federica Invernizzi⁵, Andrea Casadei-Gardini^{2,3}, Francesco De Cobelli^{3,6}, Massimo Colombo⁵, Luca Aldrighetti^{1,3}

¹Hepatobiliary Surgery Division, IRCCS San Raffaele Scientific Institute, Milan 20132, Italy.

²Department of Oncology, IRCCS San Raffaele Scientific Institute, Milan 20132, Italy.

³Vita-Salute San Raffaele University, Milan 20132, Italy.

⁴Department of Experimental Oncology, Pathology Unit, IRCCS San Raffaele Scientific Institute, Milan 20132, Italy.

⁵Division of Hepatology, IRCCS San Raffaele Scientific Institute, Milan 20132, Italy.

⁶Department of Radiology, IRCCS San Raffaele Scientific Institute, Milan 20132, Italy.

Correspondence to: Dr. Federica Cipriani, Hepatobiliary Surgery Division, IRCCS San Raffaele Scientific Institute, Via Olgettina Milano 60, Milan 20132, Italy. E-mail: cipriani.federica@hsr.it

How to cite this article: Cipriani F, Fornoni G, Rimini M, Pedica F, Invernizzi F, Casadei-Gardini A, Cobelli FD, Colombo M, Aldrighetti L. Surgery for hepatocellular carcinoma and intrahepatic cholangiocarcinoma: milestone changes in the last two decades potentially affecting current guidelines. *Hepatoma Res* 2023;9:13. <https://dx.doi.org/10.20517/2394-5079.2022.80>

Received: 28 Oct 2022 **First Decision:** 28 Feb 2023 **Revised:** 12 Mar 2023 **Accepted:** 6 Apr 2023 **Published:** 20 Apr 2023

Academic Editor: Giuliano Ramadori **Copy Editor:** Yanbing Bai **Production Editor:** Yanbing Bai

Abstract

The aim of this review is to describe the relevance of minimally invasive liver resection (MILR) for the treatment of most common primary liver tumors. The uptake has been slow but steady, and thus MILR has become a well-established field of hepatobiliary surgery and is considered a landmark change of the past 30 years. There is evidence that the advantage of MILR regarding specific complications of liver surgery for HCC (reduced incidence of postoperative hepatic decompensation and ascites) can be a tool to potentially expand the indications to surgical treatment. Evidence for intrahepatic cholangiocarcinoma is early and exploratory; however, it is beginning to be documented that the fundamental principles of surgical oncology for this tumor can be respected while offering patients the advantages of minimal invasiveness.



© The Author(s) 2023. **Open Access** This article is licensed under a Creative Commons Attribution 4.0 International License (<https://creativecommons.org/licenses/by/4.0/>), which permits unrestricted use, sharing, adaptation, distribution and reproduction in any medium or format, for any purpose, even commercially, as long as you give appropriate credit to the original author(s) and the source, provide a link to the Creative Commons license, and indicate if changes were made.



Keywords: Hepatocellular carcinoma, intrahepatic cholangiocarcinoma, minimally invasive hepatectomy, laparoscopic liver resection

INTRODUCTION

Until the '90s, the only possible technique for performing liver resections was laparotomy. In 1991, the first laparoscopic liver resection was performed, thus opening up a new promising field of liver surgery^[1]. During the next thirty years, minimally invasive liver resection (MILR) spread worldwide due to the benefits seen in patient outcomes. MILR has been reported beneficial in terms of blood loss, transfusion rates, pain control, complications, and length of hospital stay^[2-7].

Gradually, MILR has become feasible, safe and efficient for the treatment of both benign and malignant liver diseases, including those requiring complex hepatectomies^[8-10]. The diffusion has been slow but steady, and thus MILR has become a well-established field of hepatobiliary surgery and is considered a fundamental change in recent years^[11].

The purpose of this narrative review is to describe the relevance of MILR for the treatment of the most common primary liver tumors, namely hepatocellular carcinoma (HCC) and intrahepatic cholangiocarcinoma (ICC). The treatment for the two types of tumors is different because they both have specific oncological and surgical characteristics that must be considered in the application of minimally invasive techniques for their resective treatment.

REVIEW STRATEGY

The methodology implied a literature search performed in the PubMed database conducted with the search words (“HCC”, or “hepatocellular carcinoma”, or “cholangiocarcinoma”, or “intrahepatic cholangiocarcinoma”) AND (“laparoscopic”, or “minimally invasive”, or “robotic”, or “robot-assisted”). The definition of “minimally invasive” included pure laparoscopic and robotic techniques, which are the most common minimally invasive approaches for liver surgery; hand-assisted, hybrid and laparoendoscopic single-site techniques were not considered. Laparoscopic and robotic surgery have many similarities: both use small incisions, a camera that magnifies the view, and require the surgeon to operate instruments from outside the patient’s body. However, laparoscopic devices are manipulated directly by hands, whereas robotic instruments use a console as part of an advanced surgical system with arms moving around the surgical field.

A language restriction was applied to include English literature only and publications up to September 2022 were considered. The authors have selected and included the most relevant literature evidence to support the illustrated hot topic concepts. It should be emphasized that the evidence on MILR for HCC and ICC is essentially supported by retrospective studies. This is in line with the general paucity of prospective studies in the surgical field. While the rigorous form of RCT is the ideal method for providing evidence, prospective surgical trials are associated with several difficult obstacles to overcome. Timing and planning are complex as surgical techniques evolve over time; perioperative care and surveillance often differ between centers; surgical randomized controlled trials are not usually carried on in stages (as drugs trials are), and selecting the most appropriate endpoints can therefore be difficult; enrollment can be challenging because patients are often unenthusiastic about invasive procedures unless the surgeon has unequivocal recommendations.

HEPATOCELLULAR CARCINOMA

The indications for the treatment of HCC are well defined by the Barcelona Clinic Liver Cancer algorithm, which has been updated over time^[12]. Despite the significant evolution, the eligibility for liver resection remains limited to very early and early HCC in compensated cirrhosis mainly due to two factors: tumor burden (advanced, multifocal disease) and functional liver reserve (decompensated cirrhosis, portal hypertension). Wrong indications can lead to unsafe perioperative outcomes and questionable oncological benefits. MILR is among recent advances that play a role in increasing the safety and efficacy of liver surgery for HCC and potentially expanding the pool of patients eligible for liver resection.

Research into the specific role of MILR for HCC began twenty years ago with some early studies based on a few patients from pioneering surgical centers. As for other liver diagnoses, the general benefits of MILR compared to laparotomy have gradually emerged even for HCC, such as the reduction of blood loss and the shorter length of hospital stay. More importantly, MILR in this oncological setting appeared to be associated with specific advantages in terms of reduced incidence of postoperative hepatic decompensation and ascites^[13,14]. Indeed, early in 2010, Aldrighetti *et al.* showed lower blood loss and shorter length of hospitalization compared to open (258 mL *vs.* 617 mL, $P = 0.008$; 6.3 *vs.* 9 days, $P = 0.039$). In the same year, Tranchart *et al.* reported decreased ascites following MILR than laparotomic resection (7.1% *vs.* 26.1%, $P = 0.030$). Evidence has accumulated over time with many publications based on increasing numbers of HCC treated, and to date, several meta-analyses have pooled data from retrospective comparative studies on minimally invasive versus open liver resections^[15-22] [Table 1].

In most of these publications, laparoscopy was confirmed to be associated with reduced blood loss and transfusion rates, reduced overall morbidity and length of stay, with non-inferior perioperative outcomes compared to open surgery. Importantly, a meta-analysis looking at 1618 patients with HCC showed a 20% reduction in the hazard ratio of death for patients with cirrhosis who underwent MILR^[23]. Furthermore, several meta-analyses have demonstrated the advantage of MILR with regard to specific complications of liver surgery for HCC (reduced incidence of postoperative hepatic decompensation and ascites). For example, in a systematic review of high-quality case-matched studies published in 2018, Chen *et al.* reported that ascites was less in MILR than in open resections, regardless of whether they underwent minor or major hepatectomies (RR = 0.42, $P < 0.010$) and patients undergoing laparoscopy were less likely to suffer from liver failure (RR = 0.41, $P < 0.010$)^[24]. The most frequently reported reasons for the reduction of hepatic decompensation in the MILR series are the avoidance of interruption of abdominal collateral and lymphatics vessels by small incisions and limited mobilization of the liver, thus allowing the preservation of portosystemic wall shunts and thereby limiting postoperative portal hypertension, subsequent ascitic decompensation, and impaired liver function. Moreover, minimally invasiveness is able to limit postoperative ascites by reducing the laparotomy-related fluid dispersion, thus facilitating intra- and postoperative fluid and electrolyte balance^[25]. In addition, the reduced surgical stress response observed for many minimally invasive surgeries may also contribute to reducing the biological impact of surgery and underlie better perioperative outcomes than open surgery^[26]. As a further explanation of this advantage, to date, there is no evidence that MILR allows for being more selective in parenchymal resection. However, considering advances in laparoscopic anatomical resections, the increasing use of intraoperative indocyanine green fluorescence imaging and the diffusion of robotics, these techniques may allow further refinements to reduce the amount of nontumor tissue resected and further enhance the benefits on postoperative ascites and liver decompensation.

It is worth mentioning the result of a publication that aimed to analyze the outcome of MILR in patients with early and intermediate stage disease according to BCLC and to define the differential benefit with

Table 1. Significant meta-analyses of minimally invasive vs. open liver resections for HCC in different settings (cirrhosis, major hepatectomies, elderly patients)

	First author	Number of studies included	Operative time	Blood loss	Blood transfusion	Length of hospitalization	Morbidity	Mortality
HCC in cirrhosis	Twaij ^[15]	4	MI = open	MI < open	MI < open	MI < open	MI < open	Not assessable
	Chen ^[16]	7	MI = open	MI < open	MI < open	MI < open	MI < open	MI = open
	Coletta ^[17]	14	MI < open	MI < open	MI < open	MI < open	(Ascites and postoperative liver failure: MI < open)	MI = open
Major resections	Kabir ^[18]	11	MI = open	MI < open	MI = open	MI < open	MI < open	MI = open
	Pan ^[19]	16	MI = open	MI < open	MI < open	MI < open	MI < open	MI < open
	Wang ^[20]	9	MI > open	MI < open	MI = open	MI < open	MI < open	Not assessable
	Hao ^[21]	9	MI = open	MI < open	MI = open	MI < open	MI = open	MI = open
Repeat hepatectomy	Wang ^[22]	7	MI > open	Not assessable	Not assessable	MI < open	MI < open	Not assessable
HCC in elderly								

open. The differential benefit was evaluated taking into account blood loss and morbidity rate as outcome indicators and resulted in a greater advantage of MILR in intermediate stage patients compared to early stage patients for both the parameters (-270 mL vs. -150 mL, pure differential benefit: 120 mL, $P = 0.028$; -4.6% vs. -7.4%, differential benefit: 2.8%, $P = 0.042$). The conclusion was that the favorable biological scenario associated with MILR allows for greater benefits in the context of more advanced liver disease, which could potentially promote stage migration in suitable patients^[27].

Most studies and meta-analyses evaluating the oncological efficacy of MILR for HCC have documented short- and long-term outcomes comparable to open, even for major hepatectomies^[28-30]. Surrogate oncological outcomes such as radical resection rates and resection margin width are reported with no inferior outcomes due to the adoption of minimally invasive approaches, as well as recurrence-free, disease-free and overall survival rates are reported as similar. Of note, some recent publications have reported even better oncological outcomes for MILR than for open. Lower tumor recurrence rates for MILR (OR: 0.65, $P = 0.008$) and better 1-y disease-free (HR: 0.71, $P = 0.02$) and 5-year overall survival (HR: 0.60, $P = 0.004$) were shown by a meta-analysis of more than 800 HCC patients published in 2018 by Goh *et al.*, who linked these findings to reduced blood loss and lower rates of positive resection margins^[31]. In 2021, another study compared survival outcomes of MILR and open resections in the treatment of HCC by reconstructing time-to-event data for meta-analysis with Kaplan-Meier curves of high-quality propensity-score matched studies. The results suggested that MILR may improve RFS in HCC patients undergoing minor hepatectomy (HR: 1.44, $P < 0.001$)^[32]. These data support the possibility that MILR may have a favorable impact on the oncological prognosis of resected patients by reducing tumor recurrences and consequently improving disease-free and overall survival.

HCC patients with advanced cirrhosis and portal hypertension are those in whom open liver resections carry a substantial risk of mortality and relevant complications. MILR is increasingly being adopted to expand liver resection to these categories of HCC patients. In 2018 a multicenter study showed no significant differences in short-term surgical outcomes between Child A and Child B patients undergoing MILR: blood loss (400 mL vs. 350 mL, $P = 0.856$), transfusion rate (15% vs. 12%, $P > 0.05$), postoperative

mortality and morbidity rates (2% vs. 4%, $P = 0.491$; 39% vs. 36%, $P = 0.467$) including liver-specific complications as ascites and liver decompensation were all similar (11% vs. 12%, $P = 0.562$; 3% vs. 4%, $P = 0.595$)^[33]. In the same study, clinically significant portal hypertension was not among the independent risk factors for major morbidity (or: 1.45, $P = 0.287$). The advantages of MILR in advanced Child-B cirrhotic patients have been confirmed by an international multicenter propensity score-matched study reporting decreased blood loss (110 mL vs. 400 mL, $P = 0.004$) and complications including major morbidity (38% vs. 51%, $P = 0.041$; 7% vs. 21%, $P = 0.010$) compared to open^[34]. The long-term impact of MILR for HCC patients with clinically significant portal hypertension has been evaluated in some studies showing 1-y and 3-y overall survival similar to patients without portal hypertension (100% and 87%, respectively, $P = 0.800$)^[35,36]. In light of the above findings, MILR can be considered a means with a protective effect against major postoperative complications, ascites and postoperative liver failure even in HCC patients with advanced cirrhosis and portal hypertension. As such, its role in expanding indications for resection is being considered.

The results of minimally invasive techniques for liver resections have been well summarized by various expert consensus. In 2017, the Southampton consensus led to the production of clinical practice guidelines for MILR, including its application in the context of HCC. It was pointed out that MILR for HCC is associated with reduced blood loss, transfusion rate, postoperative ascites, and liver failure and hospital stay with comparable to open operation time, disease-free margin, and recurrence rates and is an independent factor in reducing the complication rates, and that laparoscopic approach appears to reduce the incidence of postoperative ascites, liver failure and morbidity assessed in terms of "Comprehensive Complication Index". In that document, the use of minimally invasive approaches for the surgical treatment of HCC was endorsed by experts in the field based on literature evidence and clinical experience^[37].

In summary, MILR for HCC has been performed largely worldwide, and the results have been investigated with propensity score matching studies and meta-analyses that included a relatively large number of patients. Compared to open resections, MILR shows advantages in perioperative outcomes and at least comparable oncologic outcomes. Although the majority of studies involve patients with compensated cirrhosis, some reports have demonstrated the feasibility of MILR in selected Child B/C patients. Further studies should refine the selection of patients with advanced cirrhosis who benefit most from a minimally invasive approach.

INTRAHEPATIC CHOLANGIOCARCINOMA

Cholangiocarcinoma is the second most common type of primary liver cancer after hepatocellular carcinoma. Among treatments of ICC, surgery remains the only potentially curative solution among existing therapeutic modalities^[38-44].

Despite continuous growth, the experience of MILR for ICC is still limited, and its adoption is not well established yet, mainly because of the technical and oncological hurdles associated with the frequent need for major hepatectomy and the indication of adequate lymphadenectomy. In the Southampton Consensus Guidelines, the role of MILR for the management of ICC has not been addressed, and - at present - it is considered in the initial phase of exploration. However, evidence is progressively accumulating and leading to the assumption that - in the near future - MILR will acquire a well-defined role in the treatment of ICC as MILR for other diseases.

Relatively small single-center series have reported the feasibility of MILR with lymphadenectomy for ICC, showing non-inferior results compared with open, with some advantages. In 2015, Uy *et al.* reported lower

blood loss for 11 MILR for ICC (325 mL vs. 750 mL, $P = 0.024$), with similar morbidity (9.1% vs. 26.9%, $P = 0.228$) and width of resection margin (0.6 cm vs. 0.2 cm, $P = 0.125$)^[45]. Likewise, in 2016, Lee *et al.* published on 14 MILR for ICC, showing lower blood loss compared to open (325 mL vs. 625 mL, $P = 0.006$), and no differences in morbidity (21.4% vs. 19%, $P = 1.000$) and mortality (0 vs. 0, $P = 1.000$). As for oncological outcomes, both overall and recurrence-free survival were similar at 3 years with a median follow-up of 21 months (75.7% vs. 84.6%, $P = 0.672$; 56.7% vs. 76.9%, $P = 0.456$)^[46]. In the same year, Ratti *et al.* analyzed 20 MILR for ICC matched with 60 open. In this series, 85% of patients underwent major hepatectomy. There was no difference in operative time (210 min vs. 180 min, $P = \text{NS}$), complications (15% vs. 13.3%, $P = \text{NS}$), mortality (0 vs. 0, $P = 1.000$), and radical resection rates (100% vs. 98.3%, $P = 1.000$), while blood loss was lower in MILR group (200 vs. 350, $P = 0.040$) along with borderline faster functional recovery (3 vs. 4, $P = 0.050$). After a mean follow-up of 39 months, median DFS and OS and overall survivals resulted comparable between the two groups (33 vs. 36 months, $P = \text{NS}$; 51 vs. 63 months, $P = \text{NS}$)^[47].

In 2021, two meta-analyses of non-randomized retrospective comparative studies of MILR for ICC versus open were published. Both publications considered eight original researches published between 2016 and 2020 involving a total of 2,872 patients (552 MILRs and 2,320 open resections)^[48,49]. The baseline characteristics and perioperative outcomes were consistent between the two meta-analyses. MILR was characterized by lower transfusion rates (7.1% vs. 17.1%; $P < 0.050$), morbidity rates (20% vs. 32.6%; $P < 0.050$), and length of hospital stay (MD: -3.48 days, SMD: -0.40 days; $P = 0.050$) compared to open resection; no differences in operative time (MD: 1.6 min, SMD: 0.15 min; $P > 0.050$) and mortality (1.6% vs. 0.9%; $P > 0.050$) were found. MILR patients had smaller tumors (MD: -1.17 cm, SMD: -0.3 cm; $P < 0.050$) and underwent major resections less frequently (41.2% vs. 55.5%; $P < 0.050$); this is reasonably the explanation for higher radical resection rates for MILR (85.6% vs. 74.6%; $P < 0.050$). For oncological outcomes, recurrence-free survivals were comparable between MILR and open resection at both 3 years (HR: 0.97; $P > 0.050$; HR: 0.77; $P > 0.050$) and 5 years from resection (HR: 0.91; $P > 0.050$). Although no difference in 3-y overall survival was reported by Machairas *et al.* (HR: 0.9; $P = 0.63$), a significantly lower 5-year overall survival for MILR was shown by Regmi *et al.* (HR: 3.01; $P < 0.001$), albeit associated with fewer deaths due to tumor recurrence (22.3% vs. 35.4%; $P < 0.050$). Hence, the authors raise the question of the oncological adequacy of MILR for ICC and further evidence needed to address the oncological findings. In the same year, Ziogas *et al.* performed a survival meta-analysis based on reconstructed individual patient data regarding laparoscopic versus open hepatectomy for intrahepatic cholangiocarcinoma^[50]. The study was based on the same eight original researches and included one- and two-stage survival analyses. Using Cox regression, the authors showed no difference regarding OS (HR: 1.11; $P = 0.70$) and RFS (HR: 1.19; $P = 0.47$), thus concluding in favor of the oncological adequacy of MILR for ICC [Table 2].

Although surgical resection is the mainstay of treatment for both tumors and, in many cases, HCC and ICC can be found on postoperative histology in the same liver, differentiating between HCC and ICC is important for proper surgical planning. The main surgical peculiarity is the indication to perform locoregional lymphadenectomy. At present, lymph nodes retrieval in HCC is indicated only in case of documented metastases, for which the role of positron emission tomography/computed tomography scan with dual tracer ^{18}F -FDG and $^{18}\text{F}/^{11}\text{C}$ -choline holds promise for complete preoperative staging and operative decision^[57]. Instead, for ICC, a routine locoregional lymphadenectomy is supported by data on its favorable effect at least on staging accuracy and potentially also on curative goals and oncological prognosis^[39,58]. In particular, regarding the issue of satisfactory lymphadenectomy during MILR for ICC, it should be noted that although the mean number of retrieved nodes was not different, in all three meta-analyses, MILR resulted associated with lymph nodes dissection less frequently than open resection (47.8% vs. 61.9%; $P < 0.05$). Differences in the period of performance of surgery, in the attitude of the center

Table 2. Minimally invasive liver resections for ICC in the eight comparative studies included in the three meta-analyses

First author, year	Patients Minimally invasive	Major hepatectomy rate	Lymphadenectomy rate	Number of retrieved lymph nodes	Radical resection rate
Lee ^[46]	14	50%	36%	4	Not assessable
Wei ^[51]	30	43%	20%	Not assessable	100%
Zhu ^[52]	18	55%	39%	Not assessable	95%
Martin ^[53]	312	44%	39%	> 6: 9%	81%
Kinoshita ^[54]	15	Not assessable	40%	Not assessable	93%
Kang ^[55]	24	75%	25%	Not assessable	Not assessable
Haber ^[56]	27	70%	85%	8	89%
Ratti ^[47]	104	33%	84%	8	97%

and the surgeon, and in minimally invasive expertise may explain this difference. The development of minimally invasive skills is necessary for this tricky surgical step. Recent studies have shown that minimally invasive lymphadenectomy can be performed without affecting the accuracy of nodal dissection and can be possible even in case of unfavorable anatomical variations, disclosing some technical tips^[59-61].

The use of intraoperative fluorescence imaging in this setting is worth mentioning, as it may facilitate anatomical MILR and appropriate lymphadenectomy. Analyzing a small series of laparoscopic left hemihepatectomies, Zhang *et al.* recently reported that more lymph nodes were harvested in the indocyanine green group (7 vs. 3.5, $P < 0.001$), and the percentage of confirmed pathological lymph nodes was higher (75.0%, 66.7%-87.5% vs. 40%, 33.3%-50.0%, $P < 0.001$). They also found that indocyanine green staining was observed in all patients at stations 8 and 12, and in 75% and 92% of patients at stations 13 and 7, respectively, concluding that the indocyanine green fluorescence imaging system is feasible, safe, and effective to trace lymph nodes. It can be used to identify the patterns of regional lymphatic drainage. It can also help to define the extent of lymph node dissection in patients with ICC on a case-by-case basis^[62].

Similar to HCC, no studies have directly compared the outcomes of MILR for ICC performed in Eastern and Western countries. Data from systematic reviews and meta-analyses show no difference in indications and outcomes^[18,63]. This is an interesting and unexplored topic, considering that the risk factors and causes of chronic liver disease as well as genetics, are partly different in world areas and could underlie a possible difference in outcomes^[64,65]. The issue deserves a specific evaluation through dedicated studies and could be the subject of future multicenter investigations.

Current data support MILR for ICC when performed in high-volume hepatobiliary centers with a significant experience in minimally invasive liver surgery, as these procedures are still innovative. Few comparative studies are currently available; as such, the findings mentioned above need to be further investigated with larger, high-quality comparative studies targeting both technical and oncological outcomes.

Figures 1 and 2 summarize the pros and cons of minimally invasive approaches for liver resection of HCC, ICC, and both.

PATIENT SELECTION AND DIFFICULTY SCORES FOR MILR

MILR is nowadays described as feasible for all liver cancers, type of resections, size and location. However, MILR for tumors located posteriorly and deep in the parenchyma has been acknowledged as complex since

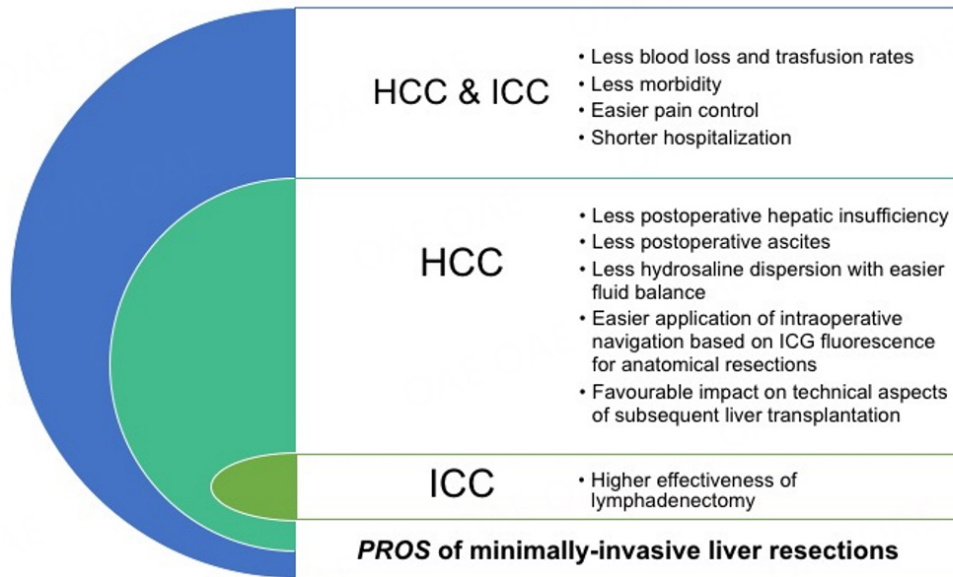


Figure 1. PROS of minimally-invasive liver resections.

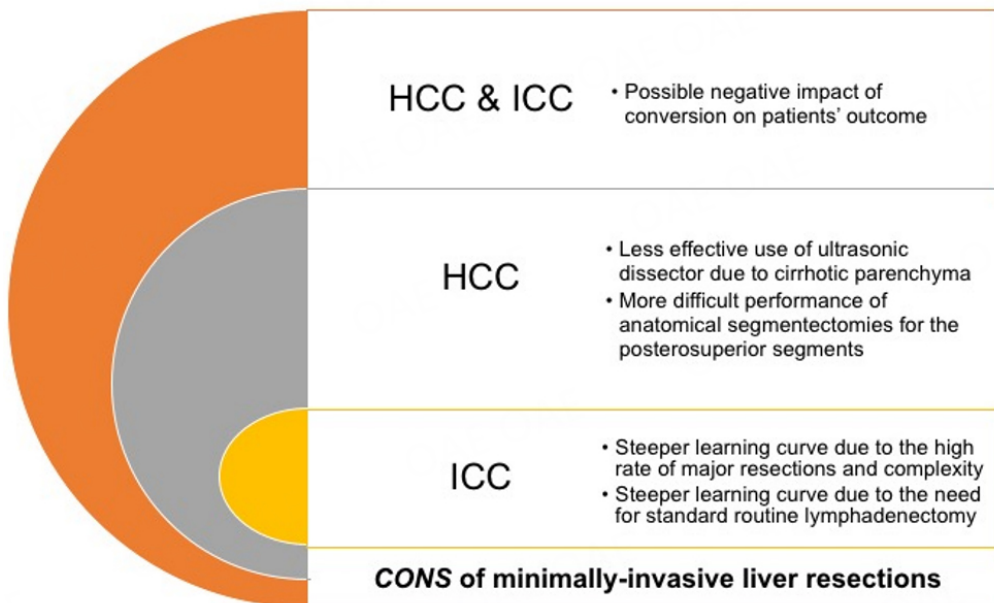


Figure 2. CONS of minimally-invasive liver resections.

the early periods of application. In fact, the first worldwide consensus on MILR, held in Louisville in 2008, identified liver resections for lesions located in the peripheral segments (i.e., segments: 2-6) as the best indications for laparoscopy^[66]. To date, laparoscopic segmentectomies on posterosuperior segments (i.e., segments 4a, 1, 7 and 8) remain technically challenging despite advancements, as well as right posterior sectionectomies, caudate lobe resections and parenchyma-sparing resections. Compared to MILR on anterolateral segments, these hepatectomies result in greater blood loss, longer operative time, and higher morbidity and conversion rates^[67-69]. In any case, even if the localization of the tumor is an extremely

Table 3. MILR difficulty scores with parameters and grading

Name of the score	First author	Parameters	Grading of difficulty
Iwate	Ban ^[10]	Size, location, proximity to major vessels, magnitude of resection, type of MILR approach, presence of cirrhosis	4 categories: low, intermediate, advanced, expert
IMM	Kawaguchi ^[68]	Operative time, blood loss, conversion to open	3 categories: low, intermediate, high
Hasegawa	Hasegawa ^[70]	Location, magnitude of resection, platelet count, presence of obesity	3 categories: low, medium, high
Southampton	Halls ^[71]	Preoperative chemotherapy, previous liver resection (open), malignant diagnosis, size, magnitude of resection	4 categories: low, moderate, high, extremely high

determining factor for the feasibility, safety and reproducibility of MILR, the evaluation of the complexity should be multifactorial as there are various factors that significantly contribute to the overall difficulty, which should then be - ultimately - related to the experience of the surgeon. With this vision, some useful and easy-to-apply scoring systems for predicting MILR complexity have been developed and validated and are currently popular tools for clinical practice and safe implementation of MILR. Table 3 summarizes the existing systems with their characteristics and grading of complexity.

For HCC, all four scoring systems have been shown to perform well in predicting operative time, blood loss, major postoperative complications, and hospital stay^[72]. Of note, the Iwate scoring system has been specifically validated for application in patients with HCC, particularly for predicting conversion to open and long-term oncological results^[72,73]. On this topic, Lv *et al.* reported that the Iwate grading correlates with short- and long-term outcomes in HCC patients in view of significant differences in intraoperative (operative time $P < 0.05$; blood loss $P < 0.05$), postoperative (hospital stay $P < 0.050$) and 5-year disease-free and overall survival (both $P < 0.050$) among the four categories^[72]. Instead, for ICC, no specific validation of the difficulty scores has been studied to date.

CONCLUSION

HCC surgery is particularly suitable for the minimally invasive approach. Laparoscopic resections for HCC are associated with improved short-term outcomes (reduced rate of ascites and liver failure) compared with open surgery, without compromising long-term oncological outcomes. These features of MILR are a landmark change in the last two decades for the surgical treatment of this disease and are the basis for a possible expansion of surgical candidates in patients with advanced liver dysfunction (portal hypertension, severe cirrhosis), which is now also to be considered when developing treatment guidelines for HCC. Although still in the phase of exploration, the use of minimally invasive surgery for ICC seems feasible and safe and short-term patient outcomes appear to benefit, but more evidence is needed to validate the long-term oncological outcomes compared to open. Should it be demonstrated that the short-term benefits are accompanied by non-inferior long-term oncological outcomes and the reproducibility of an adequate locoregional lymphadenectomy, MILR could be endorsed by expert guidelines as a standard treatment in centers with acquired expertise in the technique. Prospective trials leading to improvement of life expectancy after surgery both in HCC and ICC would be the optimal tool for research methodology; despite the difficulty, they should be encouraged.

DECLARATIONS

Authors' contributions

Made substantial contributions to the conception and design of the study and performed data analysis and interpretation: Cipriani F, Fornoni G, Rimini M, Pedica F, Invernizzi F, Casadei-Gardini A, De Cobelli F, Colombo M, Aldrighetti L

Availability of data and materials

Not applicable.

Financial support and sponsorship

None.

Conflicts of interest

All authors declared that there are no conflicts of interest.

Ethical approval and consent to participate

Not applicable.

Consent for publication

Not applicable.

Copyright

© The Author(s) 2023.

REFERENCES

1. Reich H, McGlynn F, DeCaprio J, Budin R. Laparoscopic excision of benign liver lesions. *Obstet Gynecol* 1991;78:956-8. [PubMed](#)
2. Cipriani F, Ratti F, Paganelli M, Reineke R, Catena M, Aldrighetti L. Laparoscopic or open approaches for posterosuperior and anterolateral liver resections? *HPB* 2019;21:1676-86. [DOI](#) [PubMed](#)
3. Beard RE, Wang Y, Khan S, Marsh JW, Tsung A, et al. Laparoscopic liver resection for hepatocellular carcinoma in early and advanced cirrhosis. *HPB* 2018; 20:521-529. [DOI](#) [PubMed](#)
4. Dagher I, Gayet B, Tzani D, et al. International experience for laparoscopic major liver resection. *J Hepatobiliary Pancreat Sci* 2014;21:732-6. [DOI](#) [PubMed](#)
5. Goumard C, Komatsu S, Brustia R, Fartoux L, Soubrane O, Scatton O. Technical feasibility and safety of laparoscopic right hepatectomy for hepatocellular carcinoma following sequential TACE-PVE: a comparative study. *Surg Endosc* 2017;31:2340-9. [DOI](#) [PubMed](#)
6. Pulitanò C, Arru M, Bellio L, Rossini S, Ferla G, Aldrighetti L. A risk score for predicting perioperative blood transfusion in liver surgery. *Br J Surg* 2007;94:860-5. [DOI](#) [PubMed](#)
7. Dam RM, Wong-Lun-Hing EM, et al; orANGE II Study Group. Open versus laparoscopic left lateral hepatic sectionectomy within an enhanced recovery ERAS® programme (orANGE II-trial): study protocol for a randomised controlled trial. *Trials* 2012;13:54. [DOI](#) [PubMed](#) [PMC](#)
8. Cipriani F, Ratti F, Fiorentini G, Catena M, Paganelli M, Aldrighetti L. Pure laparoscopic right hepatectomy: a risk score for conversion for the paradigm of difficult laparoscopic liver resections. a single centre case series. *Int J Surg* 2020;82:108-15. [DOI](#) [PubMed](#)
9. Yoh T, Cauchy F, Kawai T, et al. Laparoscopic right hepatectomy using the caudal approach is superior to open right hepatectomy with anterior approach and liver hanging maneuver: a comparison of short-term outcomes. *Surg Endosc* 2020;34:636-45. [DOI](#) [PubMed](#)
10. Ban D, Tanabe M, Ito H, et al. A novel difficulty scoring system for laparoscopic liver resection. *J Hepatobiliary Pancreat Sci* 2014;21:745-53. [DOI](#) [PubMed](#)
11. Cipriani F, Ratti F, Aldrighetti L. Laparoscopic liver resections at the gates of 2020: a stand-alone field of hepatobiliary surgery. *Hepatobiliary Surg Nutr* 2020;9:371-3. [DOI](#) [PubMed](#) [PMC](#)
12. Reig M, Forner A, Rimola J, et al. BCLC strategy for prognosis prediction and treatment recommendation: the 2022 update. *J Hepatol* 2022;76:681-93. [DOI](#) [PubMed](#) [PMC](#)
13. Aldrighetti L, Guzzetti E, Pulitanò C, et al. Case-matched analysis of totally laparoscopic versus open liver resection for HCC: short and middle term results. *J Surg Oncol* 2010;102:82-6. [DOI](#) [PubMed](#)
14. Tranchart H, Di Giuro G, Lainas P, et al. Laparoscopic resection for hepatocellular carcinoma: a matched-pair comparative study. *Surg Endosc* 2010;24:1170-6. [DOI](#) [PubMed](#)
15. Twaij A, Pucher PH, Sodergren MH, Gall T, Darzi A, Jiao LR. Laparoscopic vs. open approach to resection of hepatocellular carcinoma in patients with known cirrhosis: systematic review and meta-analysis. *World J Gastroenterol* 2014;20:8274-81. [DOI](#) [PubMed](#) [PMC](#)
16. Chen J, Bai T, Zhang Y, Xie ZB, Wang XB, et al. The safety and efficacy of laparoscopic and open hepatectomy in hepatocellular carcinoma patients with liver cirrhosis: a systematic review. *Int J Clin Exp Med* 2015;8:20679-89. [PubMed](#) [PMC](#)

17. Coletta D, De Padua C, Parrino C, et al. Laparoscopic liver surgery: what are the advantages in patients with cirrhosis and portal hypertension? *J Laparoendosc Adv Surg Tech A* 2020;30:1054-65. DOI PubMed
18. Kabir T, Tan ZZ, Syn NL, et al. Laparoscopic versus open resection of hepatocellular carcinoma in patients with cirrhosis: meta-analysis. *Br J Surg* 2021;109:21-9. DOI PubMed
19. Pan Y, Xia S, Cai J, Chen K, Cai X. Efficacy of laparoscopic hepatectomy versus open surgery for hepatocellular carcinoma with cirrhosis: a meta-analysis of case-matched studies. *Front Oncol* 2021;11:652272. DOI PubMed PMC
20. Wang ZY, Chen QL, Sun LL, et al. Laparoscopic versus open major liver resection for hepatocellular carcinoma: systematic review and meta-analysis of comparative cohort studies. *BMC Cancer* 2019;19:1047. DOI PubMed PMC
21. Hao F, Li H, Li N, Li J, Wu H. Laparoscopic repeat hepatectomy versus conventional open repeat hepatectomy for recurrent hepatocellular carcinoma: a systematic review and meta-analysis. *Front Oncol* 2022;12:960204. DOI PubMed PMC
22. Wang Q, Li HJ, Dai XM, Xiang ZQ, Zhu Z. Laparoscopic versus open liver resection for hepatocellular carcinoma in elderly patients: systematic review and meta-analysis of propensity-score matched studies. *Int J Surg* 2022;105:106821. DOI PubMed
23. Guro H, Cho JY, Han HS, Yoon YS, Choi Y, Periyasamy M. Current status of laparoscopic liver resection for hepatocellular carcinoma. *Clin Mol Hepatol* 2016;22:212-8. DOI PubMed PMC
24. Chen K, Pan Y, Zhang B, Liu XL, Maher H, Zheng XY. Laparoscopic versus open surgery for hepatocellular carcinoma: a meta-analysis of high-quality case-matched studies. *Can J Gastroenterol Hepatol* 2018;2018:1746895. DOI PubMed PMC
25. Gaillard M, Tranchart H, Dagher I. Laparoscopic liver resections for hepatocellular carcinoma: current role and limitations. *World J Gastroenterol* 2014;20:4892-9. DOI PubMed PMC
26. Fretland AA, Sokolov A, Postriganova N, et al. Inflammatory response after laparoscopic versus open resection of colorectal liver metastases: data from the oslo-comet Trial. *Medicine* 2015;94:e1786. DOI PubMed
27. Ratti F, Cipriani F, Fiorentini G, Catena M, Paganelli M, Aldrighetti L. Reappraisal of the advantages of laparoscopic liver resection for intermediate hepatocellular carcinoma within a stage migration perspective: propensity score analysis of the differential benefit. *J Hepatobiliary Pancreat Sci* 2020;27:510-21. DOI PubMed
28. Ciria R, Gomez-Luque I, Ocaña S, et al. A systematic review and meta-analysis comparing the short- and long-term outcomes for laparoscopic and open liver resections for hepatocellular carcinoma: updated results from the european guidelines meeting on laparoscopic liver surgery, southampton, UK, 2017. *Ann Surg Oncol* 2019;26:252-63. DOI PubMed
29. Kasai M, Cipriani F, Gayet B, et al. Laparoscopic versus open major hepatectomy: a systematic review and meta-analysis of individual patient data. *Surgery* 2018;163:985-95. DOI PubMed
30. Ivanics T, Claasen MP, Patel MS, et al. Long-term outcomes of laparoscopic liver resection for hepatocellular carcinoma: a propensity score matched analysis of a high-volume North American center. *Surgery* 2022;171:982-91. DOI PubMed
31. Goh EL, Chidambaram S, Ma S. Laparoscopic vs. open hepatectomy for hepatocellular carcinoma in patients with cirrhosis: a meta-analysis of the long-term survival outcomes. *Int J Surg* 2018;50:35-42. DOI PubMed
32. Sun Q, Zhang X, Gong X, et al. Survival analysis between laparoscopic and open hepatectomy for hepatocellular carcinoma: a meta-analysis based on reconstructed time-to-event data. *Hepatol Int* 2021;15:1215-35. DOI PubMed
33. Cipriani F, Fantini C, Ratti F, et al. Laparoscopic liver resections for hepatocellular carcinoma. can we extend the surgical indication in cirrhotic patients? *Surg Endosc* 2018;32:617-26. DOI PubMed
34. Troisi RI, Berardi G, Morise Z, et al. Laparoscopic and open liver resection for hepatocellular carcinoma with child-pugh B cirrhosis: multicentre propensity score-matched study. *Br J Surg* 2021;108:196-204. DOI PubMed
35. Molina V, Sampson-Dávila J, Ferrer J, et al. Benefits of laparoscopic liver resection in patients with hepatocellular carcinoma and portal hypertension: a case-matched study. *Surg Endosc* 2018;32:2345-54. DOI PubMed
36. Lim C, Osseis M, Lahat E, et al. Safety of laparoscopic hepatectomy in patients with hepatocellular carcinoma and portal hypertension: interim analysis of an open prospective study. *Surg Endosc* 2019;33:811-20. DOI PubMed
37. Abu Hilal M, Aldrighetti L, Dagher I, et al. The southampton consensus guidelines for laparoscopic liver surgery: from indication to implementation. *Ann Surg* 2018;268:11-8. DOI PubMed
38. Mavros MN, Economopoulos KP, Alexiou VG, Pawlik TM. Treatment and prognosis for patients with intrahepatic cholangiocarcinoma: systematic review and meta-analysis. *JAMA Surg* 2014;149:565-74. DOI PubMed
39. Bridgewater J, Galle PR, Khan SA, et al. Guidelines for the diagnosis and management of intrahepatic cholangiocarcinoma. *J Hepatol* 2014;60:1268-89.[DOI:10.1016/j.jhep.2014.01.021] Caution!
40. Weber SM, Ribero D, O'Reilly EM, Kokudo N, Miyazaki M, Pawlik TM. Intrahepatic cholangiocarcinoma: expert consensus statement. *HPB* 2015;17:669-80. DOI PubMed PMC
41. Reames BN, Bagante F, Ejaz A, et al. Impact of adjuvant chemotherapy on survival in patients with intrahepatic cholangiocarcinoma: a multi-institutional analysis. *HPB* 2017;19:901-9. DOI PubMed
42. Spolverato G, Yakoob MY, Kim Y, et al. Impact of complications on long-term survival after resection of intrahepatic cholangiocarcinoma. *Cancer* 2015;121:2730-9. DOI PubMed
43. Tsilimigras DI, Sahara K, Wu L, et al. Very early recurrence after liver resection for intrahepatic cholangiocarcinoma: considering alternative treatment approaches. *JAMA Surg* 2020;155:823-31. DOI PubMed PMC
44. Belfiore MP, Reginelli A, Maggialelli N, et al. Preliminary results in unresectable cholangiocarcinoma treated by CT percutaneous irreversible electroporation: feasibility, safety and efficacy. *Med Oncol* 2020;37:45. DOI PubMed
45. Uy BJ, Han HS, Yoon YS, Cho JY. Laparoscopic liver resection for intrahepatic cholangiocarcinoma. *J Laparoendosc Adv Surg Tech*

- A* 2015;25:272-7. [DOI](#) [PubMed](#)
46. Lee W, Park JH, Kim JY, et al. Comparison of perioperative and oncologic outcomes between open and laparoscopic liver resection for intrahepatic cholangiocarcinoma. *Surg Endosc* 2016;30:4835-40. [DOI](#) [PubMed](#)
 47. Ratti F, Cipriani F, Ariotti R, et al. Safety and feasibility of laparoscopic liver resection with associated lymphadenectomy for intrahepatic cholangiocarcinoma: a propensity score-based case-matched analysis from a single institution. *Surg Endosc* 2016;30:1999-2010. [DOI](#) [PubMed](#)
 48. Regmi P, Hu HJ, Paudyal P, et al. Is laparoscopic liver resection safe for intrahepatic cholangiocarcinoma? *Eur J Surg Oncol* 2021;47:979-89. [DOI](#) [PubMed](#)
 49. Machairas N, Kostakis ID, Schizas D, Kykalos S, Nikiteas N, Sotiropoulos GC. Meta-analysis of laparoscopic versus open liver resection for intrahepatic cholangiocarcinoma. *Updates Surg* 2021;73:59-68. [DOI](#) [PubMed](#)
 50. Ziogas IA, Esagian SM, Giannis D, et al. Laparoscopic versus open hepatectomy for intrahepatic cholangiocarcinoma: an individual patient data survival meta-analysis. *Am J Surg* 2021;222:731-8. [DOI](#) [PubMed](#)
 51. Wei F, Lu C, Cai L, Yu H, Liang X, Cai X. Can laparoscopic liver resection provide a favorable option for patients with large or multiple intrahepatic cholangiocarcinomas? *Surg Endosc* 2017;31:3646-55. [DOI](#) [PubMed](#)
 52. Zhu Y, Song J, Xu X, Tan Y, Yang J. Safety and feasibility of laparoscopic liver resection for patients with large or multiple intrahepatic cholangiocarcinomas: a propensity score based case-matched analysis from a single institute. *Medicine* 2019;98:e18307. [DOI](#) [PubMed](#) [PMC](#)
 53. Martin SP, Drake J, Wach MM, et al. Laparoscopic approach to intrahepatic cholangiocarcinoma is associated with an exacerbation of inadequate nodal staging. *Ann Surg Oncol* 2019;26:1851-7. [DOI](#) [PubMed](#) [PMC](#)
 54. Kinoshita M, Kanazawa A, Takemura S, et al. Indications for laparoscopic liver resection of mass-forming intrahepatic cholangiocarcinoma. *Asian J Endosc Surg* 2020;13:46-58. [DOI](#) [PubMed](#)
 55. Kang SH, Choi Y, Lee W, et al. Laparoscopic liver resection versus open liver resection for intrahepatic cholangiocarcinoma: 3-year outcomes of a cohort study with propensity score matching. *Surg Oncol* 2020;33:63-9. [DOI](#) [PubMed](#)
 56. Haber PK, Wabitsch S, Kästner A, et al. Laparoscopic liver resection for intrahepatic cholangiocarcinoma: a single-center experience. *J Laparoendosc Adv Surg Tech A* 2020;30:1354-9. [DOI](#) [PubMed](#)
 57. Bertagna F, Bertoli M, Bosio G, et al. Diagnostic role of radiolabelled choline PET or PET/CT in hepatocellular carcinoma: a systematic review and meta-analysis. *Hepatol Int* 2014;8:493-500. [DOI](#) [PubMed](#)
 58. Amini N, Ejaz A, Spolverato G, Maithel SK, Kim Y, Pawlik TM. Management of lymph nodes during resection of hepatocellular carcinoma and intrahepatic cholangiocarcinoma: a systematic review. *J Gastrointest Surg* 2014;18:2136-48. [DOI](#) [PubMed](#)
 59. Fiorentini G, Ratti F, Cipriani F, Catena M, Paganelli M, Aldrighetti L. Challenges and technical innovations for an effective laparoscopic lymphadenectomy in liver malignancies. *J Laparoendosc Adv Surg Tech A* 2019;29:72-5. [DOI](#) [PubMed](#)
 60. Ratti F, Fiorentini G, Cipriani F, Paganelli M, Catena M, Aldrighetti L. Perioperative and long-term outcomes of laparoscopic versus open lymphadenectomy for biliary tumors: a propensity-score-based, case-matched analysis. *Ann Surg Oncol* 2019;26:564-75. [DOI](#) [PubMed](#)
 61. Anselmo A, Siragusa L, Pisani G, Materazzo M, Pirozzi B, Tisone G. Laparoscopic left hemihepatectomy for intrahepatic cholangiocellular carcinoma: an adequate lymphadenectomy is also possible in artery variation. *Ann Surg Oncol* ;2022:4359-60. [DOI](#) [PubMed](#)
 62. Zhang Y, Zhang Y, Zhu J, et al. Clinical application of indocyanine green fluorescence imaging in laparoscopic lymph node dissection for intrahepatic cholangiocarcinoma: a pilot study (with video). *Surgery* 2022;171:1589-95. [DOI](#) [PubMed](#)
 63. Shiraiwa DK, Carvalho PFDC, Maeda CT, et al. The role of minimally invasive hepatectomy for hilar and intrahepatic cholangiocarcinoma: a systematic review of the literature. *J Surg Oncol* 2020;121:863-72. [DOI](#) [PubMed](#)
 64. Cao J, Hu J, Liu S, et al. Intrahepatic cholangiocarcinoma: genomic heterogeneity between eastern and western patients. *JCO Precis Oncol* 2020;4. [DOI](#) [PubMed](#) [PMC](#)
 65. Baecker A, Liu X, La Vecchia C, Zhang ZF. Worldwide incidence of hepatocellular carcinoma cases attributable to major risk factors. *Eur J Cancer Prev* 2018;27:205-12. [DOI](#) [PubMed](#) [PMC](#)
 66. Buell JF, Cherqui D, Geller DA, et al; World consensus conference on laparoscopic surgery. The international position on laparoscopic liver surgery: the louisville statement, 2008. *Ann Surg* 2009;250:825-30. [DOI](#) [PubMed](#)
 67. Ishizawa T, Gumbs AA, Kokudo N, Gayet B. Laparoscopic segmentectomy of the liver: from segment I to VIII. *Ann Surg* 2012;256:959-64. [DOI](#) [PubMed](#)
 68. Kawaguchi Y, Fuks D, Kokudo N, Gayet B. Difficulty of laparoscopic liver resection: proposal for a new classification. *Ann Surg* 2018;267:13-7. [DOI](#) [PubMed](#)
 69. Gholami S, Judge SJ, Lee SY, et al. Is minimally invasive surgery of lesions in the right superior segments of the liver justified? *J Surg Oncol* 2020;122:1428-34. [DOI](#) [PubMed](#) [PMC](#)
 70. Hasegawa Y, Wakabayashi G, Nitta H, et al. A novel model for prediction of pure laparoscopic liver resection surgical difficulty. *Surg Endosc* 2017;31:5356-63. [DOI](#) [PubMed](#)
 71. Halls MC, Berardi G, Cipriani F, et al. Development and validation of a difficulty score to predict intraoperative complications during laparoscopic liver resection. *Br J Surg* 2018;105:1182-91. [DOI](#) [PubMed](#)
 72. Lin H, Bai Y, Yin M, Chen Z, Yu S. External validation of different difficulty scoring systems of laparoscopic liver resection for hepatocellular carcinoma. *Surg Endosc* 2022;36:3732-49. [DOI](#) [PubMed](#)

73. Lv X, Zhang L, Yu X, Yu H. The difficulty grade of laparoscopic hepatectomy for hepatocellular carcinoma correlates with long-term outcomes. *Updates Surg.* DOI PubMed