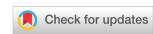

Technical Note

Open Access



# Robotic Ivor Lewis esophagectomy

James M. Ackerman, James D. Luketich, Inderpal S. Sarkaria

Department of Cardiothoracic Surgery, University of Pittsburgh Medical Center, Pittsburgh, PA 15213, USA.

**Correspondence to:** Dr. Inderpal Sarkaria, Department of Cardiothoracic Surgery, University of Pittsburgh Medical Center, 200 Lothrop Street, Pittsburgh, PA 15213, USA. E-mail: sarkariais@upmc.edu.

**How to cite this article:** Ackerman JM, Luketich JD, Sarkaria IS. Robotic Ivor Lewis esophagectomy. *Mini-invasive Surg* 2021;5:14. <https://dx.doi.org/10.20517/2574-1225.2021.02>

**Received:** 6 Jan 2021 **First Decision:** 26 Jan 2021 **Revised:** 7 Feb 2021 **Accepted:** 23 Feb 2021 **Available online:** 8 Apr 2021

**Academic Editor:** Farid Gharagozloo **Copy Editor:** Xi-Jun Chen **Production Editor:** Xi-Jun Chen

## Abstract

The addition of robotic-assistance is the latest evolution of minimally invasive esophageal resection and reconstruction. Despite the improved visualization, the addition of wristed instrumentation, and improved ergonomics, there remains a significant learning curve for complex procedures like esophagectomy. In experienced, high-volume centers, robotic-assisted minimally invasive esophagectomy (RAMIE) has demonstrated outcomes equivalent to traditional laparoscopic and thoracoscopic minimally invasive esophagectomy. Herein, the RAMIE procedure is described in detail in key steps. This approach has been established as safe and effective for esophagectomy.

**Keywords:** Robotic esophagectomy, esophagectomy, esophageal cancer, Ivor Lewis, robotic-assisted minimally invasive esophagectomy

## INTRODUCTION

Worldwide, esophageal cancer is the seventh most commonly occurring cancer in men and the 13th most commonly occurring cancer in women<sup>[1]</sup>. Overall, there are 572,000 new cases per year and esophageal cancer carries the sixth-highest overall mortality, being responsible for an estimated 1 in every 20 cancer deaths in 2018<sup>[1]</sup>. Although also performed for benign diseases, esophageal cancer represents the most common indication for esophagectomy<sup>[2]</sup>. In this work, we outline the general principles of the preoperative evaluation, technical details of intraoperative steps, and the outcomes of robotic-assisted minimally invasive esophagectomy (RAMIE).



© The Author(s) 2021. **Open Access** This article is licensed under a Creative Commons Attribution 4.0 International License (<https://creativecommons.org/licenses/by/4.0/>), which permits unrestricted use, sharing, adaptation, distribution and reproduction in any medium or format, for any purpose, even commercially, as long as you give appropriate credit to the original author(s) and the source, provide a link to the Creative Commons license, and indicate if changes were made.

## BACKGROUND

As a complex, multi-cavity procedure, Ivor Lewis esophagectomy requires a thorough understanding of surgical anatomy, technical skill, and perioperative care to achieve acceptable outcomes. The first successful transthoracic esophagectomy was performed in 1913 by Dr. Torek<sup>[3]</sup>, which marked the beginning of the open surgical era that was plagued by high morbidity. Even in this modern era, outcomes can vary widely, with mortality ranging from 8%-23%, largely dependent upon hospital volume<sup>[4]</sup>. However, in experienced centers, an acceptable 30-day (and even 90-day) hospital and/or overall mortality below 5% is often achieved and becoming the standard<sup>[5]</sup>. The initial descriptions of a minimally invasive esophagectomy (MIE) in the early 1990s by Drs. Cuschieri *et al.*<sup>[6]</sup>, Dallemagne *et al.*<sup>[7]</sup>, and DePaula *et al.*<sup>[8]</sup> ushered in a new era of esophageal surgery. The safety, feasibility, oncologic soundness, and reproducibility of MIE were validated in Eastern Cooperative Oncology Group (ECOG) 2202, a large, multicenter, prospective, randomized trial published in 2015<sup>[9]</sup>. As the MIE was gaining popularity, the first report of a RAMIE was published by Dr. Horgan *et al.*<sup>[10]</sup> in 2003. Since its introduction, RAMIE has been validated against the standard open and minimally invasive approaches<sup>[11]</sup>. When compared to open esophagectomy, RAMIE has demonstrated intraoperative benefits including less blood loss and more complete lymphadenectomy, despite its longer operative time. RAMIE showed faster convalescence with a shorter length of stay (LOS), decreased pain, decreased intensive care unit (ICU) admissions, and fewer infectious and cardiopulmonary complications. There were no consistent differences in overall major complications, anastomotic leak rate, and 90-day mortality<sup>[11-13]</sup>. When directly compared to MIE, RAMIE resulted in longer operative time, but no significant difference in blood loss, overall complication rate, length of stay, or the number of total dissected lymph nodes<sup>[14]</sup>.

## PREOPERATIVE PREPARATION

### Risk stratification

In efforts to define and reduce significant morbidity and mortality, multiple attempts have been made to define the risk factors associated with the adverse outcomes of esophagectomy. A large, prospective analysis of the Department of Veterans Affairs (VA) National Surgical Quality Improvement Program (NSQIP) database identified both preoperative and intraoperative risk factors for morbidity and mortality. Preoperative predictors impacting mortality included neoadjuvant therapy, decreased functional status, increasing age, insulin-dependent diabetes mellitus, and signs of hepatic dysfunction (elevated blood urea nitrogen, elevated alkaline phosphatase, alcohol abuse, and ascites), while the addition of dyspnea with mild exertion, chronic obstructive pulmonary disease, decreased serum albumin concentration, and an increased complexity score increased overall morbidity<sup>[15]</sup>. Intraoperative risk factors for morbidity included the need for blood transfusion and prolonged operative time, while only transfusion requirement impacted mortality<sup>[15]</sup>. A review of the Society of Thoracic Surgeons General Thoracic Surgery Database revealed age > 65, BMI  $\geq$  35, preoperative congestive heart failure, Zubrod score > 1, McKeown Esophagectomy, current or former smoking status, and squamous cell histology to be significant predictors of combined major morbidity or mortality<sup>[16]</sup>.

A preoperative esophagectomy risk score, developed as a composite of the revised cardiac risk index, the model for end-stage liver disease score, and the pulmonary function test, was found to be an independent predictor of tumor recurrence and overall survival<sup>[17]</sup>. At our institution, we routinely calculate the Risk Analysis Index (RAI), which is a practical, prospective frailty assessment tool requiring only a median of 33 s to complete and demonstrates a dose-dependent relationship with mortality, overall LOS, ICU LOS, and readmission. When comparing patients using an RAI cutoff of  $\geq$  37 with those < 37, there was a 60% higher 30-day and 90-day readmission rate, twice the rate of an extended LOS > 14 days, and almost twice the rates of prolonged ICU stay. When comparing for 180-day mortality, an RAI of < 37 carried an NPV of 98.6%

while an RAI of  $\geq 37$  had a PPV of 10.7%<sup>[18]</sup>.

### **Disease specific**

In addition to the aforementioned assessments, additional testing is performed selectively based on the patient's underlying ailment.

#### *Malignancy*

Once malignancy is confirmed by endoscopic biopsy, staging is completed with endoscopic ultrasound (EUS), computed tomography (CT) with fluorodeoxyglucose-18 positron emission tomography (PET), and/or staging laparoscopy with gastric extension<sup>[19]</sup>. Upfront surgery is offered for selected patients with node-negative clinical T1a or T1b tumors, and patients with T2 N0 disease. For patients with potentially resectable disease that are clinically node-positive or at high-risk for node positivity (cT3-4), neoadjuvant chemotherapy with or without radiation is performed before restaging and consideration for surgery. Patients with local-regional disease unfit for surgery are treated with definitive chemoradiotherapy. This approach echoes with that outlined by the American Society of Clinical Oncology in their recent guideline<sup>[20]</sup>.

#### *Benign*

Less commonly performed for benign indications than for malignant, esophagectomy remains a definitive treatment for several conditions. End-stage achalasia, previously failed (often multiple) operations for gastroesophageal reflux disease (GERD) and/or hiatal hernia, and trauma account for 84% of esophagectomies for benign indications<sup>[21]</sup>. Other less common indications in selected patients include motility disorders (diffuse esophageal spasm, scleroderma), strictures, benign tumors, spontaneous or iatrogenic perforations, congenital anomalies, and caustic ingestion.

The preoperative workup is tailored to the exact benign indication. At a minimum, esophagoscopy and fluoroscopic esophagram are required. Frequent additions include but are not limited to CT scans, esophageal manometry, esophageal pH monitoring, endoscopic ultrasound, endobronchial ultrasound, gastric emptying studies, and bronchoscopy.

## **OPERATIVE TECHNIQUE**

Despite many technological advances, the principles and techniques of minimally invasive esophagectomy at the University of Pittsburgh remain largely unchanged from Dr. Luketich's early description in the 1990s<sup>[2,22-24]</sup>. Especially for those with prior minimally invasive esophageal surgery experience, the robotic techniques described are largely an evolution of the traditional minimally invasive concepts rather than a unique procedure, albeit with far more sophisticated instrumentation<sup>[25]</sup>. Here, we describe in detail the Ivor Lewis esophagectomy for malignant diseases and also discuss minor differences in procedures for benign indications.

### **Pre-incision**

Although often overlooked, the period prior to an incision should be used as an opportunity to maximize the chances of a successful surgery. The team should review the case specifics ahead of time and outline a clear plan for the conduct of the operation. Attention should be paid to emergency contingencies and plans for such events should be verbalized.

### *Anesthesia*

The patient should be anesthetized under general anesthesia with a double-lumen endotracheal tube, adequate IV access, and invasive hemodynamic monitoring. If a central venous catheter is inserted, we prefer to avoid the left neck and chest in the event a cervical esophagostomy is required. The position of the double lumen endotracheal tube is confirmed with fiberoptic bronchoscopy. Alternatively, newer double lumen endobronchial blockers may be utilized through a single lumen endotracheal tube (Rusch EZ-Blocker, Teleflex). All patients receive venous thromboembolism prophylaxis with sequential compression devices and subcutaneous heparin. Perioperative antibiotics should comply with Surgical Care Improvement Project measures, with cefazolin being the first-line of choice<sup>[26]</sup>. Communication between the surgeon and anesthesia provider is crucial to the conduct of the operation. The surgeon should be made aware of the patient's hemodynamic changes at all times. Once the gastric vasculature is divided, hypotension should generally be treated with volume expansion as opposed to vasopressors to minimize conduit ischemia.

### *Endoscopy*

Flexible fiberoptic esophagogastrosopy is routinely performed at our institution. This allows for a final assessment of the esophageal pathology for which the esophagectomy is indicated. The stomach and esophagus should be decompressed on withdrawal of the scope to allow for safe laparoscopic port placement and subsequent visualization.

### **Laparoscopy**

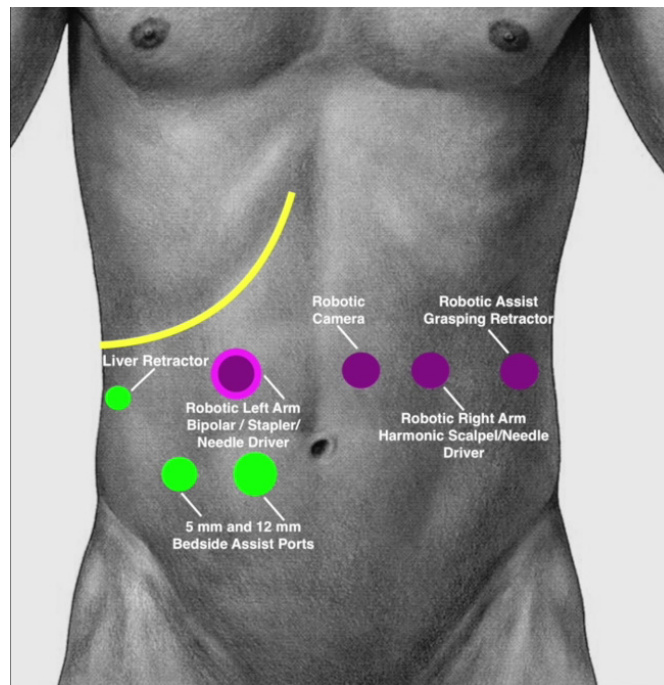
Ivor Lewis esophagectomy begins in the abdomen and progresses through an assessment for metastatic disease, esophagogastric mobilization with lymphadenectomy, conduit creation, pyloroplasty, and feeding jejunostomy insertion.

### *Positioning*

The patient is placed in a supine position on the operating table with a footboard to allow for safe steep reverse-Trendelenburg positioning. The left arm is tucked and the right arm is extended to approximately 45 degrees. For non-robotic procedures, the surgeon stands on the patient's right side with the assistant standing on the left. A liver retractor (Lapro-Flex® Triangular Retractor, Mediflex, Islandia, NY) is attached to the right side of the bed between the knee and hip.

### *Port placement*

Abdominal port placement is shown in [Figure 1](#). Although we find these locations to be the most useful, port placement may vary based on surgeon preference or patient factors. The peritoneal cavity is accessed per surgeon comfort, although we prefer starting with an optical separator 5 mm robotic port in the left midclavicular line approximately 3 cm inferior to the costal margin. This port will be replaced with an 8 mm robotic port and used for the robotic right arm (arm 3). In a potentially hostile abdomen, the location and method of entry should be tailored to the scenario with a focus on safety. The abdomen is insufflated, and a 30-degree camera is introduced into the abdomen. Adhesiolysis is performed as necessary to facilitate placement of subsequent ports under direct laparoscopic visualization. Three additional robotic working ports, a port for the liver retractor, and two bedside assistant ports are placed. The additional robotic ports include a 12 mm robotic port with an 8 mm reducing sheath in the right midclavicular line approximately one-third from the umbilicus to xiphoid for the robotic left arm and stapler (arm 1), an 8 mm robotic port just to the left of midline approximately one-third from the umbilicus to xiphoid for the camera (arm 2), and an 8 mm robotic port in the left anterior axillary line 2-3 cm inferior to the costal margin for the robotic assist (arm 4). The laparoscopic liver retractor port is placed inferior to the costal margin in the right midaxillary line just anterior to the peritoneal reflection of the hepatic flexure of the colon. The bedside



**Figure 1.** Port location for abdominal portion. The yellow line denotes the costal margin. This figure is quoted with permission from Ekeke *et al.*<sup>[27]</sup>.

assistant ports are placed in the right lower paraumbilical region and include an 11 mm laparoscopic port just medial to the midclavicular line and a 5 mm laparoscopic port approximately a hands breadth lateral to the 11 mm port. The patient is placed in a steep reverse-Trendelenburg position to displace the viscera from the diaphragm. The liver retractor is inserted, and the left lobe of the liver is elevated.

#### *Docking*

The da Vinci Xi robotic side cart (Intuitive Surgical, Sunnyvale, CA) is brought in from the patient's right at the level of the torso and the camera port is docked to arm 2. The hiatus is targeted, the remaining arms are docked, the instruments are inserted, and patient clearance is optimized. A da Vinci Force Bipolar grasper (Intuitive Surgical, Sunnyvale, CA) is initially inserted into arm 1 (robotic left hand), an ultrasonic shear is inserted into arm 3 (robotic right hand), and a da Vinci small grasping retractor (Intuitive Surgical, Sunnyvale, CA) is inserted into arm 4 (robotic assist). The bedside assistant utilizes a suction and a laparoscopic grasper.

#### *Crural assessment*

Dissection begins by excising the gastrohepatic ligament to expose the caudate lobe of the liver and the right diaphragmatic crus. The dissection should stay close to the liver from the porta hepatis to the right crus to reflect any lymphoid tissue with the specimen. A replaced or accessory left hepatic artery is occasionally encountered in the gastrohepatic ligament. Preservation of this artery makes the remaining operation more difficult but should be considered if the vessel appears to represent a significant contribution to hepatic circulation, such as a replaced left hepatic artery. If there is doubt, the vessel can be temporarily occluded, and the liver can be observed for signs of ischemia before division. The phrenoesophageal ligament is incised circumferentially and the esophagus is mobilized from the crura. If there is diaphragmatic invasion by the tumor, the muscle may be resected en bloc with the specimen. The mobilization continues anteriorly along the pericardium and posteriorly along the aorta to assess for tumor invasion that may render the

tumor unresectable [Figure 2].

#### *Retrogastric dissection*

To expose the left gastric vascular pedicle, the stomach is retracted anteriorly by passing the robotic assist arm posterior to the stomach, medial to the left gastric pedicle, and into the lesser sac with the bedside assistant elevating the gastroesophageal junction [Figure 3]. The origin of the left gastric artery and vein are identified, and the lymphatic tissue is reflected with the specimen [Figure 4]. The lymphadenectomy continues along the splenic and common hepatic vascular pedicles to complete the celiac dissection. The left gastric artery and vein are divided with a robotic vascular staple load [Figure 5]. Initial short gastric dissection is initiated from a retrogastric approach and continues along the gastrosplenic hilum [Figure 6].

#### *Greater curvature dissection*

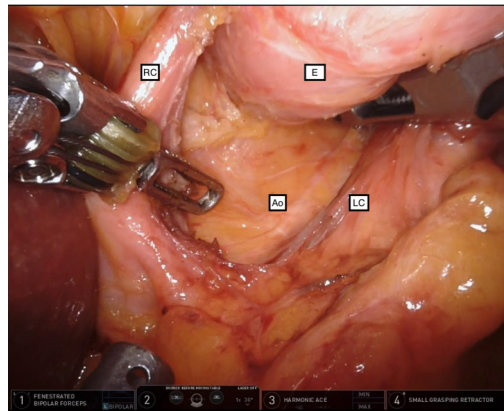
The robotic assist arm and bedside assist arm are advanced posterior to the stomach towards the left upper quadrant to expose the short gastric vessels in the retrogastric plane. Greater curve dissection, along with completion of the gastrosplenic ligament dissection initiated from the retrogastric approach, is continued along the fundus from proximal to distal while individually ligating the short gastric vessels with ultrasonic shears. Especially in patients with preoperative radiotherapy, a pedicled omental flap can be created along two sequential omental branches off the gastroepiploic arcade during this portion of the mobilization (not shown). The retrogastric attachments to the retroperitoneum are divided. The dissection continues along the greater curve of the stomach to approximately the pylorus. The lesser curve of the stomach is then gently grasped with arm 4 in an area that will be included with the specimen and is retracted towards the hiatus/liver. Taking care to avoid injuring the gastroepiploic vascular arcade, the dissection continues along the greater curve of the stomach and omentum, completely freeing the attachments that restrict mobilization of the stomach. A partial or complete Kocher maneuver may be completed if desired by the surgeon. The remaining retroantral attachments are divided. Adequate tension-free mobilization is confirmed by ensuring that the pylorus reaches the right crus of the diaphragm.

#### *Conduit creation*

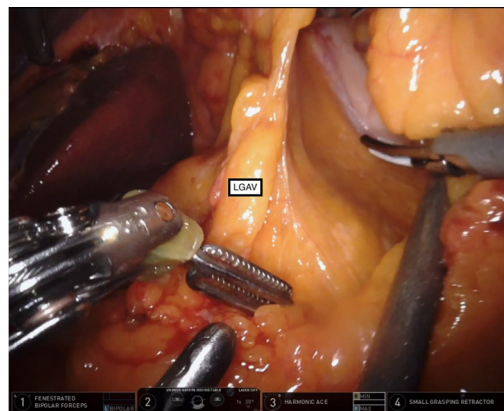
The pylorus is identified and a site on the stomach approximately 5-6 cm proximal to the pylorus is identified as the distal aspect of the gastric tube. The stomach is oriented for conduit creation with the arm 4 robot assist retracting the fundus towards the apex of the left hemidiaphragm, thus clearly delineating the orientation and lay of the future conduit [Figure 7]. Once the conduit is initiated, the robotic right-hand arm 3 “hooks” and retract the neo-lesser curve inferiorly to provide traction and better reveal the anticipated staple path to create a linear conduit. The first robotic stapler firing is a vascular load and traverses and ligates the lesser curve vasculature [Figure 8]. A 3 cm gastric conduit is then created with multiple fires of the robotic stapler parallel to the greater curve of the stomach [Figure 9]. Care should be taken to keep the staple line parallel to the short gastric line for proper orientation. The proximal tip of the conduit should be divided at a point that allows for adequate conduit length but maintains an appropriate oncologic margin. The tip of the conduit is tacked to the specimen in anatomic orientation with a horizontal mattress suture and the omental flap (if created) is tacked to the tip of the conduit. A marking stitch is placed on the conduit staple line at the junction between the future subdiaphragmatic antral reservoir and the supradiaphragmatic neo-esophagus. The specimen and proximal conduit may be tucked into the mediastinum. A cruroplasty is not routinely performed unless the hiatus is exceptionally enlarged.

#### *Pyloroplasty*

The role of pyloroplasty is debated but is frequently performed. When performed, a Heineke-Mikulicz pyloroplasty is utilized. The pylorus is identified, using endoscopy if necessary. Stay sutures are placed at the



**Figure 2.** Early circumferential hiatal mobilization is performed to assess the extent of local disease and ensure resectability. E: Esophagus; RC: right crural pillar; LC: left crural pillar; Ao: aorta.

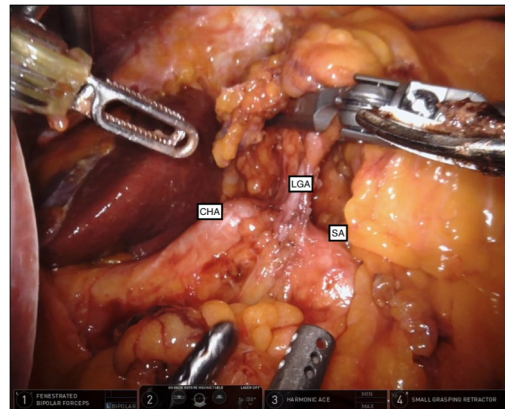


**Figure 3.** Retrogastric exposure is obtained by retracting the stomach anteriorly by passing the robotic assist arm into the lesser sac and elevating the gastroesophageal junction anteriorly. The bedside assist arm provides further retraction of the stomach and lesser omentum, as shown, to clearly expose the vascular pedicle and retrogastric space. LGAV: Left gastric artery and vein.

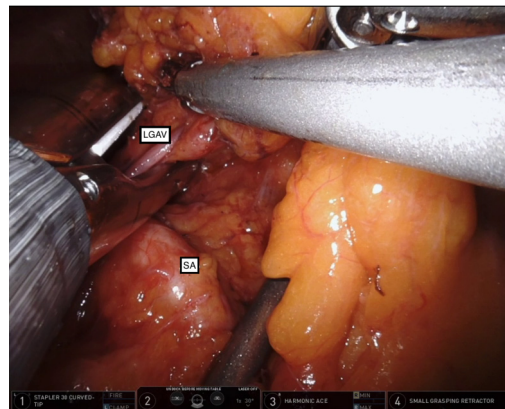
lateral aspects of the pylorus including the vein of Mayo. The robotic left arm grasps the “superior” stay suture (screen orientation) and the bedside assistant grasps the “inferior” stay suture to apply traction on the pylorus. The pylorus is divided along its full width with a longitudinal full-thickness antro-duodenal incision [Figure 10]. The lumen should be inspected to ensure no injury to the back wall and complete division of the muscle. The defect is closed transversely with 2-0 non-absorbable braided sutures [Figure 11]. The sutures must be of full-thickness to include the mucosa, but avoid catching the back wall. A portion of the omentum can be secured over the closure for added protection from a leak.

### *Feeding jejunostomy*

Traditionally, feeding jejunostomy tubes are placed at the time of esophagectomy for nutritional support. While we advocate routine placement of a feeding tube, like pyloroplasty, there is some debate and equipoise regarding the necessity of this procedure<sup>[28]</sup>. Although it can be performed with robotic assistance, we elect to perform this with routine laparoscopy as the last part of the abdominal procedure. The robotic instruments are removed and the robot is undocked from the patient. With a 5 mm 30-degree laparoscopic camera in the 5 mm right lower quadrant port, and in-line graspers in the right subcostal robotic port and the right lower quadrant 12 mm port, the transverse colon is retracted cranially to expose the ligament of Treitz. The jejunum is measured for a length of 35-40 cm, and a loop near this distance is selected that easily



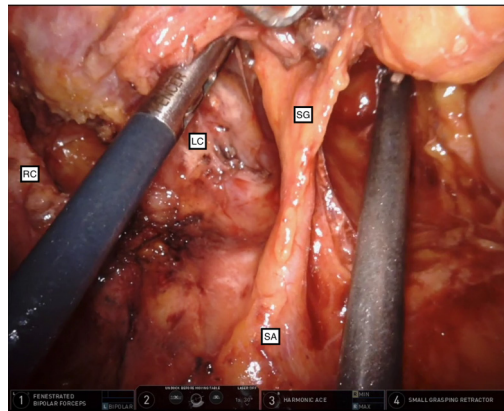
**Figure 4.** The celiac axis is skeletonized along the left gastric vascular pedicle, splenic artery, and common hepatic artery. All lymph node bearing tissue is dissected, elevated, and kept with the specimen. LGA: Left gastric artery and vein; CHA: common hepatic artery; SA: splenic artery.



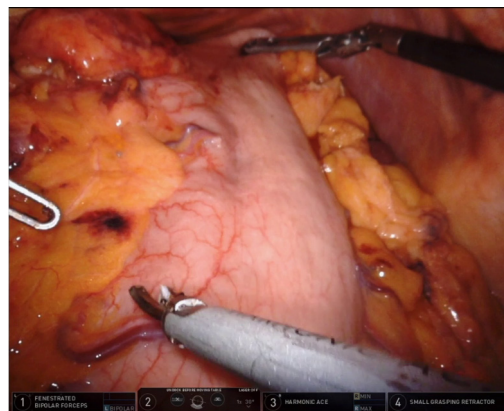
**Figure 5.** The left gastric artery and vein are divided with a robotic vascular stapler. LGAV: Left gastric artery and vein; SA: splenic artery.

reaches the anterior abdominal wall. An insertion site in the left lower quadrant is selected and a 25-gauge needle is inserted through the skin to identify the jejunostomy tube site. The jejunum is then sutured to the abdominal wall with a 2-0 Surgidac Endostitch (Medtronic, New Haven, CT), keeping the orientation of the afferent and efferent limbs. The finder needle is exchanged for a Yueh needle, which is advanced through the abdominal wall into the jejunal lumen. The intraluminal position is confirmed by an air bolus. Next, a guidewire is inserted into the distal limb of the jejunum and the Yueh needle is removed. A skin incision is made, the dilator and sheath are advanced over the wire into the jejunal lumen under direct visualization, and the guidewire and dilator are removed leaving the sheath in place. A 10-French jejunostomy tube is trimmed to a length of 20 cm from the balloon, which is cut to avoid accidental inflation. The feeding tube is advanced through the sheath into the distal limb of jejunum and the sheath is removed. Two Witzel-type 2-0 Surgidac Endostitches are placed on the efferent jejunum and the jejunum is circumferentially sutured to the abdominal wall with a 2-0 Surgidac Endostitch. An additional 2-0 Surgidac Endostitch is placed a few centimeters distally as an anti-torsion stitch. The tube position is again confirmed by an air bolus. The feeding tube is secured to the bumper with a 2-0 silk suture and the bumper is secured to the skin with 2-0 silk sutures.

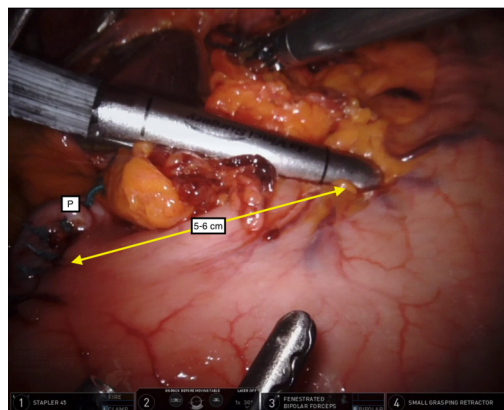




**Figure 6.** Greater curve dissection with individual ligation of the short gastric vessels is performed with the retrogastric approach. SG: Short gastric vessels; RC: right crural pillar; LC: left crural pillar; SA: splenic artery.



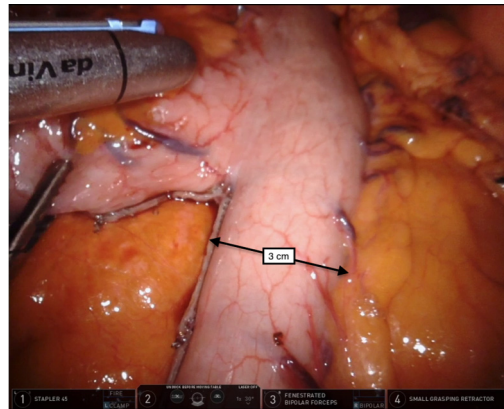
**Figure 7.** The stomach is oriented for conduit creation by retracting the tip of the fundus towards the apex of the left hemidiaphragm with the robotic assist (arm 4).



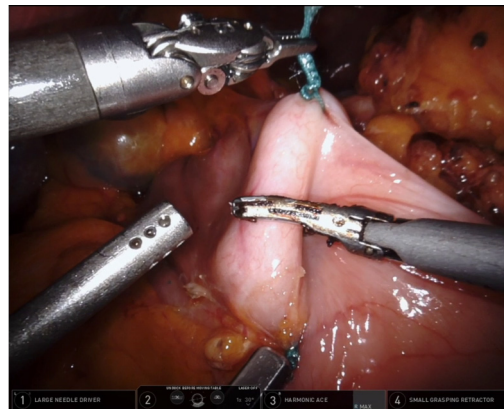
**Figure 8.** The first robotic vascular stapler is fired 5-6 cm proximal to the pylorus to include the lesser omentum and ending just on the stomach. P: Pylorus.

### *Closing*

The liver retractor and its port are removed under direct visualization and the fascia of the port sites are



**Figure 9.** A 3 cm gastric conduit is created with multiple fires of the robotic endo-gastrointestinal stapler parallel to the greater curve of the stomach, and the insertion line of the left gastroepiploic and short gastric vessels. Note the clear orientation of the conduit-information at all times.



**Figure 10.** Pyloromyotomy is performed by dividing the pylorus longitudinally along its entire length with the ultrasonic scalpel. Note the “12 o'clock” and “6 o'clock” orientation of the pylorus created by traction on the lateral stay sutures.

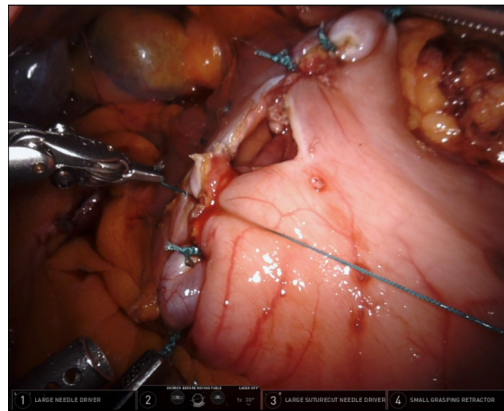
closed according to surgeon comfort. We prefer to use a Carter-Thomason suture passer for entry sites 12 mm or greater (the right upper abdominal stapler port). Drains are not routinely placed in the abdomen. We frequently place a left pleural pigtail catheter after the abdominal portion of the operation before positioning the patient laterally. This allows for the evacuation of potential pneumothorax or pleural effusion if the left pleura is violated during the thoracic portion of the esophagectomy.

### Thoracoscopy

After completion of the abdominal portion, Ivor Lewis esophagectomy proceeds in the chest for esophageal mobilization with en bloc mediastinal lymphadenectomy, specimen removal, and restoration of intestinal continuity by esophagogastrostomy.

### Positioning

The patient is turned into the left lateral decubitus position on a padded beanbag. The bed is flexed to widen the intercostal spaces and the beanbag is deflated to secure the patient. A gel axillary roll is placed in the left axilla and the right arm is secured with an arm holder. The position of the double-lumen endotracheal tube is confirmed by bronchoscopy and the right lung is isolated.



**Figure 11.** A Heineke-Mikulicz pyloroplasty is performed by closing the defect transversely. Sutures are alternated between the “upper” and “lower” lateral aspects of the defect to ensure an even closure.

### *Port placement*

Thoracic port placement is shown in [Figure 12](#). Although rarely utilized, a standard thoracotomy incision is marked on the patient if emergent conversion to open is required [[Figure 12](#)]. We prefer to enter the chest with an 8 mm robotic optical separator in approximately the 3rd or 4th intercostal space in the posterior axillary line (arm 4). Pneumothorax is established with CO<sub>2</sub> insufflation and additional ports are placed in this line in approximately the 8th or 9th space above the diaphragmatic insertion (arm 2) and approximately the 5th or 6th intercostal space (arm 3). An additional 8 mm port (arm 1) is placed at the “dome” or apex of the right lateral chest approximately “over” the right crural pillar in approximately the 9th or 10th intercostal space. The bedside assistant/robotic stapling port is a 12 mm robotic port with a 5-8 mm cap and is inserted halfway between the inferior two robotic ports at the insertion of the diaphragm.

### *Docking*

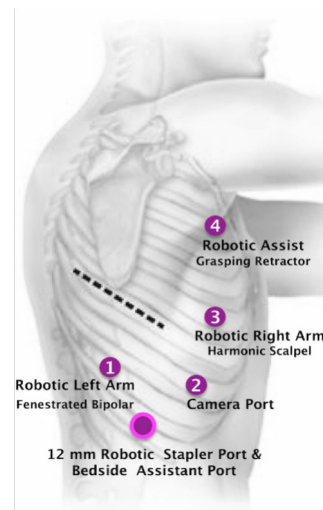
The da Vinci Xi robotic side cart is brought in from the patient’s right at the level of the shoulders and the camera port is docked to arm 2. The azygous vein is targeted, the remaining arms are docked, the instruments are inserted, and patient clearance is optimized. A Force Bipolar Grasper is initially inserted into arm 1 (robotic left hand), an ultrasonic shear is inserted into arm 3 (robotic right hand), and a small grasping retractor is inserted into arm 4 (robotic assist). The bedside assistant utilizes a suction device.

### *Subcarinal dissection*

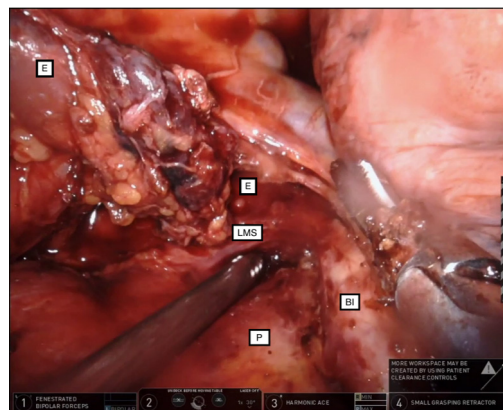
The right lower lobe posterior basilar edge is retracted superiorly with the robotic assist arm and the inferior pulmonary ligament is divided to expose the inferior pulmonary vein. An intracorporeal rolled gauze “cigar” is inserted in the chest and is grasped by the robotic assist arm for anterior lung retraction. The pleura over the posterior hilum is incised along the pericardium to expose the bronchus intermedius. Dissection along the inferior edge of the airway continues to the carina, onto the posterior aspect of the trachea, and again distal onto the left mainstem bronchus. This sequence ensures clear and confident exposure of the left mainstem bronchus (the most common site of injury to the airway) and subsequent safe exenteration of all nodal tissue from the bronchi, left pleura, and pericardium [[Figure 13](#)]. Care must be taken to avoid thermal injury to the posterior membranous airway, especially during minimally invasive esophageal resections<sup>[29]</sup>.

### *Posterior dissection*

The pleura overlying the posterior esophagus is incised starting at the inferior edge of the azygous vein and



**Figure 12.** Port location for the thorax. The dashed line represents the standard thoracotomy incision. This figure is quoted with permission from Ekeke et al.<sup>[27]</sup>.

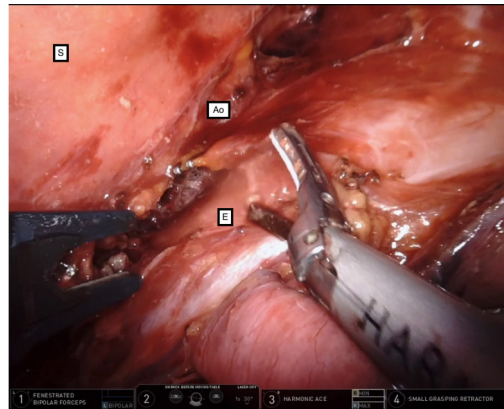


**Figure 13.** The subcarinal lymphadenectomy includes all nodal tissue between the bronchi, left pleura, and pericardium. Note the dissected lymph node packet swept up with the esophagus. LMS: Left mainstem bronchus; BI: bronchus intermedius; P: pericardium; E: esophagus.

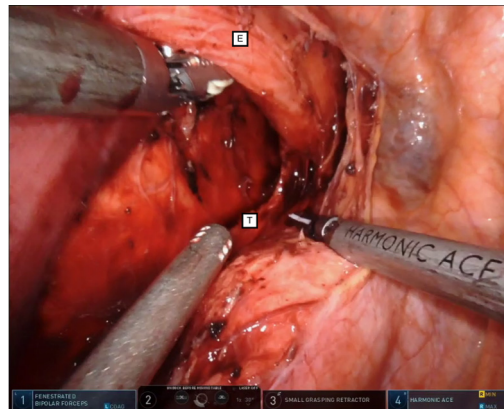
extending to the hiatus. The pleura overlying the right diaphragmatic crural pillar is incised to meet the prior dissection along the pericardium, and the low paraesophageal lymph nodes along the diaphragm are reflected with the specimen. The pleura overlying the esophagus is grasped with the robotic assist arm and the esophagus is reflected anteriorly. The posterior esophagus is mobilized along the spine and aorta from the hiatus to the azygous with the bedside assistant placing clips on any tissue potentially containing branches of the thoracic duct, or the duct itself [Figure 14]. The pleura overlying the azygous vein is incised, and the vein divided with a robotic vascular staple load.

#### *Proximal esophageal dissection*

Above the level of the azygous vein, the dissection shifts to “hug” the esophagus [Figure 15]. The right vagus nerve is divided at the level of the azygous to avoid traction injury to the recurrent laryngeal nerve during the remaining dissection. The esophagus is circumferentially mobilized to the level of the thoracic inlet (if needed) to provide adequate mobility for the esophagogastric anastomosis.



**Figure 14.** The posterior esophagus is mobilized along the spine while clipping any tissue potentially containing the thoracic duct or one of its branches. The robot assist (arm 4) can provide medial retraction on the esophagus away from the aorta. S: Spine; Ao: aorta; E: esophagus.



**Figure 15.** Circumferential dissection proximal to the azygous vein “hugs” the esophagus. E: Esophagus; T: trachea.

#### *Completion of esophageal dissection*

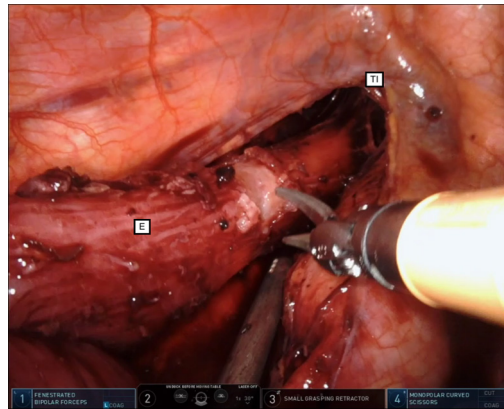
With the robotic assist (arm 4) elevating the esophagus, the esophagus is mobilized from the left pleura along its length to complete the circumferential esophageal mobilization with en bloc lymphadenectomy. The esophagus is divided with either a scissor or ultrasonic shears at a level appropriate for a sound oncologic margin. This may be as high as the thoracic inlet, but generally 2-3 cm proximal to the azygous vein for lower esophageal tumors [Figure 16]. The proximal stomach and the gastric conduit are pulled into the chest and the tacking suture is removed. The proximal conduit is temporarily sutured to the diaphragm to prevent retraction back into the abdomen.

#### *Specimen removal and conduit preparation*

The posterior robotic arm 1 is undocked and the port is removed. The incision is extended to approximately 4 cm and a small wound protector is inserted. Alternatively, a specimen retrieval bag can be inserted through the 12 mm bedside assist port, and the incision upsized on retrieval. The specimen is sent for frozen pathologic analysis of margins, which should be confirmed as benign prior to reconstruction.

#### *Anastomosis*

We utilize an extra-long circular end-to-end anastomotic (EEA) 28 mm stapler (DST XL 28mm EEA,



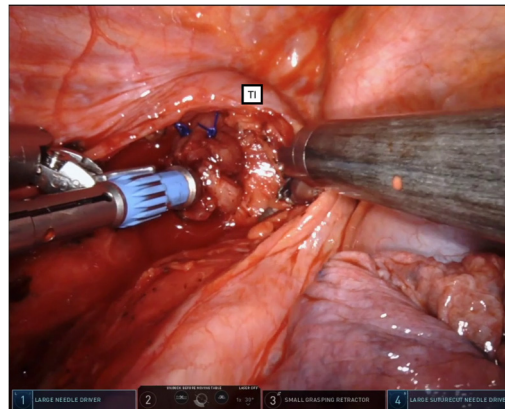
**Figure 16.** The esophagus is divided at a level appropriate for a sound oncologic margin, but no lower than the level of the azygous vein. Shown is division high in the chest at approximately the level of the thoracic inlet. E: Esophagus; TI: thoracic inlet.

Covidien, USA) to create an end-to-side (functional end-to-end) esophagogastrostomy. Regardless of the technique, the goal is to create a well-perfused, tension-free, properly oriented, pneumostatic, full-thickness anastomosis. The conduit needs to be of adequate length to avoid anastomotic tension, yet short enough to lay straight without redundancy. The redundant tip of the conduit is frequently ischemic or damaged from manipulation and is resected. The anastomotic site should be chosen at a location of healthy appearing conduit either by gross visualization or with the aid of indocyanine green near-infrared fluorescence imaging available on the robotic platform (Firefly, Intuitive Surgical, Sunnyvale, CA)<sup>[30]</sup>. It is generally feasible to create the anastomosis just proximal to the site of the gastroepiploic vascular arcade termination.

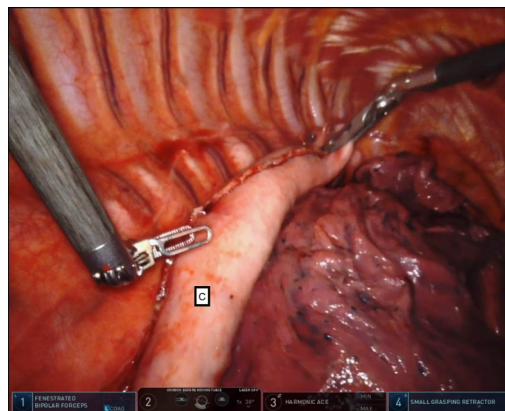
To create an EEA stapled anastomosis, the stapler anvil is inserted into the chest through the anterior aspect of the access incision. The Force Bipolar is placed in the robotic left arm 1 and a large self-cutting needle driver (Large Suture Cut Needle Driver, Intuitive Surgical, Sunnyvale, CA) is placed in the robotic right arm 3. A running baseball stitch with 2-0 non-absorbable monofilament suture is placed. Care should be taken to ensure that each suture bite is full-thickness containing the mucosa, but not excessively deep (2-3 mm bites). Grasping only the plastic portion of the anvil with the large Suture Cut needle driver, while the assist arm 4 and left arm 1 gently splay open the esophageal lumen, the anvil is inserted into the esophagus. The suture is tied down to secure the anvil. A second purse-string suture is placed for reinforcement and “tucking” of redundant tissue folds [Figure 17].

The suture securing the conduit to the diaphragm is cut and the conduit is gently grasped at the tip and retracted cranially. Simultaneous and gentle lateral “lifting” of the conduit at the hiatus can facilitate ease of passage of tubularized stomach and omentum through the hiatus. Grasping of the conduit itself should be avoided when possible to minimize damage to the serosa and/or microvasculature. Proper orientation of the conduit is maintained with the staple line facing approximately towards the lateral chest, and the vascular arcade facing medially towards the mediastinum [Figure 18]. The conduit should be brought into the chest until the previously placed marking suture on the staple line is visible.

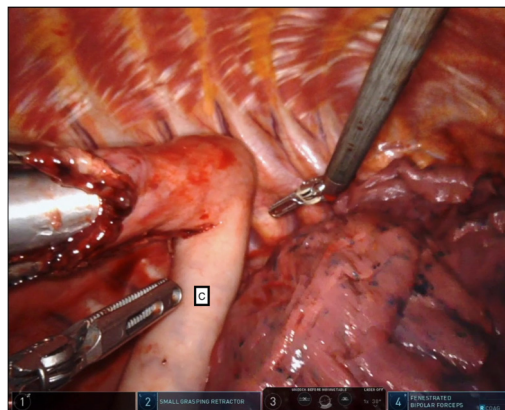
A gastrotomy is created at the apex of the conduit parallel to the staple line, large enough to insert the EEA stapler. The robotic left arm and port are removed, the conduit is oriented toward the access incision, and the conduit lumen is irrigated with antibiotic-infused saline. The EEA stapler is inserted through the anterior portion of the access incision along with a laparoscopic grasper and the stapler is passed into the conduit [Figure 19]. The conduit and stapler are brought together into the upper chest and the spike is



**Figure 17.** The EEA anvil is inserted into the esophagus and secured with an inner baseball stitch and an outer purse-string stitch. TI: Thoracic inlet.

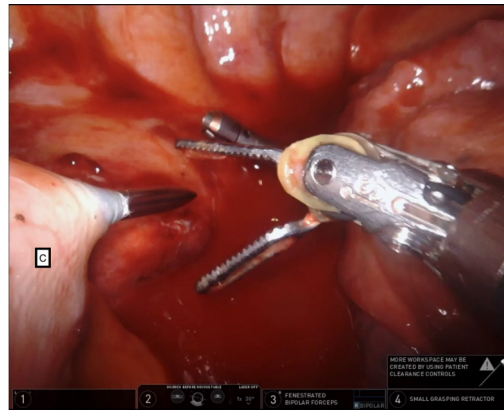


**Figure 18.** The conduit is advanced cranially with minimal grasping of the conduit. C: Conduit.

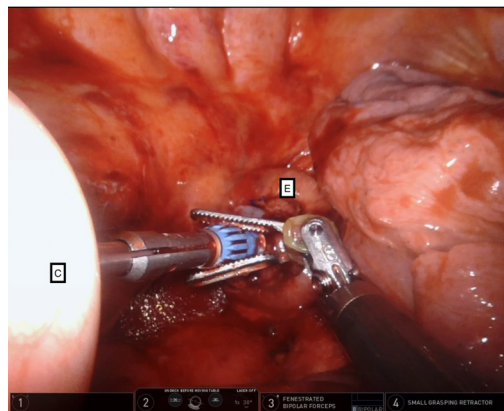


**Figure 19.** The end-to-end anastomotic stapler is inserted into the chest and passed into the conduit. Careful attention to the proper orientation of the conduit is critical at all times to avoid twisting, torsion, and obstruction. C: Conduit.

deployed through the greater curve of the conduit, ideally at the level of the proximal gastroepiploic arcade [Figure 20]. The spike is docked into the anvil and the stapler is fired [Figure 21]. The anastomotic rings are inspected for completeness and sent to pathology. The robotic left arm (arm 1) is port-hopped to the 12 mm



**Figure 20.** The end-to-end anastomotic spike is deployed through the greater curve of the conduit, ideally at the level of the proximal gastroepiploic arcade. C: Conduit.



**Figure 21.** The end-to-end anastomotic spike is docked into its anvil. The stapler is gently approximated, closed, and fired to complete the anastomosis. C: Conduit; E: esophagus.

port to allow for use of the robotic stapler. The proximal tip of the conduit is amputated using a robotic stapler load with care to leave some tissue distance between the new staple line and the circular anastomosis to avoid undue tissue ischemia [Figure 22].

#### *Endoscopy, drains, and flaps*

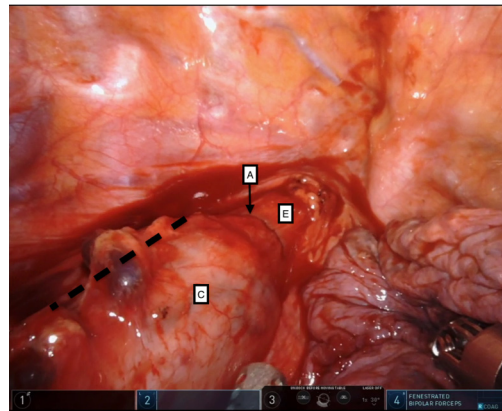
After the anastomosis is completed, intraoperative endoscopy may be performed under thoracoscopic visualization with the chest filled with irrigation to assess for conduit integrity and leak. A nasogastric tube is passed under thoracoscopic visualization before endoscope removal.

If a pedicled omental flap was created (not shown), it is interposed between the anastomosis and the airway, and wrapped around the anastomosis. A 10 mm flat Jackson-Pratt drain (Cardinal Health, Dublin, OH) is placed adjacent and posterior to the anastomosis between the conduit and spine. A 28-French chest tube is placed in the posterior chest and directed towards the apex.

## TECHNICAL CONSIDERATIONS

In addition to understanding the sequence of the procedure, some elements of the technique require discussion.





**Figure 22.** The proximal tip of the conduit is amputated using robotic stapler loads. Although not directly visible in this figure, the dashed line represents the approximate location of the stapled proximal conduit. Note distance (approximately 2 cm) maintained between the anastomotic and conduit staple lines to avoid undue tissue ischemia. A: Anastomosis; C: conduit; E: esophagus.

### Benign disease

When operating for a benign indication, the overall conduct of the operation is similar. The major difference is the omission of an aggressive lymphadenectomy. Dissection should stay close to the esophagus for the entire thoracic portion to minimize risk to surrounding structures including the airway and thoracic duct. The conduit length is much more flexible without the need for oncologic margins and can extend further along the fundus. The site of transection of the native esophagus is also flexible, but it should be located at or higher than the level of the azygous vein to avoid excessive reflux. The underlying esophageal pathology may also dictate the level of transection to avoid leaving an excessive nonfunctional esophageal segment in situ.

### Learning curve

Although the robotic Ivor Lewis esophagectomy is conceptually similar to a standard minimally invasive Ivor Lewis esophagectomy, it requires the mastery of additional skill sets. Some robotic skills are not directly transferable from prior experience with open or laparoscopic/thoracoscopic surgeries<sup>[31]</sup> and require dedicated training. The time to proficiency varies on an individual basis but has been reported between 20<sup>[32]</sup> to 70<sup>[33]</sup> cases. The initial experience with 100 consecutive cases performed by a single team of two surgeons at Memorial Sloan Kettering Cancer Center identified significantly decreased operative times and surgical complications after approximately 45 cases<sup>[34]</sup>.

Highlighting the importance of mentorship, surgeons at the University of Utrecht in the Netherlands reduced their time to proficiency by 66% using a structured proctoring program in an established robotic practice<sup>[33]</sup>. Conversely, the learning curve for an operation time was not affected when an experienced RAMIE surgeon joined an experienced non-robotic minimally invasive thoracic surgical practice, suggesting the presence of an institutional learning curve in addition to a personal learning curve<sup>[35]</sup>.

### CONCLUSION

As esophageal surgery continues to remain clinically relevant, advances in technology will increasingly evolve the field. Although a relative newcomer to the repertoire of the esophageal surgeon's toolbox, RAMIE is readily establishing itself as a safe and effective approach to esophagectomy<sup>[36-38]</sup>. With the expected ongoing development and growing sophistication of robotic platforms, the current and immediate future represents an exciting era in esophageal surgery.

## DECLARATIONS

### Acknowledgments

The authors would like to acknowledge Mrs. Kathy Lovas for her expert editorial assistance.

### Authors' contributions

Made substantial contributions to conception and design of the study and performed data analysis and interpretation, and acquisition: Ackerman JM, Sarkaria IS

Provided administrative, technical, and material support: Sarkaria IS, Luketich JD

### Availability of data and materials

Not applicable.

### Financial support and sponsorship

None.

### Conflicts of interest

Inderpal S. Sarkaria, MD, has received honoraria for consulting and speaking for Intuitive Surgical. James D. Luketich, MD discloses the following: Consultant: Medtronic; CE Speaker's Bureau: Covidien; Stockholder: Intuitive Surgical, Inc., Cigna Corp., and Proctor & Gamble. Dr. Ackerman has no conflicts of interest.

### Ethical approval and consent to participate

Not applicable.

### Consent for publication

Patients provided consent for teaching purposes and publication of operative images.

### Copyright

© The Author(s) 2021.

## REFERENCES

1. Bray F, Ferlay J, Soerjomataram I, Siegel RL, Torre LA, Jemal A. Global cancer statistics 2018: GLOBOCAN estimates of incidence and mortality worldwide for 36 cancers in 185 countries. *CA Cancer J Clin* 2018;68:394-424. [DOI](#) [PubMed](#)
2. Luketich JD, Pennathur A, Awais O, et al. Outcomes after minimally invasive esophagectomy: review of over 1000 patients. *Ann Surg* 2012;256:95-103. [DOI](#) [PubMed](#)
3. Torek F. The first successful resection of the thoracic portion of the esophagus for carcinoma. *JAMA* 1913;60:1533. [DOI](#)
4. Birkmeyer JD, Siewers AE, Finlayson EV, et al. Hospital volume and surgical mortality in the United States. *N Engl J Med* 2002;346:1128-37. [DOI](#) [PubMed](#)
5. Lee RB, Miller JI. Esophagectomy for cancer. *Surg Clin North Am* 1997;77:1169-96. [DOI](#) [PubMed](#)
6. Cuschieri A, Shimi S, Banting S. Endoscopic oesophagectomy through a right thorascopic approach. *J R Coll Surg Edinb* 1992;37:7-11. [PubMed](#)
7. Dallemagne B, Weerts JM, Jehaes C, et al. Case report: Subtotal oesophagectomy by thoracoscopy and laparoscopy. *Minimally Invasive Therapy* 1992;1:183-5. [DOI](#)
8. DePaula AL, Hashiba K, Ferreira EA, de Paula RA, Grecco E. Laparoscopic transhiatal esophagectomy with esophagogastroplasty. *Surg Laparosc Endosc* 1995;5:1-5. [PubMed](#)
9. Luketich JD, Pennathur A, Franchetti Y, et al. Minimally invasive esophagectomy: results of a prospective phase II multicenter trial-the eastern cooperative oncology group (E2202) study. *Ann Surg* 2015;261:702-7. [DOI](#) [PubMed](#)
10. Horgan S, Berger RA, Elli EF, Espat NJ. Robotic-assisted minimally invasive transhiatal esophagectomy. *Am Surg* 2003;69:624-6. [PubMed](#)
11. Sarkaria IS, Rizk NP, Goldman DA, et al. Early quality of life outcomes after robotic-assisted minimally invasive and open Esophagectomy. *Ann Thorac Surg* 2019;108:920-928. [PubMed](#)
12. van der Sluis PC, van der Horst S, May AM, et al. Robot-assisted minimally invasive thoracoscopic esophagectomy versus open transthoracic esophagectomy for resectable esophageal cancer: a randomized controlled trial. *Ann Surg* 2019;269:621-30. [DOI](#) [PubMed](#)

13. Vimolratana M, Sarkaria IS, Goldman DA, et al. Two-year quality of life outcomes after robotic-assisted minimally invasive and open esophagectomy. *Ann Thorac Surg* ;2020:S0003-4975(20)31832. DOI PubMed
14. Zhang Y, Han Y, Gan Q, et al. Early outcomes of robot-assisted versus thoracoscopic-assisted Ivor Lewis esophagectomy for esophageal cancer: a propensity score-matched study. *Ann Surg Oncol* 2019;26:1284-91. DOI PubMed
15. Bailey SH, Bull DA, Harpole DH, et al. Outcomes after esophagectomy: a ten-year prospective cohort. *Ann Thorac Surg* 2003;75:217-22; discussion 222. DOI PubMed
16. Raymond DP, Seder CW, Wright CD, et al. Predictors of major morbidity or mortality after resection for esophageal cancer: a Society of Thoracic Surgeons general thoracic surgery database risk adjustment model. *Ann Thorac Surg* 2016;102:207-14. DOI PubMed
17. Reeh M, Metze J, Uzunoglu FG, et al. The PER (preoperative esophagectomy risk) score: a simple risk score to predict short-term and long-term outcome in patients with surgically treated esophageal cancer. *Medicine (Baltimore)* 2016;95:e2724. DOI PubMed
18. Varley PR, Borrebach JD, Arya S, et al. Clinical utility of the Risk Analysis Index as a prospective frailty screening tool within a multi-practice, multi-hospital integrated healthcare system. *Ann Surg* 2020. DOI PubMed
19. Rice TW, Patil DT, Blackstone EH. 8th edition AJCC/UICC staging of cancers of the esophagus and esophagogastric junction: application to clinical practice. *Ann Cardiothorac Surg* 2017;6:119-30. DOI PubMed
20. Shah MA, Kennedy EB, Catenacci DV, et al. Treatment of locally advanced esophageal carcinoma: ASCO Guideline. *J Clin Oncol* 2020;38:2677-94. DOI PubMed
21. Madenci AL, Reames BN, Chang AC, Lin J, Orringer MB, Reddy RM. Factors associated with rapid progression to esophagectomy for benign disease. *J Am Coll Surg* 2013;217:889-95. DOI PubMed
22. Luketich JD, Nguyen NT, Weigel T, Ferson P, Keenan R, Schauer P. Minimally invasive approach to esophagectomy. *JSLS* 1998;2:243-7. PubMed
23. Nguyen NT, Schauer PR, Luketich JD. Combined laparoscopic and thoracoscopic approach to esophagectomy. *J Am Coll Surg* 1999;188:328-32. DOI PubMed
24. Luketich JD, Schauer PR, Christie NA, et al. Minimally invasive esophagectomy. *Ann Thorac Surg* 2000;70:906-11; discussion 911. DOI PubMed
25. Sarkaria IS, Rizk NP. Robotic-assisted minimally invasive esophagectomy: the Ivor Lewis approach. *Thorac Surg Clin* 2014;24:211-22, vii. DOI PubMed
26. Bratzler DW, Dellinger EP, Olsen KM, et al. Clinical practice guidelines for antimicrobial prophylaxis in surgery. *Surg Infect (Larchmt)* 2013;14:73-156. DOI PubMed
27. Ekeke CN, Luketich JD, Sarkaria IS. Robotic-assisted minimally invasive esophagectomy. *Ann Esophagus* 2021;4:7. DOI
28. Carroll PA, Yeung JC, Darling GE. Elimination of routine feeding jejunostomy after esophagectomy. *Ann Thorac Surg* 2020;110:1706-13. DOI PubMed
29. Sarkaria IS, Rizk NP, Finley DJ, et al. Combined thoracoscopic and laparoscopic robotic-assisted minimally invasive esophagectomy using a four-arm platform: experience, technique and cautions during early procedure development. *Eur J Cardiothorac Surg* 2013;43:e107-15. DOI PubMed
30. Sarkaria IS, Bains MS, Finley DJ, et al. Intraoperative near-infrared fluorescence imaging as an adjunct to robotic-assisted minimally invasive esophagectomy. *Innovations (Phila)* 2014;9:391-3. DOI PubMed
31. Kowalewski KF, Schmidt MW, Proctor T, et al. Skills in minimally invasive and open surgery show limited transferability to robotic surgery: results from a prospective study. *Surg Endosc* 2018;32:1656-67. DOI PubMed
32. Hernandez JM, Dimou F, Weber J, et al. Defining the learning curve for robotic-assisted esophagogastrectomy. *J Gastrointest Surg* 2013;17:1346-51. DOI PubMed
33. der Sluis PC, Ruurda JP, van der Horst S, Goense L, van Hillegersberg R. Learning curve for robot-assisted minimally invasive thoracoscopic esophagectomy: results from 312 Cases. *Ann Thorac Surg* 2018;106:264-71. DOI PubMed
34. Sarkaria IS, Rizk NP, Grosser R, et al. Attaining proficiency in robotic-assisted minimally invasive esophagectomy while maximizing safety during procedure development. *Innovations (Phila)* 2016;11:268-73. DOI PubMed
35. Okusanya OT, Sarkaria IS, Hess NR, et al. Robotic assisted minimally invasive esophagectomy (RAMIE): the University of Pittsburgh Medical Center initial experience. *Ann Cardiothorac Surg* 2017;6:179-85. DOI PubMed
36. Witek TD, Melvin TJ, Luketich JD, Sarkaria IS. Open, minimally invasive, and robotic approaches for esophagectomy: What is the approach algorithm? *Thorac Surg Clin* 2020;30:269-77. DOI PubMed
37. Kingma BF, Grimminger PP, van der Sluis PC, et al. Worldwide techniques and outcomes in robot-assisted minimally invasive esophagectomy (RAMIE): Results from the Multicenter International Registry. *Ann Surg* 2020. DOI PubMed
38. Meredith K, Huston J, Andacoglu O, Shridhar R. Safety and feasibility of robotic-assisted Ivor-Lewis esophagectomy. *Dis Esophagus* 2018;31. DOI PubMed