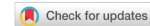

Case Report

Open Access



Nivolumab-induced severe bullous pemphigoid in a patient with renal cancer: a case report and literature review

Xiaorong Wu, Sreekanth Palvai, Awais Jalil

Department of Medical Oncology, Southend University Hospital NHS Foundation Trust, Prittlewell Chase, Westcliff-on-Sea, Essex SSO 0RY, United Kingdom.

Correspondence to: Dr. Xiaorong Wu, Department of Medical Oncology, Southend University Hospital NHS Foundation Trust, Prittlewell Chase, Westcliff-on-Sea, Essex SSO 0RY, United Kingdom. E-mail: Xiaorong.wu@nhs.net

How to cite this article: Wu X, Palvai S, Jalil A. Nivolumab-induced severe bullous pemphigoid in a patient with renal cancer: a case report and literature review. *J Cancer Metastasis Treat* 2020;6:40. <http://dx.doi.org/10.20517/2394-4722.2020.77>

Received: 30 Jul 2020 **Accepted:** 23 Oct 2020 **Published:** 29 Oct 2020

Academic Editor: Godefridus J. Peters **Copy Editor:** Cai-Hong Wang **Production Editor:** Jing Yu

Abstract

With the widespread use of immunotherapy in numerous solid tumours, immunotherapy-related adverse events (irAEs) have started to emerge and bring new challenges for clinicians to manage. Among established irAEs, dermatologic toxicity is one of the most common toxicities; it is often mild but can be severe and potentially life-threatening, such as bullous pemphigoid. Here, we report a case of nivolumab-mediated severe, extensive, refractory bullous pemphigoid involving both skin and oral mucosa in a patient with metastatic renal cancer. We also summarise a list of selected case reports of immunotherapy-induced bullous pemphigoid by literature review. We highlight various presentations, investigations and managements of this type of skin irAEs. Meantime, we would like to discuss the correlation of skin irAEs incidence rate with immunotherapy drug benefit and resistance.

Keywords: Bullous pemphigoid, mucous membrane pemphigoid, immunotherapy, dermatologic toxicity, nivolumab

INTRODUCTION

Immunotherapy, such as anti-programmeddeath-1 (PD-1)/programmed death ligand 1 (PD-L1) antibody or anti-CTLA 4 antibody or combination, has significantly improved survival of patients with various malignancies. However, immunotherapy-related adverse events (irAEs) have started to emerge and bring new challenges for oncologists to manage. Among the known irAEs, dermatologic toxicity is one of the



© The Author(s) 2020. **Open Access** This article is licensed under a Creative Commons Attribution 4.0 International License (<https://creativecommons.org/licenses/by/4.0/>), which permits unrestricted use, sharing, adaptation, distribution and reproduction in any medium or format, for any purpose, even commercially, as long as you give appropriate credit to the original author(s) and the source, provide a link to the Creative Commons license, and indicate if changes were made.



most common toxicities^[1]. Most immunotherapy-induced cutaneous toxicities are mild, such as non-specific rashes or pruritus. However, some manifestations of skin irAEs can progress to high-grade and potentially life-threatening situations, such as bullous pemphigoid (BP)^[2]. Since 2015, more than 40 cases of immunotherapy-induced BP have been reported with the majority involving either the skin or mucous membrane only. Presentations of both cutaneous and oral mucous BP are rare (less than seven cases).

Here, we report a severe, extensive (involving both skin and oral mucosa), refractory case of BP that occurred 9 months after initiation of nivolumab in a patient with metastatic renal clear cell cancer. We also summarise a list of selected case reports of checkpoint inhibitor-induced BP by literature review. We highlight various presentations, investigations and management approaches of immunotherapy-induced BP. Meantime, we would like to discuss the correlation of skin irAE incidence rate with immunotherapy drug benefit and resistance.

CASE REPORT

A 66-year-old gentleman with no known history of autoimmune disease was diagnosed with right clear renal cancer in 2014. He was initially treated with radical nephrectomy with excision of tumour thrombus in the renal vein and retro-hepatic inferior vena cava. In March 2017, his cancer relapsed with a single spinal metastasis, which was treated with excision of the intradural tumour and laminectomy and radiotherapy as well, which resulted in complete neurological recovery. Post-radiotherapy, he opted for active tyrosine kinase inhibitor, sunitinib, in light of relapsed renal cancer in his spine. In October 2017, sunitinib was discontinued due to spontaneous haematoma in his right calf and thigh, which was likely due to combination of sunitinib and low-molecular-weight heparin (LMWH) for his atrial fibrillation. He then had a long period of surveillance, during which he gradually developed asymptomatic relapsed metastatic renal cancer in his left adrenal gland, followed by relapsed cancer in his left kidney. In March 2019, he commenced immunotherapy infusion with 2 weekly nivolumab, considering further disease progression with multiple lung metastatic disease. His other medical history was only atrial fibrillation, for which he was on LMWH and bisoprolol.

From August 2019, five months post-initiation of nivolumab, he developed a mild pruritic erythematous skin rash scattered mainly over his chest and upper limbs. At that time, there were no blisters reported. He continued nivolumab with the rash controlled mainly by topical steroids or short courses of oral steroids. In November 2019, he developed large, tense, haemorrhagic blisters, which were exacerbated following a 3-week holiday in Australia, leading to an emergency hospital admission. On clinical examination, he had a severe widespread bullous eruption affecting his chest, abdomen, inner thighs and upper arms. Active blisters and erosions were seen on the roof of his mouth and scrotal skin as well. Some blisters had burst leaving severely eroded skin with signs of superimposed infection. Bullae at various stages were seen, including intact ones, burst ones with an eroded base, and a few areas of early re-epithelialisation as [Figure 1](#). He had no involvement of the scalp region and external eye examination was normal.

An incisional skin biopsy from an active blister with haematoxylin and eosin examination revealed epidermal hyperplasia and subepidermal splitting. There were few eosinophils, scattered plasma cells and neutrophils with a subjacent chronic inflammation. Direct immunofluorescence (DIF) showed clearly positive staining for IgG in the basement membrane zone, and a faint positive IgA staining. Subsequent serum antibody analysis confirmed positive pemphigoid antibodies consistent with BP see [Figures 2 and 3](#).

The patient was started immediately on intravenous methylprednisolone 1 mg/kg as well as flucloxacillin for 4 days and then switched to oral prednisolone and flucloxacillin when no new blisters developed. Most of the blisters gradually re-epithelialised within 4-6 weeks of oral steroids. Two months later, the corticosteroid treatment was tapered. However, the blisters reappeared when prednisolone was stepped

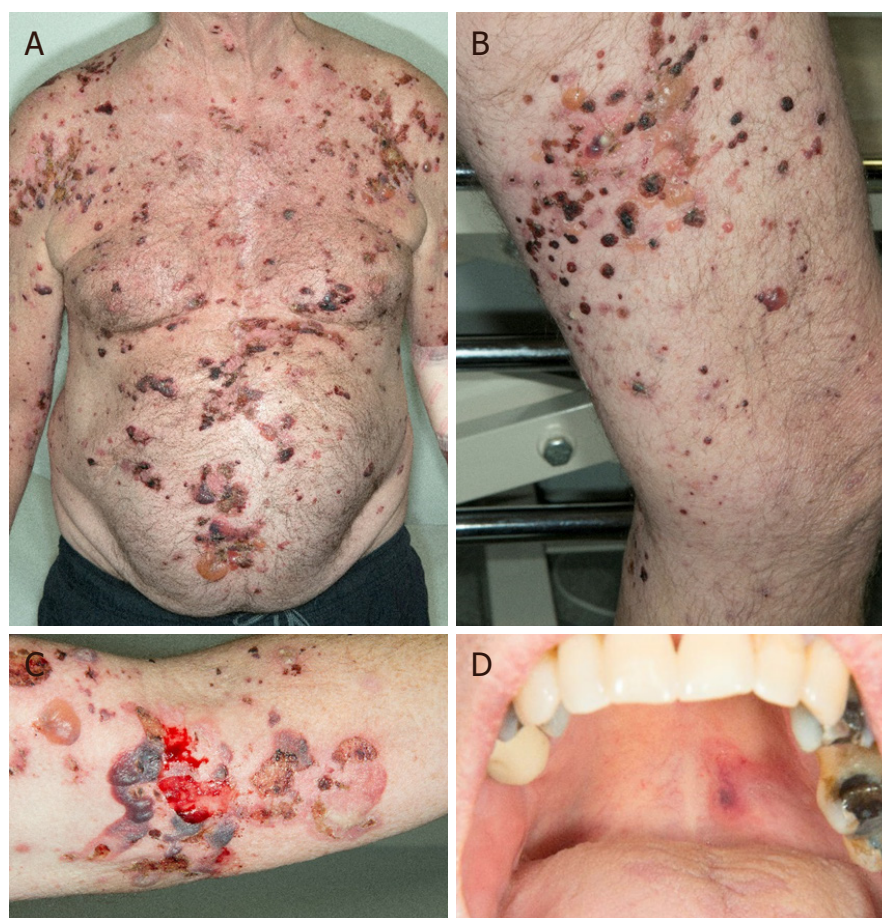

Figure 1. Clinical presentations. Multiple, grouped, large, tense haemorrhagic blisters were seen on the first clinical presentation, which affected the chest, abdomen, inner thighs and upper arms (A, B and C); active blisters and erosions were seen on the roof of the mouth (D)

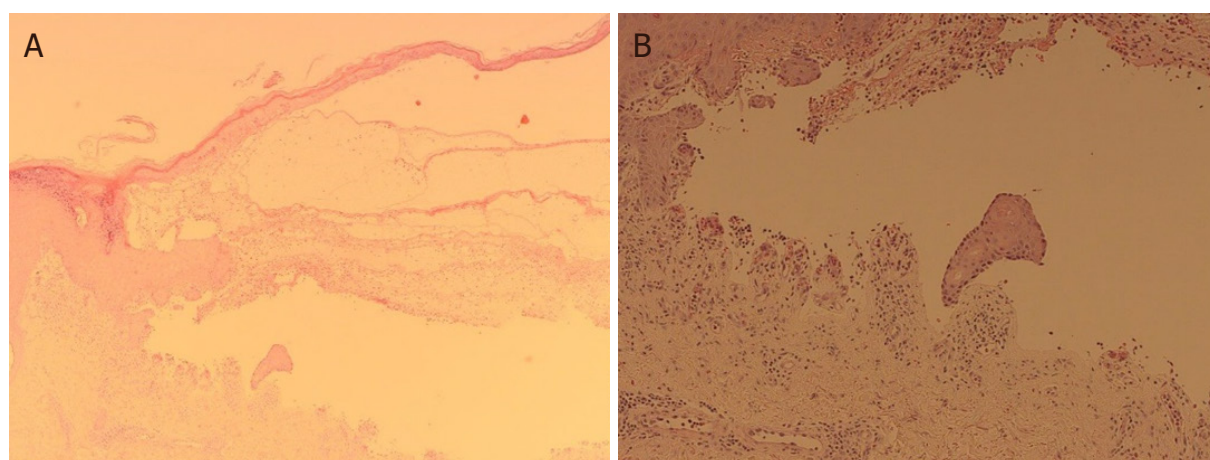


Figure 2. Haematoxylin and eosin staining of edge (A) and base (B) of blisters. Epidermal hyperplasia and subepidermal splitting were seen with few eosinophils, scattered plasma cells, neutrophils and a subjacent chronic inflammation

down to 10 mg per day, requiring re-introduction of high-dose prednisolone. Consequently, nivolumab had been permanently discontinued in view of refractory BP and further disease progression in his adrenal metastatic disease.

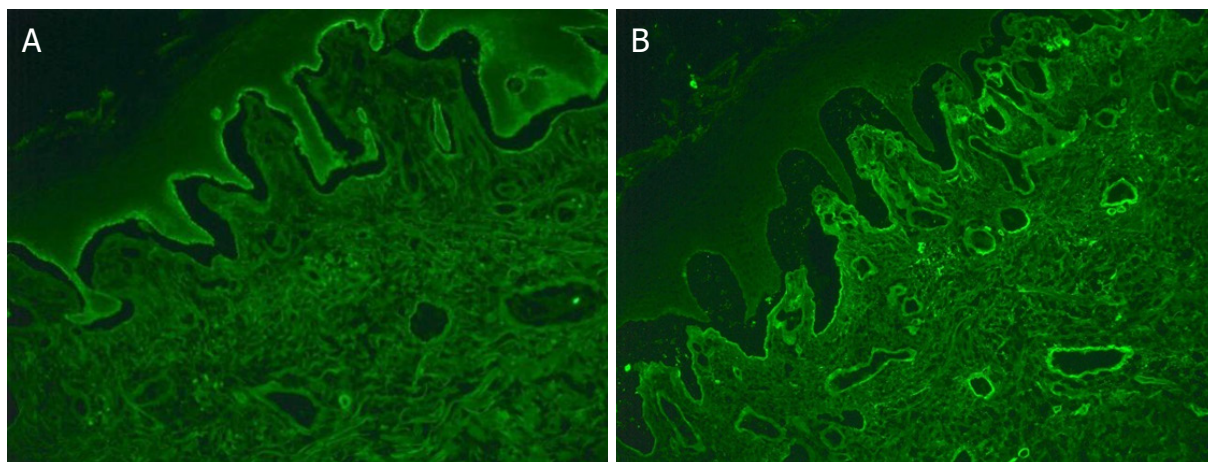


Figure 3. Direct immunofluorescence showed clearly positive staining for IgG in the basement membrane zone (A), and a faint positive IgA staining (B)

DISCUSSION

BP is an autoimmune blistering disorder that is caused by autoantibodies against hemidesmosomal protein BP180 and BP230 at the skin basement membrane^[1]. The causes of BP in oncologic patients could be idiopathic, paraneoplastic^[2,3], secondary to cancer therapy or related to another medication. With the widespread use of immunotherapy in cancer management, BP has become a well-established cutaneous toxicity associated with immunotherapy. The cause of BP in our case is most likely nivolumab, as the patient denied a history of BP, and as his other medications were generally tolerated for years. The timing of his renal cancer diagnosis (5 years prior) and nivolumab initiation (9 months prior) makes the paraneoplastic phenomenon highly unlikely.

Here, we summarise a list of selected case reports of immunotherapy induced BP by literature review in [Table 1](#). Most reported immunotherapy-induced BP involving either skin or mucous membrane only [Table 1](#); combination of cutaneous BP and mucous membrane pemphigoid (MMP) is rare^[4]. Cutaneous BP typically presents with pruritic blisters that arise on erythematous or urticarial plaques. Gradually, the bullous lesion can erode and leave haemorrhagic crust^[5]. MMP usually presents with oral erosions, blistering or desquamative gingivitis, which are associated with significant morbidity and severe complications, such as tissue destruction, fibrosis and loss of function (e.g., laryngeal stenosis). In addition, MMP could be initially indistinguishable from a gingivitis due to poor oral hygiene practices^[6]. Thus, oncologists should be aware of cutaneous BP and MMP in all patients who have been treated with immunotherapy.

Onset of BP post-initiation of immunotherapy varies from weeks to several months [[Table 1](#)]. Previous evidence showed that the median number of weeks of immunotherapy prior to onset of BP was 17 (range of 3 to 91)^[7]. However, delayed cases have been reported, even several months after discontinuation of immunotherapy^[8,9].

Diagnostic workup usually includes skin biopsy for histology and immunofluorescence staining. Histopathology normally shows subepidermal clefting with an eosinophilic inflammatory infiltration^[10]. DIF characteristically shows linear deposits of IgG and/or C3 along the epidermal basement membrane zone. Indirect immunofluorescence (IIF) or enzyme-linked immunosorbent assays will confirm the deposit of autoantibodies specific for BP230 (also known as BPAG1) and/or BP180 (also known as BPAG2; collagen XVII)^[6,11]. Several cases have been reported with raised serum anti-BP180 associated with immunotherapy-induced BP as well^[12]. Interestingly, in one case, it was demonstrated that immunotherapy-induced BP

Table 1. Selected reported cases of immunotherapy-induced bullous pemphigoid

Case number	Immunotherapy	Primary tumour	Clinical presentation	Time to develop BP (weeks)	Treatment	Ref.
1	Pembrolizumab	Melanoma	Cutaneous BP	22	Oral steroids	[27]
2	Nivolumab	Tongue SCC	Oral and cutaneous BP	8	Topical/oral steroids	[9]
3	Pembrolizumab	Melanoma	Cutaneous BP	16	Topical/oral steroids	[9]
4	Nivolumab	Urothelial Ca.	Cutaneous BP	18	IV/oral steroids	[9]
5	Nivolumab	NSCLC	Cutaneous BP	6	Oral and topical steroids and nicotinamide	[9]
6	Nivolumab	Melanoma	Cutaneous BP	3	IV/oral steroids	[9]
7	Pembrolizumab	Melanoma	Severe BP exacerbation		Oral steroids	[28]
8	Nivolumab	Lung cancer	Cutaneous BP	6	Oral steroids and omalizumab	[29]
9	Pembrolizumab	Melanoma	Cutaneous BP	84	Topical and oral steroids	[30]
10	Ipilimumab then nivolumab	Melanoma	Cutaneous BP	24	Topical and oral steroids	[23]
11	Durvalumab then nivolumab	Melanoma	Cutaneous BP	52	Topical steroids	[23]
12	Nivolumab	SCC of lung	Cutaneous BP	18	Oral and topical steroids	[23]
13	Pembrolizumab after ipilimumab	Melanoma	Cutaneous BP	32	Oral and topical steroids	[31]
14	Pembrolizumab	Melanoma	Oral and cutaneous BP	78	Topical steroid	[32]
15	Pembrolizumab	Melanoma	Oral and cutaneous BP	18	Oral steroid and methotrexate	[32]
16	Pembrolizumab	Melanoma	Recurrent BP		Oral steroid	[32]
17	Pembrolizumab then nivolumab	Melanoma	Localised BP		Monitoring	[33]
18	Nivolumab	Lung	Oral and cutaneous BP	80	IV Methylpred+ rituximab	[17]
19	Pembrolizumab	Melanoma	Prolonged BP	44	Oral and topical steroids	[34]
20	Nivolumab	Renal cell Ca.	Cutaneous BP	12	Oral and topical steroids	[35]
21	Pembrolizumab	Melanoma	Cutaneous BP	24	Niacinamide	[36]
22	Nivolumab	Melanoma	Cutaneous BP	12	Oral and topical steroids	[36]
23	Pembrolizumab and ipilimumab	Melanoma	Cutaneous BP	24	IV and oral steroids and methotrexate	[37]
24	Pembrolizumab	Melanoma	Cutaneous BP	51	Oral steroids	[38]
25	Nivolumab	Skin SCC	Cutaneous BP		Oral steroids and dapsone	[7]
26	Nivolumab	Melanoma	Cutaneous BP		Topical steroids	[7]
27	Atezolizumab	Urothelial Ca.	Cutaneous BP	22	Topical/oral steroids and omalizumab, methotrexate	[12]
28	Nivolumab	NSCLC	Cutaneous BP		Topical/oral steroids	[12]
29	Nivolumab	NSCLC	Cutaneous BP		Topical/oral steroids and omalizumab	[12]
30	Nivolumab then Pembrolizumab	NSCLC	Cutaneous BP		Topical and oral steroids and nicotinamide	[12]
31	Pembrolizumab then ipilimumab and nivolumab	Melanoma	Cutaneous BP		Topical and oral steroids and nicotinamide	[12]
32	Nivolumab	Renal cell Ca.	Cutaneous BP		Oral steroids and nicotinamide	[12]
33	Pembrolizumab	NSCLC	Cutaneous and oral BP		Topical and oral steroids	[12]
34	Pembrolizumab	Melanoma	MMP	66	Doxycycline only	[39]
35	Pembrolizumab	Melanoma	Cutaneous BP	12	Topical and oral steroids	[14]
36	Ipilimumab then pembrolizumab	Melanoma	Cutaneous BP	29	Topical and oral steroids	[14]
37	Nivolumab	NSCLC	Cutaneous BP	7	Topical and oral steroids and niacinamide	[26]
38	Ipilimumab after pembrolizumab	Melanoma	BP		Oral and topical steroid	[40]
39	Nivolumab	NSCLC	BP		Oral steroids	[41]
40	Ipilimumab after nivolumab	Melanoma	BP	50	Topical steroids	[42]
41	Pembrolizumab	Merkel cell Ca.	MMP	13	Topical steroids	[43]
42	Nivolumab	Melanoma	Oral and cutaneous BP		Topical steroids	[44]
43	Nivolumab	Renal cell Ca.	BP on higher dose immunotherapy		Oral steroids	[18]

44	Nivolumab	Melanoma	Cutaneous BP		Topical/oral steroids and dapsone	[13]
45	Nivolumab	Melanoma	MMP		Topical steroids	[45]
46	Pembrolizumab	Ovarian Ca.	Severe MMP	3	Topical and oral steroids	[46]
47	Nivolumab	Lung	Oral and cutaneous BP		Oral steroid	[8]
48	Atezolizumab	Penile SCC	Photodistributed BP		Oral steroids	[47]
49	Atezolizumab	Urothelial cell Ca.	Cutaneous BP	77	Topical steroids, doxycycline and niacinamide	[15]
50	Nivolumab	Renal cell Ca.	Cutaneous BP	52	IV and oral steroids	[48]
51	Durvalumab and tremelimumab	NSCLC	BP	42	Oral steroids	[49]
52	Cemiplimab	Cutaneous SCC	BP		Oral steroids and rituximab	[50]

SCC: squamous cell cancer; Ca.: carcinoma; NSCLC: non-small cell lung cancer; MMP: mucous membrane pemphigoid; BP: bullous pemphigoid

may develop in the presence of anti-LAD-1 IgG antibodies alone but absence of anti-BP180 or anti-BP230 autoantibodies^[13].

Treatment regimens generally include steroids (oral or topical or combination), often in conjunction with discontinuation of immunotherapy. As steroids can potentially diminish immunomodulatory actions, topical steroids are first-line treatment for BP and are largely safe due to their limited systemic absorption. Meanwhile, oral nicotinamide and tetracycline (doxycycline or minocycline) have demonstrated a good effect in mild or moderate cases whilst completely avoiding systemic steroids^[14,15]. The role of nicotinamide in treating BP is modulating inflammatory cytokines and acting as poly adenosine diphosphate ribose polymerase inhibitor^[16]. However, severe cases have frequently required intravenous methylprednisolone (1-2 mg/kg). Refractory immunotherapy-induced BP shows response to rituximab or omalizumab^[12,17], which are started after immunotherapy discontinuation and lead to resolution of BP. Future studies are warranted to explore targeted immunosuppressant agents for severe steroid-refractory BP.

The question of resuming immunotherapy after resolution of BP remains under discussion. In the situations where immunotherapy is ineffective, discontinuation is clearly warranted. While in the context of a clinical response to immunotherapy, the discontinuation of immunotherapy is challenging, and the risks of continued treatment must be carefully weighed against its benefits. As such, the decision of resuming immunotherapy should be made as a part of multidisciplinary team and on an individual basis. In one case report BP developed after the patient was transitioned to a higher dose of nivolumab. Another case report showed improvement in BP after switching from nivolumab to pembrolizumab^[18]. Consequently, immunotherapy should not be permanently discontinued without the trial of the previously tolerated dose or frequency or different immunotherapy.

Understanding the correlation between the incidence rate of skin irAEs and oncology benefit or immunotherapy resistance is critical for clinical practice. There is some evidence showing potential positive association between development of cutaneous irAEs and improved survival in patients on immunotherapy, particularly vitiligo^[19,20]. In addition, a systematic review and meta-analysis suggested that the skin, gastrointestinal and endocrine irAEs might be positively associated with clinical benefit, while the pulmonary irAEs might be associated with immunotherapy resistance^[21]. However, the development of severe BP in our case is not a marker of good response to immunotherapy, as the patient failed to respond to nivolumab despite the extensive, refractory, severe BP. Immunotherapy resistance can be classified as primary, such as in never-responders, or acquired, which emerges after a period of response^[22]. Our patient had continuously slow disease progression in his metastatic left adrenal and left kidney mass since nivolumab, which could be primary immunotherapy resistance. However, we could not totally exclude the possibility of pseudo-progression, as his other metastatic diseases were largely stable. In a later phase, the

extra use of steroids and cessation of nivolumab certainly further contributed to his disease progression. Consequently, understanding the correlation between skin irAEs and clinical outcome could provide valuable information in distinguishing between pseudo-progression and immunotherapy resistance, which will assist oncologists in the decision of resuming immunotherapy after the recovery from manageable skin irAEs.

The mechanism of immunotherapy induced BP is currently unclear. While BP is associated with both a humoral and a cellular response, it is widely believed that immunotherapy induced BP could be provoked by an autoantibody targeted to a shared antigen and the dysfunction in T-regulatory cells, which is inhibited by immunotherapy^[23]. The shared target antigen is located both at the dermoepidermal junction and on the surface of tumour cells, such as BP 180, which can be expressed on the surface of melanoma cells, non-small cell lung cancer cells and basement membrane skin cancer^[24,25]. Meanwhile, dysregulation of PD-1/PD-L1 and CTLA-4 signal pathway induced by immunotherapy can impair the balance within the immune system, resulting in the development of off-target effects and autoimmunity^[26]. Further studies are required to determine the underlying mechanisms of immunotherapy induced BP.

Conclusion

Here, we report a rare case of severe, extensive and refractory nivolumab-induced BP in a patient with advanced renal cancer. With the widespread use of immunotherapy, it has become increasingly important to document cases of immunotherapy-induced BP to provide more information in diagnosing and treating these cutaneous adverse events. Moreover, the close collaboration between dermatologists and oncologists is essential to allow the patients with cutaneous irAEs to continue antitumor therapy, avoiding unnecessary discontinuation of immunotherapy.

DECLARATIONS

Acknowledgments

All authors would like to acknowledge Dr. Dalila Malek, Dr. Paul Gatt, Dr. Ravi Suchak and Dr. Marice Sudaerson (Southend Hospital) for support and advice.

Authors' contributions

Designed the study and wrote the manuscript: Wu X, Palvai S

Reviewed and approved the manuscript: Jalil A

Availability of data and materials

Not applicable.

Financial support and sponsorship

This study supported by National Health Service Funding.

Conflicts of interest

All authors declared that there are no conflicts of interest.

Ethical approval and consent to participate

Written informed consent was obtained from the patient.

Consent for publication

Written informed consent was obtained from the patient for publication of this case report and any accompanying images.

Copyright

© The Author(s) 2020.

REFERENCES

1. Schiavo AL, Ruocco E, Brancaccio G, Caccavale S, Ruocco V, Wolf R. Bullous pemphigoid: etiology, pathogenesis, and inducing factors: facts and controversies. *Clin Dermatol* 2013;31:391-9.
2. Amber KT, Panganiban CM, Korta D, Feraudy S, Kelly KM, Grando SA. A case report of bullous pemphigoid associated with a melanoma and review of the literature. *Melanoma Res* 2017;27:65-7.
3. Yatim A, Bohelay G, Grootenboer-Mignot S, et al. Paraneoplastic pemphigus revealed by anti-programmed Death-1 pembrolizumab therapy for cutaneous squamous cell carcinoma complicating hidradenitis suppurativa. *Front Med (Lausanne)* 2019;6:249.
4. Kridin K, Bergman R. Assessment of the prevalence of mucosal involvement in bullous pemphigoid. *JAMA Dermatol* 2019;155:166-71.
5. Ellis SR, Vierra AT, Millsop JW, Lacouture ME, Kiuru M. Dermatologic toxicities to immune checkpoint inhibitor therapy: A review of histopathologic features. *J Am Acad Dermatol* 2020;83:1130-43.
6. Buonavoglia A, Leone P, Dammacco R, et al. Pemphigus and mucous membrane pemphigoid: An update from diagnosis to therapy. *Autoimmun Rev* 2019;18:349-58.
7. Nahmias Z P, Merrill ED, Briscoe CC, et al. Development of bullous pemphigoid while receiving PD-1 checkpoint inhibitor nivolumab. *SKIN J Cutane Med* 2018;2:175-80.
8. Cuenca-Barrales C, Espadafor-López B, Martínez-López A, Cancela-Díez B, Ruiz-Villaverde R. Bullous pemphigoid in a patient treated with nivolumab. *Dermatol Ther* 2019;32:e13030.
9. Jour G, Glitza IC, Ellis RM, et al. Autoimmune dermatologic toxicities from immune checkpoint blockade with anti-PD-1 antibody therapy: a report on bullous skin eruptions. *J Cutan Pathol* 2016;43:688-96.
10. Amber KT, Valdebran M, Kridin K, Grando SA. The role of eosinophils in bullous pemphigoid: a developing model of eosinophil pathogenicity in mucocutaneous disease. *Front Med (Lausanne)* 2018;5:201.
11. Tampoia M, Giavarina D, Di Giorgio C, Bizzaro N. Diagnostic accuracy of enzyme-linked immunosorbent assays (ELISA) to detect anti-skin autoantibodies in autoimmune blistering skin diseases: a systematic review and meta-analysis. *Autoimmun Rev* 2012;12:121-6.
12. Siegel J, Totonchy M, Damsky W, et al. Bullous disorders associated with anti-PD-1 and anti-PD-L1 therapy: A retrospective analysis evaluating the clinical and histopathologic features, frequency, and impact on cancer therapy. *J Am Acad Dermatol* 2018;79:1081-8.
13. Sadik CD, Langan EA, Grätz V, Zillikens D, Terheyden P. Checkpoint inhibition may trigger the rare variant of anti-LAD-1 IgG-positive, anti-BP180 NC16A IgG-negative bullous pemphigoid. *Front Immunol* 2019;10:1934.
14. Thomsen K, Diernaes J, Øllegaard TH, Spaun E, Vestergaard C. Bullous pemphigoid as an adverse reaction to pembrolizumab: two case reports. *Case Rep Dermatol* 2018;10:154-7.
15. Kosche C, Owen JL, Sadowsky LM, Choi JN. Bullous dermatoses secondary to anti-PD-L1 agents: a case report and review of the literature. *Dermatol Online J* 2019;25:6.
16. Fivenson DP, Breneman DL, Rosen GB, Hersh CS, Cardone S, Mutasim D. Nicotinamide and tetracycline therapy of bullous pemphigoid. *Arch Dermatol* 1994;130:753-8.
17. Sowerby L, Dewan AK, Granter S, Gandhi L, LeBoeuf NR. Rituximab treatment of nivolumab-induced bullous pemphigoid. *JAMA Dermatol* 2017;153:603-5.
18. Palla AR, Smith E, Doll D. Bullous pemphigoid associated with the 480-mg nivolumab dose in a patient with metastatic renal cell carcinoma. *Immunotherapy* 2019;11:1187-92.
19. Freeman-Keller M, Kim Y, Cronin H, Richards A, Gibney G, Weber JS. Nivolumab in resected and unresectable metastatic melanoma: characteristics of immune-related adverse events and association with outcomes. *Clin Cancer Res* 2016;22:886-94.
20. Sanlorenzo M, Vujic I, Daud A, et al. Pembrolizumab cutaneous adverse events and their association with disease progression. *JAMA Dermatol* 2015;151:1206-12.
21. Xing P, Zhang F, Wang G, et al. Incidence rates of immune-related adverse events and their correlation with response in advanced solid tumours treated with NIVO or NIVO+IPI: a systematic review and meta-analysis. *J Immunother Cancer* 2019;7:341.
22. Fares CM, Van Allen EM, Drake CG, Allison JP, Hu-Lieskovan S. Mechanisms of resistance to immune checkpoint blockade: why does checkpoint inhibitor immunotherapy not work for all patients? *Am Soc Clin Oncol Educ Book* 2019;39:147-64.
23. Naidoo J, Schindler K, Querfeld C, et al. Autoimmune bullous skin disorders with immune checkpoint inhibitors targeting PD-1 and PD-L1. *Cancer Immunol Res* 2016;4:383-9.
24. Krenacs T, Kiszner G, Stelkovic E, et al. Collagen XVII is expressed in malignant but not in benign melanocytic tumors and it can mediate antibody induced melanoma apoptosis. *Histochem Cell Biol* 2012;138:653-7.
25. Papay J, Krenacs T, Moldvay J, et al. Immunophenotypic profiling of nonsmall cell lung cancer progression using the tissue microarray approach. *Appl Immunohistochem Mol Morphol* 2007;15:19-30.
26. Lopez AT, Geskin L. A case of nivolumab-induced bullous pemphigoid: Review of dermatologic toxicity associated with programmed cell death protein-1/programmed death ligand-1 inhibitors and recommendations for diagnosis and management. *Oncologist* 2018;23:1119-26.
27. Carlos G, Anforth R, Chou S, Clements A, Fernandez-Peñas P. A case of bullous pemphigoid in a patient with metastatic melanoma treated with pembrolizumab. *Melanoma Res* 2015;25:265-8.
28. Beck KM, Dong J, Geskin LJ, et al. Disease stabilization with pembrolizumab for metastatic acral melanoma in the setting of autoimmune

- bullous pemphigoid. *J Immunother Cancer* 2016;4:20.
29. Damsky W, Kole L, Tomayko MM. Development of bullous pemphigoid during nivolumab therapy. *JAAD Case Rep* 2016;2:442-4.
 30. Mochel MC, Ming ME, Imadojemu S, et al. Cutaneous autoimmune effects in the setting of therapeutic immune checkpoint inhibition for metastatic melanoma. *J Cutan Pathol* 2016;43:787-91.
 31. Lomax AJ, Ge L, Anand S, McNeil C, Lowe P. Bullous pemphigoid-like reaction in a patient with metastatic melanoma receiving pembrolizumab and previously treated with ipilimumab. *Australas J Dermatol* 2016;57:333-5.
 32. Hwang SJ, Carlos G, Chou S, Wakade D, Carlino MS, Fernandez-Penas P. Bullous pemphigoid, an autoantibody-mediated disease, is a novel immune-related adverse event in patients treated with anti-programmed cell death 1 antibodies. *Melanoma Res* 2016;26:413-6.
 33. Hirotsu K, Chiou AS, Chiang A, Kim J, Kwong BY, Pugliese S. Localized bullous pemphigoid in a melanoma patient with dual exposure to PD-1 checkpoint inhibition and radiation therapy. *JAAD Case Rep* 2017;3:404-6.
 34. Parakh S, Nguyen R, Opie JM, Andrews MC. Late presentation of generalised bullous pemphigoid-like reaction in a patient treated with pembrolizumab for metastatic melanoma. *Australas J Dermatol* 2017;58:e109-12.
 35. Kwon CW, Land AS, Smoller BR, Scott G, Beck LA, Mercurio MG. Bullous pemphigoid associated with nivolumab, a programmed cell death 1 protein inhibitor. *J Eur Acad Dermatol Venereol* 2017;31:e349-50.
 36. Bandino JP, Perry DM, Clarke CE, Marchell RM, Elston DM. Two cases of anti-programmed cell death 1-associated bullous pemphigoid-like disease and eruptive keratoacanthomas featuring combined histopathology. *J Eur Acad Dermatol Venereol* 2017;31:e378-80.
 37. Rofe O, Bar-Sela G, Keidar Z, Sezin T, Sadik CD, Bergman R. Severe bullous pemphigoid associated with pembrolizumab therapy for metastatic melanoma with complete regression. *Clin Exp Dermatol* 2017;42:309-12.
 38. Wada N, Uchi H, Furue M. Bullous pemphigoid induced by pembrolizumab in a patient with advanced melanoma expressing collagen XVII. *J Dermatol* 2017;44:e240-1.
 39. Zumelzu C, Alexandre M, Le Roux C, et al. Mucous membrane pemphigoid, bullous pemphigoid, and anti-programmed death-1/programmed death-ligand 1: a case report of an elderly woman with mucous membrane pemphigoid developing after pembrolizumab therapy for metastatic melanoma and review of the literature. *Front Med (Lausanne)* 2018;5:268.
 40. Hanley T, Papa S, Saha M. Bullous pemphigoid associated with ipilimumab therapy for advanced metastatic melanoma. *JRSM Open* 2018;9:2054270418793029.
 41. Panariello L, Fattore D, Annunziata MC, Piantedosi F, Gilli M, Fabbrocini G. Bullous pemphigoid and nivolumab: dermatologic management to support and continue oncologic therapy. *Eur J Cancer* 2018;103:284-6.
 42. Kuwatsuka Y, Iwanaga A, Kuwatsuka S, et al. Bullous pemphigoid induced by ipilimumab in a patient with metastatic malignant melanoma after unsuccessful treatment with nivolumab. *J Dermatol* 2018;45:e21-2.
 43. Haug V, Behle V, Benoit S, et al. Pembrolizumab-associated mucous membrane pemphigoid in a patient with Merkel cell carcinoma. *Br J Dermatol* 2018;179:993-4.
 44. Sturque J, Boralevi F, Fricain JC. Nivolumab-induced oral and cutaneous bullous pemphigoid: a case report. *J Oral Med Oral Surg* 2019;25:17.
 45. Sibaud V, Vigarios E, Siegfried A, Bost C, Meyer N, Pages-Laurent C. Nivolumab-related mucous membrane pemphigoid. *Eur J Cancer* 2019;121:172-6.
 46. Bezinelli LM, Eduardo FP, Migliorati CA, et al. A severe, refractory case of mucous membrane pemphigoid after treatment with pembrolizumab: brief communication. *J Immunother* 2019;42:359-62.
 47. Leavitt E, Holland V. A case of atezolizumab-induced photodistributed bullous pemphigoid. *Dermatol Ther* 2019;32:e12924.
 48. Anedda J, Atzori L, Rongioletti F, Pilloni L. Nivolumab bullous pemphigoid: case description and literature review. *J Clin Exp Pathol* 2019;9:364.
 49. Fontecilla NM, Khanna T, Bayan CAY, Antonov NA, Geskin LJ. Bullous pemphigoid associated with a new combination checkpoint inhibitor immunotherapy. *J Drugs Dermatol* 2019;18:103-4.
 50. Virgen CA, Nguyen TA, Di Raimondo C, et al. Bullous pemphigoid associated with cemiplimab therapy in a patient with locally advanced cutaneous squamous cell carcinoma. *JAAD Case Rep* 2020;6:195-7.