

Review

Open Access



Early and long-term outcomes of less invasive approaches to coronary artery bypass surgery

Christine Ashenhurst^{1,2,#}, Omar Toubar^{1,3,#}, Ming Hao Guo¹, Hugo Issa¹, Menaka Ponnambalam¹, Marc Ruel¹ 

¹Division of Cardiac Surgery, University of Ottawa Heart Institute, Ottawa, ON K1Y 4W7, Canada.

²Department of Chemistry, Faculty of Science, University of Victoria, Victoria, BC V8W 2Y2, Canada.

³Faculty of Medicine, McGill University, Montréal, QC H3A 0G4, Canada.

#Authors contributed equally.

Correspondence to: Dr. Marc Ruel, Division of Cardiac Surgery, University of Ottawa Heart Institute, 3402-40 Ruskin Street, Ottawa, ON K1Y 4W7, Canada. E-mail: mruel@ottawaheart.ca

How to cite this article: Ashenhurst C, Toubar O, Guo MH, Issa H, Ponnambalam M, Ruel M. Early and long-term outcomes of less invasive approaches to coronary artery bypass surgery. *Vessel Plus* 2024;8:3. <https://dx.doi.org/10.20517/2574-1209.2023.90>

Received: 26 Jul 2023 **First Decision:** 20 Nov 2023 **Revised:** 25 Dec 2023 **Accepted:** 3 Jan 2024 **Published:** 15 Jan 2024

Academic Editor: Giuseppe Andò **Copy Editor:** Fangling Lan **Production Editor:** Fangling Lan

Abstract

This review outlines the development of less invasive treatments for coronary artery disease, focusing primarily on minimally invasive coronary artery bypass grafting (MICS CABG). We compare conventional coronary artery bypass grafting (CABG) and MICS CABG indications and contraindications, surgical techniques, early and long-term outcomes, and the process of implementation of MICS CABG to cardiac surgery programs. The invasiveness of cardiopulmonary bypass and the sternotomy incision used in conventional CABG are appreciably mitigated by the MICS CABG procedure, which is generally performed off-pump and through a left mini-thoracotomy. In the literature, MICS CABG is a feasible alternative to sternotomy CABG with safe, reproducible, efficient, and durable outcomes.

Keywords: Coronary artery disease, coronary artery bypass grafting, minimally invasive, minimally invasive coronary artery bypass grafting, mini-thoracotomy, learning curve

INTRODUCTION

Cardiovascular diseases are the predominant cause of death worldwide, accounting for 32% of deaths



© The Author(s) 2024. **Open Access** This article is licensed under a Creative Commons Attribution 4.0 International License (<https://creativecommons.org/licenses/by/4.0/>), which permits unrestricted use, sharing, adaptation, distribution and reproduction in any medium or format, for any purpose, even commercially, as long as you give appropriate credit to the original author(s) and the source, provide a link to the Creative Commons license, and indicate if changes were made.



globally in 2019^[1]. Coronary artery disease (CAD) is the most common cardiovascular disease and is associated with a significant economic and social burden. The direct and indirect cost of healthcare expenditures and loss of productivity, for example, are estimated to be a multi-billion-dollar loss^[1].

Evidently, the treatment of CAD has had a robust history. First conceptualized in 1910 by Carrel^[2] as an experimental procedure, coronary artery bypass grafting gained popularity as a surgical treatment for CAD in the 1960s after its initial iteration by Kolesov and Potashov^[3]. Venous or arterial conduits are used to bypass atheromatous blockages in coronary arteries, restoring blood supply to the ischemic myocardium. The median sternotomy incision typically employed in the surgery provides a clear view of the operating field and easy manipulation of the heart^[4]. Although still considered the “gold standard” incision^[5], the invasiveness of sternotomy is nearly unchanged from its inaugural procedure. Each year, nearly 300,000 and 15,000 individuals undergo CABG in the United States and Canada, respectively, making it one of the most common surgeries performed^[5-7]. Still, traditional CABG is associated with significant invasiveness, including that related to the use of cardiopulmonary bypass (CPB) and a sternotomy incision^[8-10]. Procedures that reduce the morbidity of CABG through less invasive techniques have been developed and adopted^[11]. This article summarizes the evolution of minimally invasive coronary artery bypass grafting, the early, long-term, and functional outcomes, and outlines strategies to implement MICS CABG in cardiac surgery programs.

INDICATIONS

The 2021 ACC/AHA/SCAI Guidelines outline the indications for patients to undergo coronary revascularization^[4]. The patients’ preferences, goals, cultural beliefs, health literacy, and social determinants of health are to be considered and adequate information concerning benefits, risks, and potential consequences is to be disclosed before proceeding to ensure their best interest is at the center of the treatment decision.

For patients presenting with stable ischemic heart disease (SIHD) and significant left main stenosis, CABG is indicated. Historically, CABG was also indicated in patients with SIHD, triple vessel disease, and normal left ventricular ejection fraction (LVEF)^[12]. However, the 2021 guidelines lowered the indication of CABG for these patients from a Class 1 to a Class 2b recommendation^[4]. There has been controversy surrounding the downgrade of these indications, and this change has not been endorsed by several cardiologic and surgical societies^[13,14]. Instead, the societies suggest that randomized control trials and meta-analyses have established strong evidence that surgical intervention does improve patient survival over medical intervention^[15].

Healthcare professionals must assess the perioperative risks and comorbidities and consider if they outweigh the surgery’s benefit before proceeding. Patient refusal and anatomical incompatibility with grafting constitute the general contraindications for CABG. Unsuitable conduits and targets, non-viable myocardium after infarct, and the presence of anatomical barriers such as porcelain aorta or mediastinal radiation make surgical revascularization complex and more risky^[4,5,16].

The indications for MICS CABG are similar to that of conventional sternotomy CABG. Additionally, MICS CABG is employed in cases of left main coronary artery disease with normal right coronary artery disease, previous unsuccessful PCIs, triple vessel disease with medium to large PDA or left ventricular branch of the RCA, and complex proximal left-sided lesions in the presence or absence of main branch involvement^[17]. Patients with less diffuse coronary artery may elect to undergo MICS CABG due to its reduced invasiveness and improved functional outcomes^[18]. Furthermore, for patients who are at high risk of complications

related to sternotomy, such as those with chronic tracheostoma or diabetes^[5,19], MICS CABG could be an attractive alternative. Lastly, MICS CABG is also indicated for patients who prefer to undergo less invasive procedures and lead an active lifestyle^[17,20].

Despite the advantages that come with the less invasive approach, certain patient presentations are contraindicated for the procedure, including emergency cases, hemodynamic instability, severe chest wall deformities (i.e., pectus excavatum), or severe pulmonary disease^[5,17,20]. Relative contraindications include left subclavian stenosis, hemodialysis arteriovenous fistula on the left side, morbid obesity, and moderate valve disease or ventricular dysfunction^[17].

LESS INVASIVE CARDIAC SURGERY APPROACHES

Comparison

With the rapid advancement of technology, several minimal techniques have been established and continue to evolve. [Table 1](#) categorizes each surgical procedure based on the incision employed and the respective use of CBP.

The negative inflammatory risks associated with CPB^[8-10] can be avoided by offering off-pump CABG (OPCAB), which has become increasingly popular. In OPCAB, the bypass is performed through a median sternotomy on a beating heart, without the use of a cardiopulmonary bypass machine. All regions of the heart can be accessed for revascularization, though specialized equipment must be employed to stabilize the coronary artery during grafting.

In the 1990s, an even less invasive single-vessel bypass surgery was performed without the use of bypass or sternotomy^[21]. This technique, known as minimally invasive direct coronary artery bypass (MIDCAB), involves grafting the left internal thoracic artery (LIMA) to the left anterior descending coronary artery (LAD). Based on the anatomy of the incision, it is restricted to grafting only the LITA-LAD, which makes it technically difficult to target severe or diffuse CAD. At MIDCAB's inception, multi-vessel bypass grafting was not considered feasible through a nonsternotomy incision.

However, in 2009, McGinn and Ruel demonstrated the systematic safety and feasibility of the evolution towards multivessel MIDCAB, now known as minimally invasive coronary artery bypass grafting^[17]. MICS CABG allows the surgeon to perform complete revascularization through a sternum-sparing small left thoracotomy incision, often without the use of CPB^[17]. The incision allows access to all coronary territories and a graft configuration comparable to that achieved with a sternotomy. The use of robotic technology has further advanced the evolution of MICS CABG and permitted more complex grafts to be performed either robotically assisted or totally robotically^[22]. Often, MICS CABG is coupled with percutaneous coronary interventions in the context of Hybrid Coronary Revascularization (HCR)^[23].

Surgical incisions

Median sternotomy is frequently used in cardiothoracic procedures requiring access to contents of the mediastinum and is the most used incision for CABG. The opening and closing of the incision can be associated with various post-op complications, but it can be performed safely with proper execution and consideration [[Figure 1](#)].

On the other hand, as the name suggests, MIDCAB and MICS CABG utilize a significantly less invasive incision, a small left thoracotomy, which is associated with a lower risk of post-op complications^[17,20]. Perioperative pain control can be achieved through paravertebral thoracic local anesthetic injection at the

Table 1. Differentiation of minimally invasive coronary artery bypass grafting techniques

		Incision	
		Median sternotomy	Small left anterior thoracotomy
Use of CPB	On-pump	Conventional CABG (all territories accessible)	Pump assistance may be used in the learning phase and complicated cases of MIDCAB and MICS CABG
	Off-pump	OPCAB (all territories accessible)	MIDCAB (Single vessel; LITA-LAD) MICS CABG (Single or multivessel; not restricted)

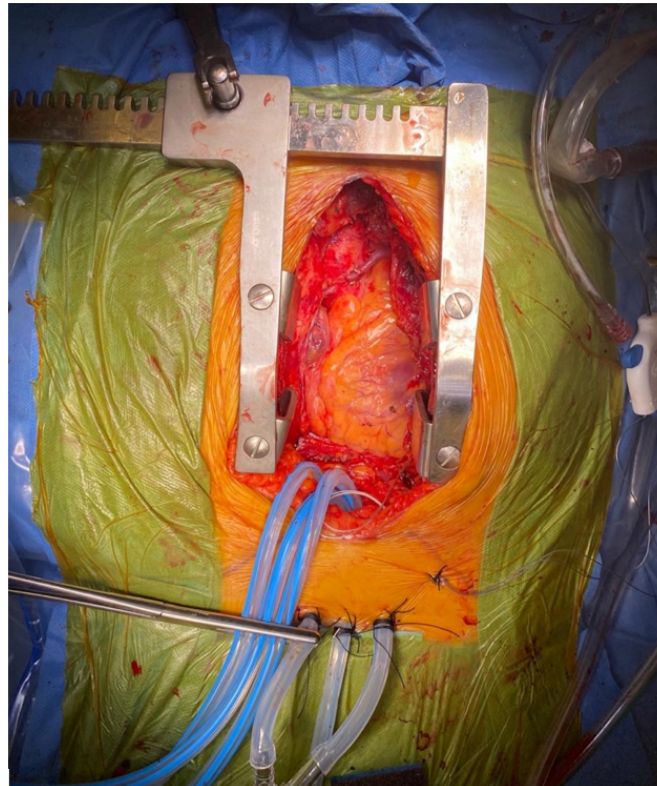


Figure 1. CABG sternotomy incision during operation, demonstrating the invasiveness of the procedure (Internal photos of the incisions and procedures). The patient gave explicit consent to have their photo included in this review.

T2-T3 level^[17]. Using a double-lumen endotracheal tube or a regular endotracheal tube and a left bronchial blocker, the patient is intubated, and the left lung is deflated. The patient is then placed in a 15-30° right lateral decubitus position and a roller is placed under the supine patient between the spine and left scapula with the left arm tucked at a 45-degree angle to facilitate rib separation. The patient is draped in a way that facilitates access to the groin for femoral venous and arterial cannulas should CBP be required. The legs are also available for saphenous vein harvest if indicated in the procedure. The main incision or the “window incision” aims to access the thoracic cavity through the fourth or fifth intercostal spaces at the midclavicular line and starts medially right beneath the left nipple in males and is then extended 5 to 8 cm laterally [Figure 2]. For female patients, an inframammary incision is used instead. In MICS CABG, in addition to the main incision, there are two additional access portals, namely at the subxiphoid region and the sixth or seventh intercostal space down the anterior axillary line. Through these portals, a Starfish Non-Sternotomy Heart Positioner (Medtronic, Minneapolis, MN, USA) and the Octopus Non-Sternotomy Tissue Stabilizer (Medtronic) are inserted through the subxiphoid and the sixth intercostal ports, respectively, enabling visualization of all coronary arteries as illustrated in Figure 3.

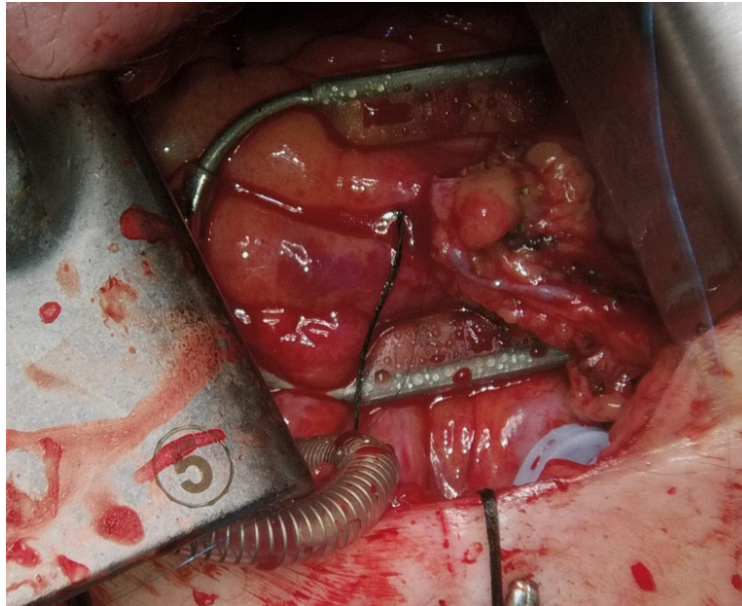


Figure 2. Visualization of the heart through a left mini-thoracotomy (Internal photos of the incisions and procedures). The incision measures approximately 5 to 8 cm. The patient gave explicit consent for their photo to be included in this review.

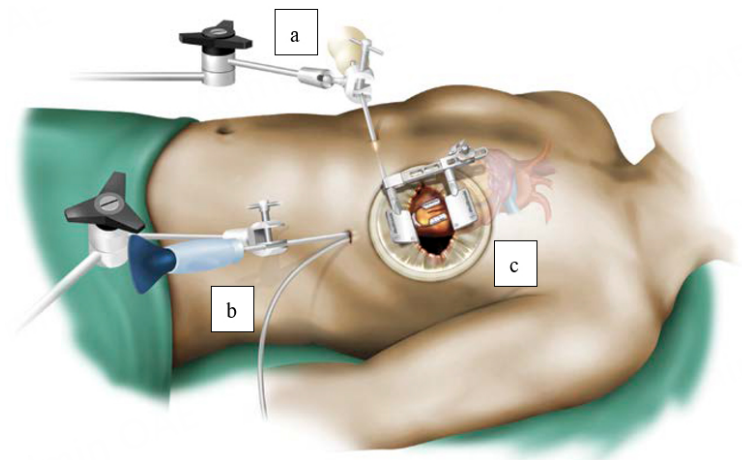


Figure 3. MICS CABG illustration with the equipment required to carry out the procedure: Starfish NS Heart Positioner (a), Octopus Nuvo Tissue Stabilizer (b), and Thoratrak MICS Retractor System (c)^[17].

OUTCOMES

The appeal of minimally invasive surgery to patients is multifaceted: mitigation of inflammatory responses due to CBP, lower risk of wound infection or pain, cosmesis and excellent short- and long-term outcomes^[17,24].

The physiologic derangements brought on by CBP have been well-established in the literature^[8-10]. Prolonged use of CPB in coronary surgery is associated with an increased risk of stroke and other postoperative complications affecting both long-term and short-term survival^[25]. By mitigating the use of CBP, OPCAB and MICS CABG have been associated with a lower incidence of complications, especially in high-risk patients^[17,19,24,26-29].

Complications such as sternal dehiscence, mediastinitis, malunion, and chronic pain can arise as a result of sternotomy. The incidence of deep sternal wound infections has been reported between 1% and 8% and is associated with a mortality of approximately 10%-25%^[30-35]. Deep sternal wound infections greatly increase the morbidity and mortality of patients and are a significant burden on the healthcare systems, with potential long-term implications^[34,35].

With a smaller incision and preservation of the sternum, access to the heart by a mini-thoracotomy avoids the risks associated with sternal trauma. Thoracotomy incisions appreciably mitigate the risk of deep sternal wound infections and have been consistently associated with lower rates of wound infection^[17,20,36].

Chronic pain following a sternotomy incision affects approximately 17%-56% of surgical patients, having serious implications for the patient's recovery^[8]. A prospective study found that, in comparison, patients undergoing MICS CABG experience lower pain levels, possibly because of preserved bony thorax integrity permitting earlier mobilization^[37,38]. However, persistent pain following minimally invasive cardiac surgery continues to be a complication due to the nature of the incision causing damage to the ribs, pleura, intercostal nerves, costovertebral joints, and muscles. Pain management for thoracotomy usually requires a multimodal approach and can include nerve blocks, cryoanalgesia, liposomal bupivacaine, nonsteroidal anti-inflammatory drugs, and gabapentinoids^[38,39].

Open heart surgery involving a sternotomy incision leaves patients with a significant scar down the midline [Figure 4]. The scar left by a small thoracotomy, in comparison, extends 6 to 10 centimeters and is highly discrete [Figure 5].

Early outcomes

The limited availability of comprehensive studies comparing the long-term outcomes of patients undergoing minimally invasive coronary artery bypass grafting (MICS CABG) *vs.* conventional CABG has increased the urgency to conduct rigorous research to supplement such gaps in the literature. This urgency is primarily driven by the growing popularity of the MICS CABG procedure^[17]. The Minimally Invasive coronary surgery compared to STernotomy coronary artery bypass grafting (MIST) trial is the first multicenter prospective, randomized clinical trial comparing the postoperative quality of life for patients after conventional *vs.* minimally invasive CABG^[40]. The results of this trial will be critical in ascertaining if MICS CABG has a clinical benefit over sternotomy. Table 2 provides a summary of the early clinical outcomes of contemporary, published papers evaluating MICS CABG surgeries.

In McGinn and Ruel's inaugural paper, 450 patients with CAD underwent MICS CABG between 2005 and 2008^[17]. The operation was completed without conversion to sternotomy in 433 (96.2%) of the 450 patients and perioperative mortality occurred in 6 patients (1.3%). Follow-up after a mean of 19.2 ± 9.4 months was available from the series' first 300 patients. In this mid-term period, 10 patients (3.0%) required PCI and 2 (0.6%) mid-term saphenous vein graft failures occurred. Unlike MIDCAB, which is restricted to one LITA-LAD graft, MICS CABG can access all regions of the heart and, as such, can treat diffuse CAD. This inaugural paper introduced MICS CABG as a safe and reproducible procedure associated with complete vascularization, low morbidity and mortality profile, and graft configuration comparable to conventional CABG. From its inception, the literature has subsequently shown a growing, significant interest in MICS CABG procedures.

In a case-matched study, Lapierre investigated the difference in patient outcomes by comparing those who underwent MICS CABG *vs.* OPCAB^[20]. Patients were propensity matched using criteria including age,

Table 2. Perioperative results with MICS CABG

Author, year	n	Average number of grafts	Complete revascularization	Average length of stay	Conversion to sternotomy	Use of CPB	Perioperative mortality	Perioperative blood transfusion	New onset atrial fibrillation	Pleural effusion	Deep wound infection	Additional PCI intervention at the time of hospitalization
McGinn <i>et al.</i> , 2009 ^[17]	450	2.1 ± 0.7	427 (94.9%)	5.9 ± 3.4 ^a (range 1-86)	17 (3.8%)	34 (7.6%)	6 (1.3%)	96 (21.3%)	24.4%	9.1%	0	17 (3.8%)
Lapierre <i>et al.</i> , 2011 ^[20]	150	1.8 ± 0.7	150 (100%)	5 ^b (range 2-60)	10 (6.7%)	28 (18.7)	0	13 (8.7%)	35 (23.3%)	22 (14.7%)	0	5 (3.3%)
Ruel <i>et al.</i> , 2012 ^[45]	800	2.2 ± 0.8	-	4 ^b	25 (3.1%)	77 (9.6%)	-	-	18 (23.4%)	-	-	-
Ruel <i>et al.</i> , 2013 ^[36]	89	2.3 ± 0.9	89 (100%)	4 (range 3-9)	0	21 (23.6%)	0	24 (26%)	15 (17%)	14 (15%)	0	-
Rabindranauth <i>et al.</i> , 2014 ^[24]	129	2.1 ± 0.9	123 (95.3%)	4.0 ± 1.3 ^a	1 (0.8%)	10 (7.7%)	0	17 (13%)	26 (20.1%)	2 (1.5%)	0	3 (2.3%)
Liang <i>et al.</i> , 2022 ^[41]	172	3.0 ± 0.8	172 (100%)	6.2 ± 1.4 ^a	1 (0.6%)	3 (1.7%)	0	2 (1.2%)	35 (20.4%)	-	-	-
Guo <i>et al.</i> , 2023 ^[18]	566	-	-	5.8 ± 4.2 ^a	25 (4.4%)	81 (14.3%)	1 (0.2%, massive pulmonary embolism at discharge)	20 (3.5%)	111 (19.6%)	8 (1.1%)	0	35 (6.2%)

^aindicates mean; ^bindicates median.

gender, left ventricular function, and median number of distal anastomoses. The use of CPB assistance was more likely in MICS CABG than OPCAB and was used in instances of hemodynamic instability or poor exposure over conversion to sternotomy and had no clinical implications. Complete revascularization was achieved in all patients; however, five patients from each group required hybrid revascularization during their hospital stay. The MICS CABG patients had a significantly lower transfusion rate and a significantly higher rate of pleural effusion in comparison to OPCAB groups. There was no statistical difference in the other reported complications. On average, the OPCAB patients remained in the hospital for 1 day longer than MICS CABG patients and had higher wound infection rates. Additionally, MICS CABG patients experienced no deep wound infection compared to the 6 (4.0%) OPCAB patients who did. Similar wound infection rates have been consistently observed in the literature^[17,41].

Liang *et al.* compared the early outcomes between multivessel coronary bypass grafting by a sternotomy or a mini-thoracotomy in a retrospective single-center study^[41]. From January 2017 to January 2020, 211 patients underwent MICS CABG and 371 underwent conventional OPCAB. Patients in the MICS CABG group were propensity matched with a 1:1 ratio (MICS CABG = 172, OPCAB = 172) with those in the OPCAB group based on epidemiological data, preoperative clinical characteristics, and SYNTAX score. Although MICS CABG surgery was associated with longer operative times, those patients who

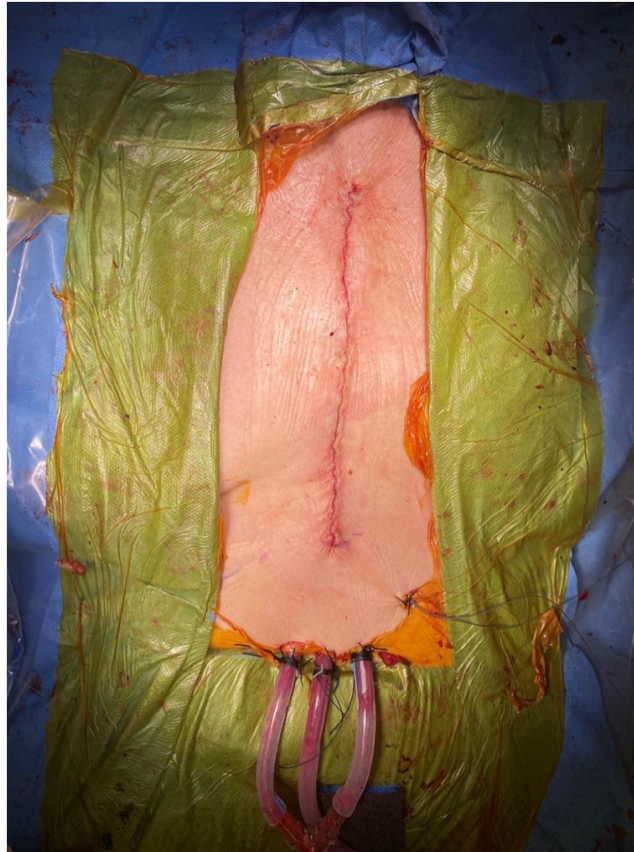

Figure 4. Postoperative scars left by sternotomy (Internal photos of the incisions and procedures). Patient gave explicit consent to have their photo included in this review.

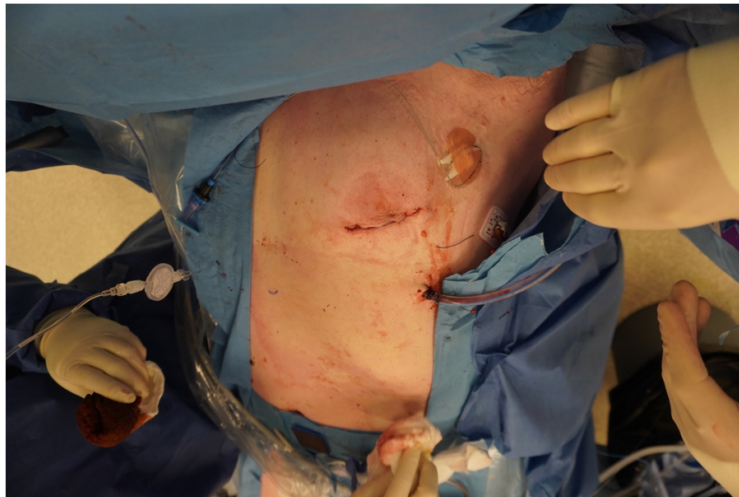


Figure 5. Postoperative scars left by left mini-thoracotomy (Internal photos of the incisions and procedures). Patient gave explicit consent to have their photo included in this review.

underwent MICS CABG had a shorter postoperative hospitalization and earlier return to physical functioning. The 30-day mortality rate and six-month graft patency were comparable between the MICS

CABG and the OPCAB groups. A comparison of these cohorts found that the CABG cohorts had higher, but statistically insignificant, rates of major adverse cardiac or cerebrovascular events^[42].

A prospective, observational, comparative review by Baishya found that patients undergoing MICS CABG generally have longer surgery durations, but a shorter period of ventilation use and less intraoperative blood loss^[43]. Notably, MICS CABG patients receive few blood transfusions and have short ICU and hospital stays on average^[24], as outlined in [Table 2](#).

Long-term outcomes

From its introduction in the 1960s, the durability of surgical revascularization has been well established in the literature, although continued research on alternative, less invasive techniques must still be pursued^[4]. [Tables 3](#) and [4](#) summarize the results of studies following the midterm and long-term outcomes of MICS CABG.

In 2018, a prospective study was conducted by McGinn and Ruel, studying the long-term outcomes in 800 patients who have undergone MICS CABG performed by two cardiac surgeons^[44,45]. The LITA was harvested in all the patients and a 4-6 cm thoracotomy in the left 5th intercostal space was used. The mean follow-up for the patients was 2.2 years and a maximum of 6.4 years. This study showed that MICS CABG is associated with a short hospital stay, no postoperative wound complications, and 6-year mortality rates comparable to that of conventional CABG.

A recent prospective study conducted by Guo *et al.* investigated the 12-year survival, major adverse cardiac and cerebrovascular events, revascularization, and function outcomes in an all-inclusive cohort from a single center^[18]. A total of 566 patients who underwent MICS CABG were followed for survival. They were then contacted for a questionnaire to assess their long-term functional outcomes. Clinical follow-up was complete for 100% of the patients, and 83.9% ($n = 427$) of the alive patients were able to complete the questionnaire. The study showed that at 12 years, the survival for the cohort was $82.2\% \pm 2.6\%$ and freedom from major adverse cardiac or cerebrovascular events (MACCE) was $75.5\% \pm 3.0\%$ [[Figure 6](#) and [7](#)].

Functional outcomes

Guo *et al.* also reported functional outcomes to supplement and strengthen the investigated clinical outcomes^[18]. Of the patients who completed the questionnaire, 12 (2.8%) had > CCS Class II angina and 19 (4.5%) reported having > NYHA Class II symptoms. Over 98% of patients indicated no pain at the incision site. Cox proportional hazards analysis showed older age, peripheral vascular disease, prior MI, LV dysfunction, cancer in the past 5 years, intraoperative transfusion, and hybrid revascularization to be correlated with mortality during the follow-up period. This study further enforces MICS CABG as a reliable and durable substitute to the conventional, more invasive sternotomy CABG for patients that match the selection criteria.

Many advocates of minimally invasive surgeries indicate reduced hospital time and improved functional outcomes earlier compared to traditional sternotomies. A recent multicenter randomized control trial by Akowuah *et al.* compared the twelve-week functional outcome of patients who underwent a traditional median sternotomy vs. mini-thoracotomy for a mitral valve repair surgery (MVR)^[46]. The study was unique as it was an expertise-driven trial, requiring participating surgeons to have performed at least 50 of the required procedures. Of the 1,167 screened patients, 330 were enrolled and randomized to the mini-thoracotomy or sternotomy group. Investigators used the change in baseline 36-Item Short Form Health Survey (SF-36) version 2 function T score to assess the functional outcomes of the two surgeries. The MICS

Table 3. Mid-term and long-term clinical results with MICS CABG

Author, year	n	Chest pain at 6 months	Graft patency at 6 months	6-month MACCE	2-year freedom from MACCE	2-year survival	10-year survival	10-year freedom from MACCE
Ruel et al., 2013 ^[36]	89	5 (6%)	151/165 grafts (92%)	0	-	-	-	-
Liang et al., 2022 ^[41,42]	172	-	401/436 grafts (92%)	3 (1.7%)	166 (96.5%)	167 (97.0%)	-	-
Guo et al., 2021 ^[65]	510	-	-	-	-	-	90.3 ± 2.1%	87.2 ± 2.1%

MI: Myocardial infarction; CVA: cerebrovascular accident; MACCE: major adverse cardiac or cerebrovascular events.

Table 4. Long-term functional results with MICS CABG

Author, year	At 12 years (n = 566)			At the time of cross-sectional functional follow-up (n = 427)				Incisional issues limiting daily activities
	Survival	Freedom from MACCE	Cumulative incidence of repeat revascularization	Any angina	Any dyspnea	Chronic incisional pain	Any incisional numbness/hypersensitivity	
Guo et al., 2023 ^[18]	82.2 ± 2.6%	75.5 ± 2.0%	14.8 ± 2.5%	53 (12.4%)	115 (26.9%)	7 (1.6%)	27 (6.3%)	2 (0.5%)

MACCE: Major adverse cardiac or cerebrovascular events.

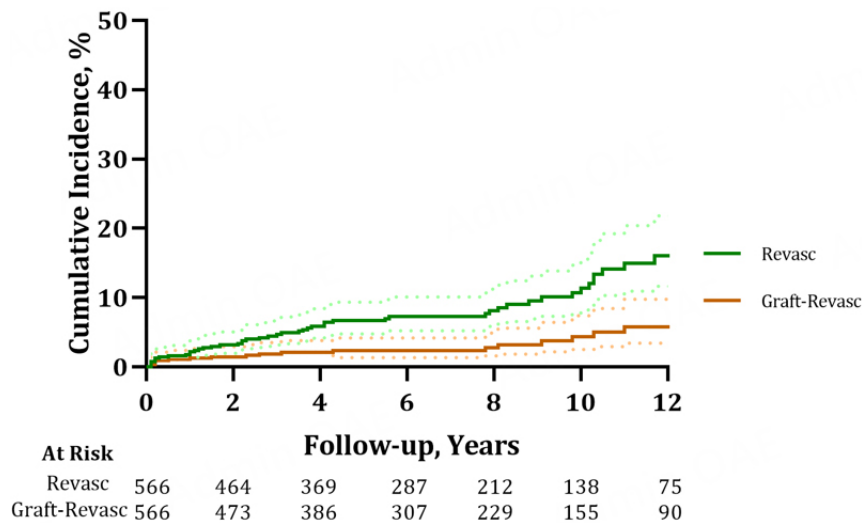


Figure 6. Repeat revascularization and repeat revascularization for graft failure cumulative incidence for patients who underwent minimally invasive coronary artery bypass grafting, accounting for death as a competing risk. Confidence Interval: 95%; Revasc: repeat revascularization; Graft-Revasc: revascularization for graft failure^[18].

MVr group did have improved functional outcomes at 6 weeks. The primary outcome revealed there was no significant difference in the outcome 12 weeks postoperatively. They reported similar outcomes and durability between the MVr performed by sternotomy or thoracotomy at 1 year postoperatively. These results demonstrate the effectiveness and safety of minimally invasive MVr surgery with improved physical functioning at 6 weeks postoperatively, but not at 12 weeks. Early improvement in functioning potentially

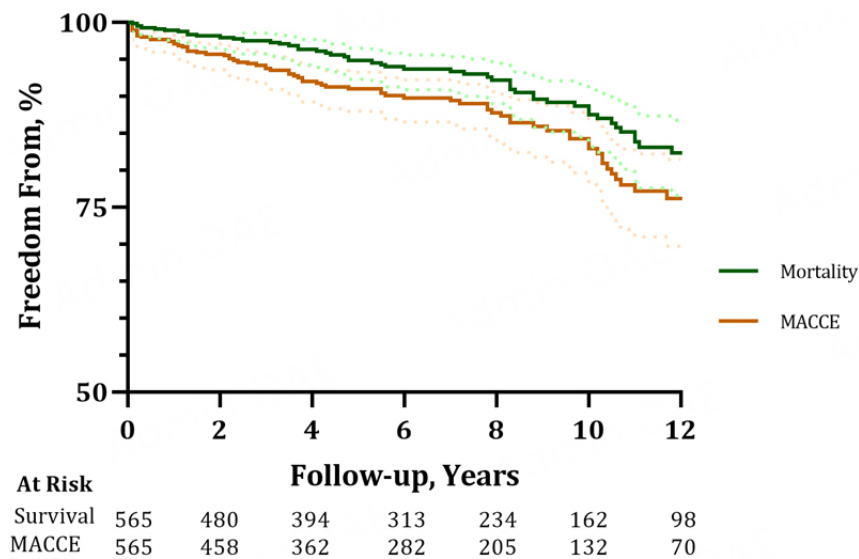


Figure 7. Freedom from all-cause mortality or MACCE for patients who underwent MICS CABG in a 12-year period. Confidence Interval: 95%; MACCE: major adverse cardiac and cerebrovascular events; MICS CABG: minimally invasive coronary artery bypass grafting^[18].

reduces the physical and emotional burden that is associated with major surgeries. However, a multicentered randomized control trial comparing CABG outcomes is still required before suggesting these MVr outcomes are transferable.

ADOPTING MICS CABG

Since its introduction in 2009, MICS CABG has gained popularity and the feasibility of its implementation has been analyzed^[17]. The technical adoption of MICS CABG involves a sequential progression^[47-49]. First, the surgeon must be fully comfortable and competent in performing OPCAB. Next, the surgeon will receive training to perform MIDCAB, a sternum-sparing incision alternative to graft the LITA to the LAD. Combining these two skill modalities, the surgeon then will gain confidence performing increasingly technically difficult anastomoses, including the left-sided vessels, LAD, Ramus, first obtuse marginal artery (OM1), then the second obtuse marginal artery (OM2). Access to the remaining territories of the heart, and a similar anatomical configuration to that of a sternotomy, are achieved when the surgeon can graft the posterior descending artery (PDA) and the left ventricular branch of the right coronary artery (RCA).

Though the risks of on-pump surgery have been established, there has been debate on OPCAB's feasibility and efficacy as an alternative^[50]. With a beating heart, the bypass surgery is more technically demanding and some concerns about graft patency have been reported, especially concerning incomplete revascularization rates^[51,52]. These concerns have been refuted by recent evidence showing the comparable long-term patency of grafts performed off-pump and on-pump^[53]. This long-standing controversy may, in part, be due to the influence of institutions and individual surgeons have on outcome^[50]. In patients requiring more than one graft, off-pump CABG increased the risk-adjusted mortality when performed in low-volume centers by low-volume individuals, in comparison to on-pump^[54]. However, in high volume-centers, OPCAB has been shown to reduce perioperative mortality and morbidity^[54], and has especially superior short-term outcomes compared to on-pump CABG^[28,52-55].

In 2013, Une *et al.* studied the learning curve by comparing clinical events from the first 25 patients in 200 consecutive patients who underwent MICS CABG procedures by the same surgeon^[56]. In this study,

experience was correlated with operative time for off-pump procedures, but not pump-assisted procedures. The use of pump assistance may be employed to alleviate some of the learning curve's adverse effects before reaching learning period optimization, calculated to be 45 cases^[56]. The learning curve, as shown by Rodriguez *et al.* (2016), is the most common factor causing a conversion from a minimally invasive to a conventional CABG approach^[57]. Increased exposure to the procedure reduced difficulties with conduit harvest and anastomoses and concomitantly increased freedom from conversion to sternotomy^[57]. Mid-term follow-up of MICS CABG patients found the overall procedural safety was not affected by the learning period; instead, with increased exposure to the procedure, they observed improved freedom from conversion to sternotomy and from repeat revascularization^[58]. This phenomenon was further enforced in 2018 by Andrawes *et al.*^[59].

With the implementation of a new procedure, the cost of health care is an important factor to consider. Patients who experience complications associated with CABG surgery may require a longer hospitalization period and consume more healthcare resources^[60,61]. A multi-institutional analysis found that MICS CABG approaches were associated with fewer transfusions, shorter intensive care unit stays, and shorter hospital lengths of stay than conventional CABG patients. MICS CABG patients used fewer healthcare resources and, on average, saved \$7,000 USD compared to conventional CABG patients. Both the conventional CABG and MICS CABG patients were linked with excellent short-term outcomes^[62]. However, others have called into question whether this research was successful in comparing the groups as the baseline characteristics between the groups were not well matched: the MICS CABG patients were lower risk and had, on average, fewer grafts which created inherent bias^[63]. That said, short-term outcomes from other trials are consistent with MICS CABG patients spending less time in the ICU and hospital^[17,20]. Further research is required to explore the correlation between MICS CABG and associated costs to definitively suggest that MICS CABG has an economic advantage and improved resource utilization over conventional CABG.

In our experience, the implementation of MICS CABG at our institution involved not just adopting a novel approach to surgical revascularization, but also innovating matched perioperative management. This evolution towards the delivery of minimally invasive CABG is predicated on recognizing the importance of multi-disciplinary collaboration to achieve patient care, with individualization of care prioritized over protocols. The key features of perioperative optimization are outlined by Ponnambalam and Alex^[64]. Patient education, discharge planning, and medical optimization are offered strategically prior to admission. Multimodal analgesia specific to thoracotomy - including the use of intercostal and fascial plane block, acetaminophen, gabapentinoid, opioids, and nonsteroid anti-inflammatory drugs - are administered perioperatively^[38]. Early feeding and a program for early mobilization are also recommended to enhance the patient's functional recovery after surgery to facilitate rapid discharge. The implementation of a MICS CABG program goes beyond satisfactory clinical outcomes, as it has the potential to improve the patient experience by resulting in earlier normalization and return to work. In unpublished internal quality assurance data from our center, an appreciable decrease in the length of hospital stay has been observed in patients undergoing MICS CABG since the adoption of the aforementioned strategies in 2020. Additionally, reduced ICU and hospital length of stays has a positive implication for organizational flow and capacity.

Future directions should continue to include research that encompasses patient-specific and functional outcomes; patient satisfaction and quality-of-life data should be reported in conjunction with clinical outcomes. The literature indicates that MICS CABG, and associated less invasive procedures, have significant potential to improve care for patients on a global scale.

CONCLUSION

In the literature, MICS CABG has been consistently shown to be a durable, safe, and feasible alternative to sternotomy CABG. With favorable early outcomes, comparable long-term outcomes and graft patency, and the feasibility of its implementation, MICS CABG is an exciting development in the field of cardiac surgery. It is a safe, learnable, effective, full-revascularization non-sternotomy CABG operation that requires proficiency with OPCAB and MIDCAB prior to being undertaken. Multicenter, prospective randomized control trials are underway and will help establish MICS CABG as a standard treatment for patients afflicted with CAD.

DECLARATIONS

Authors' contributions

Made substantial contributions to the conception and design of the study: Ashenhurst C, Toubar O, Ruel M
Guidance and recommendations on this review: Guo M, Issa H, Ponnambalam M
Contributed significantly to the content and meet the ICMJE criteria: All authors
Read and approved the final submission: All authors

Availability of data and materials

Not applicable.

Financial support and sponsorship

None.

Conflicts of interest

Dr. Ruel M is a MICS CABG proctor and PI for the MIST trial (both with support from Medtronic, Inc.). All other authors declared that there are no conflicts of interest.

Ethical approval and consent to participate

There is no original human research data in this paper. Prior review of surgical and medical records was performed under Research Ethics Approval from the University of Ottawa Heart Institute.

Consent for publication

All patients gave explicit consent for their photo to be included in this review.

Copyright

© The Author(s) 2024.

REFERENCES

1. Cardiovascular diseases (CVDs). Available from: [https://www.who.int/news-room/fact-sheets/detail/cardiovascular-diseases-\(cvds\)](https://www.who.int/news-room/fact-sheets/detail/cardiovascular-diseases-(cvds)) [Last accessed on 10 Jan 2024].
2. Carrel A VIII. On the experimental surgery of the thoracic aorta and heart. *Ann Surg* 1910;52:83-95. DOI PubMed PMC
3. Kolesov VI, Potashov LV. [Surgery of coronary arteries]. *Eksp Khir Anesteziol* 1965;10:3-8. PubMed
4. Writing Committee Members; Lawton JS, Tamis-Holland JE, et al. 2021 ACC/AHA/SCAI guideline for coronary artery revascularization: a report of the american college of cardiology/American heart association joint committee on clinical practice guidelines. *J Am Coll Cardiol* 2022;79:e21-129. DOI
5. Head SJ, Milojevic M, Taggart DP, Puskas JD. Current practice of state-of-the-art surgical coronary revascularization. *Circulation* 2017;136:1331-45. DOI PubMed
6. Bachar BJ, Manna B. Coronary artery bypass graft. 2023. Available from: <http://www.ncbi.nlm.nih.gov/books/NBK507836/> [Last accessed on 10 Jan 2024].
7. Coronary artery bypass graft (CABG) rate. Available from: <https://www.cihi.ca/en/indicators/coronary-artery-bypass-graft-cabg-rate> [Last accessed on 10 Jan 2024].
8. van Gulik L, Janssen LI, Ahlers SJ, et al. Risk factors for chronic thoracic pain after cardiac surgery via sternotomy. *Eur J Cardiothorac Surg* 2011;40:1309-13. DOI

9. Whitlock RP, Devereaux PJ, Teoh KH, et al. Methylprednisolone in patients undergoing cardiopulmonary bypass (SIRS): a randomised, double-blind, placebo-controlled trial. *Lancet* 2015;386:1243-53. [DOI](#)
10. Day JR, Taylor KM. The systemic inflammatory response syndrome and cardiopulmonary bypass. *Int J Surg* 2005;3:129-40. [DOI](#) [PubMed](#)
11. Dieberg G, Smart NA, King N. Minimally invasive cardiac surgery: a systematic review and meta-analysis. *Int J Cardiol* 2016;223:554-60. [DOI](#) [PubMed](#)
12. Hillis LD, Smith PK, Anderson JL, et al. 2011 ACCF/AHA guideline for coronary artery bypass graft surgery: a report of the american college of cardiology foundation/American heart association task force on practice guidelines. *Circulation* 2011;124:e652-735. [DOI](#)
13. Ruel M, Williams A, Ouzounian M, et al. Missing the goal with the 2021 ACC/AHA/SCAI Guideline for coronary artery revascularization. *Can J Cardiol* 2022;38:705-8. [DOI](#)
14. Yadava OP, Narayan P, Padmanabhan C, et al. IACTS position statement on “2021 ACC/AHA/SCAI guideline for coronary artery revascularization”: section 7.1-a consensus document. *Indian J Thorac Cardiovasc Surg* 2022;38:126-33. [DOI](#) [PubMed](#) [PMC](#)
15. Yusuf S, Zucker D, Peduzzi P, et al. Effect of coronary artery bypass graft surgery on survival: overview of 10-year results from randomised trials by the coronary artery bypass graft surgery trialists collaboration. *Lancet* 1994;344:563-70. [DOI](#)
16. Al-Atassi T, Toeg H, Chan V, Ruel M. Coronary artery bypass grafting. In: *Surgery of the chest*, 9th ed. The Netherlands: Elsevier; 2016, pp. 1551-79.
17. McGinn JT Jr, Usman S, Lapierre H, Pothula VR, Mesana TG, Ruel M. Minimally invasive coronary artery bypass grafting: dual-center experience in 450 consecutive patients. *Circulation* 2009;120:S78-84. [DOI](#) [PubMed](#)
18. Guo MH, Toubar O, Issa H, et al. Long-term survival, cardiovascular, and functional outcomes after minimally invasive coronary artery bypass grafting in 566 patients. *J Thorac Cardiovasc Surg* 2023;S0022-5223(23)00652-9. [DOI](#)
19. Nantsios A, Elmistekawy E, Ponnambalam M, Lambert AS, Ruel M. Minimally invasive coronary artery bypass grafting in a patient with chronic tracheostoma: alternative to reduce sternal wound complication risk. *Innovations* 2022;17:574-6. [DOI](#) [PubMed](#) [PMC](#)
20. Lapierre H, Chan V, Sohmer B, Mesana TG, Ruel M. Minimally invasive coronary artery bypass grafting via a small thoracotomy versus off-pump: a case-matched study. *Eur J Cardiothorac Surg* 2011;40:804-10. [DOI](#)
21. Calafiore AM, Giammarco GD, Teodori G, et al. Left anterior descending coronary artery grafting via left anterior small thoracotomy without cardiopulmonary bypass. *Ann Thorac Surg* 1996;61:1658-65. [DOI](#)
22. Marin-Cuartas M, Sá MP, Torregrossa G, Davierwala PM. Minimally invasive coronary artery surgery: robotic and nonrobotic minimally invasive direct coronary artery bypass techniques. *JTCVS Tech* 2021;10:170-7. [DOI](#) [PubMed](#) [PMC](#)
23. Shen L, Hu S, Wang H, et al. One-stop hybrid coronary revascularization versus coronary artery bypass grafting and percutaneous coronary intervention for the treatment of multivessel coronary artery disease: 3-year follow-up results from a single institution. *J Am Coll Cardiol* 2013;61:2525-33. [DOI](#)
24. Rabindranauth P, Burns JG, Vessey TT, Mathiason MA, Kallies KJ, Paramesh V. Minimally invasive coronary artery bypass grafting is associated with improved clinical outcomes. *Innovations* 2014;9:421-6. [DOI](#) [PubMed](#)
25. Hedberg M, Boivie P, Engström KG. Early and delayed stroke after coronary surgery - an analysis of risk factors and the impact on short- and long-term survival. *Eur J Cardiothorac Surg* 2011;40:379-87. [DOI](#)
26. Albert A, Ennker J, Hegazy Y, et al. Implementation of the aortic no-touch technique to reduce stroke after off-pump coronary surgery. *J Thorac Cardiovasc Surg* 2018;156:544-54.e4. [DOI](#)
27. Ziankou A, Ostrovsky Y. Early and midterm results of no-touch aorta multivessel small thoracotomy coronary artery bypass grafting: a propensity score-matched study. *Innovations* 2015;10:258-67. [DOI](#) [PubMed](#)
28. Seki T, Yoshida T. Comparison of Mid-term graft patency between on-pump and off-pump coronary artery bypass grafting. *Ann Thorac Cardiovasc Surg* 2017;23:141-8. [DOI](#) [PubMed](#) [PMC](#)
29. Farkouh ME, Domanski M, Sleeper LA, et al. Strategies for multivessel revascularization in patients with diabetes. *N Engl J Med* 2012;367:2375-84. [DOI](#)
30. Ridderstolpe L, Gill H, Granfeldt H, Ahlfeldt H, Rutberg H. Superficial and deep sternal wound complications: incidence, risk factors and mortality. *Eur J Cardiothorac Surg* 2001;20:1168-75. [DOI](#) [PubMed](#)
31. Jonkers D, Elenbaas T, Terporten P, Nieman F, Stobberingh E. Prevalence of 90-days postoperative wound infections after cardiac surgery. *Eur J Cardiothorac Surg* 2003;23:97-102. [DOI](#) [PubMed](#)
32. Lemaignan A, Birgand G, Ghodhbane W, et al. Sternal wound infection after cardiac surgery: incidence and risk factors according to clinical presentation. *Clin Microbiol Infect* 2015;21:674.e11-8. [DOI](#)
33. Gudbjartsson T, Jeppsson A, Sjögren J, et al. Sternal wound infections following open heart surgery - a review. *Scand Cardiovasc J* 2016;50:341-8. [DOI](#)
34. Arribas-Leal JM, Rivera-Caravaca JM, Hernández-Torres A, et al. Incidence and predictors of sternal surgical wound infection in cardiac surgery: a prospective study. *Int Wound J* 2023;20:917-24. [DOI](#) [PubMed](#) [PMC](#)
35. Hernandez R, Lehr EJ. Mortality following deep sternal wound infection-not just a short-term complication? *Eur J Cardiothorac Surg* 2021;60:242-3. [DOI](#) [PubMed](#)
36. Ruel M, Shariff MA, Lapierre H, et al. Results of the minimally invasive coronary artery bypass grafting angiographic patency study. *J Thorac Cardiovasc Surg* 2013;147:203-9. [DOI](#)
37. Walther T, Falk V, Metz S, et al. Pain and quality of life after minimally invasive versus conventional cardiac surgery. *Ann Thorac Surg* 1999;67:1643-7. [DOI](#)

38. Sherazee EA, Chen SA, Li D, Li D, Frank P, Kiaii B. Pain management strategies for minimally invasive cardiothoracic surgery. *Innovations* 2022;17:167-76. DOI
39. Karmakar MK, Ho AM. Postthoracotomy pain syndrome. *Thorac Surg Clin* 2004;14:345-52. DOI PubMed
40. Guo MH, Wells GA, Glineur D, et al. Minimally Invasive coronary surgery compared to STernotomy coronary artery bypass grafting: the MIST trial. *Contemp Clin Trials* 2019;78:140-5. DOI
41. Liang L, Liu JJ, Kong QY, et al. Comparison of early outcomes associated with coronary artery bypass grafting for multi-vessel disease conducted using minimally invasive or conventional off-pump techniques: a propensity-matched study based on SYNTAX score. *J Cardiothorac Surg* 2022;17:144. DOI PubMed PMC
42. Liang L, Ma X, Kong Q, et al. Comparing patient outcomes following minimally invasive coronary artery bypass grafting surgery vs. coronary artery bypass grafting: a single-center retrospective cohort study. *Cardiovasc Diagn Ther* 2022;12:378-88. DOI PubMed PMC
43. Baishya J, George A, Krishnamoorthy J, Muniraju G, Chakravarthy M. Minimally invasive compared to conventional approach for coronary artery bypass grafting improves outcome. *Ann Card Anaesth* 2017;20:57-60. DOI PubMed PMC
44. McGinn JT, Shariff M, Lapierre H, Sohmer B, Goyal N, Ruel M. Abstract 18959: minimally invasive CABG: results to 6 years. *Circulation* 2012;126:A18959. Available from: https://www.ahajournals.org/doi/abs/10.1161/circ.126.suppl_21.a18959 [Last accessed on 10 Jan 2024]
45. Ruel M, Shariff M, Lapierre H, Sohmer B, McGinn J. 254 mid-term results of 800 minimally invasive coronary bypass operations. *Can J Cardiol* 2012;28:S186. DOI
46. Akowuah EF, Maier RH, Hancock HC, et al. Minithoracotomy vs conventional sternotomy for mitral valve repair: a randomized clinical trial. *JAMA* 2023;329:1957-66. DOI
47. Issa HMN, Ruel M. Beating heart multi-vessel minimally invasive direct coronary artery bypass grafting: techniques and pitfalls. *J Vis Surg* 2023;9:5. DOI
48. Ruel M. Commentary: sternotomy for every cardiac surgery patient ain't the future, so let's get going. *J Thorac Cardiovasc Surg* 2023;165:129-31. DOI
49. Qureshi SH, Ruel M. The 7 pillars of multivessel minimally invasive coronary surgery. *Innovations* 2021;16:216-7. DOI PubMed PMC
50. Gaudino M, Angelini GD, Antoniadis C, et al. Off-pump coronary artery bypass grafting: 30 years of debate. *J Am Heart Assoc* 2018;7:e009934. DOI PubMed PMC
51. Shaefi S, Mittel A, Loberman D, Ramakrishna H. Off-pump versus on-pump coronary artery bypass grafting-a systematic review and analysis of clinical outcomes. *J Cardiothorac Vasc Anesth* 2019;33:232-44. DOI PubMed
52. Ivanov J, Borger MA, Tu JV, Rao V, David TE. Mid-term outcomes of off-pump versus on-pump coronary artery bypass graft surgery. *Can J Cardiol* 2008;24:279-84. DOI PubMed PMC
53. Yang L, Lin S, Zhang H, et al. Long-term graft patency after off-pump and on-pump coronary artery bypass: a coronary trial cohort. *Ann Thorac Surg* 2020;110:2055-61. DOI
54. Benedetto U, Lau C, Caputo M, et al. Comparison of outcomes for off-pump versus on-pump coronary artery bypass grafting in low-volume and high-volume centers and by low-volume and high-volume surgeons. *Am J Cardiol* 2018;121:552-7. DOI
55. Kuss O, von Salviati B, Börgermann J. Off-pump versus on-pump coronary artery bypass grafting: a systematic review and meta-analysis of propensity score analyses. *J Thorac Cardiovasc Surg* 2010;140:829-35, 835.e1-13. DOI PubMed
56. Une D, Lapierre H, Sohmer B, Rai V, Ruel M. Can minimally invasive coronary artery bypass grafting be initiated and practiced safely? Learning curve of small thoracotomy CABG. *Can J Cardiol* 2013;29:S250-1. DOI
57. Rodriguez ML, Lapierre HR, Sohmer B, Ruel JP, Ruel MA. Predictors and outcomes of sternotomy conversion and cardiopulmonary bypass assistance in minimally invasive coronary artery bypass grafting. *Innovations* 2016;11:315-20. DOI PubMed
58. Rodriguez ML, Lapierre HR, Sohmer B, Glineur D, Ruel M. Mid-term follow-up of minimally invasive multivessel coronary artery bypass grafting: is the early learning phase detrimental? *Innovations* 2017;12:116-20. DOI PubMed
59. Andrawes PA, Shariff MA, Nabagiez JP, et al. Evolution of minimally invasive coronary artery bypass grafting: learning curve. *Innovations* 2018;13:81-90. DOI
60. Brown PP, Kugelmass AD, Cohen DJ, et al. The frequency and cost of complications associated with coronary artery bypass grafting surgery: results from the United States Medicare program. *Ann Thorac Surg* 2008;85:1980-6. DOI
61. Chen JC, Kaul P, Levy JH, et al. Myocardial infarction following coronary artery bypass graft surgery increases healthcare resource utilization. *Crit Care Med* 2007;35:1296-301. DOI
62. Teman NR, Hawkins RB, Charles EJ, et al. Minimally invasive vs open coronary surgery: a multi-institutional analysis of cost and outcomes. *Ann Thorac Surg* 2021;111:1478-84. DOI
63. Jahangiri M, Mani K, Nowell J. Does minimally invasive coronary artery surgery have prognostic and cost benefits? *Ann Thorac Surg* 2022;114:609-10. DOI PubMed
64. Ponnambalam M, Alex RM. Preoperative optimization and rapid discharge after coronary artery bypass grafting. *Curr Opin Cardiol* 2023;38:471-7. DOI PubMed
65. Guo MH, Vo TX, Horsthuis K, et al. Durability of minimally invasive coronary artery bypass grafting. *J Am Coll Cardiol* 2021;78:1390-1. DOI