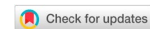

Original Article

Open Access



Gastric cancer treated with pressurized intraperitoneal aerosol chemotherapy: revising an option for peritoneal carcinomatosis

Filipa Macedo¹, Kátia Ladeira^{2,3,4}, Adhemar Longatto-Filho^{3,4,5,6}, Sandra F. Martins^{3,4,7}

¹Portuguese Oncology Institute-Coimbra, Coimbra 3000-075, Portugal.

²Portuguese Oncology Institute-Lisbon, Lisbon 1099-023, Portugal.

³Life and Health Science Research Institute, School of Health Sciences, University of Minho, Braga 4710-057, Portugal.

⁴ICVS/3B's-PT Government Associate Laboratory, Braga/Guimarães, Braga 4710-057, Portugal.

⁵Molecular Oncology Research Center, Barretos Cancer Hospital, Barretos, São Paulo 14784-400, Brazil.

⁶Laboratory of Medical Investigation 14, Faculty of Medicine, University of São Paulo, São Paulo 01246-903, Brazil.

⁷Surgery Department, Coloproctology Unit, Braga Hospital, Braga 4710-243, Portugal.

Correspondence to: Dr. Sandra F. Martins, Life and Health Science Research Institute, School of Health Sciences, University of Minho, Braga 4710-057, Portugal. E-mail: sandramartins@med.uminho.pt

How to cite this article: Macedo F, Ladeira K, Longatto-Filho A, Martins SF. Gastric cancer treated with pressurized intraperitoneal aerosol chemotherapy: revising an option for peritoneal carcinomatosis. *J Cancer Metastasis Treat* 2018;4:8. <http://dx.doi.org/10.20517/2394-4722.2017.72>

Received: 7 Nov 2017 **First Decision:** 28 Dec 2017 **Revised:** 19 Jan 2018 **Accepted:** 22 Jan 2018 **Published:** 9 Feb 2018

Science Editor: Masayuki Watanabe **Copy Editor:** Jun-Yao Li **Production Editor:** Huan-Liang Wu

Abstract

Aim: Gastric cancer is the cancer with the highest rate of peritoneal metastization and this type of spread is associated with a higher death rate compared to distant organ metastasis. The systemic chemotherapy has a minimal effect in peritoneal metastasis so new types of treatment have emerged. The authors revised the main studies done in pressurized intraperitoneal aerosol chemotherapy (PIPAC) and presented the main conclusions.

Methods: A PubMed search was conducted focusing on PIPAC in gastric cancer. The MeSH database was searched with the terms: "Gastric cancer [MeSH] and intraperitoneal aerosol chemotherapy".

Results: Seven studies were analyzed. All the studies performed the technique with aerosol of doxorubicin and cisplatin. All cases were well tolerated, with minor adverse effects. Patients presented resolution of their abdominal symptoms and regression of macroscopic carcinomatosis. Cytoreductive surgery or hypertermic intraperitoneal chemotherapy could be performed in some patients with good response to PIPAC. The peritonitis caused by the chemotherapy was well tolerated.

Conclusion: PIPAC can induce remission in end-stage and resistant disease with acceptable side effects, good safety levels for patients and health professionals, and quality of life improvement.



© The Author(s) 2018. **Open Access** This article is licensed under a Creative Commons Attribution 4.0 International License (<https://creativecommons.org/licenses/by/4.0/>), which permits unrestricted use, sharing, adaptation, distribution and reproduction in any medium or format, for any purpose, even commercially, as long as you give appropriate credit to the original author(s) and the source, provide a link to the Creative Commons license, and indicate if changes were made.



Keywords: Pressurized intraperitoneal aerosol chemotherapy, gastric cancer, peritoneal carcinomatosis

INTRODUCTION

Gastric cancer accounts for 6.8% of all cancers and it is the fifth most common cancer worldwide. Moreover, it is the third leading cause of death associated with cancer^[1]. Gastric cancer has three ways to spread through the body: neoplastic cells could use the lymphatic system to spread to the lymph nodes, the blood stream to spread to distant organs, and the dissemination to peritoneal cavity. This last type of spread is called peritoneal metastatization. Gastric cancer is the cancer with the highest rate of peritoneal metastization and this type of spread is associated with a higher death rate compared to distant organ metastasis^[2]. Without treatment, the median survival of these patients is 3-5 months.

Gastrectomy combined with D2 lymph node dissection remains the standard of care to manage gastric cancer in advanced stages, however, peritoneal metastases still needs to be optimized. The systemic chemotherapy has a minimal effect in peritoneal metastasis because the barrier between blood and peritoneum do not allow a high concentration of drug in the peritoneum^[3]. An alternative to systemic chemotherapy consists in surgical removal of affected tissue combined with perioperative chemotherapy that includes: extensive intraoperative peritoneal lavage, neoadjuvant intraperitoneal/systemic chemotherapy, hypertermic intraperitoneal chemotherapy (HIPEC), laparoscopic HIPEC and early postoperative intraperitoneal chemotherapy. The problems with these techniques are the need of complete cytoreduction in surgery and they are appropriate only for selected patients^[4]. Moreover, this treatment is hindered by significant risks and side effects with a 30-day mortality rate of 5% in referral centers^[5].

Recently, a new alternative therapy has emerged: pressurized intraperitoneal aerosol chemotherapy (PIPAC). This method can only be applied by laparoscopy and it is performed under general anesthesia. In this case, the chemotherapy is dispersed as pressurized aerosol into the peritoneal cavity by minimal invasive techniques, and left acting during 30 min. After this time, the gas is aspired. The recommendation is 3 applications within 3 months. The most frequent adverse effects are fever, abdominal pain and nausea. Complications like infections, herniation or adhesion are uncommon due to minimally-invasive procedure [Figure 1].

METHODS

A PubMed search was conducted focusing on PIPAC in gastric cancer. The MeSH database was searched with the terms: “Gastric cancer [MeSH] and intraperitoneal aerosol chemotherapy”.

A total of 5 articles were collected. One study was excluded because it is written in Chinese. Then, 3 articles were added because they were recent and pertinent. Ultimately, 7 studies were included in the analysis.

RESULTS

The main results of the studies are listed in Table 1^[6-12].

Nadiradze *et al.*^[6] demonstrated that PIPAC is well tolerated but has no effect in patients with synchronous malignant pleural effusion. Twenty-four patients were included in the study, and 60 PIPAC were performed: 71% of the patients had repeated the procedure; no procedure-related mortality was reported; the mean survival time was 15.4 months; and objective tumor response was observed in 50% of the patients.

Hübner *et al.*^[7] had used as exclusion criteria for PIPAC the thrombosis of portal vein, intestinal occlusion and some clinical condition that could be a contra-indication for capnoperitoneum. Fifty-eight patients

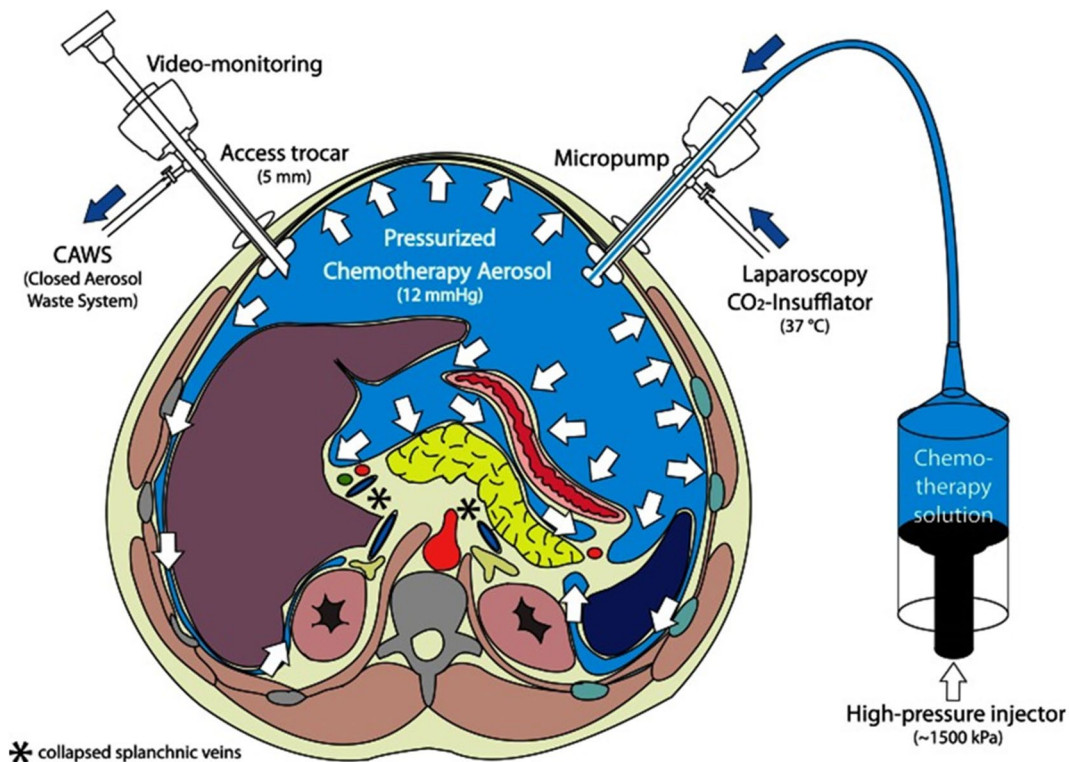


Figure 1. Pressurized intraperitoneal aerosol chemotherapy (PIPAC). Two trocars are inserted into the peritoneal cavity; then CO₂ is insufflated in a pressure of 12 mmHg. Small tissue samples of the tumor are retrieved (biopsy). Then, the chemotherapy is dispersed as pressurized aerosol inside the peritoneal cavity. At the end of the procedure (30 min), the gas is released over a closed aerosol waste system (CAWS)

were included and 127 PIPAC procedures were performed. One PIPAC was excluded due to incidental small bowel injury.

Tempfer^[8] reported some studies, only one with gastric cancer patients. The main emphasis was ovarian cancer. The reported gastric cancer patient was the same patient described in Solass *et al.*^[9] study.

Solass *et al.*^[9] followed 3 patients, 1 with gastric cancer, 1 with ovarian cancer and 1 with appendix cancer. In the gastric cancer patient, an early hospital discharge was possible and no severe side effects were observed. Globally, 2 patients showed a complete histological remission and 1 showed a partial remission. It was observed a mean survival of 288 days.

Teixeira Farinha *et al.*^[10] followed 42 patients that underwent PIPAC and evaluated their quality of life during the treatment time and main symptoms.

Girshally *et al.*^[11] performed PIPAC in patients with colorectal cancer, appendiceal cancer, ovarian cancer, peritoneal mesothelioma and pseudomyxoma peritoneal as a neoadjuvant treatment in peritoneal metastasis not eligible for cytoreductive surgery and HIPEC. The gastric cancer patients have no extensive peritoneal disease so they were not included.

Alyami *et al.*^[12] evaluated the postoperative outcome of 164 procedures of PIPAC using the peritoneal cancer index.

DISCUSSION

Intraperitoneal chemotherapy is associated to local toxicity due to high drug concentration in peritoneal cavity and the repeated delivery, which leads to chemical peritonitis and a systemic inflammatory response.

Table 1. Main conclusions of the studies

Authors	Year	Patients	Aerosol	Conclusion
Nadiradze <i>et al.</i> ^[6]	2016	24 patients with peritoneal metastases from gastric cancer resistant to systemic chemotherapy and with no option for cytoreductive surgery and HIPEC	Doxorubicin 1.5 mg/m ² followed by cisplatin 7.5 mg/m ²	Follow-up: 248 days; median survival time: 15.4 months; survival after follow-up time: 13 patients; objective tumor response in 12 patients; complete histological regression in 6 patients
Hübner <i>et al.</i> ^[7]	2017	58 patients with peritoneal disease from digestive cancer that was persistent or progressive after prior standard surgical and/or medical treatment	Doxorubicin 1.5 mg/m ² in combination with cisplatin 7.5 mg/m ²	Intraoperative event rate: 11%; deaths after the procedure: 1 patient
Tempfer ^[8]	2015	1 patient with peritoneal disease from gastric cancer after gastrectomy and 2 chemotherapy lines	Doxorubicin 1.5 mg/m ² with cisplatin 7.5 mg/m ²	Survival of 109 days; the patient developed liver and bone metastases but with no evidence of peritoneal metastases
Solass <i>et al.</i> ^[9]	2014			PIPAC had no negative impact on patients' overall quality of life or in main symptoms; there was no worse quality of life in PIPAC patients with high intraperitoneal tumor load
Teixeira Farinha <i>et al.</i> ^[10]	2017	42 patients: 21 patients with chemoresistant isolated peritoneal carcinomatosis from gynecological origin, 14 patients from colorectal origin and 3 from gastric origin	Not mentioned	7 patients obtained objective radiological tumor regression; 8 patients obtained objective major histological regression
Girshally <i>et al.</i> ^[11]	2016	9 patients with advanced peritoneal disease no candidates for primary cytoreductive surgery and HIPEC	Doxorubicin 1.5 mg/m ² followed by cisplatin 7.5 mg/m ²	63.5% of patients presented complete regression of symptoms; peritoneal cancer index improved in 64.5% of patients
Alyami <i>et al.</i> ^[12]	2017	73 patients with non-resectable peritoneal carcinomatosis (26 from gastric cancer)	Cisplatin 7.5 mg/m ² followed by doxorubicin 1.5 mg/m ²	

PIPAC: pressurized intraperitoneal aerosol chemotherapy; HIPEC: hyperthermic intraperitoneal chemotherapy

No significant renal toxicity was documented in these studies, however a low-grade liver toxicity was reported in a quarter of patients in Nadiradze *et al.*^[6] study.

Hübner *et al.*^[7] concluded that no learning curve was observed because the operation time did not decrease over time. Some minor complications were observed during this study such as constipation, ileus, transitory neutropenia, urinary retention and wound complications. Looking to these effects, the procedure seems to be safe. Only one patient died due to cardiac arrhythmia.

Tempfer *et al.*^[8] reported that delivering chemotherapy as an aerosol did not represent a risk to health care workers so, it could be used safely in the clinical setting. Moreover, the quality of life improved over 5-6 months.

Solass *et al.*^[9] achieved 2 complete remissions and all 3 cases had tumor response. The mean survival of the 3 patients was 288 days, and the gastric cancer patients died 109 days after the procedure.

Teixeira Farinha *et al.*^[10] concluded that PIPAC had no undesirable impact on quality of life of patients with peritoneal carcinomatosis. A shorter hospital stay was associated with patients with better scores at baseline in quality of life. Nondigestive and digestive symptoms remained unchanged after repeated treatments.

Girshally *et al.*^[11] concluded that patients with extensive peritoneal disease that were treated with PIPAC as neoadjuvant therapy had worse prognosis than those treated primarily with cytoreductive surgery and HIPEC in limited disease. However, when the cytoreductive surgery and HIPEC were not possible due to extensive disease, PIPAC was successful in diminishing the tumor burden and allowed forward procedures.

Alyami *et al.*^[12] found that symptoms related to peritoneal carcinomatosis like ascites, pain or transit disorders were decreased during PIPAC. Some major complications occurred in 9.7% of the patients and 5 died within 30 days of the PIPAC procedure.

Searching in the ClinicalTrials.gov registry, we found 1 clinical trial completed in Germany (PIPAC-GA01), but 4 more trials recruiting: 1 in Italy, 1 in Singapore, 1 in Germany and the last 1 in 14 countries. PIPAC-GA01 is a clinical trial with 35 patients where cisplatin and doxorubicin will be applied in 3 single doses in 6 weeks intervals. The safety and efficacy in terms of the clinical benefit rate will be accessed, but no results were published yet.

At this stage, it is not possible to define indications and contraindications for PIPAC. The authors think that this method could be a good option for patients who have done systemic chemotherapy with severe side effects, patients with renal failure, hepatic failure or patients with cardiac toxicity. On the other hand, it is no option for patients with end-stage disease or malignant pleural effusion.

PIPAC was tested mainly in ovarian cancer, gastric cancer and colon cancer, and it seems feasible in most patients with refractory carcinomatosis of various origins. There were no consistent studies comparing what type of cancer will benefit the most with this technique.

This procedure could be a new palliative treatment option because it may increase quality of life. The next step should be the appliance of this technique in patients in an early stage of peritoneal carcinomatosis to access the efficacy.

DECLARATIONS

Authors' contributions

Concept and design of the review, article analysis and interpretation: all authors

Drafting the manuscript: Macedo F, Ladeira K

Manuscript revising: Longatto-Filho A, Martins SF

Approved the final version to be published: all authors

Data source and availability

All the information analysed during the current study are available in the Pubmed Repository (<https://www.ncbi.nlm.nih.gov/pubmed/>).

Financial support and sponsorship

None.

Conflicts of interest

There are no conflicts of interest.

Patient consent

Not applicable.

Ethics approval

Not applicable.

Copyright

© The Author(s) 2018.

REFERENCES

1. Ferlay J, Soerjomataram I, Dikshit R, Eser S, Mathers C, Rebelo M, Parkin DM, Forman D, Bray F. Cancer incidence and mortality worldwide: Sources, methods and major patterns in GLOBOCAN 2012. *Int J Cancer* 2015;136:E359-86.
2. Okines A, Verheij M, Allum W, Cunningham D, Cervantes A; ESMO Guidelines Working Group. Gastric cancer: ESMO clinical

- practice guidelines for diagnosis, treatment and follow-up. *Ann Oncol* 2010;21 Suppl 5:v50-4.
3. Yonemura Y, Endou Y, Sasaki T, Hirano M, Mizumoto A, Matsuda T, Takao N, Ichinose M, Miura M, Li Y. Surgical treatment for peritoneal carcinomatosis from gastric cancer. *Eur J Surg Oncol* 2010;36:1131-8.
 4. Yonemura Y, Canbay E, Endou Y, Ishibashi H, Mizumoto A, Miura M, Li Y, Liu Y, Takeshita K, Ichinose M, Takao N, Hirano M, Sako S, Tsukiyama G. Peritoneal cancer treatment. *Expert Opin Pharmacother* 2014;15:623-36.
 5. Gill RS, Al-Adra DP, Nagendran J, Campbell S, Shi X, Haase E, Schiller D. Treatment of gastric cancer with peritoneal carcinomatosis by cytoreductive surgery and HIPEC: a systematic review of survival, mortality, and morbidity. *J Surg Oncol* 2011;104:692-8.
 6. Nadiradze G, Giger-Pabst U, Zieren J, Strumberg D, Solass W, Reymond MA. Pressurized intraperitoneal aerosol chemotherapy (PIPAC) with low-dose cisplatin and doxorubicin in gastric peritoneal metastasis. *J Gastrointest Surg* 2016;20:367-73.
 7. Hübner M, Grass F, Teixeira-Farinha H, Pache B, Mathevet P, Demartines N. Pressurized intraperitoneal aerosol chemotherapy - practical aspects. *Eur J Surg Oncol* 2017;43:1102-9.
 8. Tempfer C. Pressurized intraperitoneal aerosol chemotherapy as an innovative approach to treat peritoneal carcinomatosis. *Med Hypotheses* 2015;85:480-4
 9. Solass W, Kerb R, Mürdter T, Giger-Pabst U, Strumberg D, Tempfer C, Zieren J, Schwab M, Reymond MA. Intraperitoneal chemotherapy of peritoneal carcinomatosis using pressurized aerosol as an alternative to liquid solution: first evidence for efficacy. *Ann Surg Oncol* 2014;21:553-9.
 10. Teixeira Farinha H, Grass F, Kefleyesus A, Achtari C, Romain B, Montemurro M, Demartines N, Hübner M. Impact of pressurized intraperitoneal aerosol chemotherapy on quality of life and symptoms in patients with peritoneal carcinomatosis: a retrospective cohort study. *Gastroenterol Res Pract* 2017;2017:4596176.
 11. Girshally R, Demtröder C, Albayrak N, Zieren J, Tempfer C, Reymond MA. Pressurized intraperitoneal aerosol chemotherapy (PIPAC) as a neoadjuvant therapy before cytoreductive surgery and hyperthermic intraperitoneal chemotherapy. *World J Surg Oncol* 2016;14:253.
 12. Alyami M, Gagniere J, Sgarbura O, Cabelguenne D, Villeneuve L, Pezet D, Quenet F, Glehen O, Bakrin N, Passot G. Multicentric initial experience with the use of the pressurized intraperitoneal aerosol chemotherapy (PIPAC) in the management of unresectable peritoneal carcinomatosis. *Eur J Surg Oncol* 2017;43:2178-83.