

Review

Open Access



Improving oncological outcomes after robot-assisted radical prostatectomy: what novel tools do we have?

Roser Vives Dilme¹ , Juan Gómez Rivas^{1,2}, Laura Fernández Hernández¹, Laura Ibáñez Vázquez¹, Giovanni E Cacciamani^{2,3,4,5}, Stefano Puliatti^{2,6,7,8}, Mark Taratkin^{2,9}, Enrico Checcucci^{2,10,11}, Inés Rivero Belenchón^{2,12}, Karl-Friedrich Kowalewski^{2,13}, Álvaro Serrano¹, Jesús Moreno-Sierra¹

¹Department of Urology, Hospital Clínico San Carlos, Complutense University of Madrid, Madrid 28040, Spain.

²European Association of Urology (EAU) Young Academic Office (YAU), Uro-technology working group, Arnhem 30016, Netherlands.

³Keck School of Medicine, Catherine and Joseph Aresty Department of Urology, USC Institute of Urology, Los Angeles, CA 90033, USA.

⁴Keck School of Medicine, Department of Radiology, University of Southern California, Los Angeles, CA 90033, USA.

⁵Artificial Intelligence (AI) Center at USC Urology, USC Institute of Urology, Los Angeles, CA 91208, USA.

⁶Department of Urology, University of Modena and Reggio Emilia, Modena 41121, Italy.

⁷Department of Urology, OLV, Aalst 9300, Belgium.

⁸ORSI Academy, Melle 9090, Belgium.

⁹Institute for Urology and Reproductive Health, Sechenov University, Moscow 119048, Russia.

¹⁰School of Medicine, Division of Urology, Department of Oncology, San Luigi Hospital, University of Turin, Orbassano, Turin 10043, Italy.

¹¹Department of Surgery, IRCCS Candiolo Cancer Institute, Torino 10060, Italy.

¹²Department of Urology and Nephrology, Virgen del Rocío University Hospital, Seville 41013, Spain.

¹³Department of Urology and Urosurgery, University Hospital of Mannheim, Mannheim 68167, Germany.

Correspondence to: Dr. Roser Vives Dilme, Department of Urology, Hospital Clínico San Carlos, Complutense University of Madrid, Profesor Martín Lagos s/n, Madrid 28040, Spain. E-mail: rvivesdilme@gmail.com

How to cite this article: Dilme RV, Rivas JG, Hernández LF, Vázquez LI, Cacciamani GE, Puliatti S, Taratkin M, Checcucci E, Belenchón IR, Kowalewski KF, Serrano Á, Moreno-Sierra J. Improving oncological outcomes after robot-assisted radical prostatectomy: what novel tools do we have? *Mini-invasive Surg* 2022;6:53. <https://dx.doi.org/10.20517/2574-1225.2022.48>

Received: 11 Aug 2022 **First Decision:** 1 Aug 2022 **Revised:** 26 Aug 2022 **Accepted:** 9 Sep 2022 **Published:** 8 Oct 2022

Academic Editor: Giulio Belli **Copy Editor:** Jia-Xin Zhang **Production Editor:** Jia-Xin Zhang

Abstract

The recent application of novel technologies to the robot-assisted radical prostatectomy (RARP) procedure has provided a new perspective and demonstrated potential usefulness in surgical planning, intraoperative navigation, and education of both patients and healthcare professionals, allowing for a patient-tailored prostate cancer (PCa) treatment. Integration of novel techniques into robotic surgery has improved the accuracy of surgery and has demonstrated a potential benefit in functional and oncological outcomes in patients with PCa. However, further



© The Author(s) 2022. **Open Access** This article is licensed under a Creative Commons Attribution 4.0 International License (<https://creativecommons.org/licenses/by/4.0/>), which permits unrestricted use, sharing, adaptation, distribution and reproduction in any medium or format, for any purpose, even commercially, as long as you give appropriate credit to the original author(s) and the source, provide a link to the Creative Commons license, and indicate if changes were made.



randomized and prospective studies are needed to assess and validate the role of these technologies in clinical practice. The aim of this review is to summarize the current evidence on the new emerging techniques, such as three-dimensional (3D) imaging and printing, augmented reality (AR), and confocal microscopy (CM), and their impact on RARP and its oncological outcomes.

Keywords: Robot-assisted radical prostatectomy, augmented reality, three-dimensional (3D) imaging, 3D printed models, confocal microscopy

INTRODUCTION

Radical prostatectomy (RP) represents one of the mainstays of treatment for localized prostate cancer (PCa). The cornerstone of PCa surgery is achieving the balance between complete removal of the prostate gland without jeopardizing oncological results and optimal postoperative functional outcomes^[1]. In this setting, the nerve-sparing (NS) surgical technique allows preservation of the neurovascular bundles (NVBs), improving functional results, even though it is associated with a higher risk of positive surgical margins (PSMs)^[2]. Furthermore, PSMs have been identified as predictive factors of biochemical recurrence (BCR), cancer-specific survival (CSS), and overall survival (OS) in PCa patients^[3]. Consequently, many techniques have been proposed to assist in the intraoperative guidance of RP and evaluate surgical margins in real time, aiming to reduce PSM rates^[4].

Currently, PSM rates range from 9%-26% for robot-assisted radical prostatectomy (RARP)^[5]. In the last decade, entering the era of precision surgery^[6], RARP has been adopted as the preferred and most frequently used surgical approach^[7-11]. Furthermore, robotic surgery allows the integration of novel tools and innovative technologies to plan and guide RP^[6].

Moreover, the introduction of imaging techniques for the assessment of the local extent of PCa, such as multiparametric magnetic resonance imaging (mpMRI), aids in predicting and localizing areas of possible extraprostatic extension (EPE) and its proximity to NVBs^[12,13]. Therefore, mpMRI may have a role in guiding NS surgery, potentially improving the preservation of NVBs and reducing PSM rates^[4].

Recently, novel tools integrating mpMRI and robotic surgery have been described for assisting the surgeon during RARP in the real-time evaluation of the main anatomical structures, aiming for optimal oncological and functional outcomes^[14]. Some authors reported the use of three-dimensional (3D) models in surgical planning and intraoperative guidance^[15]. Likewise, other techniques such as augmented reality (AR) and confocal laser endomicroscopy (CLE) or fluorescence confocal microscopy (FCM) have recently been introduced as an additional tool in RARP^[14,16].

This review summarizes the state of the art of imaging technology (3D models, AR, CLE, and FCM), their emerging role in real-time surgical assessment, and their impact on oncological outcomes in RARP.

EVIDENCE ACQUISITION

This review covers the current scenario of the impact of new technologies (3D imaging and printing, AR, CLE, and FCM) in surgical planning and intraoperative assessment of RARP. We conducted a comprehensive literature search for original and review articles using Medline and PubMed databases from February-March 2022. We searched for the following terms: “robot-assisted radical prostatectomy”, “augmented reality”, “3D imaging”, “3D printed models”, “confocal microscopy”, and “prostate cancer” alone or in combination. The search period ranged from 2012 to 2022. We included studies in English,

original articles, systematic reviews, and metanalysis. Studies in other languages, case reports, and abstracts in congresses were excluded. The combination of terms is found in more than 1500 related articles. Studies with the highest level of evidence and relevance to the discussed topics were selected with the consensus of the authors, and 39 papers were finally included in this review [Table 1].

EVIDENCE SYNTHESIS

Three-dimensional imaging and printed models

Three-dimensional (3D) imaging reconstruction, whether in digital modeling or 3D printing, has appeared as an emerging technology in urology in recent years. 3D printing was first described in 1986 by Hull^[17], and since then, its application has demonstrated remarkable potential in surgical planning, patient counseling, training, and intraoperative guidance^[18]. 3D visualization techniques allow a better understanding of the organ's anatomy, the identification of the tumor lesions in each patient, and its relationship with adjacent anatomical structures^[17], thus enabling patient-tailored surgery. In the context of RP, a 3D-printed prostate model may help to identify NVB and lesions in their vicinity and, consequently, improve the oncological and functional outcomes by assisting NS surgery whenever possible^[14] [Figures 1 and 2].

Ukimura *et al.*, described a novel 3D surgical navigation model based on transrectal ultrasound (TRUS)-guided prostate biopsies, which was displayed on the TilePro™ function of the da Vinci Surgical System[®]^[19]. The TilePro function allows for direct and simultaneous visualization of 3D reconstruction and intraoperative endoscopic images on the robotic console screen. The main purpose of the 3D navigation system was to assist NS surgery by facilitating surgical dissection in areas adjacent to biopsy-proven index lesions. Negative surgical margins were achieved in 0 of 10 patients included in the study. Subsequently, Shin *et al.* created life-sized 3D-printed prostate models based on MRI, including the transparent prostate gland, index lesion, and bilateral NVBs^[20]. They described the advantages of using 3D models in preoperative planning and intraoperative guidance, achieving negative surgical margins in all five reported cases. Jomoto *et al.* presented a new 3D system based on magnetic resonance angiography^[21]. The study included six PCa patients and suggested a potential benefit of the 3D system in the identification of accessory pudendal arteries and NVBs during RARP. Chandak *et al.* conducted a phase 2 study evaluating the impact of using a 3D-printed model based on MRI in preoperative planning, intraoperative guidance, and postoperative outcomes^[22]. They reported only 1 PSM among the 10 patients studied.

Recently, Wang *et al.* performed a systematic review of the currently available evidence including 27 nonrandomized studies, nine of which refer to the use of 3D reconstructed images or printed models, demonstrating a promising role for 3D visualization in preoperative planning, intraoperative navigation, and education and training, while noting that prospective studies are needed to validate these technologies and their clinical impact on RARP outcomes^[18]. Checucci *et al.* performed a prospective study including 160 PCa patients undergoing RARP with mpMRI-based 3D reconstruction and compared them to a control group of 640 patients in whom 3D technology was not applied^[23]. In the 3D-assisted RARP group, a more conservative NS approach (full NS 20.6% vs. 12.7%; $P = 0.02$) and a lower rate of PSM (25% vs. 35.1%; $P = 0.01$) were observed.

Moreover, in the setting of surgical planning and physician/patient education, Ebbing *et al.* evaluated a 3D-printed model based on MRI in a non-surgical setting, comparing the impact on interpreting PCa lesion location by medical personnel of different levels of expertise^[24]. The study showed that 3D models were more accessible to evaluate than MRI results presented in a multidisciplinary conference, especially by less experienced professionals. Porpiglia *et al.* assessed the use of 3D-printed models in physician education and preoperative surgical planning^[25]. The survey showed high patient satisfaction with preoperative counseling

Table 1. Summary of the most relevant studies included in this review

Author	Year	Technique	Image acquisition	Procedure	Application	Study design	Study objective	Results
Simpfendorfer <i>et al.</i> ^[31]	2011	AR	US	Laparoscopic RP	Surgical navigation	Case report/series	To describe an ultrasound-based AR navigation system	Real-time assessment using tracking needles inserted into the prostate surface (visualization error 0.55–0.28 mm)
Ukimura <i>et al.</i> ^[19]	2014	3D model	TRUS/MRI	RARP	Surgical navigation	Case report/series	To evaluate the use of a 3D model based on biopsy-proven index PCa lesions for NS-RARP	9/10 (90%) patients achieved negative surgical margins
Shin <i>et al.</i> ^[20]	2016	3D model	MRI	RARP	Surgical planning and navigation	Case report/series	To describe the advantages of using a life-size 3D printed prostate model with index lesions pre- and intraoperatively	5/5 (100%) patients achieved negative surgical margins
Jomoto <i>et al.</i> ^[21]	2018	3D model	MRI angiography	RARP	Surgical planning and navigation	Case report/series	To assess the benefit of using a 3D printed model during RARP	Improved detection of accessory pudendal arteries and NVB
Chandak <i>et al.</i> ^[22]	2018	3D model	MRI	RARP	Surgical planning and navigation	Non-randomized trial	To investigate the use of a 3D printed prostate model with PCa lesions in RARP	9/10 (90%) patients achieved negative surgical margins. Continence 100% at 12 months, 40% no erectile dysfunction at 24 months
Porpiglia <i>et al.</i> ^[16]	2018	AR	MRI	RARP	Surgical navigation	Case report/series	To evaluate the use of AR-assisted RARP	NS-RARP with selective biopsies if EPE is suspected (positive rate of 78%, 11/14 patients)
Harrison <i>et al.</i> ^[37]	2018	AR	-	Ex vivo RARP	Physician training	Non-randomized trial	To analyze the impact of an AR robotic training module on novice surgeon's learning curves	Improvement in performance of bladder dissection and vesicourethral anastomosis (surgical time, instrument collisions, injury to bladder or urethra and total time instruments were out of view; $P < 0.05$)
Porpiglia <i>et al.</i> ^[25]	2018	3D model	MRI	RARP	Surgical planning and patient education and physician training	Non-randomized trial	To assess the use of 3D printed models for RARP based on a survey	High level of patient satisfaction with preoperative counseling (scored 9–10/10). Perceived by surgeons as a useful tool in surgical planning (8/10), training (9/10) and anatomical representation (10/10)
Wake <i>et al.</i> ^[26]	2019	3D model	MRI	RARP	Patient education	Non-randomized trial	To evaluate the role of 3D models in patient preoperative counseling	Using 3D models vs. standard imaging, patients better understood the disease, cancer location, size and surgical plan (scores 4.6–4.78/5 vs. 4.06–4.49/5; $P < 0.05$)
Porpiglia <i>et al.</i> ^[33]	2019	AR	MRI	RARP	Surgical navigation	Non-randomized trial	To introduce an elastic 3D AR real-time navigation system	Improved capsular involvement identification vs. 2D cognitive group (100% vs. 47%; $P < 0.05$). No significant reduction in PSM rate ($P = 0.73$)
Samei <i>et al.</i> ^[5]	2020	AR	TRUS/MRI	RARP	Surgical navigation	Case report/series	To describe a combined MRI-TRUS-based AR guidance system for RARP	The average error between US and da Vinci system was 1.4 ±0.3 mm
Shee <i>et al.</i> ^[36]	2020	3D model	-	Ex vivo RARP	Physician training	Non-randomized trial	To develop a 3D-printed vesicourethral anastomosis model for RARP training	Superior rate of completion of the anastomosis in the pre-trained group of residents (54% vs. 20%; $P < 0.0001$)
Saba <i>et al.</i> ^[27]	2021	3D model	MRI	RARP	Surgical planning and physician training	Non-randomized trial	To investigate the use of 3D computer-aided designs and 3D-printed models as preoperative tools for urologists	Improved accuracy, faster and more confident identification of PCa lesions by urologists comparing 3D visualization with mpMRI
Schiavina	2021	AR	MRI	RARP	Surgical navigation	Case	To describe the impact of 3D AR	Improvement in index PCa lesion identification and change

<i>et al.</i> ^[15]						report/series	technology to guide NS-RARP	in NS surgical planning in 38.5% of patients (appropriate decision in 94.4% of cases)
Bianchi <i>et al.</i> ^[4]	2021	AR	MRI	RARP	Surgical navigation	Non-randomized trial	To assess a novel technique of IFS targeted to the index PCa lesion by using AR-3D models for NS-RARP	Comparable overall PSM rate but a lower rate of PSMs at the level of the index PCa lesion in patients who underwent IFS (5% vs. 20%; $P = 0.01$)
Rocco <i>et al.</i> ^[13]	2021	FCM	-	RARP	Surgical navigation	Case report/series	To describe a technique for intraoperative evaluation of margin status using FCM analysis	PSMs were found intraoperatively in 4/24 patients, performing a secondary resection. Final histopathology showed negative surgical margins in all patients
Checucci <i>et al.</i> ^[23]	2022	3D model	MRI	RARP	Surgical navigation	Non-randomized trial	To evaluate the role of 3D models on PSM rate	Lower rate of PSM (25% vs. 35.1%; $P = 0.01$) and more conservative NS approach (full NS 20.6% vs. 12.7%; $P = 0.02$) in the 3D-assisted RARP-group

AR: Augmented reality; EPE: extraprostatic extension; FCM: fluorescence confocal microscopy; IFS: intraoperative frozen section; mpMRI: multiparametric magnetic resonance imaging; MRI: magnetic resonance imaging; NS: nerve-sparing; NVB: neurovascular bundles; PCa: prostate cancer; PSM: positive surgical margin; RARP: robot-assisted radical prostatectomy; RP: radical prostatectomy; TRUS: transrectal ultrasound; US: ultrasound; 3D: three-dimensional.

(Likert scores 9-10/10). Moreover, the surgeons perceived 3D visualization as a useful tool in procedure planning (score 8/10). Subsequently, Wake *et al.* performed a study including 200 patients randomized to receive a preoperative assessment with a routine imaging test or with a 3D model (printed, visualized in AR, or viewed on a computer monitor)^[26]. The results show that patients better understood the disease, cancer localization, size, and surgical plan using 3D models versus standard imaging (scores 4.60-4.78/5 vs. 4.06-4.49/5; $P < 0.05$). Recently, Saba *et al.* evaluated 3D prostate computer-aided designs and 3D-printed models as preoperative planning tools^[27]. Comparing 3D visualization with mpMRI in the pre-RARP evaluation of ten PCa patients, urologists showed improved accuracy, with faster and more confident identification of prostate lesions. Finally, Cipollari *et al.* introduced the new approach of applying histological tissue clearing techniques to 3D technology, demonstrating the role of 3D imaging in molecular and histopathological assessment of prostate volumes and its correlation with mpMRI^[28].

Nevertheless, although an increasing trend in the use of 3D modeling has been reported over the last decade, there are still limitations to these techniques. Firstly, 3D models are based on image acquisition from MRI or ultrasound, thus assuming the risk of missing some PCa lesions not visible on these imaging tests^[18]. Secondly, 3D-printed models can reproduce the same size as the real organ, although the material does not reproduce the consistency and elasticity of normal tissue^[18,22]. Thirdly, 3D models add an additional cost to the RARP procedure. Therefore, a cost-effectiveness analysis of the implementation of these technologies in the routine surgical process in the future would be necessary^[14,18,22]. Lastly, all currently available studies evaluating the role of 3D technology are based on small, single-center cohorts. Therefore, the overall level of evidence remains suboptimal, and further prospective randomized trials will be needed to assess the potential benefit of novel technologies and validate their use in clinical practice^[14,18].

Augmented reality

In the era of patient-tailored surgery, another innovative technique has been developed to implement 3D reconstruction in real-time assessment during

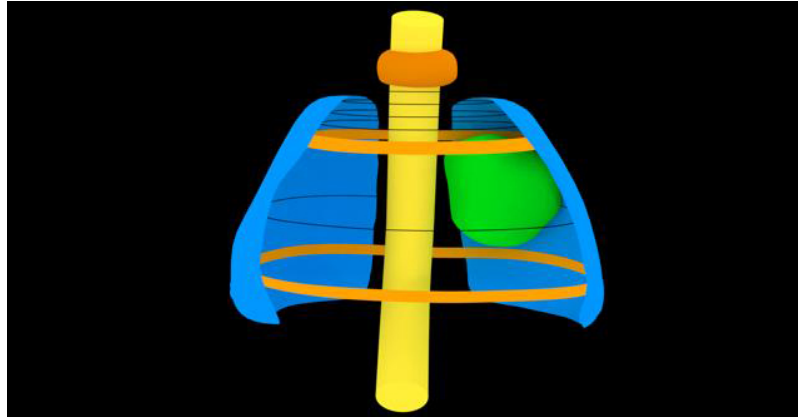


Figure 1. 3D prostate rendering (image courtesy of Medics). The tumor lesion is highlighted in green, the urethra in yellow, and the prostatic limits in blue. 3D: Three-dimensional.



Figure 2. QR-code that links to a YouTube video of the 3D prostate model designed for robot-assisted radical prostatectomy (image courtesy of Medics). QR: Quick response; 3D: three-dimensional.

surgical procedures. Augmented reality (AR) is a technology that overlays objects or images onto the real world. Superimposing 3D models on the robotic vision enhances intraoperative navigation and accuracy in the identification of essential anatomical structures during the surgical procedure^[4,18,29] [Figures 3 and 4].

The first clinical application of AR in RP was described in 2008 by Ukimura and Gill^[30], introducing a real-time fusion system of TRUS with intraoperative laparoscopic vision. The system enabled synchronization of

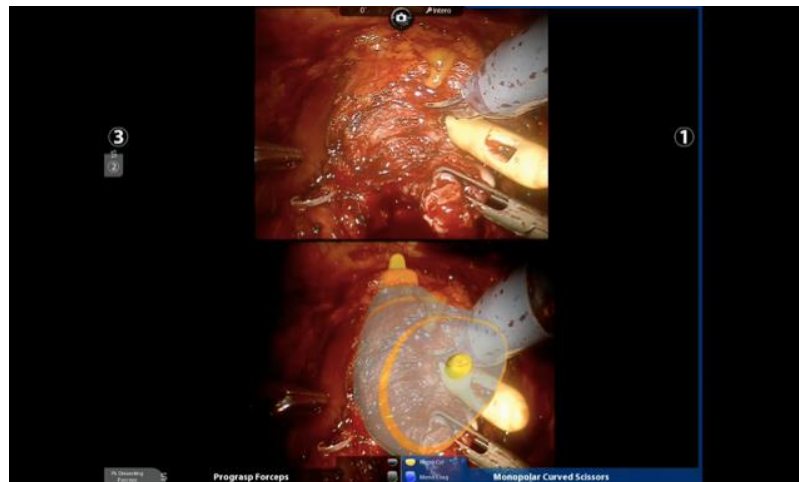


Figure 3. AR images during RARP (courtesy of Prof. Porpiglia). AR: Augmented reality; RARP, robot-assisted radical prostatectomy.

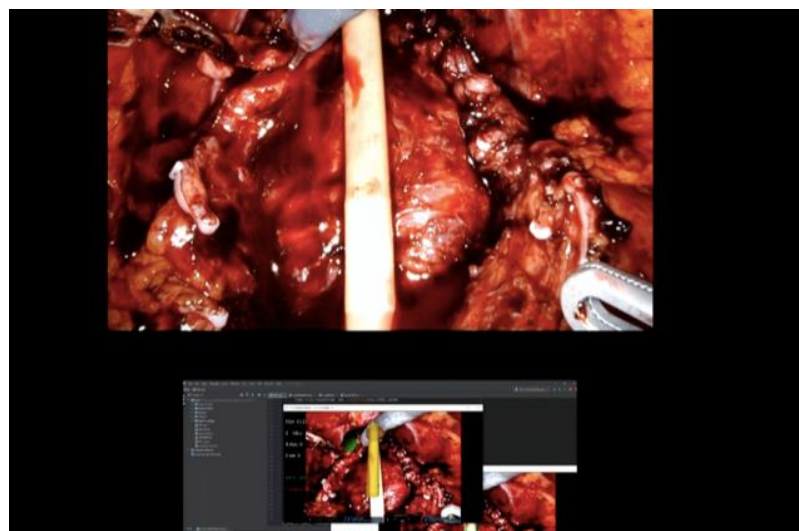


Figure 4. AR images during RARP (courtesy of Prof. Porpiglia). AR: Augmented reality; RARP: robot-assisted radical prostatectomy.

the TRUS 3D images with the surgical view through a high-speed computer workstation and the use of optical tracking systems for the dynamic motion of the surgical instruments. The authors concluded that AR is a valuable tool in intraoperative guidance, providing increased accuracy and confidence to the surgeon and a better understanding and interpretation of the tumor lesions and surrounding anatomy. Subsequently, Simpfendörfer *et al.* described the *in vivo* application of an ultrasound-based AR navigation system for laparoscopic RP^[51]. The system used tracking needles inserted into the prostate surface and traced their movements and locations in real time with a 3D ultrasound probe. Furthermore, Porpiglia *et al.* introduced an AR technique based on preoperative MRI^[16]. The MRI-based 3D imaging was superimposed on the real anatomy in the robotic view. The NS strategy was based on local staging and reconstruction obtained from MRI, including 16 clinical T2 (cT2) patients who underwent the intrafascial NS technique and 14 cT3 patients in whom standard NS and AR-guided biopsy of suspected EPE were performed. Final pathology confirmed clinical staging and all the intraprostatic lesions. Selective biopsies in patients with suspected EPE showed a positive rate of 78% (11/14 patients). The discrepancy between the surgical specimen and the 3D reconstruction ranged from 1 to 5 mm. Despite the potential advantages of using the

AR technique, the authors described some limitations: the need for manual orientation and the rigidity of the virtual models. In this setting, the group improved the AR technique by implementing hyper-accurate 3D reconstruction technology (HA3D)^[32] and further developed a 3D elastic AR system, which allowed simulating the prostate deformation caused by the robotic instruments in the dynamic phase of the surgery and, therefore, to better adapt the imaging overlay during the surgical procedure^[31]. Porpiglia *et al.* conducted a prospective study including 40 PCa patients, 20 undergoing 3D AR RARP and 20 undergoing 2D cognitive RARP^[33]. In the 3D AR group, capsular involvement was correctly identified in 100% of cases versus 47% in the 2D cognitive group ($P < 0.05$). Moreover, a 10% reduction in PSM rate was noted in the 3D AR group, although no statistical significance was demonstrated (25% vs. 35%; $P = 0.73$). The authors concluded that the introduction of an elastic system allowed a more accurate surgical simulation and a better adjustment to the dynamic reality of tissue manipulation during surgery. However, this model still had the limitation of requiring manual segmentation and overlapping of the images. Schiavina *et al.* evaluated the impact of 3D AR technology to guide NS RARP^[15]. The study included 26 patients who underwent 3D AR-assisted NS RARP, showing an improvement in index lesion identification and a change in NS surgical planning in 38.5% of patients, resulting in an appropriate decision in 94.4% of cases. Samei *et al.* presented a novel MRI-TRUS-based image guidance system for RARP consisting of a preoperative MRI non-rigidly registered to intraoperative TRUS^[5]. This technology offered the surgeon a combination of the two imaging tests simultaneously on the robotic console, potentially improving intraoperative tailoring to the specific prostate anatomy and PCa location. Kalia *et al.* proposed a markerless AR guidance system for RARP, which coordinated the TRUS image with the robotic camera image without the requirement for external calibration markers before or during surgery^[34]. The focus can thus be changed during surgery, allowing for a re-estimation and adaptation of the image without stopping the procedure. Borgmann *et al.* introduced the use of wearable computing smart glasses in combination with AR in urological surgery^[35]. The study demonstrated a high usefulness of this technology, as reported by the surgeons, considering applications in taking photographs, recording videos, reviewing patients' medical records and images, searching for online information, and hands-free teleconsultation. Recently, Roberts *et al.* conducted a systematic review of the current evidence on AR applications in urology, including 15 studies on prostate surgery which demonstrated a potential value of AR in intraoperative guidance, identification of PCa lesions, detection of capsular involvement, and patient counseling^[29]. Finally, some authors have assessed the impact of new technologies on surgical training. Shee *et al.* developed a 3D-printed model of the vesicourethral anastomosis (VUA) for *ex vivo* RARP training, showing a superior rate of completion of the anastomosis in the pre-trained group of residents compared to the untrained resident group (54% vs. 20%; $P < 0.0001$)^[36]. All participants considered the 3D model a useful tool in the setting of surgical training. Harrison *et al.* analyzed the impact of an AR robotic training module on novice surgeon's learning curves, demonstrating a significant improvement in performance of bladder dissection and VUA in terms of surgical time ($P < 0.0001$ and $P = 0.0135$, respectively), instrument collisions ($P = 0.0013$ and $P = 0.066$; respectively), total time instruments were out of view ($P = 0.0251$), and injury to the urethra and bladder ($P = 0.032$ and $P = 0.0189$, respectively)^[37]. Nevertheless, despite the increasing use of robotics in urological surgery, there are currently no standardized training programs for novice urologists. Several authors have presented different training methods, some of them including 3D or AR simulation models to optimize the teaching of RARP. In this setting, Anceschi *et al.* recently proposed a new system for assessing the quality of RARP learning curves based on pathologic and perioperative outcomes^[38]. They defined a score to evaluate the RARP procedures performed by trainees, which was established as a predictor of early trifecta achievement ($P < 0.05$). Conclusively, although the use of new technological tools in surgical training is promising, further studies are needed to define standardized training programs and validate their evaluation methods.

In summary, the development of AR passed through different phases, from the use of ultrasound initially to the inclusion of MRI and the emergence of elastic models. The major limitation of this technique was the rigidity of the 3D virtual models, which failed to adapt the image overlay to the tractions and tissue manipulations involved in the surgical procedure. This barrier was overcome by Porpiglia *et al.*, who described an elastic AR model in 2019. However, all current MRI-based AR systems still have the limitation of requiring manual adjustment of the image by another urologist during surgery^[33]. Therefore, the development of new automated models in this field will be necessary. In this setting, the advent of artificial intelligence and its application in robotic surgery may play a key role in addressing the technological limitations described to date^[39]. Finally, as with 3D modeling, further randomized trials are needed to assess the oncological and functional improvement related to these new technologies^[6,14,18].

Confocal microscopy

In the precision surgery setting and to improve the identification of the main anatomical structures and PCa involvement, different histopathological and optical imaging techniques have been developed^[14,40,41]. Real-time assessment of surgical margins and extracapsular extension allows for accurate intraoperative guidance of NS surgery, potentially improving the oncological and functional outcomes of RP^[40].

In this context, intraoperative frozen section (FS) analysis is considered the gold standard approach for assessing surgical margin status during surgery. However, the role of FS during RP is debatable due to the lack of benefit in BCR-free survival, the time-consuming nature of the procedure, and the heterogeneity of the technique described in the studies available to date^[13,39,42]. In 2012, Schlomm *et al.* presented the neurovascular-adjacent frozen section examination (NeuroSAFE) technique^[43]. The NeuroSAFE approach involves complete dissection of the neurovascular tissue surrounding the prostate and assessment via FS, allowing real-time monitoring of oncological safety in NS surgery. Nevertheless, the use of this technique failed to progress due to the complexity of its application and low reproducibility, requiring the availability of a specific and fully equipped laboratory, a trained pathologist present on-site, and a total time exceeding 30 min^[13,44,45]. Recently, Bianchi *et al.* conducted a prospective study evaluating a novel technique consisting of intraoperative index PCa lesion FS using 3D AR models in patients undergoing NS RARP^[4]. The results show a comparable overall PSM rate between the group of patients who received intraoperative FS and the control group, although a lower rate of PSMs at the level of the index lesion was demonstrated in those patients who underwent intraoperative FS (5% vs. 20%; $P = 0.01$).

In this scenario, López *et al.* introduced confocal laser endomicroscopy (CLE) in the RARP procedure^[46]. CLE is an imaging technology based on a fiber-optic system that provides high-resolution cellular images using a blue laser (488 nm) in combination with fluorescein^[14,40]. The study demonstrated the intraoperative applicability of CLE and the feasibility of identifying NVBs and performing an optical biopsy of periprostatic tissue during RARP^[46]. Subsequently, Panarello *et al.* developed an atlas of CLE images of prostatic and periprostatic tissues, thus providing the basis for identifying and interpreting histological patterns during RARP^[47].

Recently, Rocco *et al.* presented a novel technology to assess real-time pathological examination: fluorescence confocal microscopy (FCM)^[45]. FCM is an optical technique that allows the acquisition of immediate digital hematoxylin-eosin-like images from freshly excised tissue^[13,40,45]. FCM analysis has shown 91% concordance with the conventional hematoxylin-eosin technique in discriminating PCa from normal prostatic tissue^[48]. The group conducted a subsequent prospective study^[13], including 24 patients undergoing RARP with intraoperative FCM control of margin status. Digital images from the surgical margins were obtained immediately via FCM. PSMs were found intraoperatively in four patients, and a secondary focal

resection was performed. Final histopathology showed the absence of PSMs in all patients. The authors concluded that FCM might provide a feasible alternative to the NeuroSAFE technique due to the ability to digitalize hematoxylin-eosin-like images and report them in real time remotely and without the need for specific image processing. Further, Bertoni *et al.* developed an *ex vivo* tissue atlas based on FCM images and reported a short learning curve of this novel technique for pathologists^[49].

In summary, optical imaging techniques have shown promising results in the assessment of surgical margins and the potential improvement of oncological and functional outcomes of RP. However, further studies are required to define their possible applications in PCa treatment.

CONCLUSIONS

The advent of novel imaging technologies and their application to RARP procedures has led to a new understanding of surgical planning, intraoperative navigation, professional training, and patient education. Despite the current limitations of the different techniques and the low quality of the available evidence, the new tools have shown a promising role in potentially improving the oncological and functional outcomes of RARP. Nevertheless, further randomized and prospective studies are needed to assess and validate the clinical utility of these technologies.

DECLARATIONS

Authors' contributions

Acquisition of data: Dilme RV, Rivas JG

Analysis and interpretation of data: Dilme RV, Rivas JG, Hernández LF, Vázquez LI

Drafting of the manuscript: Dilme RV

Supervision and critical revision of the manuscript: Rivas JG, Cacciamani GE, Puliatti S, Taratkin M, Checcucci E, Belenchón IR, Kowalewski KF, Serrano A, Moreno-Sierra J

Availability of data and materials

Not applicable.

Financial support and sponsorship

None.

Conflicts of interest

All authors declared that there are no conflicts of interest.

Ethical approval and consent to participate

Not applicable.

Consent for publication

Not applicable.

Copyright

© The Author(s) 2022.

REFERENCES

1. Mottet N, Cornford P, van den Bergh RCN, et al. EAU-EANM-ESTRO-ESUR-ISUP-SIOG Guidelines on Prostate Cancer. 2022. Available from: https://d56bochluxqz.cloudfront.net/documents/full-guideline/EAU-EANM-ESTRO-ESUR-ISUP_SIOG-Guidelines-on-Prostate-Cancer-2022.pdf [Last accessed on 15 Sep 2022].

2. Schiavina R, Bianchi L, Borghesi M, et al. MRI displays the prostatic cancer anatomy and improves the bundles management before robot-assisted radical prostatectomy. *J Endourol* 2018;32:315-21. [DOI PubMed](#)
3. Zhang L, Wu B, Zha Z, et al. Surgical margin status and its impact on prostate cancer prognosis after radical prostatectomy: a meta-analysis. *World J Urol* 2018;36:1803-15. [DOI PubMed PMC](#)
4. Bianchi L, Chessa F, Angiolini A, et al. The Use of augmented reality to guide the intraoperative frozen section during robot-assisted radical prostatectomy. *Eur Urol* 2021;80:480-8. [DOI PubMed](#)
5. Samei G, Tsang K, Kesch C, et al. A partial augmented reality system with live ultrasound and registered preoperative MRI for guiding robot-assisted radical prostatectomy. *Med Image Anal* 2020;60:101588. [DOI PubMed](#)
6. Autorino R, Porpiglia F. Robotic surgery in urology: the way forward. *World J Urol* 2020;38:809-11. [DOI PubMed](#)
7. Knipper S, Graefen M. Robot-assisted radical prostatectomy-so successful because it is better or better because it is so successful? *Eur Urol Oncol* 2018;1:361-3. [DOI PubMed](#)
8. Mazzone E, Mistretta FA, Knipper S, et al. Contemporary national assessment of robot-assisted surgery rates and total hospital charges for major surgical Uro-oncological procedures in the United States. *J Endourol* 2019;33:438-47. [DOI PubMed](#)
9. Leow JJ, Chang SL, Meyer CP, et al. Robot-assisted versus open radical prostatectomy: a contemporary analysis of an all-payer discharge database. *Eur Urol* 2016;70:837-45. [DOI PubMed](#)
10. Moreno-Sierra J, Galante-Romo MI, Senovilla-Perez JL, et al. Oncologic outcomes in 408 consecutive patient cohort treated with da Vinci robot-assisted radical prostatectomy. *Actas Urol Esp (Engl Ed)* 2020;44:179-86. [DOI PubMed](#)
11. Sierra JM. Robotic radical prostatectomy in the 21 st century: evolution of experience. *MRAJ* 2021:9. [DOI](#)
12. Martini A, Wagaskar VG, Dell'Oglio P, et al. Image guidance in robot-assisted radical prostatectomy: how far do we stand? *Curr Opin Urol* 2019;29:10-3. [DOI PubMed](#)
13. Rocco B, Sarchi L, Assumma S, et al. Digital frozen sections with fluorescence confocal microscopy during robot-assisted radical prostatectomy: surgical technique. *Eur Urol* 2021;80:724-9. [DOI PubMed](#)
14. Makary J, van Diepen DC, Arianayagam R, et al. The evolution of image guidance in robotic-assisted laparoscopic prostatectomy (RALP): a glimpse into the future. *J Robot Surg* 2022;16:765-74. [DOI PubMed](#)
15. Schiavina R, Bianchi L, Lodi S, et al. Real-time augmented reality three-dimensional guided robotic radical prostatectomy: preliminary experience and evaluation of the impact on surgical planning. *Eur Urol Focus* 2021;7:1260-7. [DOI PubMed](#)
16. Porpiglia F, Fiori C, Checcucci E, Amparore D, Bertolo R. Augmented reality robot-assisted radical prostatectomy: preliminary experience. *Urology* 2018;115:184. [DOI PubMed](#)
17. Cacciamani GE, Okhunov Z, Meneses AD, et al. Impact of three-dimensional printing in urology: state of the art and future perspectives. A systematic review by ESUT-YAUWP group. *Eur Urol* 2019;76:209-21. [DOI PubMed](#)
18. Wang S, Frisbie J, Keepers Z, et al. The use of three-dimensional visualization techniques for prostate procedures: a systematic review. *Eur Urol Focus* 2021;7:1274-86. [DOI PubMed](#)
19. Ukimura O, Aron M, Nakamoto M, et al. Three-dimensional surgical navigation model with TilePro display during robot-assisted radical prostatectomy. *J Endourol* 2014;28:625-30. [DOI PubMed](#)
20. Shin T, Ukimura O, Gill IS. Three-dimensional printed model of prostate anatomy and targeted biopsy-proven index tumor to facilitate nerve-sparing prostatectomy. *Eur Urol* 2016;69:377-9. [DOI PubMed PMC](#)
21. Jomoto W, Tanooka M, Doi H, et al. Development of a three-dimensional surgical navigation system with magnetic resonance angiography and a three-dimensional printer for robot-assisted radical prostatectomy. *Cureus* 2018;10:e2018. [DOI PubMed PMC](#)
22. Chandak P, Byrne N, Lynch H, et al. Three-dimensional printing in robot-assisted radical prostatectomy - an idea, development, exploration, assessment, long-term follow-up (IDEAL) phase 2a study. *BJU Int* 2018;122:360-1. [DOI PubMed](#)
23. Checcucci E, Pecoraro A, Amparore D, et al; Uro-technology and SoMe Working Group of the Young Academic Urologists Working Party of the European Association of Urology. The impact of 3D models on positive surgical margins after robot-assisted radical prostatectomy. *World J Urol* 2022;40:2221-9. [DOI PubMed](#)
24. Ebbing J, Jäderling F, Collins JW, et al. Comparison of 3D printed prostate models with standard radiological information to aid understanding of the precise location of prostate cancer: a construct validation study. *PLoS One* 2018;13:e0199477. [DOI PubMed PMC](#)
25. Porpiglia F, Bertolo R, Checcucci E, et al; ESUT Research Group. Development and validation of 3D printed virtual models for robot-assisted radical prostatectomy and partial nephrectomy: urologists' and patients' perception. *World J Urol* 2018;36:201-7. [DOI PubMed](#)
26. Wake N, Rosenkrantz AB, Huang R, et al. Patient-specific 3D printed and augmented reality kidney and prostate cancer models: impact on patient education. *3D Print Med* 2019;5:4. [DOI PubMed PMC](#)
27. Saba P, Melnyk R, Holler T, et al. Comparison of multi-parametric MRI of the prostate to 3D prostate computer aided designs and 3D-printed prostate models for pre-operative planning of radical prostatectomies: a pilot study. *Urology* 2021;158:150-5. [DOI PubMed](#)
28. Cipollari S, Jamshidi N, Du L, et al. Tissue clearing techniques for three-dimensional optical imaging of intact human prostate and correlations with multi-parametric MRI. *Prostate* 2021;81:1450. [DOI PubMed](#)
29. Roberts S, Desai A, Checcucci E, et al. "Augmented reality" applications in urology: a systematic review. *Minerva Urol Nephrol* 2022. [DOI PubMed](#)
30. Ukimura O, Gill IS. Imaging-assisted endoscopic surgery: cleveland Clinic experience. *J Endourol* 2008;22:803-10. [DOI PubMed](#)
31. Simpfendorfer T, Baumhauer M, Müller M, et al. Augmented reality visualization during laparoscopic radical prostatectomy. *J*

- Endourol* 2011;25:1841-5. DOI PubMed
32. Porpiglia F, Checcucci E, Amparore D, et al. Augmented-reality robot-assisted radical prostatectomy using hyper-accuracy three-dimensional reconstruction (HA3D™) technology: a radiological and pathological study. *BJU Int* 2019;123:834-45. DOI PubMed
 33. Porpiglia F, Checcucci E, Amparore D, et al. Three-dimensional elastic augmented-reality robot-assisted radical prostatectomy using hyperaccuracy three-dimensional reconstruction technology: a step further in the identification of capsular involvement. *Eur Urol* 2019;76:505-14. DOI PubMed
 34. Kalia M, Avinash A, Navab N, Salcudean S. Preclinical evaluation of a markerless, real-time, augmented reality guidance system for robot-assisted radical prostatectomy. *Int J Comput Assist Radiol Surg* 2021;16:1181-8. DOI PubMed
 35. Borgmann H, Rodríguez Socarrás M, Salem J, et al. Feasibility and safety of augmented reality-assisted urological surgery using smartglass. *World J Urol* 2017;35:967-72. DOI PubMed
 36. Shee K, Koo K, Wu X, Ghali FM, Halter RJ, Hyams ES. A novel ex vivo trainer for robotic vesicourethral anastomosis. *J Robot Surg* 2020;14:21-7. DOI PubMed
 37. Harrison P, Raison N, Abe T, et al. The validation of a novel robot-assisted radical prostatectomy virtual reality module. *J Surg Educ* 2018;75:758-66. DOI PubMed
 38. Anceschi U, Galfano A, Luciani L, et al. Analysis of predictors of early trifecta achievement after robot-assisted radical prostatectomy for trainers and expert surgeons: the learning curve never ends. *Minerva Urol Nephrol* 2022;74:133-6. DOI PubMed
 39. Checcucci E, Porpiglia F. The future of robotic radical prostatectomy driven by artificial intelligence. *Mini-invasive Surg* 2021;5:49. DOI
 40. Eissa A, Zoeir A, Sighinolfi MC, et al. "Real-time" assessment of surgical margins during radical prostatectomy: state-of-the-art. *Clin Genitourin Cancer* 2020;18:95-104. DOI PubMed
 41. Jaulim A, Aydın A, Ebrahim F, Ahmed K, Elhage O, Dasgupta P. Imaging modalities aiding nerve-sparing during radical prostatectomy. *Turk J Urol* 2019;45:325-30. DOI PubMed PMC
 42. Gillitzer R, Thüroff C, Fandel T, et al. Intraoperative peripheral frozen sections do not significantly affect prognosis after nerve-sparing radical prostatectomy for prostate cancer. *BJU Int* 2011;107:755-9. DOI PubMed PMC
 43. Schlomm T, Tennstedt P, Huxhold C, et al. Neurovascular structure-adjacent frozen-section examination (NeuroSAFE) increases nerve-sparing frequency and reduces positive surgical margins in open and robot-assisted laparoscopic radical prostatectomy: experience after 11,069 consecutive patients. *Eur Urol* 2012;62:333-40. DOI PubMed
 44. Oxley J, Bray A, Rowe E. Could a Mohs technique make NeuroSAFE a viable option? *BJU Int* 2018;122:358-9. DOI PubMed
 45. Rocco B, Sighinolfi MC, Bertoni L, et al. Real-time assessment of surgical margins during radical prostatectomy: a novel approach that uses fluorescence confocal microscopy for the evaluation of peri-prostatic soft tissue. *BJU Int* 2020;125:487-9. DOI PubMed
 46. Lopez A, Zlatev DV, Mach KE, et al. Intraoperative optical biopsy during robotic assisted radical prostatectomy using confocal endomicroscopy. *J Urol* 2016;195:1110-7. DOI PubMed PMC
 47. Panarello D, Compérat E, Seyde O, Colau A, Terrone C, Guillonnet B. Atlas of ex vivo prostate tissue and cancer images using confocal laser endomicroscopy: a project for intraoperative positive surgical margin detection during radical prostatectomy. *Eur Urol Focus* 2020;6:941-58. DOI PubMed
 48. Puliatti S, Bertoni L, Pirola GM, et al. Ex vivo fluorescence confocal microscopy: the first application for real-time pathological examination of prostatic tissue. *BJU Int* 2019;124:469-76. DOI PubMed
 49. Bertoni L, Puliatti S, Reggiani Bonetti L, et al. Ex vivo fluorescence confocal microscopy: prostatic and periprostatic tissues atlas and evaluation of the learning curve. *Virchows Arch* 2020;476:511-20. DOI PubMed