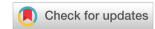

Review

Open Access



# Two birds one stone: lymphatic and breast reconstruction with autologous tissue

**Shayan M. Sarrami, Carolyn De La Cruz**

Department of Plastic Surgery, University of Pittsburgh Medical Center, Pittsburgh, PA 15213, USA.

**Correspondence to:** Dr. Carolyn De La Cruz, Department of Plastic Surgery, University of Pittsburgh Medical Center, 5200 Centre Ave Suite 703, Pittsburgh, PA 15213, USA. E-mail: delacruz@upmc.edu

**How to cite this article:** Sarrami SM, De La Cruz C. Two birds one stone: lymphatic and breast reconstruction with autologous tissue. *Plast Aesthet Res* 2024;11:13. <https://dx.doi.org/10.20517/2347-9264.2024.06>

**Received:** 10 Jan 2024 **First Decision:** 27 Mar 2024 **Revised:** 3 Apr 2024 **Accepted:** 9 Apr 2024 **Published:** 12 Apr 2024

**Academic Editor:** Tine Engberg Damsgaard **Copy Editor:** Yanbing Bai **Production Editor:** Yanbing Bai

## Abstract

Patients with breast cancer-related lymphedema (BCRL) commonly present with both debilitating upper extremity symptoms and the need for breast reconstruction. By combining autologous flaps with physiologic lymphatic surgery, postmastectomy patients with BCRL can obtain aesthetic breast reconstruction and lymphedema management in a single operation. Lymph node transfer to an area of lymphatic obstruction creates a healthy lymphatic bridge and restores physiologic flow. Early success and improved understanding of vascularized lymph node transfer (VLNT) physiology have led to the rapid development of numerous flap options and modalities. Several studies have shown the efficacy of combining autologous breast reconstruction with VLNT. Chimeric flaps using inguinal nodes, lateral thoracic nodes, or omentum aim to construct an aesthetic breast and improve lymphatic function. In this article, we will detail the surgical options that accomplish autologous breast reconstruction and restore the lymphatic network in a single operation.

**Keywords:** Breast reconstruction, lymphedema, breast cancer-related lymphedema, vascularized lymph node transfer

## INTRODUCTION

Patients with breast cancer-related lymphedema (BCRL) commonly present with both debilitating upper extremity symptoms and the need for breast reconstruction. Approximately 20% of patients receiving



© The Author(s) 2024. **Open Access** This article is licensed under a Creative Commons Attribution 4.0 International License (<https://creativecommons.org/licenses/by/4.0/>), which permits unrestricted use, sharing, adaptation, distribution and reproduction in any medium or format, for any purpose, even commercially, as long as you give appropriate credit to the original author(s) and the source, provide a link to the Creative Commons license, and indicate if changes were made.



mastectomies develop BCRL and the incidence significantly increases in patients receiving axillary lymph node dissection and radiation<sup>[1-4]</sup>. The mainstay of treatment for lymphedema continues to be complete decompression therapy; however, if conservative management fails, surgical intervention may be needed<sup>[5-7]</sup>. The two current options for lymphedema management are debulking and physiologic procedures. Debulking is used in patients with severely nonfunctional lymphatic systems and provides symptom relief. New treatment modalities focus on physiologic reconstruction using lymphovenous bypass or vascularized lymph node transfer (VLNT), aiming to restore lymphatic function and improve lymph flow<sup>[5,7,8]</sup>. By combining autologous flaps with physiologic lymphatic surgery, postmastectomy patients with BCRL can obtain aesthetic breast reconstruction and lymphedema management in a single operation.

The aim of lymph node transfer to an area of lymphatic obstruction is to create a healthy lymphatic bridge and restore physiologic flow. At the recipient site, the VLNT will form lymphatic connections and promote new channel growth<sup>[9-11]</sup>. This is mediated by the production of VEGF-C which stimulates lymphangiogenesis in the donor and recipient tissue<sup>[10,12,13]</sup>. Additionally, it is hypothesized that the transferred lymph nodes act as a pump that absorbs interstitial fluid<sup>[14-16]</sup>. Lymph flow has been mapped through spontaneous connections with the VLNT flap, which then drains into the venous outflow<sup>[10]</sup>. Early success and improved understanding of VLNT physiology have led to the rapid development of numerous lymph node transfer options and modalities<sup>[5]</sup>.

Several studies have shown the efficacy of combining autologous breast reconstruction with VLNT<sup>[4,8,16]</sup>. Chimeric flaps using inguinal nodes, lateral thoracic nodes, or omentum aim to construct an aesthetic breast and improve lymphatic function. In this article, we will describe the surgical options that accomplish autologous breast reconstruction and restore the lymphatic network in a single operation.

## PATIENT SELECTION

The combined autologous breast reconstruction and lymph node transfer are indicated for patients with upper extremity lymphedema and significant soft tissue breast defects. These patients tend to have a history of breast cancer with mastectomies and usually have received axillary dissection and radiation<sup>[2,17]</sup>. If lymphedema symptoms progress after 6 months of conservative management, surgical intervention is advised<sup>[5]</sup>. A multidisciplinary team is necessary to optimize patients for the operation. It is preferred that breast cancer patients complete radiation treatment with their oncologist and wait 6 months before attempting surgery [Table 1]. Additionally, improving the patient's health and nutrition can play a large role in the outcomes of autologous reconstruction and lymphedema surgery<sup>[4,5,7]</sup>. Prior surgical history, such as cesarean section or thoracic node dissection, is also important and may limit certain flap options.

## IMAGING

Though the utility of perforator mapping is debated for autologous free flap breast reconstruction, it is widely accepted that lymphography is a vital component of lymphatic surgery<sup>[18,19]</sup>. Commonly, intraoperative reverse lymphatic mapping of the donor site is utilized to identify lymph nodes draining the extremity that should be avoided during flap harvest. In this technique, pioneered by Dayan *et al.*, technetium is injected into the webspace of the extremity to identify nodes draining the leg using a gamma probe<sup>[18]</sup>. Congruently, indocyanine green (ICG) is injected in the trunk and identifies nodes to be included within the flap using a near-infrared imaging device. The main purpose of this practice is to prevent donor site lymphedema of the extremity<sup>[5,14,16]</sup>. In this technique, it is recommended that a 10-second count with the gamma probe that is within 10% of the hottest node should not be harvested. Isosulfan blue can be used in place of technetium to visualize the lymphatic vessels intraoperatively. Other imaging options include lymphoscintigraphy, which can be obtained preoperatively to roughly identify nodes draining the extremity.

**Table 1. Indications for autologous breast reconstruction with vascularized lymph node transfer**

- Delayed breast reconstruction with arm lymphedema
- Immediate breast reconstruction with arm lymphedema
- Revision breast reconstruction following complications associated with arm lymphedema
- > 6 months of conservative management
- > 6 months following radiation therapy

This older lymphography method can also assess the lymphatic flow rate<sup>[8]</sup>. Additionally, ICG can be useful in the lymphedematous limb to map the areas of lymphatic disruption and level of dermal backflow<sup>[6,8]</sup>. A combination of techniques may be required to provide adequate care when planning an autologous flap with a VLNT.

## RECONSTRUCTIVE OPTIONS

### Deep inferior epigastric perforator flap with inguinal lymph nodes

The deep inferior epigastric perforator (DIEP) flap remains a reliable and well published autologous option for breast reconstruction<sup>[6,8,13]</sup>. With the advent of lymph node transfers, the inguinal nodes became a common donor for upper extremity lymphedema<sup>[5,7]</sup>. This is partially due to the consistent anatomy of the region and numerous lymph nodes available for harvest<sup>[20-22]</sup>. Conjoining DIEP flap harvest with inguinal lymph nodes is the most popular option for patients suffering from BCRL and interested in breast reconstruction<sup>[16]</sup>.

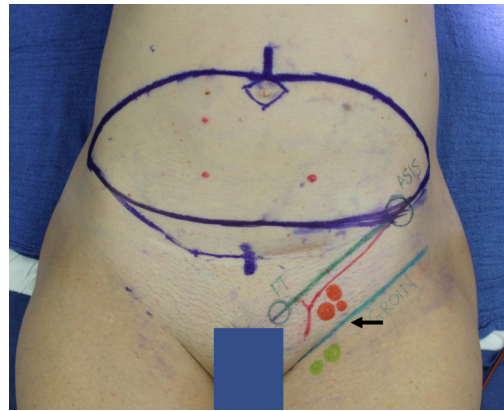
#### *Technical considerations*

This approach was first described by Saaristo *et al.*<sup>[1]</sup>. Typically, the nodes can be safely harvested above the groin crease, at or below the inguinal ligament, and lateral to the femoral vessels, but this does not consistently correlate with lymphatic drainage pathways [Figure 1]<sup>[8,18]</sup>. Reverse lymphatic mapping prior to incision allows surgeons to navigate the inguinal lymph node basin in real time [Figure 2]. For favorable inset into the recipient site, the contralateral lymph nodes and ipsilateral deep inferior epigastric artery are harvested<sup>[16]</sup>. Flap dissection begins inferiorly, identifying the superficial inferior epigastric perforator and the superficial circumflex iliac perforator (SCIP)<sup>[13,23]</sup>. The inguinal nodes are commonly reliant on the SCIP. A wide adipofascial margin should be maintained to avoid lymph node devascularization [Figure 3]. The DIEP flap is then harvested in the usual fashion. Of note, the transverse rectus abdominis myocutaneous flap can also be used, but it significantly increases donor site morbidity<sup>[6,7]</sup>.

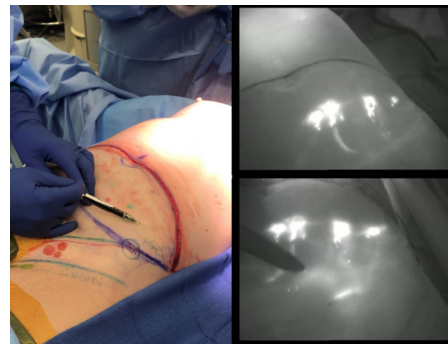
The DIEP flap is commonly anastomosed to the internal mammary vessels, but axillary vessels can also be used when necessary<sup>[8,16]</sup>. Dissecting recipient axillary vessels also accomplishes scar release which is recognized as a vital component of lymphedema management<sup>[5,7]</sup>. Ideally, the inguinal lymph nodes are inset in the axilla with an additional anastomosis and vascular supply. The thoracodorsal vessel, or its branches, provides the best match in both orientation and size. A bipedicle flap may not always be necessary<sup>[1,8,23]</sup>. Often, the inguinal nodes maintain adequate perfusion through attachment to the DIEP flap. This can be assessed using ICG angiography<sup>[6,23]</sup>. Some recommend separate venous anastomosis for the lymph node flap to support lymphatic outflow<sup>[8]</sup>. Alternatively, the VLNT can be separated entirely from the DIEP flap [Figure 4]. This allows for flexibility in DIEP flap positioning and orientation<sup>[24]</sup>.

#### *Outcomes*

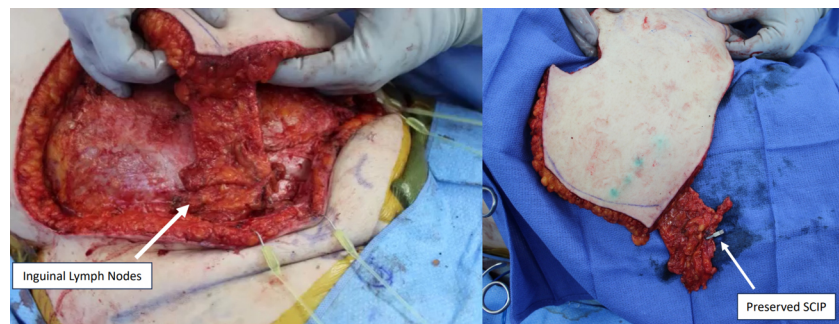
The DIEP flap with inguinal lymph node transfer has shown BCRL improvement since its inception. In the 9-patient study originally published by Saaristo *et al.*, 6 had a reduction in upper limb circumference, and of the patients who underwent lymphoscintigraphy, 5 of the 6 showed improved lymphatic drainage<sup>[1]</sup>. These results were supported by the study from Nguyen *et al.* of 29 patients who had a mean volume reduction of



**Figure 1.** Preoperative markings of DIEP flap with inguinal lymph node harvest. Femoral vessels are drawn in red. The arrow depicts the groin crease with the lymph nodes available for harvest above (red) and the lymph nodes draining the leg below (green). DIEP: deep inferior epigastric perforator.

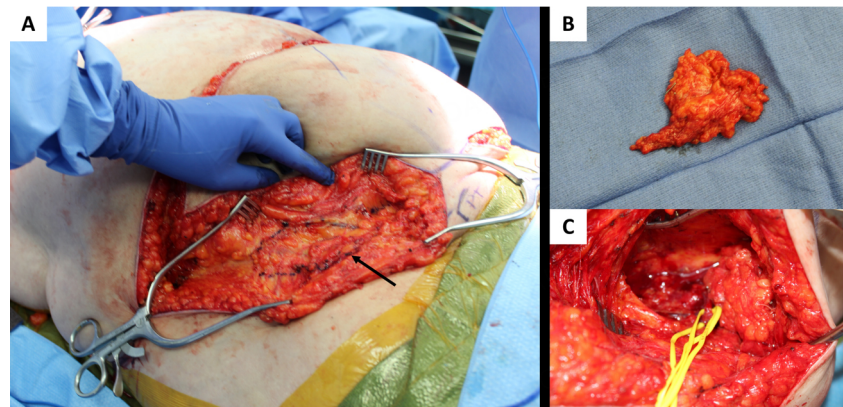


**Figure 2.** Lymphatic mapping of DIEP flap with inguinal lymph nodes using ICG. The fluorescent dye shows lymphatic drainage pathways into the inguinal lymph nodes. ICG: indocyanine green; DIEP: deep inferior epigastric perforator.



**Figure 3.** (Right) Inguinal lymph node harvest attached to DIEP flap; (Left) Preserved superficial circumflex iliac perforator for anastomosis into the axilla. DIEP: deep inferior epigastric perforator.

10% in the arm 90 days postop<sup>[16]</sup>. Using a lymphedema questionnaire focused on physical, psychological, and social factors, Winters *et al.* and De Brucker *et al.* have shown significant improvement in quality of life after surgery<sup>[25,26]</sup>. Both authors reported a discontinuation of compression garments in their populations (40% and 60%, respectively) and a reduction in physiotherapy (60% and 100%, respectively). In patients with recurrent infections of the arm, Winters and De Brucker also report cessation or reduction following surgery; however, the population size is limited.



**Figure 4.** (A) Identification of inguinal lymph nodes; (B) Harvested inguinal lymph node flap; (C) Vascularized inguinal lymph node anastomosis to axillary blood supply.

### Benefits

In addition to its early promising results, the DIEP flap with inguinal lymph nodes has many added benefits [Figure 5]<sup>[1]</sup>. The flap size allows for adequate aesthetic reconstruction and easy lymph node insertion into the axilla. Nguyen *et al.* report the utility of a hemi-abdominal flap which can be designed for patients undergoing bilateral reconstruction or have a prior midline incision<sup>[16]</sup>. Lastly, the DIEP flap has a very reliable vascular supply which has a low failure rate and has repeatedly shown good perfusion of the inguinal nodes<sup>[8]</sup>.

### Pitfalls

In addition to the risks associated with the DIEP flap alone, the VLNT flap also presents complications<sup>[27]</sup>. Inguinal lymph node anastomosis to the thoracodorsal artery ensures a strong vascular supply but disrupts the pedicle to the latissimus dorsi flap. This sacrifices the latissimus dorsi as a future lifeboat for breast reconstruction and is another reason some choose not to construct a bipedicle flap<sup>[5,7]</sup>. Inguinal node dissection also results in hollowing of the groin, which can complicate abdominal site closure. This is generally well addressed using local tissue advancement<sup>[8]</sup>. In the clinical studies previously discussed, donor site complications occurred in 14%-22% of patients. The most common complication was seroma formation and was treated conservatively<sup>[16,25,26]</sup>. As with all VLNT flaps, there is a risk of donor site lymphedema, but very few reports of lower extremity lymphedema have been documented with the use of reverse lymphatic mapping [Table 2]<sup>[5]</sup>.

### Latissimus dorsi flap with lateral thoracic lymph nodes

A growing number of studies have reported success using the latissimus dorsi (LD) flap in conjunction with a lateral thoracic lymph node transfer<sup>[4,28]</sup>. Becker *et al.* first introduced the idea of a thoracodorsal artery perforator flap, which was then popularized by Inbal *et al.*<sup>[4,7]</sup>. This technique has been described as both a pedicled flap for BCRL management and a free flap for distant lymphatic defects like the groin and lower extremity<sup>[5,7,11]</sup>.

### Technical considerations

The chimeric flap is designed more anterior than the classic LD flap<sup>[4]</sup>. This positioning captures the majority of lymph nodes which sit around the mid-axillary line [Figure 6A]. In 60% of cases, the lateral thoracic vessels perfuse the lymph nodes located at the superior border of the muscle. In the other 40% of people, the lymph nodes are located at the distal end of the thoracodorsal vessel and supplied by the serratus anterior branches<sup>[7]</sup>. ICG lymphography prior to surgical incision is useful to insure the availability of lymph

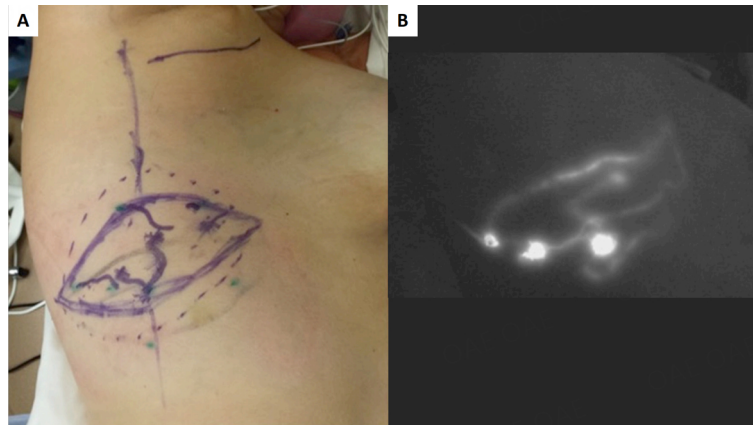


**Table 2. Surgical options for autologous breast reconstruction with vascularized lymph node transfer**

	Outcomes	Benefits	Pitfalls	Donor site lymphedema
DIEP flap with inguinal nodes	Mean volume reduction: 10%-31% <sup>[16,25]</sup> Discontinuation of compression therapy: 40%-60% <sup>[25,26]</sup> Reduction of physiotherapy: 60%-100% <sup>[25,26]</sup>	Reliable vascular supply to flap and lymph nodes Large amount of soft tissue for breast reconstruction	Bipedicle flap design Donor site hollowing wound breakdown: 16%-20% <sup>[16,26]</sup> Donor site seroma: 2%-12% <sup>[16,25,26]</sup>	1.6% <sup>[29]</sup>
LD Flap with lateral thoracic nodes	Mean volume reduction: 44.4%-48% <sup>[4,28]</sup>	Pedicled flap design	High overall complication rate: 13.2% <sup>[29]</sup> 18.4% <sup>[29]</sup> Lymphocele: 2.5% <sup>[29]</sup>	
SCIP Flap with inguinal nodes	Discontinuation of compression therapy ( <i>n</i> = 1): 100% <sup>[32]</sup> Discontinuation of physiotherapy ( <i>n</i> = 3): 100% <sup>[26]</sup> Change in quality-of-life score* ( <i>n</i> = 3): 2% <sup>[25,26]</sup>	Flap harvest does not invade underlying fascia	Overall complication rate: 10.9% <sup>[29]</sup> Lymphocele or seroma: 7.7% <sup>[29]</sup>	1.6% <sup>[29]</sup>
Vascularized omentum lymphatic transfer	Mean volume reduction ( <i>n</i> = 7): 0%-77% <sup>[44]</sup>	No disruption of donor site lymphatic drainage	Intra-abdominal surgery Risk of ileus (2.2%), transient pancreatitis (1.1%) <sup>[45]</sup>	0% <sup>[29,45]</sup>

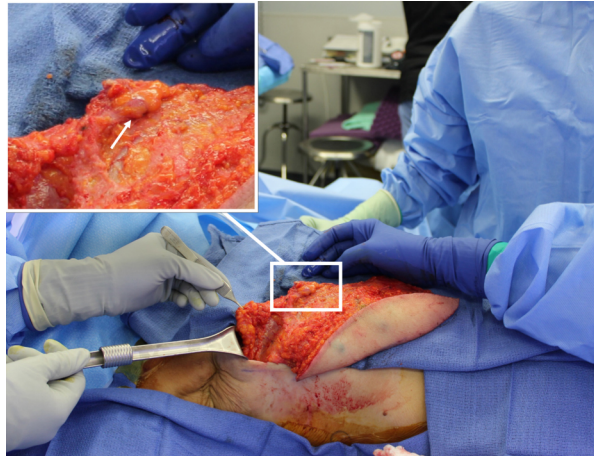
DIEP: deep inferior epigastric perforator; LD: latissimus dorsi; SCIP: superficial circumflex iliac perforator; \*: Quality-of-life assessed using Upper Limb Lymphedema-27 Questionnaire

**Figure 5.** Preoperative (right) and postoperative (left) images of DIEP flap breast reconstruction with inguinal lymph nodes for the breast cancer patient with a history of upper extremity lymphedema. DIEP: deep inferior epigastric perforator.



**Figure 6.** (A) Preoperative markings of the latissimus dorsi flap with lateral thoracic nodes made around the mid-axillary line; (B) ICG lymphography is used to design the flap around healthy lateral thoracic nodes. ICG: indocyanine green.

nodes in the vicinity of the flap [Figure 6B]<sup>[4,5]</sup>. Flap harvest can be muscle-sparing, though larger defects may require further muscle dissection to provide appropriate volume<sup>[4,7]</sup>. The adipolymphatic tissue is harvested anterior to the LD but should remain inferior to the pectoral muscle border [Figure 7]. Limiting lymphatic harvest to level 1 nodes protects lymph drainage of the arm<sup>[7]</sup>. Reverse mapping of the upper extremity could also be used<sup>[18]</sup>. Finally, the surgeon should ensure adequate scar release prior to flap rotation and lymph node positioning in the axilla.



**Figure 7.** Harvested latissimus dorsi flap with lateral thoracic node dissection (arrow).

### Outcomes

There are limited high-level studies reporting the use of chimeric LD flaps with vascularized lymph nodes and even fewer focusing on BCRL treatment<sup>[5,7]</sup>. Vibhakar *et al.* published the first case of total autologous breast reconstruction with a pedicled LD flap and transfer of lateral thoracic nodes. At 10 weeks postop, the patient had a significant volume reduction of 44.4% with a complete resolution of her symptoms<sup>[28]</sup>. This result can be backed by a case series from Inbal *et al.*, reporting on 7 patients with BCRL<sup>[4]</sup>. They utilized a muscle-sparing technique to correct minor defects in the axilla with a pedicled fasciocutaneous VLNT. In their study assessing the use of this chimeric flap, they found a volume differential reduction of 48% at three months postop and showed improvement in quality-of-life scores<sup>[4]</sup>.

### Benefits

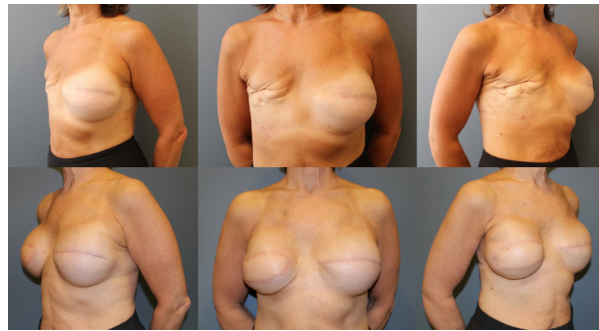
This provides an excellent chimeric flap option in patients with contraindications to an abdominal free flap or had a failed abdominal-based reconstruction [Figure 8]<sup>[28]</sup>. This technique does not require microsurgical anastomosis and maintains a reliable blood supply to the muscle and adipofascial tissue.

### Pitfalls

Prior to surgery, it should be considered that breast cancer treatment could have disturbed the lymphatics and blood vessels in the lateral thoracic region. Proper preoperative imaging with ICG is necessary to ensure viable lymph nodes are available for harvest with no concerning signs of dermal backflow or lymphatic disruption. Preoperative imaging may help reduce the increased complications associated with lateral thoracic node dissection<sup>[5,27]</sup>. In a systematic review by Scaglioni *et al.* comparing multiple lymph node transfers, the lateral thoracic nodes had the highest overall complication rate of 18.4% and the highest donor site complication rate of 15.8%<sup>[29]</sup>. These included iatrogenic lymphedema, lymphocele, and long-term pain. A final consideration is that flap volume alone is often inadequate to provide proper cosmesis. This reconstruction is traditionally combined with an implant, but Abdou *et al.* have recently pioneered the use of immediate fat grafting into the LD flap as a completely autologous option<sup>[30]</sup>.

### Superficial circumflex iliac perforator flap with inguinal lymph nodes

The superficial circumflex iliac perforator (SCIP) flap has begun to regain popularity<sup>[31]</sup>. Current research supports the use of the SCIP flap for small breast reconstruction<sup>[32,33]</sup>. The adipocutaneous flap contains lymphatic channels within the soft tissue, hypothesized to stimulate lymphangiogenesis at the recipient site, improving lymphatic function<sup>[9,34,35]</sup>. The SCIP flap can be raised with underlying inguinal lymph nodes to



**Figure 8.** Preoperative (top row) and postoperative (bottom row) images of right latissimus dorsi flap breast reconstruction with an implant and harvested lateral thoracic lymph nodes.

ensure a robust lymphatic response when inset in a lymphedematous region<sup>[5,7]</sup>.

#### *Technical considerations*

Prior to incision, reverse lymphatic mapping should be implemented to ensure the protection of lymph nodes draining the lower extremity<sup>[18]</sup>. Width and bulk of the flap are dependent on patient body habitus and can be determined with a pinch test<sup>[33]</sup>. During flap dissection, a wide margin of adipose tissue should be maintained to maximize volume and avoid skeletonizing the lymph nodes<sup>[5,7]</sup>. Once the perforator is identified, it is followed down to the source vessels [Figure 9]. If necessary, opening the deep fascia will help obtain a longer pedicle with increased luminal diameter<sup>[31]</sup>. This is helpful during flap inset but increases donor site morbidity risks. Ideally, the lymph nodes are positioned in the axilla and anastomosis can be made to the lateral thoracic or internal mammary vessels<sup>[32,33]</sup>.

As described by Yano *et al.*, a bipedicle flap based on the SCIP and the superficial inferior epigastric artery can also provide a robust reconstructive option without penetrating the deep fascia<sup>[36]</sup>. In their study, the flap showed good perfusion over a large territory. Additionally, they preserved the DIEP as an alternative vascular option<sup>[24,36]</sup>.

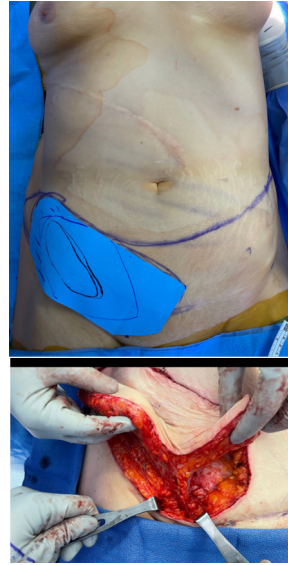
#### *Outcomes*

To date, Akita *et al.* have reported the only use of a chimeric SCIP flap with inguinal nodes for a BCRL patient requiring partial breast reconstruction<sup>[32]</sup>. They were able to adequately augment the breast with adipose tissue while positioning the skin paddle and lymph nodes in the axilla. At 12 months postop, the patient was able to discontinue compression therapy of her arm<sup>[32]</sup>. Similarly favorable results were found in the quality-of-life study by De Brucker *et al.*<sup>[26]</sup>. Three patients received SCIP flap reconstruction with lymph nodes for BCRL treatment; however, the small skin paddle was only included for flap monitoring. At a follow-up of 12-31 months, patients had improved quality of life scores and discontinued all physiotherapy<sup>[26]</sup>. This chimeric flap has shown successful soft tissue and lymphatic reconstruction in the upper extremity [Figure 10].

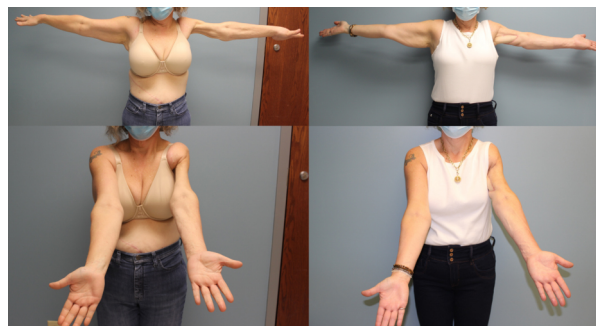#### *Benefits*

The major benefit of the SCIP flap is its minimal donor site morbidity. This surgical option preserves the deep fascia, preventing abdominal bulges and herniations<sup>[33,36]</sup>. The donor site scar is also relatively low and lateral, keeping it well concealed<sup>[5,7]</sup>. Additionally, two SCIP flaps can be planned and harvested for bilateral breast reconstruction if necessary<sup>[33]</sup>.





**Figure 9.** Preoperative planning of SCIP flap with inguinal lymph node harvest (top). Dissection of flap perforator and inguinal lymph nodes (bottom). SCIP: superficial circumflex iliac perforator.



**Figure 10.** Preoperative (right) and postoperative (left) images of SCIP flap for left upper extremity defect following Ewing sarcoma dissection and lymphedema development. The patient showed successful lymphedema management and complete return to daily activities within a year postoperatively. SCIP: superficial circumflex iliac perforator.

### Pitfalls

The SCIP flap works best for small or partial breast reconstructions due to its limited volume. To increase flap bulk, a bipedicle flap design or fat grafting may be useful<sup>[27,30,36]</sup>. It should also be noted that this procedure qualifies as super microsurgery due to the extremely small lumen size of the superficial vessels. This makes for a difficult anastomosis, especially in an irradiated field<sup>[5]</sup>. To avoid vessel size mismatch, anastomoses are commonly made to small vascular branches within the axilla<sup>[33]</sup>. In the current literature reporting the use of these chimeric flaps, there have been very few notable complications<sup>[26,32]</sup>. In the systematic review by Scaglioni *et al.*, they combined all inguinal lymph node transfers, including combined DIEP flap harvest, but a majority were free inguinal node flaps based on the SCIP<sup>[29]</sup>. The donor site complication rate was 10.9%, mainly comprising lymphoceles and seroma formation. Three patients, out of the 195 inguinal node transfers, developed lymphedema of their lower extremity<sup>[29]</sup>. As discussed earlier, this risk is limited with the use of dual imaging techniques<sup>[18]</sup>.

### Vascularized omentum lymphatic transplant

In plastic surgery, the omental flap has been utilized for its neovascularization and immunologic function in many surgical situations<sup>[37]</sup>. Goldsmith first described its role in lymphedema treatment in the 1960s, and it has been utilized for various lymphatic disruptions since that time<sup>[38,39]</sup>. In BCRL specifically, the omental flap has been useful in improving lymphatic flow and filling the dead space within the axilla<sup>[5,40]</sup>. This flap can be used alone to create aesthetically contoured breast or easily combined with other breast reconstruction options<sup>[41,42]</sup>. Nguyen *et al.* have shown promising results at complete autologous reconstruction, utilizing the omental flap in an acellular dermal matrix (ADM) pocket following skin-sparing or nipple-sparing mastectomy<sup>[43]</sup>.

#### Technical considerations

The omental flap is based on the gastroepiploic vessels which should be mapped preoperatively to ensure sufficient vascularity<sup>[5]</sup>. The flap is harvested laparoscopically and is a flat and malleable tissue. To increase flap volume, Nguyen *et al.* describe intra-flap fat grafting through direct visualization<sup>[37,43]</sup>. This is particularly useful when dividing the omental flap for bilateral reconstructions. The omentum is then placed in an ADM pocket which has been contoured around a saline breast sizer<sup>[37,44]</sup>. A medial opening is constructed for the pedicle, and a lateral opening allows for the vascularized lymph nodes to be positioned in the axilla. The gastroepiploic vessels are anastomosed to the internal mammary artery and the flap is inset in the mastectomy breast pocket<sup>[44]</sup>. Nguyen *et al.* favor immediate reconstruction after skin-sparing or nipple-sparing mastectomy, but delayed reconstruction with a tissue expander is also viable<sup>[37,43]</sup>.

#### Outcomes

Small case series using the omental flap for complete breast reconstruction have been published by Nguyen *et al.*<sup>[43,44]</sup>. Their group has shown great cosmetic results with good symmetry in patients with smaller breasts. In their 3-patient study outlining their surgical technique for immediate breast reconstruction with omental flap fat grafting, patients reported satisfaction based on BREAST-Q questionnaires<sup>[43]</sup>. A similar study from their group assessed omental flap use in BCRL patients; however, reconstruction with and without abdominal-based free flaps was included. In this 7-patient case series, there was a wide range of arm volume reduction from 0%-77% at about 10 months postop<sup>[44]</sup>. In a larger systematic review of omental lymph node transfer for upper extremity lymphedema by Jarvis *et al.*, the volume reduction ranged from 22.7% to 39.5%. There was also noted improvement in patient-reported outcomes and a reduction in cellulitis episodes postoperatively<sup>[45]</sup>.

#### Benefits

The omental flap has shown reliability in several surgical situations and has been well published as a treatment method for lymphatic disorders<sup>[37]</sup>. In the current literature, there has been no reported occurrence of donor site lymphedema or lymphatic disruption following omental flap harvest<sup>[5,46]</sup>. This has made it a very attractive option for lymphatic reconstruction in recent years.

#### Pitfalls

Despite the use of a laparoscopic approach, there are still many associated risks of intra-abdominal surgery in addition to free flap transfer. In a systematic review by Jarvis *et al.* assessing omental flap use for upper extremity lymphedema with a total of 91 patients, the complication rate was 17.6%<sup>[45]</sup>. Most complications were minor, though there were some reports of flap compromise and loss, ileus, transient pancreatitis, and infection<sup>[45]</sup>. There is also a risk of converting to an open operation and creating a large unaesthetic scar<sup>[5]</sup>. Additionally, estimating the size of the omentum is difficult prior to surgery and the tissue has been criticized for being too small for total breast reconstruction<sup>[41,43]</sup>. Nguyen also note that the malleable tissue

can result in rippling of the breast if positioned improperly<sup>[37]</sup>.

### Autologous reconstruction

There is a growing body of literature finding that autologous flaps without lymph nodes can improve lymphatic flow<sup>[3,47]</sup>. Slavin *et al.* first recognized the ingrowth of lymphatic channels into free tissue transfers in 1997<sup>[48]</sup>. This has been more recently supported by Yamamoto *et al.*<sup>[9]</sup>. In his retrospective study, 38 patients underwent indocyanine green lymphography after free flap or replant operations and 63% showed lymphatic flow restoration. Still, a superior lymphatic response with VLNT has been shown in a handful of studies<sup>[3,26,47]</sup>. In a systematic review by Siotos *et al.* comparing autologous breast reconstructing in BCRL patients with and without VLNT, 84% of patients who received the chimeric flap option reported symptomatic improvement versus 22% of patients who had reconstruction alone<sup>[3]</sup>. Lymph node transfer appears to offer a more robust lymphatic response which improves patients' overall outcomes. Additionally, breast reconstruction and VLNT can be completed in a staged approach, but preventative and early treatment of lymphatic disruptions is ideal for the BCRL population.

## DISCUSSION

As the number of patients anticipated to develop lymphedema increases with growing breast cancer treatment, plastic surgeons will certainly see patients who are suffering from postmastectomy lymphedema while also seeking breast reconstruction. Due to advancements in lymphedema surgery and a growing understanding of the lymphatic system, several reconstructive options are now available<sup>[7,8,23]</sup>. The aims of surgical intervention are to create aesthetic breasts and promote lymphatic flow to holistically treat these complex patients in a single operation.

Patients seeking reconstruction following breast cancer treatment often present difficult microsurgical cases, especially when complicated by the presence of lymphedema. These patients typically have undergone axillary dissection and radiation which disrupts normal and healthy blood flow<sup>[2,17]</sup>. As lymphedema progresses, the cutaneous and subcutaneous tissue becomes fibrotic and is associated with recurrent infections<sup>[49]</sup>. While most microsurgeons can perform autologous breast reconstruction safely, this multifaceted procedure typically requires additional training and experience to produce optimal results<sup>[5,32]</sup>. The increased risks associated with adding a VLNT to an autologous flap can lead to severe complications. However, surgical advancements have continued to make this reconstructive option safe and efficient<sup>[8,18]</sup>.

Lymphedema affecting the chest and abdomen as a result of breast cancer treatment is underdiscussed in the literature. Similar to upper extremity lymphedema, truncal lymphedema can cause pain, swelling, and fibrotic skin<sup>[50]</sup>. Currently, there are no individualized treatment methods for this disease process. Traditional management using complete decompression therapy or compression garments is often inadequate. Autologous reconstruction in conjunction with VLNT to the axilla may help restore lymphatic flow to the chest by providing healthy tissue and creating new lymphatic pathways. Of note, breast reconstruction using an omental flap and ADM pocket, as discussed earlier, is not an ideal treatment option for patients with chest lymphedema. This reconstructive option, similar to implants, requires healthy mastectomy skin flaps otherwise it may result in severe complications<sup>[37]</sup>.

The recipient site of a VLNT flap for treatment of upper extremity lymphedema can be the axilla, elbow, or wrist<sup>[14,22]</sup>. Any site can be combined with simultaneous breast reconstruction. Recipient site location depends largely on surgeon preference. Those who support the theory that lymph nodes act as a pump to absorb interstitial fluid prefer to position the VLNT flap distally. This allows the flap to work with gravity<sup>[14,15]</sup>. Additionally, distal flaps may be especially useful in patients who have localized lymphedema of

their lower arm and hand<sup>[46]</sup>. Surgeons who believe that VLNT works by promoting lymphangiogenesis often position the lymph nodes in the axilla to restore physiologic lymph flow<sup>[4,7,8]</sup>. Placement of the flap in the axilla is also more cosmetically appealing, because distal flaps are bulky and may require a skin graft<sup>[22]</sup>. Successful lymphedema management has been described at all three recipient sites<sup>[14]</sup>.

A growing body of literature in the field of lymphedema calls for improved preventative lymphatic surgery options<sup>[51-53]</sup>. Standard practice at several institutions now supports immediate lymphatic reconstruction at the time of axillary dissection<sup>[51,52,54]</sup>. Similarly, preventative VLNT at the time of mastectomy is now being tested. Immediate breast reconstruction has also been correlated to reduced lymphedema development, but there are considerable confounding variables in these studies<sup>[2,3]</sup>. Currently, there is not enough evidence to state the true benefit of combining immediate autologous reconstruction with preventative lymphatic surgery, but we are confident the literature will continue to grow.

This literature review has several limitations. Due to the novelty of the topic, there is a relatively small number of studies available. Most of the cited outcomes, benefits, and pitfalls are provided from case series which can have highly variable results. This makes it especially difficult to directly compare chimeric flap options. Additionally, evaluation of our own results is limited by the retrospective nature of the review and a small patient population.

## CONCLUSION

Advancements in the field of plastic and lymphatic surgery have created multiple autologous breast reconstruction procedures that can be combined with a lymph node transfer in a single operation. Although each option has distinct advantages and disadvantages, all of them adequately restore breast and lymphatic anatomy.

## DECLARATIONS

### Authors' contributions

Played a role in the conception of the work, research of included topics, and drafted the manuscript: Sarrami SM

Outlined key concepts for the work and provided substantial revisions: De La Cruz C

### Availability of data and materials

Not applicable.

### Financial support and sponsorship

None.

### Conflicts of interest

All authors declared that there are no conflicts of interest.

### Ethical approval and consent to participate

Consent has been gained for all images and no IRB approval is required. Informed consent has been obtained from patients.

### Consent for publication

Written informed consent for publication has been obtained for all patient images.

**Copyright**

© The Author(s) 2024.

**REFERENCES**

1. Saaristo AM, Niemi TS, Viitanen TP, Tervala TV, Hartiala P, Suominen EA. Microvascular breast reconstruction and lymph node transfer for postmastectomy lymphedema patients. *Ann Surg* 2012;255:468-73. DOI PubMed
2. Gillespie TC, Sayegh HE, Brunelle CL, Daniell KM, Taghian AG. Breast cancer-related lymphedema: risk factors, precautionary measures, and treatments. *Gland Surg* 2018;7:379-403. DOI PubMed PMC
3. Siotos C, Hassanein AH, Bello RJ, et al. Delayed breast reconstruction on patients with upper extremity lymphedema: a systematic review of the literature and pooled analysis. *Ann Plast Surg* 2018;81:730-5. DOI
4. Inbal A, Teven CM, Chang DW. Latissimus dorsi flap with vascularized lymph node transfer for lymphedema treatment: technique, outcomes, indications and review of literature. *J Surg Oncol* 2017;115:72-7. DOI PubMed
5. Chang EI, Chu CK, Hanson SE, Selber JC, Hanasono MM, Schaverien MV. Comprehensive overview of available donor sites for vascularized lymph node transfer. *Plast Reconstr Surg Glob Open* 2020;8:e2675. DOI PubMed PMC
6. Forte AJ, Cinotto G, Boczar D, et al. Lymph node transfer combined with deep inferior epigastric perforators and transverse rectus abdominis myocutaneous procedures: a systematic review. *Gland Surg* 2020;9:521-7. DOI PubMed PMC
7. Becker C, Vasile JV, Levine JL, et al. Microlymphatic surgery for the treatment of iatrogenic lymphedema. *Clin Plast Surg* 2012;39:385-98. DOI
8. Chang EI, Masià J, Smith ML. Combining autologous breast reconstruction and vascularized lymph node transfer. *Semin Plast Surg* 2018;32:36-41. DOI PubMed PMC
9. Yamamoto T, Iida T, Yoshimatsu H, Fuse Y, Hayashi A, Yamamoto N. Lymph flow restoration after tissue replantation and transfer: importance of lymph axiality and possibility of lymph flow reconstruction without lymph node transfer or lymphatic anastomosis. *Plast Reconstr Surg* 2018;142:796-804. DOI PubMed
10. Cheng MH, Huang JJ, Wu CW, et al. The mechanism of vascularized lymph node transfer for lymphedema: natural lymphaticovenous drainage. *Plast Reconstr Surg* 2014;133:192e-8e. DOI
11. Yamamoto T, Yoshimatsu H, Yamamoto N. Complete lymph flow reconstruction: a free vascularized lymph node true perforator flap transfer with efferent lymphaticolymphatic anastomosis. *J Plast Reconstr Aesthet Surg* 2016;69:1227-33. DOI PubMed
12. Yan A, Avraham T, Zampell JC, Aschen SZ, Mehrara BJ. Mechanisms of lymphatic regeneration after tissue transfer. *PLoS One* 2011;6:e17201. DOI PubMed PMC
13. Dancy A, Nassimzadeh A, Nassimzadeh M, Warner RM, Waters R. A chimeric vascularised groin lymph node flap and DIEP flap for the management of lymphoedema secondary to breast cancer. *J Plast Reconstr Aesthet Surg* 2013;66:735-7. DOI
14. Raju A, Chang DW. Vascularized lymph node transfer for treatment of lymphedema: a comprehensive literature review. *Ann Surg* 2015;261:1013-23. DOI PubMed
15. Lin CH, Ali R, Chen SC, et al. Vascularized groin lymph node transfer using the wrist as a recipient site for management of postmastectomy upper extremity lymphedema. *Plast Reconstr Surg* 2009;123:1265-75. DOI
16. Nguyen AT, Chang EI, Suami H, Chang DW. An algorithmic approach to simultaneous vascularized lymph node transfer with microvascular breast reconstruction. *Ann Surg Oncol* 2015;22:2919-24. DOI PubMed
17. Nguyen TT, Hoskin TL, Habermann EB, Cheville AL, Boughey JC. Breast cancer-related lymphedema risk is related to multidisciplinary treatment and not surgery alone: results from a large cohort study. *Ann Surg Oncol* 2017;24:2972-80. DOI PubMed PMC
18. Dayan JH, Dayan E, Smith ML. Reverse lymphatic mapping: a new technique for maximizing safety in vascularized lymph node transfer. *Plast Reconstr Surg* 2015;135:277-85. DOI PubMed
19. Weinstein B, Le NK, Robertson E, et al. Reverse lymphatic mapping and immediate microsurgical lymphatic reconstruction reduces early risk of breast cancer-related lymphedema. *Plast Reconstr Surg* 2022;149:1061-9. DOI
20. Scaglioni MF, Suami H. Lymphatic anatomy of the inguinal region in aid of vascularized lymph node flap harvesting. *J Plast Reconstr Aesthet Surg* 2015;68:419-27. DOI PubMed
21. Liu HL, Pang SY, Lee CC. Donor limb assessment after vascularized groin lymph node transfer for the treatment of breast cancer-related lymphedema: clinical and lymphoscintigraphy findings. *J Plast Reconstr Aesthet Surg* 2019;72:216-24. DOI PubMed
22. Cheng MH, Chen SC, Henry SL, Tan BK, Chia-Yu Lin M, Huang JJ. Vascularized groin lymph node flap transfer for postmastectomy upper limb lymphedema: flap anatomy, recipient sites, and outcomes. *Plast Reconstr Surg* 2013;131:1286-98. DOI PubMed
23. Chen R, Mu L, Zhang H, et al. Simultaneous breast reconstruction and treatment of breast cancer-related upper arm lymphedema with lymphatic lower abdominal flap. *Ann Plast Surg* 2014;73 Suppl 1:S12-7. DOI
24. Yoshimatsu H, Karakawa R, Fuse Y, Yano T. Simultaneous lymphatic superficial circumflex iliac artery perforator flap transfer from the zone 4 region in autologous breast reconstruction using the deep inferior epigastric artery perforator flap: a proof-of-concept study. *J Clin Med* 2022;11:534. DOI PubMed PMC
25. Winters H, Tieleman HJP, Hummelink S, Slater NJ, Ulrich DJO. DIEP flap breast reconstruction combined with vascularized lymph node transfer for patients with breast cancer-related lymphedema. *Eur J Surg Oncol* 2022;48:1718-22. DOI PubMed
26. De Brucker B, Zeltzer A, Seidenstuecker K, Hendrickx B, Adriaenssens N, Hamdi M. Breast cancer-related lymphedema: quality of



- life after lymph node transfer. *Plast Reconstr Surg* 2016;137:1673-80. DOI PubMed
27. Black CK, Zolper EG, Economides JM, Abadeer A, Fan KL, Song DH. Comparison of the pedicled latissimus dorsi flap with immediate fat transfer versus abdominally based free tissue transfer for breast reconstruction. *Plast Reconstr Surg* 2020;146:137e-46e. DOI PubMed
  28. Vibhakkar D, Reddy S, Morgan-Hazelwood W, Chang EI. Chimeric pedicled latissimus dorsi flap with lateral thoracic lymph nodes for breast reconstruction and lymphedema treatment in a hypercoagulable patient. *Plast Reconstr Surg* 2014;134:494e-5e. DOI
  29. Scaglioni MF, Arvanitakis M, Chen YC, Giovanoli P, Chia-Shen Yang J, Chang EI. Comprehensive review of vascularized lymph node transfers for lymphedema: outcomes and complications. *Microsurgery* 2018;38:222-9. DOI PubMed
  30. Abdou SA, Charipova K, Song DH. Modern approaches to pedicled latissimus dorsi flap breast reconstruction with immediate fat transfer. *Clin Plast Surg* 2023;50:259-65. DOI PubMed
  31. Hong JP, Sun SH, Ben-Nakhi M. Modified superficial circumflex iliac artery perforator flap and supermicrosurgery technique for lower extremity reconstruction: a new approach for moderate-sized defects. *Ann Plast Surg* 2013;71:380-3. DOI PubMed
  32. Akita S, Mitsukawa N, Kubota Y, Sakakibara M, Nagashima T, Satoh K. Delayed partial breast reconstruction and vascularized lymph node transfer by a superficial circumflex iliac artery perforator flap. *Plast Reconstr Surg* 2016;137:490e-1e. DOI PubMed
  33. Yamamoto T, Yamamoto N. An extended superficial circumflex iliac artery perforator flap transfer for a relatively-small breast reconstruction after total mastectomy. *Microsurgery* 2022;42:181-6. DOI PubMed
  34. Scaglioni MF, Meroni M, Fritsche E. Pedicled superficial circumflex iliac artery perforator flap combined with lymphovenous anastomosis between the recipient site lymphatic vessels and flap superficial veins for reconstruction of groin/thigh tissue defect and creation of lymph flow-through to reduce lymphatic complications: a report of preliminary results. *Microsurgery* 2023;43:44-50. DOI PubMed
  35. Scaglioni MF, Meroni M, Fritsche E, Fuchs B. Combined double superficial circumflex iliac artery perforator flap with lymphatic tissue preservation and lymphovenous anastomosis for lymphatic sequelae prevention in thigh defect reconstruction: a case report. *Microsurgery* 2022;42:265-70. DOI PubMed
  36. Yano T, Yoshimatsu H, Karakawa R, et al. Use of a combined SIEA and SCIP based double pedicled abdominal flap for breast reconstruction. *Microsurgery* 2021;41:319-26. DOI PubMed
  37. Liu FC, Thawanyarat K, Navarro Y, Nguyen DH. Current research on the use of the omental flap in breast reconstruction and post-mastectomy lymphedema: a focus on omental-vascularized lymph node transfer. *Life* 2023;13:1380. DOI PubMed PMC
  38. Goldsmith HS. Long term evaluation of omental transposition for chronic lymphedema. *Ann Surg* 1974;180:847-9. DOI PubMed PMC
  39. Goldsmith HS, De los Santos R. Omental transposition for the treatment of chronic lymphedema. *Rev Surg* 1966;23:303-4. PubMed
  40. Kenworthy EO, Nelson JA, Verma R, Mbabuike J, Mehrara BJ, Dayan JH. Double vascularized omentum lymphatic transplant (VOLT) for the treatment of lymphedema. *J Surg Oncol* 2018;117:1413-9. DOI PubMed PMC
  41. Zaha H, Inamine S, Naito T, Nomura H. Laparoscopically harvested omental flap for immediate breast reconstruction. *Am J Surg* 2006;192:556-8. DOI PubMed
  42. Cothier-Savey I, Tamtawi B, Dohnt F, Raulo Y, Baruch J. Immediate breast reconstruction using a laparoscopically harvested omental flap. *Plast Reconstr Surg* 2001;107:1156-63; discussion 1164-5. DOI PubMed
  43. Nguyen DH, Ma IT, Choi YK, Zak Y, Dua MM, Wapnir IL. Creating a biological breast implant with an omental fat-augmented free flap. *Plast Reconstr Surg* 2022;149:832-5. DOI PubMed
  44. Crowley JS, Liu FC, Rizk NM, Nguyen D. Concurrent management of lymphedema and breast reconstruction with single-stage omental vascularized lymph node transfer and autologous breast reconstruction: a case series. *Microsurgery* 2024;44:e31017. DOI PubMed
  45. Jarvis NR, Torres RA, Avila FR, Forte AJ, Rebecca AM, Teven CM. Vascularized omental lymphatic transplant for upper extremity lymphedema: a systematic review. *Cancer Rep* 2021;4:e1370. DOI PubMed PMC
  46. Brown S, Mehrara BJ, Corididi M, McGrath L, Cavalli M, Dayan JH. A prospective study on the safety and efficacy of vascularized lymph node transplant. *Ann Surg* 2022;276:635-53. DOI PubMed PMC
  47. Engel H, Lin CY, Huang JJ, Cheng MH. Outcomes of lymphedema microsurgery for breast cancer-related lymphedema with or without microvascular breast reconstruction. *Ann Surg* 2018;268:1076-83. DOI PubMed
  48. Slavin SA, Upton J, Kaplan WD, Van den Abbeele AD. An investigation of lymphatic function following free-tissue transfer. *Plast Reconstr Surg* 1997;99:730-41; discussion 742. DOI
  49. Suami H, Pan WR, Taylor GI. Changes in the lymph structure of the upper limb after axillary dissection: radiographic and anatomical study in a human cadaver. *Plast Reconstr Surg* 2007;120:982-91. DOI
  50. Fishman JE, Moroni EA, Cruz C. The Pittsburgh trunk lymphedema staging system (PTLSS) - a validated staging system for the description of breast cancer-associated trunk lymphedema. *J Plast Reconstr Aesthet Surg* 2022;75:3122-8. DOI PubMed
  51. Johnson AR, Fleishman A, Granoff MD, et al. Evaluating the impact of immediate lymphatic reconstruction for the surgical prevention of lymphedema. *Plast Reconstr Surg* 2021;147:373e-81e. DOI
  52. Corididi M, Mehrara B, Skoracki R, Singhal D, Dayan JH. Immediate lymphatic reconstruction: technical points and literature review. *Plast Reconstr Surg Glob Open* 2021;9:e3431. DOI PubMed PMC
  53. Boccardo F, Casabona F, De Cian F, et al. Lymphedema microsurgical preventive healing approach: a new technique for primary prevention of arm lymphedema after mastectomy. *Ann Surg Oncol* 2009;16:703-8. DOI

54. Boccardo F, Casabona F, De Cian F, et al. Lymphatic microsurgical preventing healing approach (LYMPHA) for primary surgical prevention of breast cancer-related lymphedema: over 4 years follow-up. *Microsurgery* 2014;34:421-4. DOI