

Review

Open Access



Lymphatic reconstruction with vascularized lymph vessel flap: lymph-interpositional-flap transfer

Hayahito Sakai¹, Chihiro Matsui^{1,2}, Toko Miyazaki¹, Reiko Tsukuura¹, Takumi Yamamoto¹

¹Department of Plastic and Reconstructive Surgery, National Center for Global Health and Medicine, Tokyo 162-8655, Japan.

²Department of Plastic and Reconstructive Surgery, Juntendo University School of Medicine, Tokyo 113-8431, Japan.

Correspondence to: Takumi Yamamoto, MD, PhD, Department of Plastic and Reconstructive Surgery, National Center for Global Health and Medicine, 1-21-1 Toyama, Shinjuku-ku, Tokyo 162-8655, Japan. E-mail: tyamamoto-tky@umin.ac.jp

How to cite this article: Sakai H, Matsui C, Miyazaki T, Tsukuura R, Yamamoto T. Lymphatic reconstruction with vascularized lymph vessel flap: lymph-interpositional-flap transfer. *Plast Aesthet Res* 2023;10:45. <https://dx.doi.org/10.20517/2347-9264.2023.18>

Received: 21 Feb 2023 **First Decision:** 27 Jun 2023 **Revised:** 22 Jul 2023 **Accepted:** 20 Aug 2023 **Published:** 29 Aug 2023

Academic Editors: Melissa B. Aldrich **Copy Editor:** Yanbing Bai **Production Editor:** Yanbing Bai

Abstract

Lymph node transfer (LNT) and lymphatic anastomosis are popular reconstructive surgeries in managing lymphedema. However, lymphatic anastomosis requires the operator to be adept at super microsurgery, and LNT has significant donor-site lymphedema risks. To address these drawbacks, lymph-interpositional-flap transfer (LIFT), a novel lymphatic reconstruction method that does not require lymph node transfers or supermicrosurgical techniques, has been introduced. Lymph circulation after tissue replantation and free flap transfer was evaluated using indocyanine green (ICG) lymphography. Postoperative ICG lymphography showed linear to linear lymphatic reconnection between an amputee/flap and a recipient site in cases where the stumps of the lymph vessels were only approximated. This was a frequent phenomenon observed in replantation cases and some free tissue transfers. Based on these results, we developed a new lymphatic reconstruction using a flap designed to include the collecting lymph vessels for bridging a lymphatic gap. ICG is injected at the peripheries of donor sites or the distal boundaries of the lymphosome where the recipient site resides in. This allows us to visualize the axial lymphatic pathways. When LIFT is used to reconstruct a soft tissue defect, ICG is also injected at the proximal edge of it to visualize proximal lymph flows. The LIFT flap is designed to include lymphatic channels seen on pre-operative ICG lymphography. As these collecting lymph vessels reside deep in the superficial fascia, the flap is elevated with the deep fat intact. Intra-operative ICG lymphography is utilized to identify the proximal and distal lymphatic stumps on the flap, and absorbable sutures are used to tag these stumps for ease of recognition during the flap inset. LIFT is indicated for soft tissue defects in major lymphosomes, resulting in a significant lymphatic gap. The advantage of the LIFT technique is the ability to perform simultaneous soft tissue and lymphatic reconstruction. LIFT can also be



© The Author(s) 2023. **Open Access** This article is licensed under a Creative Commons Attribution 4.0 International License (<https://creativecommons.org/licenses/by/4.0/>), which permits unrestricted use, sharing, adaptation, distribution and reproduction in any medium or format, for any purpose, even commercially, as long as you give appropriate credit to the original author(s) and the source, provide a link to the Creative Commons license, and indicate if changes were made.



applied in established lymphedema and elephantiasis.

Keywords: Lymphedema, supermicrosurgery, indocyanine green lymphography, lymphatic reconstruction

INTRODUCTION

Lymphedema is a chronic and debilitating disease that disrupts the lymphatic transport system, resulting in fluid retention within the interstitium. Reconstruction of soft tissue defects in the extremity is often performed without considering lymphatic disruption. This may lead to persistent lymphedema, complicating postoperative rehabilitation and lowering patients' quality of life.

Lymphedema surgery has evolved tremendously since the advent of microsurgery. Lymph node transfer (LNT) and lymphatic anastomosis have become the two most popular physiological procedures for treating lymphedema. Although LNT does not require supermicrosurgical techniques, it confers a significant risk of donor-site lymphedema. Lymphatic anastomosis, such as lymphaticovenular anastomosis (LVA), is a minimally invasive surgery that can be performed under local anesthesia. However, it has a high learning curve that requires supermicrosurgical techniques. Therefore, there is a pressing need for a new approach that can accomplish lymphatic and soft tissue reconstruction without these drawbacks^[1-6].

Several lymphatic reconstruction methods have been reported without requiring lymph node sacrifice or supermicrosurgery. These include transfers of the omentum^[7] or skin flap with the lymph vessels^[8,9]. Although the concept of lymph vessel transfer to create new lymph drainage pathways addresses the pathophysiology of obstructive lymphedema, we did not possess the navigational tools nor the level of anatomical knowledge to achieve lymphatic reconstruction. With a better understanding of the anatomy and more advanced lymphatic mapping methods, a novel soft tissue and lymphatic reconstruction technique, lymph-interpositional-flap transfer (LIFT), has been developed^[10]. LIFT allows simultaneous soft tissue and lymphatic reconstruction without lymph node transfer or supermicrosurgical techniques.

CONCEPT OF LYMPH AXIALITY AND DEVELOPMENT OF LIFT

During the development of the LIFT technique, mechanisms of lymph flow restoration (LFR) were investigated to understand factors associated with spontaneous lymphatic reconnection without lymph node transfer or supermicrosurgical lymphatic anastomosis^[11,12]. ICG lymphography performed after tissue replantation and free tissue transfer revealed that lymph axiality is critical for LFR; when the deep fat of the flap/amputee is brought in contact with the deep fat of the recipient site, lymph vessel stumps are approximated, and LFR is restored with spontaneous reconnection of the lymph vessels after healing has occurred. All this is accomplished without the need for supermicrosurgical anastomosis of the lymphatic stumps.

Postoperative lymph flows are assessed with ICG lymphography; 0.1 mL of ICG (Diagnogreen 0.25%; Daiichi Pharmaceutical, Tokyo, Japan) is injected sub-dermally at the tip of a replanted tissue such as the fingertip, and circumferential fluorescent images of lymph flows are obtained using a handheld near-infrared camera system (Photodynamic Eye-Neo [PDE-Neo™]; Hamamatsu Photonics K.K., Hamamatsu, Japan). In almost all cases, postoperative ICG lymphography has shown linear to linear lymph flow restoration beyond the replanted border. The only exception is when a wide lymphatic gap was maintained by a relatively large skin defect left to heal by secondary intention. These results strongly suggest that fibrotic tissue inhibits spontaneous lymphatic reconnection^[11].

LFR after conventional free tissue transfer is less frequently observed. Lymphatic axiality is seldom considered during flap inset as the main objective of free tissue transfer is to cover a soft tissue defect. Lymph channels of the flap and the recipient site are not closely approximated; therefore, lymphatic axiality and flow restoration are less common. Postoperative ICG lymphography in most of these free tissue transfer cases has shown extensive dermal backflow, except for cases where axes of the lymph flows are coincidentally matched between a flap and a recipient site. These results strongly suggest that LFR is achieved when the axes of lymph flows are matched. Unlike replantation surgeries, raw wounds are usually fully covered by the free flap and not left to heal by secondary intention; hence, the inability to approximate the lymphatic axes is the sole reason for the failure of LFR^[11].

Based on these preliminary results, we have developed a novel technique using a flap that includes collecting lymph vessels to bridge a lymphatic gap. By placing the lymph vessels' stumps in close proximity, the lymph vessels can spontaneously reconnect to restore lymph flows. The LIFT technique is based on this lymph axiality concept and does not require supermicrosurgical techniques or lymph node sacrifice.

OPERATIVE METHODS OF LIFT

ICG is injected at specific sites to delineate the lymphatic anatomy. At donor sites, ICG is injected at the distal peripheries of the flap boundaries to visualize the lymphatic axes. For recipient sites, ICG is injected at the most distal portion of the major lymphosome where it resides. When there is a soft tissue defect, ICG is also injected approximately 2-3 cm from the proximal border of the defect to visualize the proximal lymph axes [Figure 1].

Based on the defect size, recipient vessel location, and lymph axialities, a flap is designed to allow optimal soft tissue reconstruction and lymphatic gap bridging by interposing the lymph vessels in the flap with the surrounding soft tissue [Figures 2 and 3].

The flap is elevated to include the deep fat that carries the lymph vessels that were marked preoperatively. Deep fat around the skin paddle can be recruited as part of the flap to extend the reach of the lymphatic axes. Careful dissection prevents injury to these collecting lymph vessels within the flap [Figure 4]. The flap includes the full thickness of subcutaneous fat, so the rest of the flap harvest is fast and expedient with minimal perforator dissection. Intraoperative ICG lymphography is used to confirm the precise location of the lymph vessel stumps. These are marked with absorbable sutures and aid in flap inset.

After microsurgical anastomosis and revascularization, the flap is inset to approximate the lymph vessel stumps between the flap and the recipient site. This can be achieved by placing 2-3 absorbable stitches between the superficial fascia of the flap and the recipient site, paying close attention to the locations of the lymph vessel stumps (marked with the absorbable stitches earlier) on each side. The remaining procedures are the same as conventional free tissue transfer [Figure 1].

CLINICAL IMPACTS AND INDICATIONS OF LIFT

The strongest indication for LIFT is a simultaneous soft tissue and lymphatic reconstruction when the soft tissue defect disrupts a major lymphosome. Coverage and prophylaxis against secondary lymphedema can be accomplished in one procedure^[10,11]. This primary prevention is important as lymphedema tends to be chronic and progressive once it develops after soft tissue reconstruction. Although other physiological lymphatic reconstructions, such as LVA and LNT, can be combined with soft tissue reconstruction as a second procedure, they require supermicrosurgery expertise or lymph node sacrifice^[1-6]. On the other hand, LIFT only requires consideration of lymph axiality during flap inset without any additional procedures.

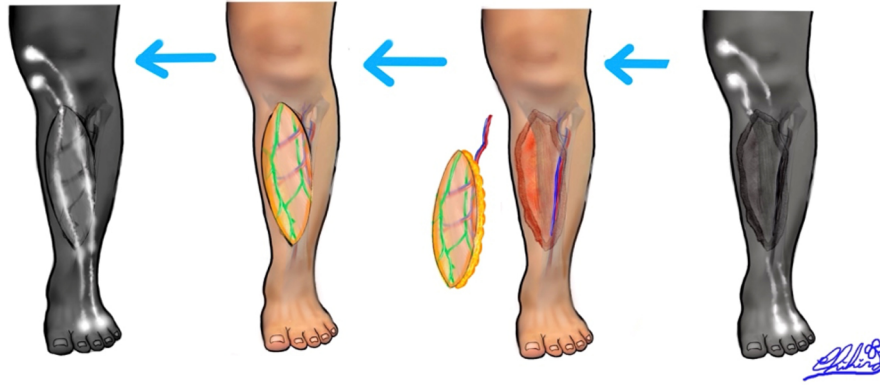


Figure 1. Based on lymphatic anatomy, ICG is injected at the most distal or peripheral parts of the lymphosomes in a recipient and donor sites to visualize the lymph axialities. ICG is also injected at the border of the defect to visualize the proximal lymph axially. After LIFT is elevated and transferred with microvascular anastomoses, the flap is inset; the lymph vessels' stumps are approximated with the superficial fascia fixation, the flap and the recipient superficial fascia are sutured with 2-3 stitches of 3-0 absorbable stitches, approximating the lymph vessels between the flap and the recipient site. ICG: indocyanine green; LIFT: lymph-interpositional-flap transfer.

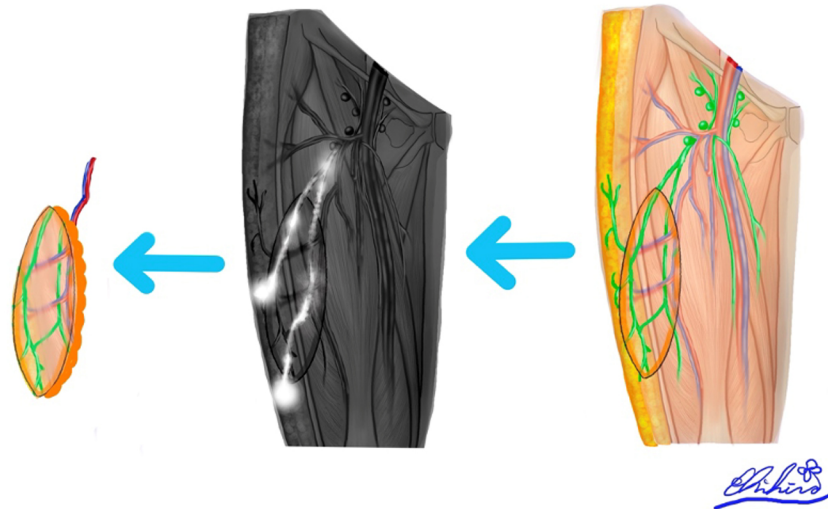


Figure 2. When ALT-LIFT flap is planned, ICG should be injected at the mid-lateral thigh to visualize ALT lymphatic pathways; lymph flows from the mid-lateral thigh towards the inguinal lymph nodes. ICG: indocyanine green; ALT-LIFT: Anterolateral thigh-lymph-interpositional-flap transfer; ALT: Anterolateral thigh.

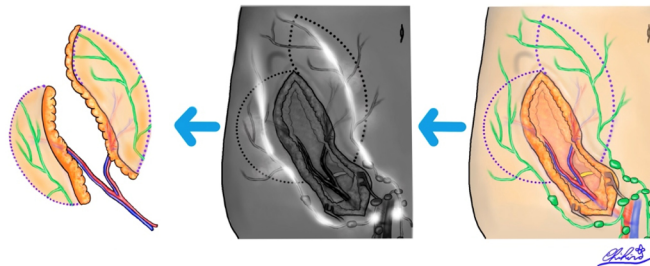


Figure 3. When a LIFT flap is planned in the lower abdomen using the SCIP or DIEP flap, ICG should be injected at the umbilical level, as lower abdominal lymph flows from the level of the umbilicus towards the inguinal lymph nodes. ICG: indocyanine green; LIFT: lymph-interpositional-flap transfer; SCIP: superficial circumflex iliac artery perforator; DIEP: deep inferior epigastric artery perforator.

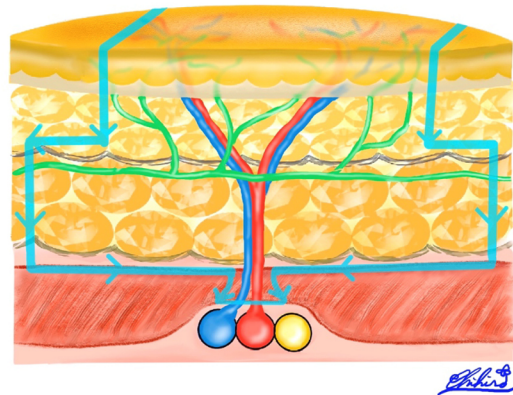


Figure 4. Because collecting lymph vessels exist just under the superficial fascia, it is safe to include the deep fat tissue by dissecting the superficial fascia layer widely enough to harvest the entire course of the preoperatively mapped lymph vessels.

Only superficial fascia fixation is needed to reapproximate the lymph vessels, which takes less than 1 min.

Our previous study has demonstrated a higher LFR rate and lower incidence of secondary lymphedema after extremity soft tissue reconstruction cases with LIFT compared to those with conventional free tissue transfer^[10]. Since there are many axial lymph vessels located in the adipose tissue, various flaps can be used for LIFT, including anterolateral thigh (ALT) flap, deep inferior epigastric artery perforator (DIEP) flap, latissimus dorsi myocutaneous flap, and superficial circumflex iliac artery perforator (SCIP) flap that are popular in microsurgical reconstruction.

Knowledge of the lymphatic anatomy is critical in the planning of the flap. For example, if an ALT flap is to be designed, ICG should be injected at the mid-lateral thigh to visualize the lymphatic pathways as lymph flows from the mid-lateral thigh towards the inguinal lymph nodes [Figure 2]^[13]. For the design of a lower abdominal flap, ICG should be injected at the level of the umbilicus, as lower abdominal lymph flows from the level of the umbilicus towards the inguinal lymph nodes [Figure 3]^[14].

LIFT can be used for the treatment of established lymphedema as well. In delayed breast reconstruction, a DIEP flap can be used for LIFT. Instead of an LNT, Zone 2 (Holm's) of the lower abdominal DIEP flap is used as a lymph vessel flap to bridge a lymphatic gap at the axilla to treat upper extremity lymphedema. The lymph vessel stumps of the DIEP flap are placed close to the deep fat of the axilla to drain lymphedema fluid from the proximal upper arm once LFR has occurred. The upper arm should demonstrate evidence of dermal backflow on ICG lymphography. A pedicled SCIP flap can treat unilateral lower extremity lymphedema using the same concept. The pedicled SCIP lymphatic flap is elevated from the normal contralateral side and transferred to the affected lower extremity via a subcutaneous tunnel^[15].

A one-stage curative surgery, radical reduction and reconstruction (RRR), has recently been developed for male genital elephantiasis. In RRR, LIFT accomplishes simultaneous genital soft tissue and lymphatic reconstruction following the resection of genital elephantiasis tissue. A pedicled SCIP lymphatic flap is transferred to reconstruct the scrotum and bridge the lymphatic pathways in one procedure. The LIFT component in RRR is critical in curbing the risk of early postoperative complications such as high output exudate, wound dehiscence, infection, and lymphedema recurrence^[16]. This is because lymphedematous tissue is often inadvertently left behind even after radical resection is performed.

PERSPECTIVE

In extremity soft tissue reconstruction, lymphatic reconstruction is often overlooked, as the primary objective is to cover a soft tissue defect. However, free tissue transfer without lymphatic reconstruction has a significant risk of secondary lymphedema^[11]. Unfortunately, most of these patients with secondary lymphedema are typically dismissed as “transient edema” and rarely given the appropriate attention by medical staff. Only after developing severe lymphedema or frequent episodes of cellulitis decades after the initial reconstruction are such patients referred to a lymphedema center for specialized treatment. As lymphedema is intractable and progressive, early diagnosis and treatment are essential, and primary prevention is ideal.

Modern lymphatic reconstruction techniques can be highly efficacious methods of managing lymphedema, but they have drawbacks. LVA requires supermicrosurgery expertise, while LNT may lead to donor-site secondary lymphedema. In addition, these procedures often involve long operative durations^[1-6]. In the LIFT procedure, the surgeon only has two extra steps, which are quick and easily performed: flap design with the inclusion of patent lymphatic pathways via ICG lymphography and careful flap inset to approximate lymph vessel stumps between the flap and recipient site^[13-15]. LIFT allows for a practical way of preventing secondary lymphedema and should be considered in any extremity soft tissue defect involving a major lymphosome^[10,16].

CONCLUSION

Based on the LIFT concept, soft tissue and lymphatic defects could be reconstructed simultaneously without the high learning curves of supermicrosurgery and the risk of donor-site lymphedema. Although detailed knowledge of the lymphatic anatomy is required, this concept is quickly learned. Hence, the LIFT technique could potentially in the future prove to be a valuable tool in reconstructive case scenarios to prevent and treat lymphedema.

DECLARATIONS

Acknowledgments

Jeremy Sun Mingfa, M.D., is an English editor of this article. Consultant, Department of Plastic and Reconstructive Surgery, Changi General Hospital, 529889 Singapore.

Authors' contributions

Made substantial contributions to the conception and design of the study and performed data analysis and interpretation: Sakai H, Yamamoto T

Performed data acquisition, as well as provided administrative, technical, and material support: Matsui C, Miyazaki T, Tsukuura R

Availability of data and materials

Not applicable.

Financial support and sponsorship

None.

Conflicts of interest

All authors declared that there are no conflicts of interest.

Ethical approval and consent to participate

Not applicable.

Consent for publication

Not applicable.

Copyright

© The Author(s) 2023.

REFERENCES

1. Yamamoto T, Saito T, Ishiura R, Iida T. Quadruple-component superficial circumflex iliac artery perforator (SCIP) flap: a chimeric SCIP flap for complex ankle reconstruction of an exposed artificial joint after total ankle arthroplasty. *J Plast Reconstr Aesthet Surg* 2016;69:1260-5. [DOI](#) [PubMed](#)
2. Vignes S, Blanchard M, Yannoutsos A, Arrault M. Complications of autologous lymph-node transplantation for limb lymphoedema. *Eur J Vasc Endovasc Surg* 2013;45:516-20. [DOI](#) [PubMed](#)
3. Pons G, Masia J, Loschi P, Nardulli ML, Duch J. A case of donor-site lymphoedema after lymph node-superficial circumflex iliac artery perforator flap transfer. *J Plast Reconstr Aesthet Surg* 2014;67:119-23. [DOI](#) [PubMed](#)
4. Yamamoto T, Chen WF, Yamamoto N, Yoshimatsu H, Tashiro K, Koshima I. Technical simplification of the supermicrosurgical side-to-end lymphaticovenular anastomosis using the parachute technique. *Microsurgery* 2015;35:129-34. [DOI](#) [PubMed](#)
5. Yamamoto T, Yamamoto N, Yamashita M, Furuya M, Hayashi A, Koshima I. Establishment of supermicrosurgical lymphaticovenular anastomosis model in rat. *Microsurgery* 2017;37:57-60. [DOI](#) [PubMed](#)
6. Yamamoto T, Yoshimatsu H, Narushima M, Yamamoto N, Koshima I. Split intravascular stents for side-to-end lymphaticovenular anastomosis. *Ann Plast Surg* 2013;71:538-40. [DOI](#) [PubMed](#)
7. Goldsmith HS, De los Santos R, Beattie EJ Jr. Relief of chronic lymphedema by omental transposition. *Ann Surg* 1967;166:573-85. [DOI](#) [PubMed](#) [PMC](#)
8. Gillies H, Fraser FR. Treatment of lymphoedema by plastic operation: (a preliminary report). *Br Med J* 1935;1:96-8. [DOI](#) [PubMed](#) [PMC](#)
9. Thompson N. Surgical treatment of chronic lymphoedema of the lower limb. with preliminary report of new operation. *Br Med J* 1962;2:1566-73. [DOI](#) [PubMed](#) [PMC](#)
10. Yamamoto T, Yamamoto N, Kageyama T, Sakai H, Fuse Y, Tsukuura R. Lymph-interpositional-flap transfer (LIFT) based on lymph-axiality concept: simultaneous soft tissue and lymphatic reconstruction without lymph node transfer or lymphatic anastomosis. *J Plast Reconstr Aesthet Surg* 2021;74:2604-12. [DOI](#) [PubMed](#)
11. Yamamoto T, Iida T, Yoshimatsu H, Fuse Y, Hayashi A, Yamamoto N. Lymph flow restoration after tissue replantation and transfer: importance of lymph axiality and possibility of lymph flow reconstruction without lymph node transfer or lymphatic anastomosis. *Plast Reconstr Surg* 2018;142:796-804. [DOI](#) [PubMed](#)
12. Gentileschi S, Servillo M, Garganese G, et al. The lymphatic superficial circumflex iliac vessels deep branch perforator flap: a new preventive approach to lower limb lymphedema after groin dissection-preliminary evidence. *Microsurgery* 2017;37:564-73. [DOI](#)
13. Sakai H, Kageyama T, Tsukuura R, Yamamoto T. Anatomical location of lymphatic pathways in the posterior thigh. *Ann Plast Surg* 2022;88:330-4. [DOI](#) [PubMed](#)
14. Neligan PC, Masia J, Neil BP. Lymphedema complete medical and surgical management. US: Thieme; 2016. p.53-59.
15. Miyazaki T, Kageyama T. Lymph interpositional flap transfer (LIFT) for upper thigh soft tissue and lymphatic reconstruction without lymphovenous anastomosis. *J Surg Oncol* 2021;123:698-9. [DOI](#) [PubMed](#)
16. Yamamoto T, Daniel BW, Rodriguez JR, et al. Radical reduction and reconstruction for male genital elephantiasis: superficial circumflex iliac artery perforator (SCIP) lymphatic flap transfer after elephantiasis tissue resection. *J Plast Reconstr Aesthet Surg* 2022;75:870-80. [DOI](#)