

Review

Open Access



# The evolution of anastomotic techniques in robot-assisted Ivor Lewis esophagectomy

Tania Triantafyllou<sup>1</sup> , Bruno Sgromo<sup>2</sup>

<sup>1</sup>Upper Gastrointestinal Surgical Unit, Royal Infirmary of Edinburgh, NHS Lothian, Edinburgh EH16 4SA, UK.

<sup>2</sup>Oxford Oesophagogastric Centre, Churchill Hospital, Oxford University Hospitals NHS Foundation Trust, Oxford OX3 7LE, UK.

**Correspondence to:** Dr. Tania Triantafyllou, Upper Gastrointestinal Surgical Unit, Royal Infirmary of Edinburgh, 51 Little France Cres, Old Dalkeith Rd, Edinburgh EH16 4SA, UK. E-mail: t\_triantafilou@yahoo.com

**How to cite this article:** Triantafyllou T, Sgromo B. The evolution of anastomotic techniques in robot-assisted Ivor Lewis esophagectomy. *Mini-invasive Surg* 2023;7:31. <https://dx.doi.org/10.20517/2574-1225.2023.48>

**Received:** 23 Apr 2023 **First Decision:** 24 Aug 2023 **Revised:** 31 Aug 2023 **Accepted:** 7 Sep 2023 **Published:** 11 Sep 2023

**Academic Editors:** Itasu Ninomiya, Farid Gharagozloo **Copy Editor:** Pei-Yun Wang **Production Editor:** Pei-Yun Wang

## Abstract

Radical esophagectomy is the cornerstone in the treatment of esophageal cancer combined with perioperative therapies, whereas patients diagnosed at an early stage may be candidates for endoscopic resection. Minimally invasive procedures aim to improve the postoperative complications and reduce overall morbidity. The short and long-term results of the incorporation of robot-assisted esophagectomy in specialised centres worldwide have been encouraging. The Ivor Lewis technique has become the preferable approach, reaching up to 61% of the minimally invasive reconstructions in the Western World; however, the percentage of anastomotic leaks remains problematic. Throughout the last decade, a few modifications of the anastomotic technique have been proposed in an effort to improve the surgical results of the robot-assisted approach. This review presents the evolving robotic techniques of performing the esophagogastric anastomosis. An overview of the available approaches will be discussed with a focus on the intrathoracic anastomosis.

**Keywords:** Esophageal cancer, Ivor Lewis esophagectomy, minimally invasive esophagectomy, robot-assisted esophagectomy, anastomotic leak

## INTRODUCTION

Esophagectomy is the mainstay of the treatment for resectable esophageal malignancy. Despite the improved accuracy of the preoperative staging, the thorough selection of patients, the development of



© The Author(s) 2023. **Open Access** This article is licensed under a Creative Commons Attribution 4.0 International License (<https://creativecommons.org/licenses/by/4.0/>), which permits unrestricted use, sharing, adaptation, distribution and reproduction in any medium or format, for any purpose, even commercially, as long as you give appropriate credit to the original author(s) and the source, provide a link to the Creative Commons license, and indicate if changes were made.



minimally invasive approaches, and the morbidity and mortality rates after the resection remain high even in specialised European centres (reported as 59% morbidity and 4.5% mortality, respectively)<sup>[1]</sup>. More precisely, anastomotic leak has long been considered to be one of the most fearful complications, with a rate that varies in the literature between 10% and 35%<sup>[2]</sup>. Two main benefits of the thoracic compared to the cervical anastomosis have been outlined regardless of the technical approach: firstly, lower rates of anastomotic leak, hence postoperative stenosis, secondary to preventing ischemia of the gastric conduit, and secondly, a lower risk of damage to the recurrent laryngeal nerve<sup>[3,4]</sup>.

Laparoscopic, thoracoscopic, robot-assisted, and hybrid techniques are evolving worldwide, aiming to minimise the surgical complications. The emergence of robot-assisted minimally invasive esophagectomy (RAMIE) has been welcomed internationally by high-volume surgical units with enthusiasm. Refinements of the anastomotic technique through the robotic approach, either in terms of suturing or using novel instruments and equipment, have the rationale to decrease the operative time, enhance the view of the surgical field, and reduce the anastomotic leak rate. To date, these rates are in favour of the intrathoracic as opposed to the cervical anastomosis; herein, many centres have almost inclusively adopted the Ivor Lewis technique<sup>[5]</sup>.

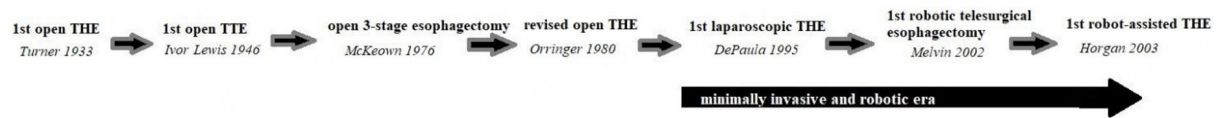Since the presentation of the first minimally invasive esophagectomy (MIE), a variety of different anastomotic techniques have been proposed, whereas there is increasing interest in establishing standard technical steps in the form of recommendations and recently published guidance by experts on the field<sup>[6]</sup>. The current trends and technical details of the robot-assisted anastomotic techniques will be discussed in this review.

## PAST

Based on multicentre randomised trials (RCTs), the emergence of MIE has shown promising perioperative and long-term results; hence, many esophageal surgeons worldwide have incorporated the technique without compromising the oncologic outcome<sup>[7,8]</sup>. RCTs have shown that apart from the improved quality of life and lower rates of cardiopulmonary complications after MIE compared to the traditional resections, the rate of anastomotic leak was found to be similar between totally MIE and open surgery<sup>[9,10]</sup>. Another interesting finding of those older studies was the preference for a neck anastomosis in both surgical arms (66% for the open resections and 64% for the minimally invasive, respectively).

The contributions of pioneers around the world have led to the evolution and advances in esophageal surgery. From the open esophagectomy to the MIE, expert teams worldwide have presented their results and the process of the learning curve in specialised centres<sup>[11-13]</sup>. RAMIE, initially introduced two decades ago, is another evolving approach with promising results. The first robotic esophagectomy was attempted in 2002 by Melvin *et al.*, while the first transhiatal RAMIE was successfully performed by Dr. Horgan more than two decades ago<sup>[14,15]</sup>. The first robotic three-stage esophagectomy was reported a few years later. Since then, the robotic procedures in the treatment of esophageal malignancy have become popular among several centres worldwide [Figure 1].

According to previously published studies, the comparison of the perioperative and oncological outcomes after traditional MIE and RAMIE has resulted in encouraging findings. The ROBOT trial compared RAMIE to open esophagectomy, indicating accelerated perioperative recovery after RAMIE and equal oncological outcomes<sup>[16]</sup>. Furthermore, a meta-analysis collected the results of eight case-control studies and resulted in similar results between MIE and RAMIE<sup>[17]</sup>. In the past, other non-randomised studies have also shown no clearly significant superiority of RAMIE over MIE; however, a trend towards more radical lymph node



**Figure 1.** Capturing the long history of esophagectomy, from the open to the robotic approach. THE: Transhiatal esophagectomy; TTE: transthoracic esophagectomy.

dissections in RAMIE patients has been reported<sup>[18-20]</sup>.

The optimal anastomotic technique has not been widely agreed upon, and a great technical discrepancy among different centres and countries has been documented. Given the variety of available surgical approaches, the preferences for the reconstruction during esophagectomy reported in international studies are difficult to interpret [Table 1]. It seems that the mechanical anastomotic technique has become more popular (73%) than the hand-sewn anastomosis (27%), especially in centres that have abandoned the open approach<sup>[4]</sup>. Mechanical stapling in neck anastomoses has shown lower leak rates compared to hand-sewn techniques; on the other hand, these rates were found to be equal in chest anastomoses regardless of the approach.

The history of transition from the open to the thoracoscopic and robotic anastomosis among different units varies and is mainly based on the previous experience of each surgeon or institution on the open technique. Hence, many esophageal surgeons either transferred their skills from bariatric surgery -gastric bypasses and gastrojejunal anastomoses- to stapling or suturing the esophagogastric reconstruction during video-assisted thoracoscopy or RAMIE or preserved their familiar approach of anastomosing similarly to their experience in open transthoracic esophagectomy.

## PRESENT AND FUTURE

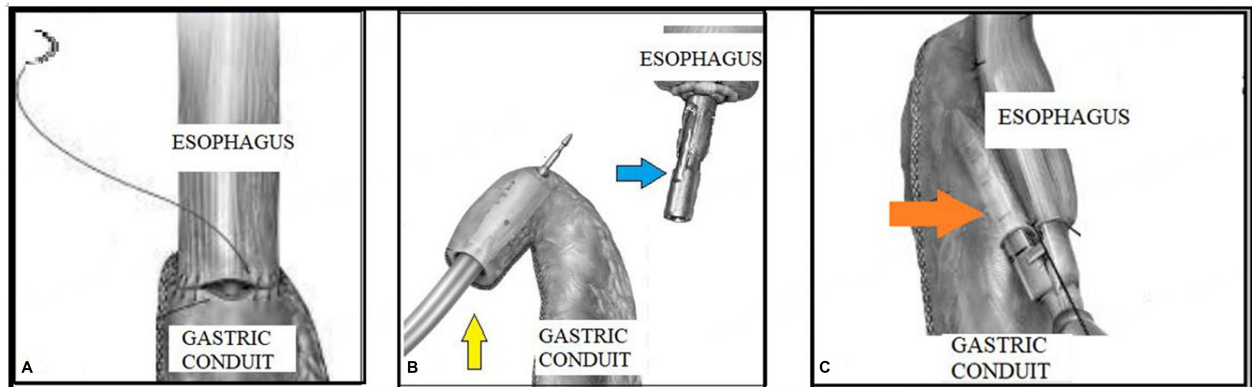
Several lessons have been learned from the preliminary and long-term results of MIE. The Ivor Lewis esophagectomy with an intrathoracic anastomosis seems to be the predominant type in the Western world currently, according to the results of the Esodata Database (estimated approximately 64% of the resections)<sup>[1]</sup>. The skills and critical steps of performing the anastomosis developed in MIE have been transferred to the robotic setup; therefore, the three main types of anastomosis have been preserved and mastered worldwide with evolving modifications [Figure 2]. All three approaches require an experienced assistant next to the operating table responsible for the trocar placement, the docking procedure, correcting any corruption/conflict of the robotic arms and switching the instruments needed for each surgical step with accuracy, safety, and without causing any delays.

The totally hand-sewn anastomosis is technically challenging because of the limited freedom of movement in the mediastinum. The barbed sutures enhanced the hand-sewn continuous one-layer esophagogastric anastomosis. Nevertheless, this technique lost its popularity, especially after the wide application of MIE, according to the analysis of the EsoBenchmark Database<sup>[21]</sup>. All in all, only 19% of the total number of esophagectomies in expert European centres are completed with a hand-sewn anastomosis, as published in a recent consensus. This percentage is exclusively referred to as cervical anastomoses, leaving a percentage of 81% for intrathoracic anastomosis<sup>[22]</sup>. Another review showed that only 126 esophagectomies with hand-sewn anastomosis have been reported as a total number of cases in the literature underlying the importance of retracting the tissues with the fourth robotic arm. A few authors find it helpful to place four full-thickness stay sutures (at 3, 6, 9, and 12 o'clock of the anastomosis) before starting the running sutures (either one or two between 3 and 9 o'clock)<sup>[23]</sup>.

**Table 1. Available techniques and different types of esophageal resection and reconstruction**

Type of esophagectomy	Location of anastomosis	Approach	Anastomotic technique
Transhiatal (2-field)	Cervical	Laparotomy/laparoscopy/robotic gastric phase	Hand-sewn/semi-mechanical/mechanical (circular)
Ivor Lewis (2-field)	Intrathoracic	Thoracotomy/thoracoscopy/robotic chest phase	Hand-sewn/mechanical (linear/circular stapler)
McKeown (3-stage)	Cervical	Hybrid/totally open/MIE/RAMIE	Hand-sewn/semi-mechanical/mechanical (circular)

MIE: Minimally invasive esophagectomy; RAMIE: robot-assisted minimally invasive esophagectomy.



**Figure 2.** The different options for robot-assisted reconstruction after esophageal resection. (A) Hand-sewn anastomosis; (B) circular stapling; (C) linear stapling. Yellow arrow: circular stapler; blue arrow: anvil; orange arrow: linear stapler.

On the other hand, using the circular stapler had to overcome the awkward angle of introducing the instrument through the chest and safely performing a purse string notch for positioning the anvil either perorally or through the chest wall<sup>[24-26]</sup>. Anvil graspers for improved adjustment, appropriate sizes of circular staplers, and a better understanding of how to eliminate tension between tissues during thoracoscopy, as opposed to the conventional thoracotomy, have gradually encouraged more surgeons to adopt the technique. The procedure is completed with a linear stapler or suturing of the defect in the gastrotomy side. The most complex step is the attachment of the circular stapler within the mediastinum, which requires the undocking of the robot to complete the anastomosis manually<sup>[18]</sup>.

The modified Orringer linear stapling technique is another option that consists of an end-to-side double stapling or side-to-side anastomosis following an esophagotomy (above, below, or at the level of the esophageal stapler line) and gastrotomy for insertion of the stapler<sup>[27,28]</sup>. A smaller load of the stapler is usually advised for easier manipulation and firing of the instrument within the mediastinum, forming the posterior side of the anastomosis with the stapler. The defect is then sutured and, again, several ways and the use of different sutures have been described; 3-0 V-loc (Covidien), 3-0 Vicryl (Ethicon), and 4-0 Stratafix (Ethicon) are being used among others. Throughout the years, the previous experience has proved that mobilisation of the esophageal stump became necessary, aiming to form a tension-free anastomosis<sup>[29]</sup>. Compared to the other two techniques, the linear stapling forms the widest anastomosis, which may account for the lower incidence of postoperative stenosis and strictures<sup>[30]</sup>.

## CURRENT AND FUTURE TRENDS

The technologic advances of RAMIE are particularly useful in overcoming the practical challenges in performing an intrathoracic anastomosis. Even when three-dimensional technology is available in MIE, the enhanced view of the surgical field and the accurate perception of the depth through RAMIE are great assets for the surgeon<sup>[6]</sup>. Additionally, the articulated instruments and the degrees of freedom provided in RAMIE can give the advantage of more convenient angles and manoeuvres, either when stapling or when selecting the hand-sewn technique. The improved ergonomics in the limited space of the thoracic mobilisations, firing of instruments, and suturing are of paramount importance.

The preliminary results of the RAMIE RCT that recruited patients who underwent RAMIE or MIE for squamous cell esophageal carcinoma disclosed a shorter operative time and more extensive lymphadenectomy after RAMIE. The morbidity and mortality rates were comparable between the two groups. The long-term results of this trial, as well as the results of the ROBOT-2 and REVATE RCTs are eagerly awaited<sup>[31-33]</sup> [Table 2].

With regards to the anastomotic leak rates, these seem to be in favour of the reconstructions using mechanical staplers compared to the hand-sewn technique. In fact, the robotic hand-sewn anastomosis presented the highest leak rate in a recent analysis (11.1%), whereas circular stapling resulted in 8.6% and the linear in 4.5%, respectively<sup>[23]</sup>. Furthermore, the use of indocyanine green (ICG) fluorescence imaging has been demonstrated during minimally invasive and robotic esophageal resections as a technology that may enlighten the status of the microvascular perfusion of the gastric conduit and decrease the rates of anastomotic leakage of cervical or intrathoracic anastomoses<sup>[34-36]</sup>. In fact, a recent study showed that the findings after the injection of ICG imaging during robotic esophagectomy guided and modified the decision-making of surgeons on the conduit site selection in 80% of the cases analysed<sup>[36]</sup>. In another prospectively designed study, the decision about the optimal location of the anastomosis was changed in 14% of the cases based on the ICG findings<sup>[37]</sup>. Whether this technological asset has the potential to affect the anastomotic leak rate and overall morbidity of esophagectomy significantly remains to be seen in future studies.

International meetings and discussions are key in further improving the anastomotic technique and decreasing the conduit ischemia and overall surgical complications<sup>[6]</sup>. A recent consensus among experts underlined the importance of a minimum diameter of 4-5 cm of the gastric conduit, minimising the retraction of the esophageal stump and the gastric conduit, selectively applying an omental wrap to cover the anastomosis, occasionally performing an intraoperative leak test, and, most importantly, gradually implementing the linear over the circular stapler. Three reasons were stated for that recommendation: first of all, a side-to-side anastomosis is at a lower risk of ischemia; secondly, many esophageal surgeons are familiar with linear stapling applied in bariatric procedures and using the same technique may accelerate the learning curve; finally, totally MIE or RAMIE is not easily feasible taking into consideration the insertion of the circular stapler through the chest wall<sup>[28]</sup>.

Optimising the perioperative care and nutritional support of the patient undergoing esophageal resection is also key in improving the surgical outcomes. More precisely, given that oral intake may be delayed during the first postoperative days and that enteral nutrition is considered to be the preferable feeding route, the use of nasogastric and jejunal feeding tubes is strongly recommended to achieve the nutritional target. The significance of this approach is supported by the Enhanced Recovery After Surgery (ERAS) society<sup>[38]</sup>. Moreover, combining both oral and jejunal -through the jejunostomy tube- feeding after discharge has shown promising results in terms of nutritional supplementation and energy levels<sup>[39]</sup>.

**Table 2. Landmark ongoing and recently completed randomised trials on the comparison between MIE and RAMIE**

<b>Trial</b>	<b>Start date</b>	<b>Origin</b>	<b>Expected number of cases</b>	<b>Surgical arms</b>		<b>Anticipated primary endpoint</b>
RAMIE <sup>[31]</sup>	7/2017	China	360	Totally MIE, chest/neck anastomosis	Totally RAMIE, chest/neck anastomosis	5-year survival
ROBOT-2 <sup>[32]</sup>	1/2021	Germany, Netherlands, Switzerland	218	Totally MIE, chest anastomosis	Totally RAMIE, chest anastomosis	Number of lymph nodes resected
REVATE <sup>[33]</sup>	10/2018	China	190	Hybrid: thoracoscopy, laparotomy/laparoscopy	Totally RAMIE	Extent of lymphadenectomy

MIE: Minimally invasive esophagectomy; RAMIE: robot-assisted minimally invasive esophagectomy.

## CONCLUSION

This narrative review demonstrated the available totally robotic and hybrid techniques for forming the esophagogastric anastomosis during RAMIE. The existing variety of the anastomotic options in MIE has been implemented in robotic resections; hence, a great diversity of tips and tricks, results, and recommendations are being discussed in the literature. Either hand-sewn or mechanical stapling, each technique presents a few advantages and challenges, and most esophageal surgeons incorporate the skills they are more familiar with from open esophagectomy or MIE. The hand-sewn suturing and the linear stapling can complete a totally robotic reconstruction, whereas the circular stapler requires undocking of the robotic arms and a trained assistant. Regardless of the preferred approach, safety and radicality, along with accurate reports of the surgical outcomes and complications, are pivotal. This aims to improve the technical experience and maximally take advantage of the robotic technique.

## DECLARATIONS

### Authors' contributions

Completed the search of the literature and conducted the manuscript: Triantafyllou T  
Revised the manuscript and completed the final editing: Sgromo B

### Availability of data and materials

Not applicable.

### Financial support and sponsorship

None.

### Conflicts of interest

All authors declared that there are no conflicts of interest.

### Ethical approval and consent to participate

Not applicable.

### Consent for publication

Not applicable.

### Copyright

© The Author(s) 2023.

## REFERENCES

1. Kuppusamy MK, Low DE; International Esodata Study Group (IESG). Evaluation of international contemporary operative outcomes and management trends associated with esophagectomy: a 4-year study of >6000 patients using ECCG definitions and the online esodata database. *Ann Surg* 2022;275:515-25. DOI PubMed
2. Low DE, Kuppusamy MK, Alderson D, et al. Benchmarking complications associated with esophagectomy. *Ann Surg* 2019;269:291-8. DOI PubMed
3. Reavis KM. The esophageal anastomosis: how improving blood supply affects leak rate. *J Gastrointest Surg* 2009;13:1558-60. DOI PubMed PMC
4. Oesophago-Gastric Anastomosis Audit study group on behalf of the West Midlands Research Collaborative. The influence of anastomotic techniques on postoperative anastomotic complications: results of the oesophago-gastric anastomosis audit. *J Thorac Cardiovasc Surg* 2022;164:674-84.e5. DOI PubMed
5. Biere SSAY, Maas KW, Cuesta MA, van der Peet DL. Cervical or thoracic anastomosis after esophagectomy for cancer: a systematic review and meta-analysis. *Dig Surg* 2011;28:29-35. DOI PubMed
6. Li B, Yang Y, Toker A, et al. International consensus statement on robot-assisted minimally invasive esophagectomy (RAMIE). *J Thorac Dis* 2020;12:7387-401. DOI PubMed PMC
7. Metcalfe C, Avery K, Berrisford R, et al. Comparing open and minimally invasive surgical procedures for oesophagectomy in the treatment of cancer: the ROMIO (Randomised Oesophagectomy: Minimally Invasive or Open) feasibility study and pilot trial. *Health Technol Assess* 2016;20:1-68. DOI PubMed PMC
8. Mariette C, Markar SR, Dabakuyo-Yonli TS, et al. Hybrid minimally invasive esophagectomy for esophageal cancer. *N Engl J Med* 2019;380:152-62. DOI PubMed
9. Maas KW, Cuesta MA, van Berge Henegouwen MI, et al. Quality of life and late complications after minimally invasive compared to open esophagectomy: results of a randomized trial. *World J Surg* 2015;39:1986-93. DOI PubMed PMC
10. Biere SSAY, van Berge Henegouwen MI, Maas KW, et al. Minimally invasive versus open oesophagectomy for patients with oesophageal cancer: a multicentre, open-label, randomised controlled trial. *Lancet* 2012;379:1887-92. DOI PubMed
11. Orringer MB, Marshall B, Chang AC, Lee J, Pickens A, Lau CL. Two thousand transhiatal esophagectomies: changing trends, lessons learned. *Ann Surg* 2007;246:363-74. DOI PubMed
12. Orringer MB. Transhiatal esophagectomy without thoracotomy for carcinoma of the thoracic esophagus. *Ann Surg* 1984;200:282-8. DOI PubMed PMC
13. DePaula AL, Hashiba K, Ferreira EA, de Paula RA, Grecco E. Laparoscopic transhiatal esophagectomy with esophagogastroplasty. *Surg Laparosc Endosc* 1995;5:1-5. PubMed
14. Melvin WS, Needleman BJ, Krause KR, et al. Computer-enhanced robotic telesurgery. Initial experience in foregut surgery. *Surg Endosc* 2002;16:1790-2. PubMed
15. Horgan S, Berger RA, Elli EF, Espat NJ. Robotic-assisted minimally invasive transhiatal esophagectomy. *Am Surg* 2003;69:624-6. PubMed
16. van der Sluis PC, van der Horst S, May AM, et al. Robot-assisted minimally invasive thoracoscopic esophagectomy versus open transthoracic esophagectomy for resectable esophageal cancer: a randomized controlled trial. *Ann Surg* 2019;269:621-30. DOI PubMed
17. Jin D, Yao L, Yu J, et al. Robotic-assisted minimally invasive esophagectomy versus the conventional minimally invasive one: a meta-analysis and systematic review. *Int J Med Robot* 2019;15:e1988. DOI PubMed
18. Harbison GJ, Vossler JD, Yim NH, Murayama KM. Outcomes of robotic versus non-robotic minimally-invasive esophagectomy for esophageal cancer: an American college of surgeons NSQIP database analysis. *Am J Surg* 2019;218:1223-8. DOI PubMed
19. Tagkalos E, Goense L, Hoppe-Lotichius M, et al. Robot-assisted minimally invasive esophagectomy (RAMIE) compared to conventional minimally invasive esophagectomy (MIE) for esophageal cancer: a propensity-matched analysis. *Dis Esophagus* 2020;33:doz060. DOI PubMed
20. Chen H, Liu Y, Peng H, Wang R, Wang K, Li D. Robot-assisted minimally invasive esophagectomy versus video-assisted minimally invasive esophagectomy: a systematic review and meta-analysis. *Transl Cancer Res* 2021;10:4601-16. DOI PubMed PMC
21. Schröder W, Raptis DA, Schmidt HM, et al. Anastomotic techniques and associated morbidity in total minimally invasive transthoracic esophagectomy: results from the esobenchmark database. *Ann Surg* 2019;270:820-6. DOI PubMed
22. Bartella I, Fransen LFC, Gutschow CA, et al. Technique of open and minimally invasive intrathoracic reconstruction following esophagectomy-an expert consensus based on a modified Delphi process. *Dis Esophagus* 2021;34:doaa127. DOI PubMed
23. Plat VD, Stam WT, Schoonmade LJ, Heineman DJ, van der Peet DL, Daams F. Implementation of robot-assisted Ivor Lewis procedure: robotic hand-sewn, linear or circular technique? *Am J Surg* 2020;220:62-8. DOI PubMed
24. Luketich JD, Pennathur A, Awais O, et al. Outcomes after minimally invasive esophagectomy: review of over 1000 patients. *Ann Surg* 2012;256:95-103. DOI PubMed PMC
25. Cao C, Liu F, Yu S, Chai H. Esophagocolonic OrVil anastomosis after minimally invasive esophagectomy. *J Laparoendosc Adv Surg Tech A* 2023;33:117-23. DOI PubMed
26. Shishido Y, Matsunaga T, Makinoya M, et al. Circular stapling anastomosis with indocyanine green fluorescence imaging for cervical esophago-gastric anastomosis after thoracoscopic esophagectomy: a propensity score-matched analysis. *BMC Surg* 2022;22:152. DOI PubMed PMC

27. Honda M, Kuriyama A, Noma H, Nunobe S, Furukawa TA. Hand-sewn versus mechanical esophagogastric anastomosis after esophagectomy: a systematic review and meta-analysis. *Ann Surg* 2013;257:238-48. [DOI PubMed](#)
28. Halliday LJ, Doran SLF, Sgromo B, et al. Variation in esophageal anastomosis technique-the role of collaborative learning. *Dis Esophagus* 2020;33:doz072. [DOI PubMed](#)
29. Okamura A, Watanabe M, Mine S, et al. Factors influencing difficulty of the thoracic procedure in minimally invasive esophagectomy. *Surg Endosc* 2016;30:4279-85. [DOI PubMed](#)
30. Deng XF, Liu QX, Zhou D, Min JX, Dai JG. Hand-sewn vs linearly stapled esophagogastric anastomosis for esophageal cancer: a meta-analysis. *World J Gastroenterol* 2015;21:4757-64. [DOI PubMed PMC](#)
31. Yang Y, Li B, Yi J, et al. Robot-assisted versus conventional minimally invasive esophagectomy for resectable esophageal squamous cell carcinoma: early results of a multicenter randomized controlled trial: the RAMIE trial. *Ann Surg* 2022;275:646-53. [DOI PubMed](#)
32. Tagkalos E, van der Sluis PC, Berlth F, et al. Robot-assisted minimally invasive thoraco-laparoscopic esophagectomy versus minimally invasive esophagectomy for resectable esophageal adenocarcinoma, a randomized controlled trial (ROBOT-2 trial). *BMC Cancer* 2021;21:1060. [DOI PubMed PMC](#)
33. Chao YK, Li ZG, Wen YW, et al. Robotic-assisted Esophagectomy vs Video-Assisted Thoracoscopic Esophagectomy (REVATE): study protocol for a randomized controlled trial. *Trials* 2019;20:346. [DOI PubMed PMC](#)
34. Ladak F, Dang JT, Switzer N, et al. Indocyanine green for the prevention of anastomotic leaks following esophagectomy: a meta-analysis. *Surg Endosc* 2019;33:384-94. [DOI PubMed](#)
35. Casas MA, Angeramo CA, Bras Harriott C, Dreifuss NH, Schlottmann F. Indocyanine green (ICG) fluorescence imaging for prevention of anastomotic leak in totally minimally invasive Ivor Lewis esophagectomy: a systematic review and meta-analysis. *Dis Esophagus* 2022;35:doab056. [DOI PubMed](#)
36. LeBlanc G, Takahashi C, Huston J, Shridhar R, Meredith K. The use of indocyanine green (ICYG) angiography intraoperatively to evaluate gastric conduit perfusion during esophagectomy: does it impact surgical decision-making? *Surg Endosc* 2023. [DOI PubMed](#)
37. de Groot EM, Kuiper GM, van der Veen A, et al. Indocyanine green fluorescence in robot-assisted minimally invasive esophagectomy with intrathoracic anastomosis: a prospective study. *Updates Surg* 2023;75:409-18. [DOI PubMed PMC](#)
38. Low DE, Allum W, De Manzoni G, et al. Guidelines for perioperative care in esophagectomy: Enhanced Recovery After Surgery (ERAS<sup>®</sup>) society recommendations. *World J Surg* 2019;43:299-330. [DOI PubMed](#)
39. Froghi F, Sanders G, Berrisford R, et al. A randomised trial of post-discharge enteral feeding following surgical resection of an upper gastrointestinal malignancy. *Clin Nutr* 2017;36:1516-9. [DOI PubMed](#)