

Review

Open Access



# State-of-the-art management for challenging complications in head and neck surgery

Kiran Ganga<sup>1</sup>, Caitlin McMullen<sup>2</sup>

<sup>1</sup>Department of Nutritional Sciences, Cornell University, Ithaca, NY 14850, USA.

<sup>2</sup>Head & Neck - Endocrine Oncology, Moffitt Cancer Center, Tampa, FL 33612, USA.

**Correspondence to:** Dr. Caitlin McMullen, Department of Head & Neck-Endocrine Oncology, H. Lee Moffitt Cancer Center and Research Institute, 12902 Magnolia Drive, Tampa, FL 33612, USA. E-mail: Caitlin.mcmullen@moffitt.org

**How to cite this article:** Ganga K, McMullen C. State-of-the-art management for challenging complications in head and neck surgery. *Plast Aesthet Res* 2023;10:69. <https://dx.doi.org/10.20517/2347-9264.2023.65>

**Received:** 4 Jul 2023 **First Decision:** 14 Sep 2023 **Revised:** 27 Sep 2023 **Accepted:** 11 Dec 2023 **Published:** 11 Dec 2023

**Academic Editors:** Marten Basta, Ruben Yap Kannan **Copy Editor:** Yanbing Bai **Production Editor:** Yanbing Bai

## Abstract

Head and neck surgical complications can result in significant morbidity for patients. Innovations over the past few years have shown promise in mitigating these effects. Specifically, new medications, bioactive agents, and bioengineered materials may reduce the resultant morbidity. Certain historic existing medical therapies, such as oxandrolone, tissue plasminogen activator, and royal jelly/honey, have *new* applications in the management of challenging head and neck surgical complications. This review describes some of the more common and challenging complications in head and neck surgery and modern techniques for management.

**Keywords:** Chylous fistula, venous thrombosis, nerve injury, microvascular free flap, octreotide, fistula

## INTRODUCTION

Even the most experienced head and neck surgeons encounter complications. Many of these complications are well-reported in the scientific literature, with varied strategies and solutions described. In recent years, there has been notable progress in management options, including the development and implementation of new technologies and medical therapies. This review delves into innovations for a few common and challenging ablative and reconstructive surgical complications.



© The Author(s) 2023. **Open Access** This article is licensed under a Creative Commons Attribution 4.0 International License (<https://creativecommons.org/licenses/by/4.0/>), which permits unrestricted use, sharing, adaptation, distribution and reproduction in any medium or format, for any purpose, even commercially, as long as you give appropriate credit to the original author(s) and the source, provide a link to the Creative Commons license, and indicate if changes were made.



## ABLATIVE COMPLICATIONS

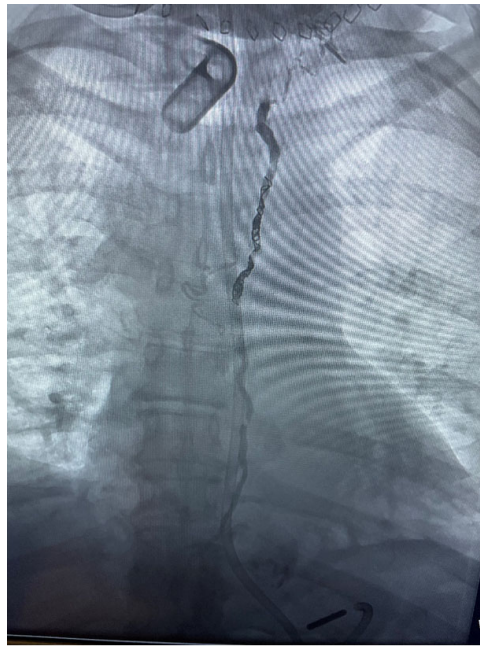
### Chyle leak

Chyle leak, or chylous fistula, can be a nuisance complication that may lead to malnutrition and prolonged wound healing in severe cases. The thoracic duct is more susceptible in the left lower neck during lateral neck dissection, but these can also occur during central neck dissections or right neck dissections. If identified intraoperatively, direct maneuvers can be implemented, such as ligation via surgical clips or sutures or locoregional muscle flaps. The addition of fibrin sealant could be incorporated for increased coverage of the wound bed<sup>[1]</sup>. Valsalvae with direct observation for leakage and closed suction drain placement should be performed to ensure the leak has been resolved. Drain fluid with a milky appearance, or triglyceride levels > 110 mg/dL, and chylomicron levels > 4% in equivocal cases is diagnostic<sup>[2]</sup>.

Postoperative treatment is dependent on the output - variably defined - but typically defined as over 500 mL per day. Initial management of low output chyle leaks (< 500 mL/day) includes bed rest, pressure dressings, electrolyte monitoring, and adoption of a nonfat, low-fat diet, or medium-chain fatty acid (MCFA) diet<sup>[2]</sup>. Dietary/nutritional management can be effective in approximately 80% of low-output cases<sup>[3]</sup>. Octreotide, or a long-acting somatostatin, reduces lymph production and decreases its flow via reduction of gastric and pancreatic secretions<sup>[4]</sup>. This medication decreases the absorption of triglycerides, inhibiting gastrointestinal motility and inhibiting splanchnic circulation - all of which reduce lymph flow<sup>[5,6]</sup>. Typically, octreotide is added when other conservative methods are inadequate<sup>[7]</sup>. While there are no official guidelines on dosing, the suggested dosage from the literature ranges from 150 to 750 µg subcutaneously, with most patients receiving no more than 300 µg. A recent systematic review reported a high rate of resolution with octreotide, higher than oral dietary management alone, but the overall level of evidence is low<sup>[8]</sup>. If these measures fail, total parenteral nutrition, which bypasses the gastrointestinal lymphatic system via a central venous line, can be offered; however, this strategy has its own inherent risks, such as fungemia and complications related to central access.

Pancreatic lipase inhibitors have also been recommended to prevent the resorption of fat cells in the intestine<sup>[9]</sup>. Negative wound pressure therapy shows promise but needs further study<sup>[10]</sup>. Another potential avenue is the use of sclerosing agents, such as OK-432 and tetracycline, which may stop chyle leak by causing an additional inflammatory response<sup>[11,12]</sup>. These agents are not used frequently, and their usage is associated with other complications, such as pain and nerve injury; moreover, the resulting inflammation could complicate any later surgical intervention<sup>[4]</sup>.

High output leaks (> 500 mL/day) typically require surgical intervention. Re-entry into the neck can be challenging due to inflammation, but surgery often significantly reduces or resolves the outflow. Cervical thoracic duct ligation can be performed concurrently with the use of muscle flaps, sclerosing agents, and fibrin sealant. Lymphangiography with or even without embolization of the thoracic duct via interventional radiology can be effective [Figure 1]<sup>[13-15]</sup>. The thoracic duct can be accessed percutaneously at the cisterna chyli in the abdomen by interventional radiology with subsequent cannulation and selective embolization of the thoracic duct distally. Thoracic duct embolism and disruptions are both safe and minimally invasive treatments for chyle leaks, although they appear to be more successful for lower leak volumes, and more clinical data are needed<sup>[16]</sup>. Lastly, consultation with thoracic surgery for intrathoracic ligation via video-assisted thoracoscopic surgery can be definitive. Thoracic/interventional radiology techniques to ligate the duct more proximally may be an ideal option if there is a microvascular anastomosis at risk with re-opening the neck.



**Figure 1.** Embolization of the thoracic duct via access to the cisterna chyli is demonstrated.

### **Salivary fistula after parotid surgery**

Post-parotidectomy, a salivary fistula with salivary drainage is a common consequence. While salivary fistulas are typically submitted to conservative treatment of pressure dressings and observation, other interventions may be needed.

The optimal modality of prevention is unclear, but many techniques have been described. Intraoperative infusion of methylene blue into the distal end of Stensen's duct to identify leakage in the wound bed has been suggested<sup>[17]</sup>. Application of platelet-rich plasma gel to the surgical bed and intraoperative direct injection of botulinum toxin has demonstrated a reduction in salivary complications in small case series<sup>[18,19]</sup>. The use of the harmonic scalpel appears to reduce the risk of salivary fistula compared to electrocautery<sup>[20]</sup>.

First-line postoperative management includes the use of needle aspiration (if amenable) followed by anticholinergic drugs (including glycopyrrolate, atropine, and scopolamine). These medications are often poorly tolerated due to nausea, constipation, xerostomia, and visual difficulties, amongst others<sup>[21,22]</sup>. Several rounds of needle aspiration may be needed, and in some rare cases, the insertion of an indwelling drain or catheter may be required.

Botulinum toxin type A has been reported as an effective primary treatment for salivary fistula and should be strongly considered prior to any invasive maneuvers. Botulinum type A leads to muscle paralysis by inhibiting acetylcholine release at the cholinergic synapses of the autonomic nervous system, affecting fibers of the salivary gland<sup>[23]</sup>. The total dosage in literature has ranged from 10 to 200 units administered in small aliquots distributed throughout the residual parotid gland with an effectiveness of 70%-100% after an injection<sup>[21,24]</sup>. Ultrasound can be used to target salivary tissue and sialoceles for injection. A less desirable option is the use of low-dose radiation therapy to shrink the salivary gland, which may be practical for patients already requiring therapy for oncologic reasons<sup>[25,26]</sup>. The procedure can be repeated, but in this author's experience, a single round of injection is typically sufficient.

In cases where other treatments have proven ineffective, one option to consider is tympanic neurectomy. This procedure involves the complete excision of the tympanic nerve, which serves as the secretomotor parasympathetic nerve supply to the parotid gland, achieved by accessing it through the hypotympanic floor. This approach effectively halts salivation altogether<sup>[27]</sup>. Generally, the chorda tympani nerve is saved. A reoperation on the surgical site may be considered, but it carries the risk of potential injury to the facial nerve.

### **Nerve transection**

Head and neck surgery places most cranial nerves at risk. Fortunately, accidental injury is rare, but it can occur inadvertently or may be required due to oncologic needs. If possible, end-to-end direct suturing should be performed, but it may still lead to significant regeneration and permanent deficit<sup>[28]</sup>. Injury or transection that prevents innervation of the distal nerve stump without tension can be managed with nerve grafting, though this is not always possible. Autologous nerve grafting is described by the excision of a donor nerve, such as the greater auricular or sural nerve, and suturing this into the injured nerve gap in the same patient; it assists in the recovery and nutrient supply to the injured nerve<sup>[28]</sup>.

Comorbidities associated with nerve trauma and grafting have led to the development of innovative biomaterials such as nerve guidance conduits (which offer an advantage by guiding axons to a distal stump) and immunosuppressive human-derived nerve grafts. Attention is being paid to small intestine submucosa as a biomaterial for conduits and anastomosis protectors, as it is collagen-rich and may contain many beneficial growth factors for nerve regeneration<sup>[29,30]</sup>. Conduits can be used for nerve gaps up to 5 mm. Human-derived acellular nerve graft products demonstrated 82% meaningful recovery at lengths up to 70 mm, but other authors have reported mixed results<sup>[31,32]</sup>. Immunosuppressive medications are not required for these materials.

### **Tranexamic acid and intraoperative/postoperative medicine**

Tranexamic acid (TXA) is an antifibrinolytic amino acid derivative well known in trauma and peripartum hemorrhage, but it is increasingly applied in head and neck surgery. Most studies note effectiveness, but mixed results have been reported. TXA, an analog of the lysine amino acid that binds plasminogen, works by blocking the interaction between plasmin and fibrin to prevent the breakdown of formed clots<sup>[33,34]</sup>. This medical can be administered topically, such as for oral cavity and oropharyngeal bleeding, and intravenously. It is gaining increased attention as it may have a more controllable prognosis and minimal risk of complications. TXA has been assessed in various head and neck surgical procedures such as thyroidectomy, neck dissection, and microvascular free flap surgery<sup>[34]</sup>. Current evidence is mixed but suggests potential advantages in several aspects of various procedures, including a reduction in intraoperative blood loss, shorter operating times, fewer transfusions, reduced drain output, and decreased likelihood of reoperation in a variety of procedures, but further, more comprehensive research is needed to warrant these findings<sup>[34,35]</sup>. Current studies indicate no influence on flap failure, postoperative complications, or the number of required transfusions when TXA was administered. Notably, TXA administration was associated with decreased blood loss<sup>[36]</sup>. In the context of free tissue transfer, TXA has demonstrated a relatively safe profile without increasing the risk of thrombosis, suggesting it may be safe even for patients with anemia or a higher risk of intra- and postoperative blood loss. Nonetheless, ongoing research is necessary to refine our understanding of TXA's role in surgical situations<sup>[37]</sup>.

## **RECONSTRUCTIVE COMPLICATIONS**

### **Salivary or pharyngocutaneous fistulas**

Postoperative fistula formation after major head and neck surgery can be a challenging complication. Patients with poor nutritional status and prior radiation therapy are particularly at risk. Fistula can result in

prolonged hospital stay, infection, wound breakdown, microvascular complications, hemorrhage, and prolonged NPO status. Typical management begins with conservative therapy, including NPO status, wound packing, and antibiotics.

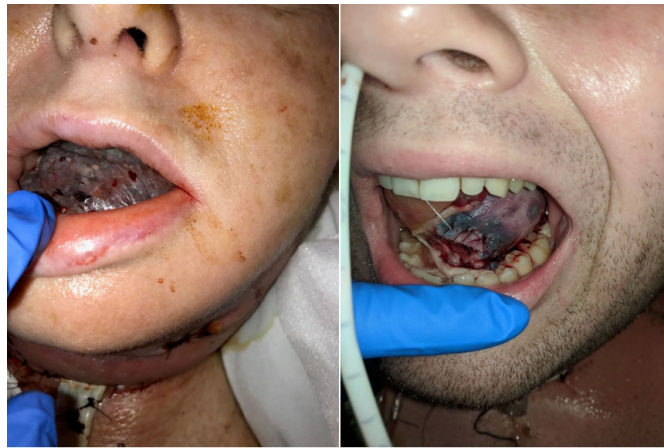Negative pressure wound therapy (NPWT) has increasingly been used for wounds in the head and neck region, including for the management of fistulas. NPWT may assist in removing drainage from the wound site, facilitating wound healing and tissue formation. A case series of five patients treated with NPWT after ablative and reconstructive surgery demonstrates that the treatment can be successful in treating unfilled dead space and avoiding postoperative infections in high-risk patient populations<sup>[38]</sup>. While most results are promising, it is imperative to note that studies assessing this issue define “success” differently; for example, some may consider “success” to just be the formation of granulation tissue in the PCF tract<sup>[39]</sup>. One study reports that maintaining the seal is difficult due to the proximity of pharyngocutaneous fistulas to the tracheal stroma, which makes it hard for the vacuum to stay to the skin<sup>[40]</sup>. It is key to consider the minimal side effects associated with NPWT, apart from discomfort and potential bleeding<sup>[41]</sup>. Intraluminal placement into the pharyngeal aspect of the defect has also been shown to be feasible and safe<sup>[42]</sup>.

Additionally, there are nutrition and immunonutrition efforts to consider that may reduce fistulas or prevent them from occurring. Studies demonstrate that the administration of a pre- and perioperative diet with arginine, fish oil, and glutamine in head and neck cancer surgery patients led to a reduction in mucocutaneous fistula<sup>[43-45]</sup>. There was a significant association between this immune-enhancing diet and a decrease in fistula rates. Some authors advise high-calorie nutritional supplements preoperatively<sup>[46]</sup>. Perioperative oxandrolone administration has also shown some promise<sup>[47]</sup>. Oxandrolone is a testosterone derivative used for weight gain. Usage has been shown to improve prealbumin levels and wound healing when administered 10mg bidaily<sup>[47]</sup>.

### **Vascular compromise of free and regional flaps**

Free flap failure is a major complication that can cause significant morbidity in head and neck surgery patients [Figure 2]. In the rare circumstance of vascular compromise and subsequent partial or complete flap loss, patients may suffer functionally and aesthetically devastating wounds, and may develop challenging pharyngocutaneous fistulae that put major vessels at risk of hemorrhage, resulting in prolonged hospital stays and even death. After recognition, the initial management technique is reoperation to examine the vessels and address potential technical issues such as poor geometry or kinking, or arterial or venous thrombosis at the site of anastomoses. Mechanical thrombectomy can be performed by manually removing with vascular dilators, small Fogarty catheters, and a revision anastomosis, though these methods can cause endothelial damage<sup>[48]</sup>. Thrombolytic agents can also be administered concurrently, postoperatively, or as an alternative if the patient is unfit for revision surgery. Systemic heparin administration is a common adjunct. The optimal thrombolytic agent is still unclear<sup>[49]</sup>. Tissue plasminogen activator (TPA) is a thrombolytic agent that breaks down blood clots and restores blood flow to ischemic regions, as it helps to immediately relieve the hypercoagulable state<sup>[48]</sup>. Its use can be beneficial before re-exploration of the flap or for patients who are not suitable candidates for further surgical interventions<sup>[50,51]</sup>. Administration can occur intraoperatively through the arterial inflow after the vein has been taken down to minimize systemic absorption. TPA can also be administered subcutaneously into the flap intraoperatively or at the bedside at regular intervals. A total dose of 2 mg is injected into small various aliquots throughout the flap paddle. This technique may assist in salvaging the flap, but concurrent administration with intravenous heparin or systemic anticoagulation should be cautioned as there may be risks of significant hemorrhage<sup>[48,51]</sup>.





**Figure 2.** Examples of venous congestion of free flaps.

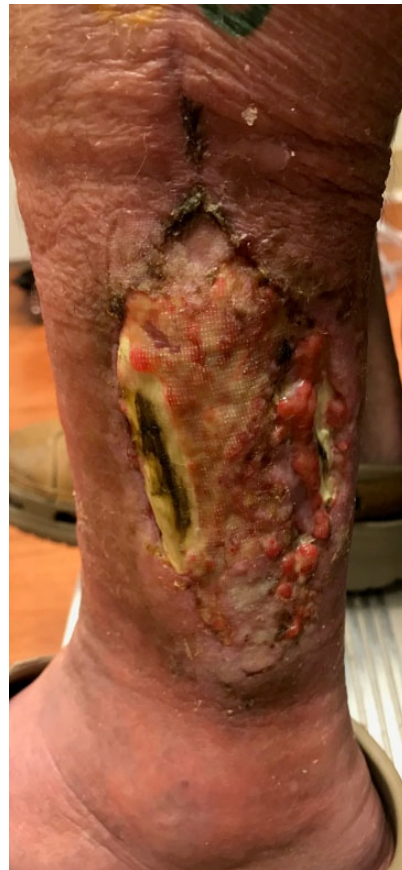The usage of topical nitropaste in addressing reconstructive complications is gaining attention. This agent plays a role in vasodilation and relaxation of smooth muscles, predominantly benefiting the venous system. Existing evidence suggests that applying up to 20% topical nitropaste can aid in flap success. Furthermore, it exhibits the potential to reduce thrombosis, enhance platelet aggregation, and prevent vasospasms. Research has indicated a reduction in flap loss and necrosis along with an increase in the viable tissue when topical nitropaste is employed. However, it is important to note that these findings require further substantiation and more research into its applicability, particularly concerning head and neck flaps<sup>[52]</sup>.

Leech therapy, using the species *Hirudo medicinalis*, is an option to relieve venous congestion. While drawing blood, the leech releases hirudin, originating from salivary glands, as well as histamine-like vasodilators that all contribute to its medicinal function and role as anticoagulant, anti-platelet aggregate, and antithrombotic agent<sup>[53]</sup>. It is worth noting that this approach could be considered secondarily for salvage after thrombectomy or usage of thrombolytic agents. However, a protocol for leeching is not yet fully established<sup>[48,54]</sup>. It is crucial to maintain a vigilant approach when considering leech therapy, as it can potentially lead to anemia and infections caused by *Aeromonas* spp. Therefore, it is essential to closely monitor blood counts and complement the treatment with antibiotic prophylaxis<sup>[55,56]</sup>. Hyperbaric oxygen therapy may be used to deliver more oxygen to tissues and stimulate angiogenesis<sup>[57]</sup>. Overall, the quality of research in the management of vascular compromise of free flaps is low, limited to case series and anecdotal reports due to the rarity of these events.

### Flap donor site complications

Donor site complications can be troubling and prolonged recovery after major head and neck surgery. Commonly encountered issues include poor skin graft take and tendon exposure [Figure 3]. Intraoperatively, a few techniques have been described to maximize skin graft take on the wound bed. Placement of a NWPT device at the conclusion of the procedure has shown some promise, but overall mixed results, in improving site complications. A barrier such as Vaseline-impregnated gauze must be placed between the skin graft and foam to prevent trauma to the skin graft once the device is removed.

Specialized fibrin sealant has been described to augment the adherence of skin grafts to the donor site wound bed. The sealant has been associated with reduced seroma formation under the graft, faster healing, reduction in graft loss, and less postoperative pain, but results are mixed<sup>[58,59]</sup>. This material can be costly and further study is warranted.



**Figure 3.** Tendon exposure and loss of skin graft are demonstrated on a fibular donor site.

Once tissue necrosis or poor healing is noted postoperatively, debridement to remove dead tissue from a wound may be necessary to prevent infection and improve epithelialization. This can be done surgically, mechanically (although this is more painful and nonselective), or enzymatically (which may be uncomfortable for a patient). Hydrosurgery is an avenue of debridement to consider, using a handpiece with a nozzle to deliver pressurized saline water to remove dead tissue; however, this is more commonly used for burn wounds and its applicability to reconstructive surgeries is still unclear<sup>[60]</sup>. Larval or maggot debridement therapy has been described, but it is aversive. Maggots release secretions with proteolytic digestive enzymes that dissolve dead tissue and also contain antimicrobial elements<sup>[61]</sup>.

Wound care products, some impregnated with bioactive agents, have shown promise in assisting in the healing process. Cobalt-impregnated and silver nanoparticle-based agents within wound dressings may augment wound healing<sup>[62,63]</sup>. Bee-derived defensin-1, which can be found in honey and royal jelly, has demonstrated efficacy in promoting wound healing and re-epithelialization<sup>[64,65]</sup>. Overall, the available evidence supporting certain donor site management is limited.

## CONCLUSION

Head and neck surgery complications can result in significant morbidity and mortality. Fortunately, numerous innovations have emerged that show promise in mitigating these preoperatively, intraoperatively, and postoperatively.

## DECLARATIONS

### Authors' contributions

Made substantial contributions to the conception and design of the review and performed literature review and interpretation of available literature: Ganga K, McMullen C

### Availability of data and materials

Not applicable.

### Financial support and sponsorship

None.

### Conflicts of interest

Both authors declared that there are no conflicts of interest.

### Ethical approval and consent to participate

Not applicable.

### Consent for publication

Not applicable.

### Copyright

© The Author(s) 2023.

## REFERENCES

1. Delaney SW, Shi H, Shokrani A, Sinha UK. Management of chyle leak after head and neck surgery: review of current treatment strategies. *Int J Otolaryngol* 2017;2017:8362874. [DOI](#) [PubMed](#) [PMC](#)
2. Smith R, Higginson J, Breik O, Praveen P, Parmar S. Nutritional management of chyle leak after head and neck surgery: a systematic review and proposed protocol for management. *Oral Maxillofac Surg* 2023:1-12. [DOI](#) [PubMed](#)
3. Smoke A, Delege MH. Chyle leaks: consensus on management? *Nutr Clin Pract* 2008;23:529-32. [DOI](#) [PubMed](#)
4. Leović D, Pastorčić Grgić M, Gugić Radojković I, Blivajs I, Matoc L, Gršić K. Management of chyle leak following head and neck surgery: review of current treatment strategies and algorithmic approach to the treatment. *Acta Clin Croat* 2022;61:88-95. [DOI](#) [PubMed](#) [PMC](#)
5. Baker A, Tassone P, Dooley LM, Galloway TI, Zitsch RP 3rd. Postoperative chyle leak rate following neck dissection for squamous cell carcinoma versus papillary thyroid cancer. *Laryngoscope* 2023;133:2959-64. [DOI](#) [PubMed](#)
6. Swanson MS, Hudson RL, Bhandari N, Sinha UK, Maceri DR, Kokot N. Use of octreotide for the management of chyle fistula following neck dissection. *JAMA Otolaryngol Head Neck Surg* 2015;141:723-7. [DOI](#) [PubMed](#)
7. Sharkey AJ, Rao JN. The successful use of octreotide in the treatment of traumatic chylothorax. *Tex Heart Inst J* 2012;39:428-30. [PubMed](#) [PMC](#)
8. Molena E, King E, Davies-Husband C. Octreotide versus oral dietary modification for the treatment of chylous fistula following neck dissection: a systematic review and meta-analysis. *Clin Otolaryngol* 2021;46:474-84. [DOI](#) [PubMed](#)
9. Belloso A, Saravanan K, de Carpentier J. The community management of chylous fistula using a pancreatic lipase inhibitor (orlistat). *Laryngoscope* 2006;116:1934-5. [DOI](#) [PubMed](#)
10. Campisi CC, Boccardo F, Piazza C, Campisi C. Evolution of chylous fistula management after neck dissection. *Curr Opin Otolaryngol Head Neck Surg* 2013;21:150-6. [DOI](#) [PubMed](#)
11. Nandy K, Jayaprakash D, Rai S, Kumar A, Puj K, Tripathi U. Management of chyle leak after head and neck surgery; our meritorious experience in 52 cases and review of literature. *Indian J Otolaryngol Head Neck Surg* 2022;74:5978-83. [DOI](#) [PubMed](#) [PMC](#)
12. Hashimoto Y, Teshima M, Yui M, et al. OK432 sclerotherapy for refractory chylous leakage after neck dissection. *J Surg Case Rep* 2023;2023:rjad310. [DOI](#) [PubMed](#) [PMC](#)
13. Moussa AM, Maybody M, Gonzalez-Aguirre AJ, Buicko JL, Shaha AR, Santos E. Thoracic duct embolization in post-neck dissection chylous leakage: a case series of six patients and review of the literature. *Cardiovasc Intervent Radiol* 2020;43:931-7. [DOI](#) [PubMed](#) [PMC](#)
14. Chen CY, Chen YH, Shiau EL, Liang HL, Chang HS, Chen HC. Therapeutic role of ultrasound-guided intranodal lymphangiography in refractory cervical chylous leakage after neck dissection: report of a case and review of the literature. *Head Neck* 2016;38:E54-60. [DOI](#) [PubMed](#)



15. Chen E, Itkin M. Thoracic duct embolization for chyloous leaks. *Semin Intervent Radiol* 2011;28:63-74. DOI PubMed PMC
16. Pamarthi V, Stecker MS, Schenker MP, et al. Thoracic duct embolization and disruption for treatment of chyloous effusions: experience with 105 patients. *J Vasc Interv Radiol* 2014;25:1398-404. DOI
17. Zou HW, Li WG, Huang SY, Chen ZW, Zhang DS. New method to prevent salivary fistula after parotidectomy. *Br J Oral Maxillofac Surg* 2019;57:801-2. DOI PubMed
18. Ricci E, Riva G, Dagna F, Cavalot AL. The use of platelet-rich plasma gel in superficial parotidectomy. *Acta Otorhinolaryngol Ital* 2019;39:363-6. DOI PubMed PMC
19. Lee DJ, Lee YM, Park HJ, Lee JW, Cha W. Intraoperative botulinum toxin injection for superficial partial parotidectomy: a prospective pilot study. *Clin Otolaryngol* 2021;46:998-1004. DOI PubMed
20. Li D, Kou Y, Huang S, Wang Z, Ning C, Zhao T. The harmonic scalpel versus electrocautery for parotidectomy: a meta - analysis. *J Craniomaxillofac Surg* 2019;47:915-21. DOI
21. Belcastro A, Reed W, Puscas L. The management of salivary fistulas. *Semin Plast Surg* 2023;37:4-8. DOI PubMed PMC
22. Bhattarai HB, Yadav R, Shah S, et al. A case report on role of hypertonic saline solution in management of parotid fistula. *Ann Med Surg* 2022;80:104208. DOI PubMed PMC
23. Lim YC, Choi EC. Treatment of an acute salivary fistula after parotid surgery: botulinum toxin type A injection as primary treatment. *Eur Arch Otorhinolaryngol* 2008;265:243-5. DOI PubMed
24. Maharaj S, Mungul S, Laher A. Botulinum toxin A is an effective therapeutic tool for the management of parotid sialoceles and fistula: a systematic review. *Laryngoscope Investig Otolaryngol* 2020;5:37-45. DOI PubMed PMC
25. Bowers EMR, Schaitkin B. Management of mucoceles, sialoceles, and ranulas. *Otolaryngol Clin North Am* 2021;54:543-51. DOI PubMed
26. Shimm DS, Berk FK, Tilsner TJ, Coulthard SW. Low-dose radiation therapy for benign salivary disorders. *Am J Clin Oncol* 1992;15:76-8. DOI PubMed
27. Mandour MA, El-Sheikh MM, El-Garem F. Tympanic neurectomy for parotid fistula. *Arch Otolaryngol* 1976;102:327-9. DOI PubMed
28. Raza C, Riaz HA, Anjum R, Shakeel NUA. Repair strategies for injured peripheral nerve: review. *Life Sci* 2020;243:117308. DOI PubMed
29. Yi JS, Lee HJ, Lee HJ, Lee IW, Yang JH. Rat peripheral nerve regeneration using nerve guidance channel by porcine small intestinal submucosa. *J Korean Neurosurg Soc* 2013;53:65-71. DOI PubMed PMC
30. Safa B, Buncke G. Autograft substitutes: conduits and processed nerve allografts. *Hand Clin* 2016;32:127-40. DOI PubMed
31. Safa B, Jain S, Desai MJ, et al. Peripheral nerve repair throughout the body with processed nerve allografts: results from a large multicenter study. *Microsurgery* 2020;40:527-37. DOI PubMed PMC
32. Peters BR, Wood MD, Hunter DA, Mackinnon SE. Acellular nerve allografts in major peripheral nerve repairs: an analysis of cases presenting with limited recovery. *Hand* 2023;18:236-43. DOI PubMed PMC
33. Golembiewski J. Antifibrinolytic use in the perioperative setting: aminocaproic acid and tranexamic acid. *J Perianesth Nurs* 2015;30:560-3. DOI PubMed
34. Jamshaid W, Jamshaid M, Coulson C, Sharma N, Muzaffar J, Nieto H. A systematic review on the efficacy of tranexamic acid in head and neck surgery. *Clin Otolaryngol* 2023;48:527-39. DOI
35. Chen CC, Wang CC, Wang CP, Lin TH, Lin WD, Liu SA. Prospective, randomized, controlled trial of tranexamic acid in patients who undergo head and neck procedures. *Otolaryngol Head Neck Surg* 2008;138:762-7. DOI PubMed
36. Klifto KM, Hanwright PJ, Sacks JM. Tranexamic acid in microvascular free flap reconstruction. *Plast Reconstr Surg* 2020;146:517e-8e. DOI PubMed
37. Lardi AM, Dreier K, Junge K, Farhadi J. The use of tranexamic acid in microsurgery-is it safe? *Gland Surg* 2018;7:S59-63. DOI PubMed PMC
38. O'Malley QF, Sims JR, Sandler ML, Spitzer H, Urken ML. The use of negative pressure wound therapy in the primary setting for high-risk head and neck surgery. *Am J Otolaryngol* 2020;41:102470. DOI PubMed
39. Locatello LG, Licci G, Maggiore G, Gallo O. Non-surgical strategies for assisting closure of pharyngocutaneous fistula after total laryngectomy: a systematic review of the literature. *J Clin Med* 2021;11:100. DOI PubMed PMC
40. Loaec E, Vaillant PY, Bonne L, Marianowski R. Negative-pressure wound therapy for the treatment of pharyngocutaneous fistula. *Eur Ann Otorhinolaryngol Head Neck Dis* 2014;131:351-5. DOI PubMed
41. Waldie K. Pain associated with negative pressure wound therapy. *Br J Nurs* 2013;22:S15-6-8-21. DOI PubMed
42. Asher SA, White HN, Illing EA, Carroll WR, Magnuson JS, Rosenthal EL. Intraluminal negative pressure wound therapy for optimizing pharyngeal reconstruction. *JAMA Otolaryngol* 2014;140:143-9. DOI PubMed
43. Sittitrai P, Ruenmarkkaew D, Booyaprapa S, Kasempitakpong B. Effect of a perioperative immune-enhancing diet in clean-contaminated head and neck cancer surgery: a randomized controlled trial. *Int J Surg* 2021;93:106051. DOI PubMed
44. Barajas-Galindo DE, Vidal-Casariago A, Pintor-de la Maza B, et al. Postoperative enteral immunonutrition in head and neck cancer patients: impact on clinical outcomes. *Endocrinol Diabetes Nutr* 2020;67:13-9. DOI
45. Mueller SA, Mayer C, Bojaxhiu B, et al. Effect of preoperative immunonutrition on complications after salvage surgery in head and neck cancer. *J Otolaryngol Head Neck Surg* 2019;48:25. DOI PubMed PMC
46. Sanchez A, Frank E, Inman J, Wang W, Namin A, Ducic Y. Fistula management in head and neck cancer. *Semin Plast Surg*

- 2020;34:299-304. DOI PubMed PMC
47. Osmolak AM, Klatt-Cromwell CN, Price AM, Sanclement JA, Krempel GA. Does perioperative oxandrolone improve nutritional status in patients with cachexia related to head and neck carcinoma? *Laryngoscope Investig Otolaryngol* 2019;4:314-8. DOI PubMed PMC
  48. Hathorn T, Nickel C, Sharma A, Shabani S, Padhya T, Mifsud M. How do i salvage that flap?; an evidence-based primer on salvage techniques for head & neck microvascular free flaps. *Oral Oncol* 2023;136:106246. DOI PubMed
  49. Coeugnet E, Al Yafi MN, Lafrance D, et al. Microcirculatory free flap failure with patent anastomosis salvaged by in situ thrombolysis in vulnerable phase burn. *J Burn Care Res* 2019;40:718-22. DOI
  50. Senchenkov A, Lemaine V, Tran NV. Management of perioperative microvascular thrombotic complications - the use of multiagent anticoagulation algorithm in 395 consecutive free flaps. *J Plast Reconstr Aesthet Surg* 2015;68:1293-303. DOI PubMed
  51. Ihler F, Matthias C, Canis M. Free flap salvage with subcutaneous injection of tissue plasminogen activator in head and neck patients. *Microsurgery* 2013;33:478-81. DOI PubMed
  52. DeVito RG, Stranix JT. Is nitropaste effective in stressed flaps? *Ann Plast Surg* 2023;90:S356-8. DOI PubMed
  53. Shtraks JP, Peng GL, Nassif PS. Utilization of leech therapy after rhinoplasty. *Plast Reconstr Surg* 2022;149:1090e-5e. DOI PubMed
  54. Tashiro K, Fujiki M, Arikawa M, Kagaya Y, Miyamoto S. Free flap salvage after recurrent venous thrombosis by means of large-scale treatment with medical leeches. *Plast Reconstr Surg Glob Open* 2016;4:e1157. DOI PubMed PMC
  55. Sig AK, Guney M, Uskudar Guclu A, Ozmen E. Medicinal leech therapy-an overall perspective. *Integr Med Res* 2017;6:337-43. DOI PubMed PMC
  56. Krueer RM, Barton CA, Roberti G, Gilbert B, McMillian WD. Antimicrobial prophylaxis during *Hirudo medicinalis* therapy: a multicenter study. *J Reconstr Microsurg* 2015;31:205-9. DOI PubMed
  57. Francis A, Baynosa RC. Hyperbaric oxygen therapy for the compromised graft or flap. *Adv Wound Care* 2017;6:23-32. PubMed PMC
  58. Grunzweig KA, Ascha M, Kumar AR. Fibrin tissue sealant and minor skin grafts in burn surgery: a systematic review and meta-analysis. *J Plast Reconstr Aesthet Surg* 2019;72:871-83. DOI PubMed
  59. Paw E, Vangaveti V, Zonta M, Heal C, Gunnarsson R. Effectiveness of fibrin glue in skin graft survival: a systematic review and meta-analysis. *Ann Med Surg* 2020;56:48-55. DOI PubMed PMC
  60. Legemate CM, Goei H, Gostelie OFE, Nijhuis THJ, van Baar ME, van der Vlies CH; Dutch Burn Repository Group. Application of hydrosurgery for burn wound debridement: an 8-year cohort analysis. *Burns* 2019;45:88-96. DOI PubMed
  61. Moya-López J, Costela-Ruiz V, García-Recio E, Sherman RA, De Luna-Bertos E. Advantages of maggot debridement therapy for chronic wounds: a bibliographic review. *Adv Skin Wound Care* 2020;33:515-25. DOI PubMed
  62. Solanki AK, Lali FV, Autefage H, et al. Bioactive glasses and electrospun composites that release cobalt to stimulate the HIF pathway for wound healing applications. *Biomater Res* 2021;25:1. DOI PubMed PMC
  63. Paladini F, Pollini M. Antimicrobial silver nanoparticles for wound healing application: progress and future trends. *Materials* 2019;12:2540. DOI PubMed PMC
  64. Oryan A, Alemzadeh E, Moshiri A. Biological properties and therapeutic activities of honey in wound healing: a narrative review and meta-analysis. *J Tissue Viability* 2016;25:98-118. DOI PubMed
  65. Bucekova M, Sojka M, Valachova I, et al. Bee-derived antibacterial peptide, defensin-1, promotes wound re-epithelialisation in vitro and in vivo. *Sci Rep* 2017;7:7340. DOI PubMed PMC