

Case Report

Open Access



# Challenges in determining the malignant potential of atypical neurofibromas (aNf) using histopathologic features and the potential need for *CDKN2A/2B* testing: a case report

Andrea M. Gross<sup>1, #</sup> , Sana Z. Mahmood<sup>1, #</sup>, Eva Dombi<sup>1</sup>, Markku Miettinen<sup>2</sup>, Mark Raffeld<sup>2</sup>, Anne Dufek<sup>1</sup>, Sneh Patel<sup>1</sup>, Prashant Chittiboina<sup>3</sup>, Brigitte C. Widemann<sup>1</sup>

<sup>1</sup>Pediatric Oncology Branch, Center for Cancer Research, National Cancer Institute, Bethesda, MD 20892, USA.

<sup>2</sup>Laboratory of Pathology, Center for Cancer Research, National Cancer Institute, Bethesda, MD 20892, USA.

<sup>3</sup>Surgical Neurology Branch, National Institute of Neurologic Disorders and Stroke, Bethesda, MD 20892, USA.

<sup>#</sup>Authors contributed equally to this work.

**Correspondence to:** Dr. Brigitte C. Widemann, Pediatric Oncology Branch, Center for Cancer Research, National Cancer Institute, 10 Center Drive, Room 1-3750, Bethesda, MD 20852, USA. E-mail: widemanb@mail.nih.gov; Dr. Andrea M. Gross, Pediatric Oncology Branch, Center for Cancer Research, National Cancer Institute, 10 Center Drive, Room 1-5742, Bethesda, MD 20852, USA. E-mail: andrea.gross@nih.gov

**How to cite this article:** Gross AM, Mahmood SZ, Dombi E, Miettinen M, Raffeld M, Dufek A, Patel S, Chittiboina P, Widemann BC. Challenges in determining the malignant potential of atypical neurofibromas (aNf) using histopathologic features and the potential need for *CDKN2A/2B* testing: a case report. *J Transl Genet Genom* 2024;8:207-15. <https://dx.doi.org/10.20517/jtgg.2024.02>

**Received:** 20 Jan 2024 **First Decision:** 26 Feb 2024 **Revised:** 22 Mar 2024 **Accepted:** 17 Apr 2024 **Published:** 22 Apr 2024

**Academic Editor:** Sanjay Gupta **Copy Editor:** Fangyuan Liu **Production Editor:** Fangyuan Liu

## Abstract

Atypical neurofibromas (aNf) are peripheral nerve sheath tumors (PNSTs) histologically defined by cytologic atypia, hypercellularity, loss of neurofibroma architecture, and/or increased mitotic activity. aNf often have a heterozygous loss of *CDKN2A/B* in addition to homozygous *NF1* loss. On MRI, aNf frequently appear as distinct nodular lesions, grow faster than plexiform neurofibromas, and have increased avidity on fluorodeoxyglucose positron emission tomography. At least some aNf are considered to be at greater risk for transformation to highly aggressive malignant PNSTs. We have observed that some PNSTs demonstrate a discrepancy between histological, clinical, and genomic criteria, where a PNST without histologically concerning findings may have clinical and imaging features concerning aNf and *CDKN2A/B* loss. This case series highlights this discrepancy and suggests the inclusion of *CDKN2A/B* loss to define aNf, along with clinical and imaging findings, to determine the potential for malignant transformation, and to select appropriate clinical management.

**Keywords:** Atypical neurofibroma, peripheral nerve sheath tumor, malignant peripheral nerve sheath tumor, neurofibromatosis type 1



© The Author(s) 2024. **Open Access** This article is licensed under a Creative Commons Attribution 4.0 International License (<https://creativecommons.org/licenses/by/4.0/>), which permits unrestricted use, sharing, adaptation, distribution and reproduction in any medium or format, for any purpose, even commercially, as long as you give appropriate credit to the original author(s) and the source, provide a link to the Creative Commons license, and indicate if changes were made.



## INTRODUCTION

Neurofibromatosis type 1 (NF1) is a genetic condition characterized by the development of peripheral nerve sheath tumors (PNSTs). PNSTs exhibit a spectrum of malignant potential<sup>[1]</sup>. On one end are histologically benign neurofibromas, including plexiform neurofibromas (pNF) that involve multiple branching nerve fascicles<sup>[2]</sup>. On the opposite end, malignant peripheral nerve sheath tumors (MPNSTs) are highly aggressive sarcomas that have a poor prognosis and are the leading cause of death in NF1<sup>[3]</sup>. Many MPNSTs develop from existing pNFs and transform through an intermediate pre-malignant tumor known as an atypical neurofibroma (aNf)<sup>[4]</sup>.

### Histologic definition of aNF

Histological features defining aNFs are cytologic atypia, hypercellularity, loss of neurofibroma architecture, and increased mitotic activity. A 2017 consensus review of the histologic definitions for aNFs defined a neurofibroma with increased cellularity alone as a cellular neurofibroma and a neurofibroma with cytologic atypia alone as a neurofibroma with atypia or an “ancient neurofibroma”<sup>[5]</sup>. In the case of both cellular neurofibromas and neurofibromas with atypia, the risk of progression to MPNST is unknown but considered to be low. In contrast, an “atypical neurofibromatous neoplasm with uncertain biologic potential” (ANNUBP) presents with cytologic atypia accompanied by hypercellularity, increased mitotic activity, and/or variable loss of neurofibroma architecture and does not yet meet criteria for an MPNST, but is considered to have an increased risk for malignant transformation<sup>[5]</sup> [Figure 1A-D]. An important potential challenge with histopathologic diagnosis of these tumors is that there is often significant intratumoral heterogeneity that may result in sampling error in the setting of a core biopsy. Therefore, for this case series, we only included tumors that were fully resected and therefore able to be more completely characterized.

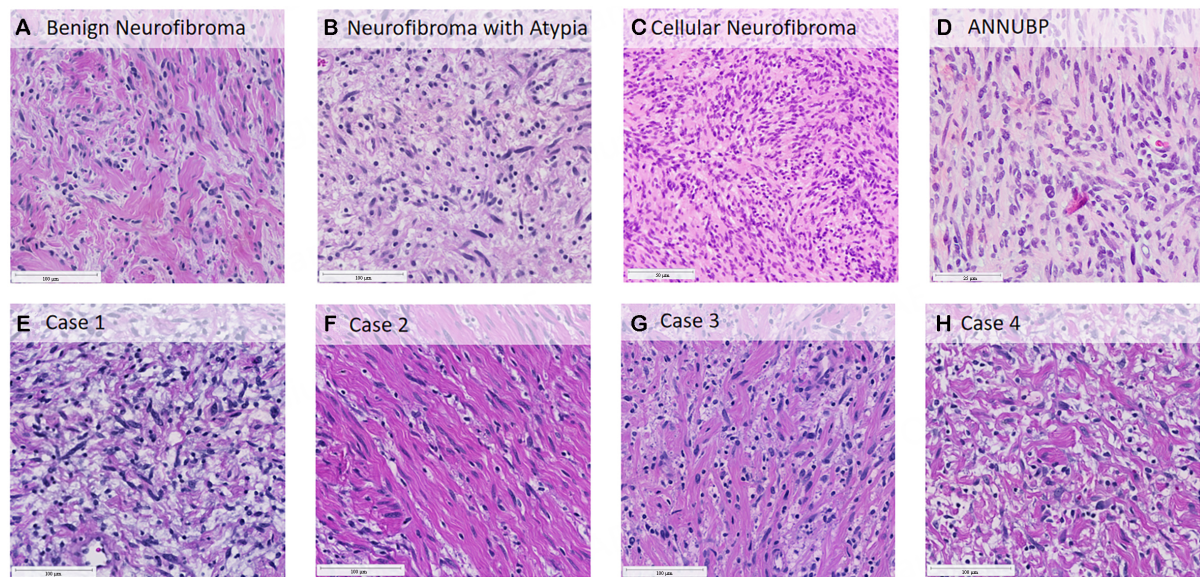
### Clinical and imaging characterization of aNF

Pain is the most frequent clinical symptom of aNF<sup>[4]</sup>. In addition, if the tumor is palpable, it may feel more firm than other neurofibromas.

On magnetic resonance imaging (MRI), aNF often appear as distinct nodular lesions (DNL), which are  $\geq 3$  cm in longest diameter, well-demarcated, and lack the central dot sign typical for pNF<sup>[6]</sup>. DNL tend to grow faster than pNF<sup>[7]</sup>. In contrast to pNF, which appear early in life, DNL typically present after early childhood and can develop and grow at any age<sup>[7]</sup>. A retrospective review of 76 histologically confirmed aNF in patients with NF1 described the imaging appearance of the majority of these lesions as DNL and confirmed the increased potential of aNF to transform into MPNST<sup>[4]</sup>. Although the terms DNL and aNF are sometimes used interchangeably, it is not yet known exactly what proportion of PNSTs that appear as DNL on imaging meet the histopathological definition of aNF, or how common atypical histological features are in tumors that have conventional pNF appearance on MRI.

On fluorodeoxyglucose positron emission tomography (FDG-PET), pNF have little or no tracer uptake, while DNL tend to have increased avidity<sup>[4,8]</sup>. Variable standard uptake values (SUV) have been suggested as a cut-off to distinguish benign, atypical, and malignant PNSTs, but due to the considerable overlap between these categories, the diagnostic accuracy is unsatisfactory<sup>[9]</sup>.

Another potential imaging biomarker for malignant transformation in PNST is diffusion weighted MRI (DWI). It provides a quantitative measure of the differences in the Brownian motion of water in tissue



**Figure 1.** Examples of various histopathologic types of peripheral nerve sheath tumors in NF1 as defined by Miettinen 2017<sup>[5]</sup> consensus review (A-D) and representative H&E slides from each clinical case (E-H). (A, B, E-H) at 5× magnification, (C) at 20×, (D) at 40×.

microstructures expressed as apparent diffusion coefficient (ADC)<sup>[10]</sup>. Cellular regions with low ADC levels ( $< 1.0 \times 10^{-3} \text{ mm}^2/\text{s}$ ) suggest a potentially concerning tumor<sup>[11]</sup>. In one study, the sensitivity and specificity of DWI to distinguish MPNST from benign PNST were 94% and 100%, respectively, which were similar or even better than FDG-PET<sup>[11,12]</sup>.

### Genomic characterization of aNF

Genomic sequencing and copy number analysis have shown that pNF possess low somatic mutation rates, stable chromosomal architecture, and intact *CDKN2A/B*<sup>[13,14]</sup>. In contrast, aNF frequently show heterozygous or homozygous loss of the tumor suppressor genes *CDKN2A/B*, which are likely drivers of the transition from a pNF to an MPNST<sup>[14-17]</sup>. *CDKN2A* homozygous loss has been described in many cancers<sup>[18]</sup>, and in NF1, there are significant pre-clinical data that suggest this loss may be a malignant driver. For example, in two mouse models, inactivation of the *Cdkn2a* locus, in addition to *Nf1* homozygous loss, leads to ANF and MPNST development<sup>[19,20]</sup>. A 2018 analysis by Carrio *et al.* looking at the histopathology and genomics of 8 PNSTs from patients with NF1 hypothesizes that monoallelic *CDKN2A/B* deletion may initiate ANF development, but that biallelic inactivation may be needed for ANNUBP formation<sup>[14]</sup>.

### Challenges in identifying aNF concerning malignant transformation

It is challenging to determine which NF1-associated PNSTs are at increased risk for malignant transformation. We have identified that some PNSTs with clinical and imaging features more consistent with pre-malignant aNF (rapid growth, DNL on MRI, increased FDG-PET avidity) have benign histologic findings consistent with a pNF or neurofibroma with atypia, rather than with an ANNUBP. However, genomic analysis identifies *CDKN2A/B* loss in these cases, which challenges the use of histologic criteria alone to define aNF and assess the risk of malignant transformation in PNST.

We present here four examples of such cases from participants with NF1, who enrolled and consented to an IRB-approved protocol at the National Cancer Institute (NCI) (NCT01109394), and had a PNST resected as part of their clinical care. Histopathology of tissue collected from resected tumors was reviewed by expert pathologists at the NIH. Molecular pathology was examined using the TruSight Oncology (TSO) 500 Gene

Panel (DNA) v3.0 and RNA Exome Fusion Panel<sup>[21]</sup>. The copy number of *CDKN2A/2B* was calculated using fold change provided by Illumina algorithm<sup>[22]</sup>. Clinical and imaging characteristics were collected retrospectively from patients' electronic medical records. [Table 1].

## CLINICAL CASES

### Case 1

Patient 1 is a 14-year-old biological female who was diagnosed with NF1 at 1 month old. The patient remained asymptomatic until 2 years old, when she complained of leg pain. An MRI performed at that time showed a large pNF of the pelvis arising from the lumbar spine (L4-L5) and extending to the left gluteal region, leg, and foot. The patient completed 9 months of treatment on a phase II study of pegylated-interferon alfa-2b (NCT00396019) but was ultimately removed due to tumor progression. At 4 years old, the patient was enrolled in a phase I trial of the MEK inhibitor selumetinib (NCT01362803). On selumetinib, she had a best overall response of -44.2% pNF volume reduction. However, three DNL developed and grew within the larger pNF while on selumetinib. The largest was 24 mL at the time of resection [Figure 2A and B]. This DNL was first noted when the patient was 9 years old, after approximately 5 years on selumetinib. DWI was obtained with minimum ADC 2.177, which is  $> 1.0 \times 10^{-3} \text{ mm}^2/\text{s}$  and therefore not by itself suggestive of restricted diffusion. However, due to continued rapid growth (average annualized growth rate of 147%), this tumor was resected with capsular margins [Figure 1E]. While histopathology of the tumor showed neurofibroma with no evidence of nuclear atypia, or other concerning features, DNA sequencing showed likely homozygous loss of both *CDKN2A* and *CDKN2B* [Table 2]. She remains on selumetinib, and two years post-resection, there has been no regrowth of this tumor.

### Case 2

Patient 2 is a 19-year-old male who was diagnosed with NF1 at 3 years old. At 8 years old, imaging revealed a pNF in the right pelvis/lower abdominal quadrant extending to the right inguinal/lumbosacral area. His pNF was growing slowly, and within the larger pNF, a DNL in the right lumbar paraspinal region was also growing [Figure 2C and D]. FDG-PET imaging collected when the patient was 10 years old showed a maximum SUV of 5.99 of the DNL. At 13 years old, the patient was enrolled in the phase II trial of selumetinib (NCT01362803). He had a confirmed partial response in his overall pNF, with a best response of -28.2% at approximately 2 years of treatment. However, the DNL, 53.4 mL when he started selumetinib, grew up to 115 mL (103% increase) over approximately 3.5 years, with an average annualized growth rate of 31%. Serial DWI was obtained with minimum ADCs of 1.307 and 1.626 on scans approximately 16 months apart, neither of which indicated significant concerns regarding restricted diffusion. The lesion was surgically resected when the patient was 16 years old due to continued growth [Figure 1F]. Histopathology of the lesion showed an intraneural neurofibroma with focal benign nuclear atypia. DNA sequencing revealed a pathogenic mutation in *CDKN2A* (*CDKN2A*, NM\_058195.4, c.193G>A, p.Gly65Ser) likely resulting in the loss of a functional allele [Table 2]. The patient resumed treatment with selumetinib post-operatively and has not experienced regrowth of the DNL during four years of follow-up.

### Case 3

Patient 3 is a 15-year-old male who was diagnosed with NF1 at 6 months old. At 2.5 years old, MRI confirmed a large left leg/hip pNF. Between 3 and 6 years old, he was treated in clinical trials of sirolimus (NCT00634270) and pegylated-interferon alfa 2b (NCT00396019), but both were discontinued due to tumor progression. At 8 years old, the patient was enrolled in the phase II trial of selumetinib (NCT01362803), with a best response of -39.4% after approximately 4.5 years of treatment. The patient underwent a left lower extremity amputation at 12 years old for recurrent poorly healing femur fractures. Following amputation, the patient experienced accelerated growth of a DNL within his larger left pelvic tumor, with an annual growth rate of 79% [Figure 2E and F], despite the continued response of his remaining overall pNF to

**Table 1. Patient and tumor characteristics**

	Case 1	Case 2	Case 3	Case 4
<b>Patient characteristics</b>				
Sex	F	M	M	M
Race	White	White	White	White
Ethnicity	Not Hispanic or Latino	Not Hispanic or Latino	Not Hispanic or Latino	Not Hispanic or Latino
Age at NF1 diagnosis (years)	0.1	3	0.5	0.4
Age when DNL first detected (years)	9.8	10.3	10.2	13.9
Age at DNL resection (years)	12.2	16	15	13.9
DNL-related pain reported prior to resection?	No	No	No	Yes
<b>MRI characteristics of DNL*</b>				
Morphology/internal structure	Fascicular/multi-nodular	Fascicular/multi-nodular	Fascicular/multi-nodular	Fascicular/multi-nodular
Depth	Deep	Deep	Deep	Deep
Relationship to adjacent tissues	Circumscribed	Circumscribed	Circumscribed	Circumscribed
DNL location relative to other tumors	Within surrounding PN	Adjacent to PN	Adjacent to PN	Within surrounding PN
Tumor volume at time of resection (mL)	24	115	36.3	28
% Volume increase in 1 year prior to resection (annualized)	147%	31%	79%	Unknown
Minimum ADC (DWI)	2.177	1.626	1.445	0.892
<b>FDG-PET characteristics</b>				
Max SUV on FDG-PET	NA	5.99	NA	4.2

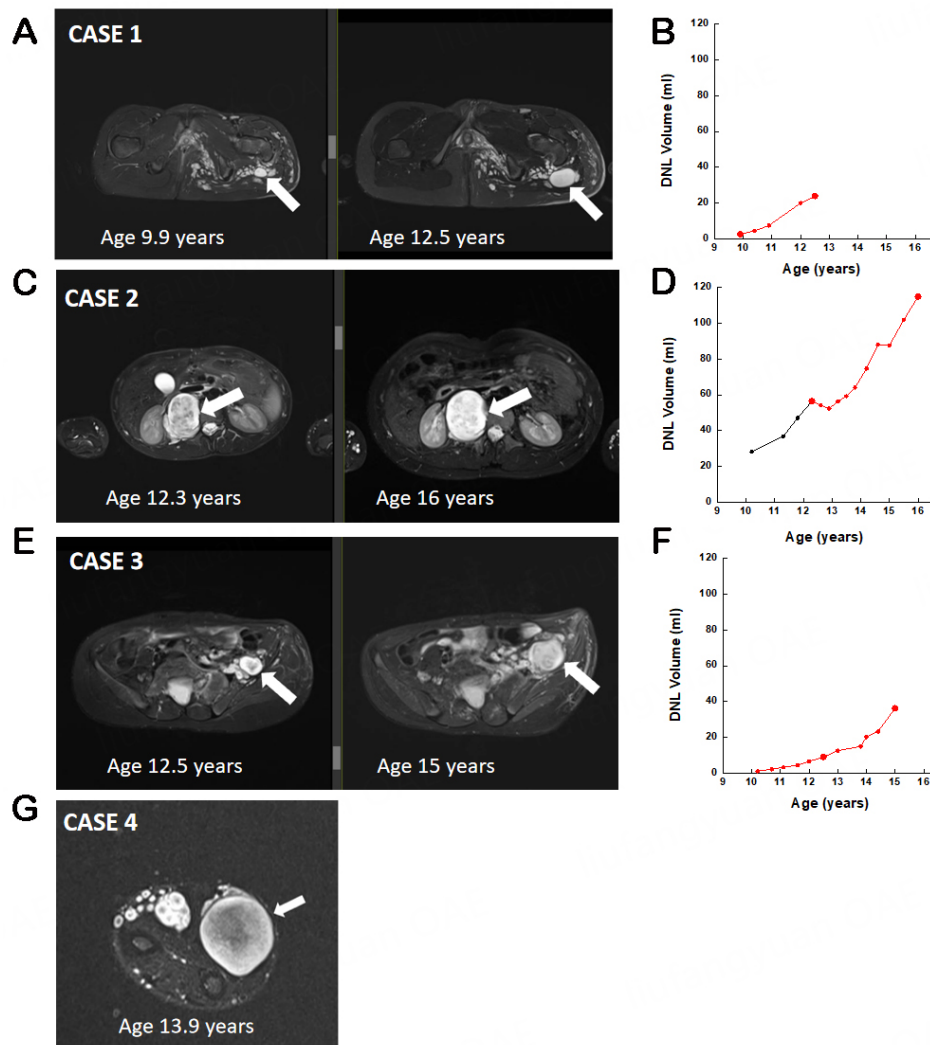
**Table 2. Tumor genomic and histopathologic results**

	Case 1	Case 2	Case 3	Case 4
<b>Molecular pathology</b>				
<i>CDKN2A</i> loss	Likely homozygous	Inactivating mutation in one allele	-	Likely homozygous
<i>CDKN2B</i> loss	Likely homozygous	-	Likely Heterozygous	Likely homozygous
<b>Histopathology</b>				
Nuclear atypia	-	Present	Present	Present
Hypercellularity	-	-	-	-
Loss of neurofibroma architecture	-	-	-	-
Increased mitotic rate	-	-	-	-
Necrosis	-	-	-	-

selumetinib. This prompted surgical resection of the DNL at 15 years old. Pathology of this lesion showed a pNF with only benign nuclear atypia [ [Figure 1G](#)], but molecular sequencing showed likely heterozygous loss of both *CDKN2A* and *CDKN2B*. Following surgery, the patient resumed selumetinib and has not had regrowth of the DNL during two years of follow-up.

#### Case 4

Patient 4 is a 15-year-old male who was diagnosed with NF1 as a newborn. His course was notable for an asymptomatic optic pathway glioma and an extensive pNF in the left brachial plexus, left chest/hemithorax, and spine. The patient underwent four debulking surgeries, but never received NF1-related medical treatments. At 12 years old, the patient noted a small painless nodule in his right distal forearm. After approximately ten months, the nodule visibly grew and became painful. The patient described his pain as up to 7/10 following activity or exertion. At 13 years old, imaging showed a 28 mL DNL adjacent to the right



**Figure 2.** MRI images and volume trends of resected tumors. Axial STIR MRI images show the evolution of the resected tumors (white arrows) up to the time of resection (A, C, E, G). Volume of each resected lesion over time where available (B, D, F). Symbols on the graphs correspond to imaging measurements, with the larger circles matching the MRI images provided on the left and the red color indicating selumetinib therapy. For case 4 (G), no longitudinal volumetric data are available. MRI: Magnetic Resonance imaging; STIR: short T1-inversion recovery.

ulna [Figure 2G]. He underwent surgical resection of the tumor and histopathology revealed mild nuclear atypia with a formal diagnosis of intraneural neurofibroma with benign nuclear atypia [Figure 1H]. Molecular pathology of the lesion revealed likely homozygous loss of both *CDKN2A* and *CDKN2B*. The patient is now approximately 2 years post-resection and continues to remain off any medical treatments and has not had clinical evidence of any regrowth of the DNL.

## DISCUSSION

Identifying which NF1 PNST is at increased risk for malignant transformation is of utmost importance, as parent nerve-sparing capsular marginal resection of these tumors is sufficient to prevent regrowth<sup>[23]</sup> and may prevent MPNST development. This is in contrast to established high-grade MPNST that require surgical resection with wide negative margins for potential cure. The risk of malignant transformation is currently assessed primarily using histopathological criteria, with ANNUBP considered to be the highest risk.

However, this case series illustrates that histopathology alone may be insufficient to define the potential of a PNST to transform into MPNST. In the four cases presented here, all had DNL that were clinically concerning due to rapid growth or pain, and several had imaging features such as increased  $SUV_{max}$  on FDG-PET scan and decreased ADC on DWI consistent with a tumor that may be at risk for malignant transformation. Despite complete resection allowing for full characterization of these heterogeneous tumors, all four had what is currently considered benign histopathology, with the only atypical feature present being scattered benign nuclear atypia in 3 of the 4 cases. None had hypercellularity, increased mitotic rate, or loss of neurofibroma architecture that would lead to the identification of an ANNUPB, according to current definitions. In contrast, molecular pathology demonstrated loss of *CDKN2A/B* (*CDKN2A* only in 1, *CDKN2B* only in 1, and *CDKN2A and B* both in 2) in all 4 cases [Table 2], which is considered a key step in the malignant transformation of pNF to MPNST<sup>[16]</sup>. Reassuringly, none of the tumors have recurred since resection, confirming the previously reported finding that DNL can be resected with capsular margins with a low risk for recurrence<sup>[23]</sup>.

In the cases presented here, the discrepancy between clinical features, which were consistent with a pre-malignant tumor, and histologic findings, which lacked significant atypia, suggests that histology alone may not be sufficient to define the malignant potential of PNST. One hypothesis is that the *CDKN2A/B* loss may precede the development of atypical histologic changes, even in the setting of clearly altered clinical behavior. Particularly in the presence of clinical concern, analysis of *CDKN2A/B* loss may thus complement the histologic analysis to define the malignant potential of a PNST and guide clinical management. In 2023, Mitchell *et al.* described a subset of benign-appearing neurofibromas in people with NF1, initially described as pNF or neurofibromas with atypia, that ultimately showed patterns of gene expression more consistent with MPNST. This finding, in combination with similar data seen at the level of mouse models of ANNUPB, where  $\geq 50\%$  of tumors maintain their benign plexiform-like appearance despite having loss of both *Nf1* and *Cdkn2a* genes<sup>[19,20,24]</sup>, further supports the argument in favor of incorporating molecular information into the standard characterization of individual neurofibromas.

One limitation of this series is that the PNSTs were resected and therefore it is unknown if they would have transformed into MPNST. However, to date, clinical features of increased PNST growth rate, diffusion restriction, increased pain, and increased  $SUV_{max}$  on FDG-PET are indicators of potential PNST malignant transformation, and therefore, the presence of these features should raise concern for malignant transformation even when histopathology is benign. Another important limitation to consider is that regardless of which gene panel technique is employed, there is always the possibility that certain inactivations or translocations of *CDKN2A/B* may be difficult to detect using standardized panels. Therefore, there may have been additional *CDKN2A/B* alterations that were missed.

If the goal of defining aNF is to identify tumors that are at increased risk for malignant transformation, a combination of clinical, imaging, pathologic, and genetic changes, and long-term patient follow-up will likely be needed to establish this definition. Importantly, based on our cases, histopathology alone may not be adequate to rule out increased risk for malignant transformation. Additional assessment for *CDKN2A/B* loss in clinically concerning tumors should be considered for a more complete risk assessment. As interventional clinical trials for aNF are ongoing and in development, the question also arises about how to determine eligibility and whether tumors with *CDKN2A/B* loss should be considered eligible despite benign appearing histology. Prospective studies including a larger number of PNST with fully characterized imaging, histopathologic and genetic findings, and long-term patient follow-up will be needed to better define which PNSTs are at risk for malignant transformation.

## DECLARATIONS

### Authors' contributions

Conceptualized this case series and wrote the initial draft of the manuscript: Gross AM, Mahmood SZ, Widemann BC

Performed volumetric MRI measurements, provided imaging for figures, and contributed to manuscript content: Dombi E

Provided imaging and clinical information for figures and reviewed and approved the manuscript: Patel S, Dufek A, Chittiboina P

Reviewed pathology results and contributed to the manuscript content: Miettinen M

Reviewed genetic testing results and contributed to the manuscript content: Raffeld M

### Availability of data and materials

Not applicable

### Financial support and sponsorship

None.

### Conflicts of interest

All authors declared that there are no conflicts of interest.

### Ethical approval and consent to participate

All the participants presented in this case series were enrolled under the National Institutes of Health Institutional Review Board (IRB) Approved protocol 10-C-0086, "Comprehensive Omics Analysis of Pediatric Solid Tumors and Establishment of a Repository for Related Biological Studies".

### Consent for publication

Written consent for their case to be included in this publication was obtained from each of the participants or their parent/legal guardian.

### Copyright

© The Author(s) 2024.

## REFERENCES

1. Bernthal NM, Putnam A, Jones KB, Viskochil D, Randall RL. The effect of surgical margins on outcomes for low grade MPNSTs and atypical neurofibroma. *J Surg Oncol* 2014;110:813-6. [DOI](#) [PubMed](#)
2. Fisher MJ, Blakeley JO, Weiss BD, et al. Management of neurofibromatosis type 1-associated plexiform neurofibromas. *Neuro Oncol* 2022;24:1827-44. [DOI](#) [PubMed](#) [PMC](#)
3. Kim A, Stewart DR, Reilly KM, Viskochil D, Miettinen MM, Widemann BC. Malignant peripheral nerve sheath tumors state of the science: leveraging clinical and biological insights into effective therapies. *Sarcoma* 2017;2017:7429697. [DOI](#) [PubMed](#) [PMC](#)
4. Higham CS, Dombi E, Rogiers A, et al. The characteristics of 76 atypical neurofibromas as precursors to neurofibromatosis 1 associated malignant peripheral nerve sheath tumors. *Neuro Oncol* 2018;20:818-25. [DOI](#) [PubMed](#) [PMC](#)
5. Miettinen MM, Antonescu CR, Fletcher CDM, et al. Histopathologic evaluation of atypical neurofibromatous tumors and their transformation into malignant peripheral nerve sheath tumor in patients with neurofibromatosis 1-a consensus overview. *Hum Pathol* 2017;67:1-10. [DOI](#) [PubMed](#) [PMC](#)
6. Meany H, Dombi E, Reynolds J, et al. 18-fluorodeoxyglucose-positron emission tomography (FDG-PET) evaluation of nodular lesions in patients with Neurofibromatosis type 1 and plexiform neurofibromas (PN) or malignant peripheral nerve sheath tumors (MPNST). *Pediatr Blood Cancer* 2013;60:59-64. [DOI](#) [PubMed](#) [PMC](#)
7. Akshintala S, Baldwin A, Liewehr DJ, et al. Longitudinal evaluation of peripheral nerve sheath tumors in neurofibromatosis type 1: growth analysis of plexiform neurofibromas and distinct nodular lesions. *Neuro Oncol* 2020;22:1368-78. [DOI](#) [PubMed](#) [PMC](#)



8. Meany H, Widemann BC, Ratner N. Malignant peripheral nerve sheath tumors: prognostic and diagnostic markers and therapeutic targets. In: Upadhyaya M, Cooper DN, editors. Neurofibromatosis type 1. Berlin: Springer Berlin Heidelberg; 2012. pp. 445-67. DOI
9. Warbey VS, Ferner RE, Dunn JT, Calonje E, O'Doherty MJ. [<sup>18</sup>F]FDG PET/CT in the diagnosis of malignant peripheral nerve sheath tumours in neurofibromatosis type-1. *Eur J Nucl Med Mol Imaging* 2009;36:751-7. DOI
10. Baliyan V, Das CJ, Sharma R, Gupta AK. Diffusion weighted imaging: technique and applications. *World J Radiol* 2016;8:785-98. DOI PubMed PMC
11. Ahlawat S, Blakeley JO, Rodriguez FJ, Fayad LM. Imaging biomarkers for malignant peripheral nerve sheath tumors in neurofibromatosis type 1. *Neurology* 2019;93:e1076-84. DOI PubMed
12. Koike H, Nishida Y, Ito S, et al. Diffusion-weighted magnetic resonance imaging improves the accuracy of differentiation of benign from malignant peripheral nerve sheath tumors. *World Neurosurg* 2022;157:e207-14. DOI
13. Pemov A, Hansen NF, Sindiri S, et al. Low mutation burden and frequent loss of CDKN2A/B and SMARCA2, but not PRC2, define premalignant neurofibromatosis type 1-associated atypical neurofibromas. *Neuro Oncol* 2019;21:981-92. DOI PubMed PMC
14. Carrió M, Gel B, Terribas E, et al. Analysis of intratumor heterogeneity in Neurofibromatosis type 1 plexiform neurofibromas and neurofibromas with atypical features: correlating histological and genomic findings. *Hum Mutat* 2018;39:1112-25. DOI
15. Beert E, Brems H, Daniëls B, et al. Atypical neurofibromas in neurofibromatosis type 1 are premalignant tumors. *Gene Chromosome Canc* 2011;50:1021-32. DOI
16. Zhang X, Murray B, Mo G, Shern JF. The role of polycomb repressive complex in malignant peripheral nerve sheath tumor. *Genes* 2020;11:287. DOI PubMed PMC
17. Magallón-Lorenz M, Fernández-Rodríguez J, Terribas E, et al. Chromosomal translocations inactivating CDKN2A support a single path for malignant peripheral nerve sheath tumor initiation. *Hum Genet* 2021;140:1241-52. DOI
18. Hamid A, Petreaca B, Petreaca R. Frequent homozygous deletions of the CDKN2A locus in somatic cancer tissues. *Mutat Res* 2019;815:30-40. DOI PubMed PMC
19. Rhodes SD, He Y, Smith A, et al. Cdkn2a (Arf) loss drives NF1-associated atypical neurofibroma and malignant transformation. *Hum Mol Genet* 2019;28:2752-62. DOI PubMed PMC
20. Chaney KE, Perrino MR, Kershner LJ, et al. Cdkn2a loss in a model of neurofibroma demonstrates stepwise tumor progression to atypical neurofibroma and MPNST. *Cancer Res* 2020;80:4720-30. DOI PubMed PMC
21. Zhao C, Jiang T, Hyun Ju J, et al. TruSight oncology 500: enabling comprehensive genomic profiling and biomarker reporting with targeted sequencing. *bioRxiv* 2020. DOI
22. Illumina I. Tumor purity and fold change. 2021. Available from: [https://support-docs.illumina.com/SW/DRAGEN\\_v39/Content/SW/DRAGEN/SomaticWESCNV\\_TumorPurity.htm](https://support-docs.illumina.com/SW/DRAGEN_v39/Content/SW/DRAGEN/SomaticWESCNV_TumorPurity.htm) [Last accessed on 22 Apr 2024].
23. Nelson CN, Dombi E, Rosenblum JS, et al. Safe marginal resection of atypical neurofibromas in neurofibromatosis type 1. *J Neurosurg* 2019;133:1516-26. DOI PubMed PMC
24. Mitchell DK, Burgess B, White E, et al. Spatial gene expression profiling unveils immuno-oncogenic programs of NF1-associated peripheral nerve sheath tumor progression. *Clin Cancer Res* 2024;30:1038-53. DOI PubMed