

Review

Open Access



Medical nose reshaping: current evidence behind techniques

Alberto Diaspro¹, Alessio Redaelli², Yves Saban³, Constantin Sulamanidze⁴, Michele Pascali⁵, Dario Bertossi⁶

¹Department of Maxillofacial Surgery, Rigeneralab Centre for Regenerative Medicine, Turin 10134, Italy.

²Visiting Professor, Genova University, Private Practice, Milan 20100, Italy.

³Department of Ear Nose and Throat and Maxillofacial Surgery, Private Practice, Nice 06100, France.

⁴Department of Plastic and Reconstructive Surgery, Total Charm Clinic of Plastic and Aesthetic Surgery, Tbilisi 0105, Georgia.

⁵Department of Plastic and Reconstructive Surgery, Plastic Surgery Academy, Rome 00198, Italy.

⁶Department of Maxillofacial Surgery, University of Verona, Verona 37121, Italy.

Correspondence to: Dr. Alberto Diaspro, Department of Maxillofacial Surgery, Rigeneralab Centre for Regenerative Medicine, Corso Unione Sovietica 159/a, Turin 10134, Italy. E-mail: info@albertodiaspro.com

How to cite this article: Diaspro A, Redaelli A, Saban Y, Sulamanidze C, Pascali M, Bertossi D. Medical nose reshaping: current evidence behind techniques. *Plast Aesthet Res* 2023;10:28. <https://dx.doi.org/10.20517/2347-9264.2022.131>

Received: 13 Nov 2022 **First Decision:** 30 Mar 2023 **Revised:** 3 May 2023 **Accepted:** 5 Jun 2023 **Published:** 12 Jun 2023

Academic Editor: Raffaele Rauso **Copy Editor:** Yanbing Bai **Production Editor:** Yanbing Bai

Abstract

The nose, centrally located on the face, plays a crucial role in facial aesthetics. Any imbalance in its length, width, tip position, or a gross deformity, such as dorsal hump and deviation, can significantly affect the overall facial harmony, which is thus a major concern for patients. When it comes to minor deformities, they have been treated with hyaluronic acid, toxin injection, and thread insertion since 2005. This study has originally been carried out to review the published medical literature on the non-surgical techniques for Medical Nose Reshaping (MNR): a PubMed search was carried out in December 2020 using the search terms: "Nose [and] filler", "Nose [and] botulinum toxin" and "Nose [and] thread". A large number of studies were identified and reviewed, and it was found that rhinoplasty remains the gold standard to correct nose defects; nevertheless, MNR is gaining popularity due to its minimal invasiveness, short downtime, and the market availability of different injectables, toxins, and threads. This study aims to provide an evidence-based approach to guide the use of non-surgical techniques for MNR by reviewing published medical literature and drawing on the authors' experience.

Keywords: Nose, medical, non-surgical, filler, threads, toxin



© The Author(s) 2023. **Open Access** This article is licensed under a Creative Commons Attribution 4.0 International License (<https://creativecommons.org/licenses/by/4.0/>), which permits unrestricted use, sharing, adaptation, distribution and reproduction in any medium or format, for any purpose, even commercially, as long as you give appropriate credit to the original author(s) and the source, provide a link to the Creative Commons license, and indicate if changes were made.



INTRODUCTION

Because the nose is centrally located within the face, it is crucial to assess its aesthetic features, as any imbalance in length, width, tip position, or a gross deformity - such as dorsal hump and deviation - can easily affect the entire facial harmony and therefore be of major concern for patients.

When it comes to minor deformities, the so-called "non-surgical or liquid rhinoplasty" offers an option for patients who prefer to avoid or are not eligible for surgery under general anesthesia. Although the results are temporary, this technique allows for addressing such deformities. After the first report on this procedure (using a resin for dental restoration in 1953)^[1], injectable silicone use has also been reported^[2].

Several authors subsequently published more papers about the use of calcium hydroxyapatite^[3], freeze-dried acellular cadaveric dermis^[4], hyaluronic acid and botulinum toxin^[5], poly-methyl-methacrylate^[6] and bovine collagen^[7].

Autologous fat then started to be used as an ancillary procedure in addition to surgical rhinoplasty^[8], but is now also used as an outpatient filling technique^[9,10].

As in surgical rhinoplasty, the tri-dimensional reshaping may be done by means of grafts^[11-13], and even when using injectables, treatment plans must be made and injections performed according to the same rules^[14].

The debate about indications, techniques, and the best material to be injected is still open, and regardless of the product used, achievable results are obtained just by mere volume addition.

As for surgical procedures, sound knowledge of nasal anatomy - both structural and vascular - is required, and even more so when a nasal injection is to be performed, regardless of the material to be injected.

The most common complications are unfortunate and harmful for both patient and doctor, as the greatest concern in injectable nose reshaping is intravascular product injection^[15,16].

Brain infarction, blindness, and skin necrosis have been reported with all available products and even after autologous fat injection^[17-20].

After a 2010 paper presented a minimally invasive procedure for the correction of nasal tip deformities in carefully selected patients, many authors began to consider threads as a valid alternative for performing medical nose jobs in response to the increasing incidence of the mentioned complications^[21].

Sutures have always been part of standardized rhinoplasties to reshape, project, and rotate the nasal tip area^[22,23], and in the last few years, threads, commonly used in cosmetic fields, were then being adopted as an alternative tool to injectables and toxins, for nose reshaping^[24-26].

As long as non-surgical procedures, even when performed under local anesthesia, do not jeopardize the key anatomic structures of the nose, they can be adopted in properly selected patients as a simple method to carry out nose reshaping. Moreover, not every patient requires all of the steps of surgical rhinoplasty in order to see his or her concerns addressed, and both selected nose deformities and nasal aging can be dealt with very easily, safely, and quickly.

The reversibility of the result, at least for a short period of time, is also appealing to patients who are uncertain about the real outcome of nasal surgery.

This study has originally been carried out to review the published medical literature on the non-surgical techniques for Medical Nose Reshaping (MNR) so as to provide an approach based on available evidence and the authors' experience.

DATA COLLECTION

PubMed research for “Nose [and] filler”, “Nose [and] botulinum toxin” and “Nose [and] thread” retrieved a total amount of 101 articles, starting from 1975 to 2020.

Results were limited to human subjects in clinical trials, randomized controlled trials, case reports, comparative studies, controlled clinical trials, and multi-center studies.

No limit based on the year or language of publication was applied.

A manual review of abstracts was also performed to omit unrelated articles.

Details of the database search are listed in [Figure 1](#). Without considering the first two references (edited in 1953 and 1986) at the end of this paper, there has been an increasing number of publications about ‘medical nose reshaping’ since 2005. The results, therefore, include 99 articles from 2005 to 2020.

DATA DISTRIBUTION

Study type

Twenty-two articles were prospective studies, 49 were retrospective, and 28 were not mentioned.

Among all the published papers, only one RCT study^[27] is currently available about nose reshaping (plunging tip) with botulinum toxin. A total of 12 review articles have been written, the first in 2009^[28], then in 2013^[29], in 2014^[30], and furthermore from 2016 to 2019^[31-39].

Additionally, among all papers related to complications, 6 include a review too, the first published in 2009^[40], then another in 2014^[41], one in 2018^[42], and the last one in 2019^[43-45].

The remainder is case series or case reports [[Figure 2](#)].

Topic: anatomy

Seven papers were published about anatomical topics [[Figure 3](#)]: interestingly enough, except for the ones published by Saban *et al.* in 2008^[46] and 2012^[47], the other five published from 2016 to 2019 were mostly directed at applying anatomy notions in order to avoid complications or to perform some particular technique disclosed within the paper^[48-52].

Topic: techniques

Since 2005, there has been an increase in articles that focused on new or personal techniques. The first described the use of botulinum toxin^[53,54] and hyaluronic acid^[55], whilst in 2007 the first nose reshaping done with collagen^[56] and fat^[8] have been presented. In 2008 Redaelli published the first comprehensive paper about the use of hyaluronic acid and botulinum toxin for nose reshaping^[5]; furthermore, polylactic acid, polyacrylamide, and tricalcium phosphate injection have been reported^[57,58].

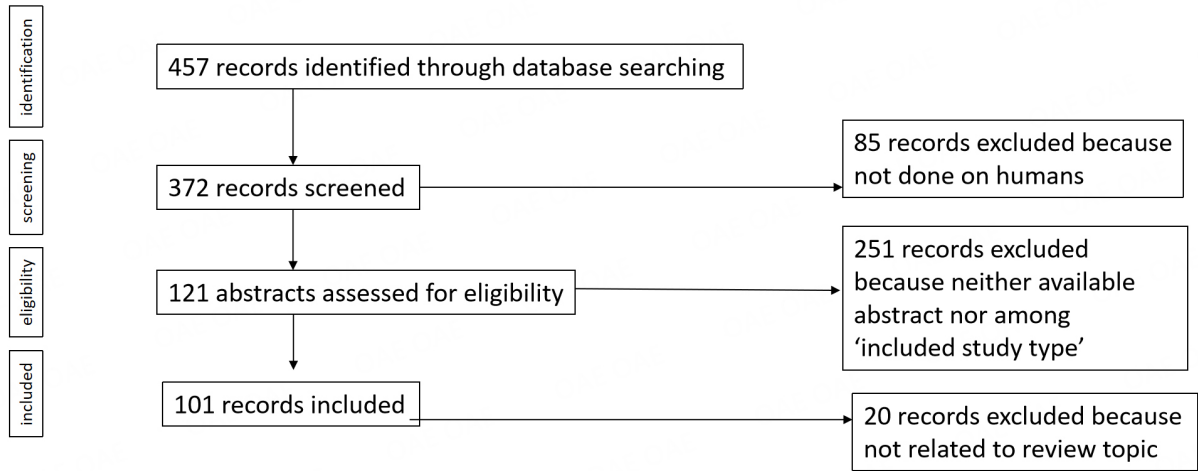


Figure 1. Flow diagram of the search strategy.

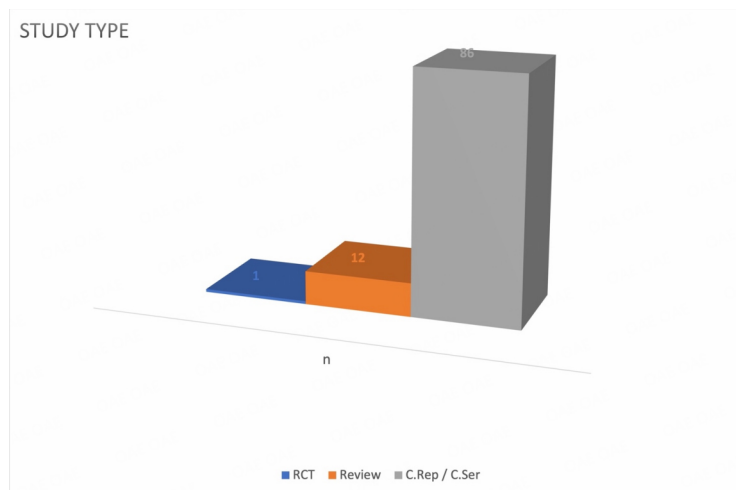


Figure 2. Retrieved articles: study type. RCT: Randomized Controlled Trial; Review: Narrative Review; C.Ser: Case Serie; C.Rep: Case Report.

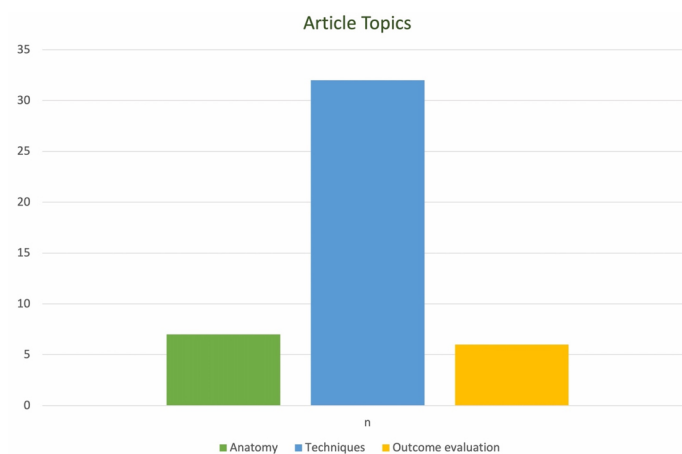

Figure 3. Articles distribution: treated topic.

In 2010 the first nose job done by threads was presented^[21] as an office-based procedure to correct selected flaws. This procedure cannot be considered by all means as non-surgical because of the procedural steps and the required skills to perform them.

Since 2010, several Authors have kept on publishing about nose reshaping until the present day, sharing their personal approaches and experience over the years through case reports and case series^[59-67].

In 2018, a paper related to the thread nose job method was published^[26], several years after the first article ever mentioning this topic.

In 2019, the use of carboxymethylcellulose was first reported^[68] as a submucosal injection to improve upper airway aerodynamics in a patient affected by 'empty nose syndrome', since Redaelli *et al.* first published in 2012^[59] about hyaluronic acid injected to functionally improve external nasal valve, normally performed only via surgical insertion of cartilage grafts on the alar rim^[69].

The rest of the published papers, even if in the form of case series, began to present injectable nose reshaping as a technique based on the principles of previously-existing surgical techniques - as opposed to techniques based on personal experience and anatomy only - in order to improve results, safety, and reliability^[14,70-74].

Nose thread lifting techniques are further presented with their related complications^[25,75] [Figure 3].

Topic: outcome evaluation

Since 2015, papers on objective and validated measurements of achievable results of non-surgical nose reshaping have started to be published constantly, once a year, ranging from anthropometric points evaluation^[76-77] to the use of software^[78,79].

The first ever medical nose reshaping satisfaction paper was published in 2015^[80] and the only one published after that date was in 2020^[81] [Figure 3].

Topic: agents

Out of the 37 published related to hyaluronic acid injections, 7 papers were published with a focus on injected materials: in 2007 and 2014 related to fat^[82,83], in 2009 about CaOH^[81] and collagen^[7], PMMA^[84] and polyacrylamide^[85] injection, and in 2019 about autologous fluid cartilage^[86], which can be harvested and used in the operating room like any other cartilage in order to refine surgical rhinoplasty^[87] [Figure 4].

Injectable fillers have been precisely mentioned in 75 papers from 2006 to 2020: 14 reporting CaOH use, 1 fluid cartilage, 1 carboxymethylcellulose, 2 collagen, 1 Acrylamide (Dermalive) 7 fat, 1 Polyamide, 1 polymethylmethacrylate, 1 silicone, and the last 8 the combined use of the mentioned injectables.

Toxin was referred to in 9 papers, 5 from 2005 to 2010, 3 in 2012-13, the last 1 in 2018; 4 alone^[27,53-54,60] while 4 in association with fillers^[5,58-59,61], and 1 in association with fillers and threads^[24].

Threads were used in 7 papers, the first in 2010, 2 in 2013-14, and then 4 in 2017-20; 4 used alone^[21,26,75,88], 2 in association with fillers^[25,65], and 1 in association with fillers and botulinum toxin^[24].

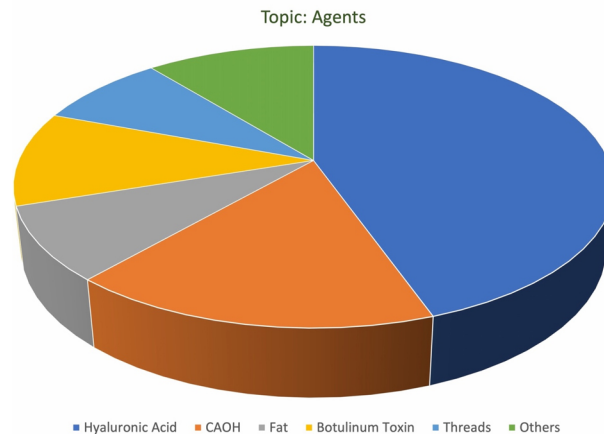


Figure 4. Articles distribution: injected agent.

In particular, the work published in 2014 by Saban *et al.* was the first one related to the functional treatment of the nasal valve with threads. Finally, 25 articles did not indicate the used material^[88].

Topic: complications

Complications-related papers have been published since 2008^[89,90], and for the next six years, their presence has been constant but minimal in 2009^[40], 2010^[91,92], 2011^[93-95], 2013^[15,96,97], 2014^[18,41,98-100] until a first rise in 2015 when five papers were published^[20,101-104].

There was a renewed focus in 2018 and 2019, with seven^[42,105-109] and seven^[43-45,110-112] published papers, respectively, after two years of low interest in 2016^[16,113-115] and 2017^[19,116,117] [Figure 5].

There is only one systematic review to be found^[45], while the others are case series or case reports and three do not mention the sample size of cases.

While non-vascular complications are the minority - mainly granulomatous reaction^[91], dermatomyositis^[110], mass formation, and migration^[89,114] - the reported complications are most commonly vascular, as reported in 27 papers: neuro-ophthalmologic complications such as brain infarction^[16,18,104,111], blindness^[43,45,96,100,106,118] and ophthalmoplegia^[102] (sometimes together), overall slightly exceeding cutaneous complications such as skin necrosis^[20,40,41,90,95,97,103,109] [Figures 6 and 7].

It is remarkable that neither botulinum toxin-related complications nor thread-related complications have been reported until today. However, there is one published paper focused on thread lifting complications on the nose, but those were due to some previously implanted prosthetic material and therefore cannot be accounted for as the root cause issue^[75].

Among the most reported materials associated with post-injection adverse events in the currently available literature, 14 papers refer to complications with HA alone^[16,18-20,80,93,94,97,107-109,114-116], while 8 reported complications encountered when injecting CaOH alone^[41,80,89,92,102,105,106,113].

Nose reshaping by fat is reported to present with complications in 2 articles^[17,45] and the remaining 12 articles generically report complications associated with “dermal fillers”^[15,40-42,83,86,90,95,96,99,100,109].

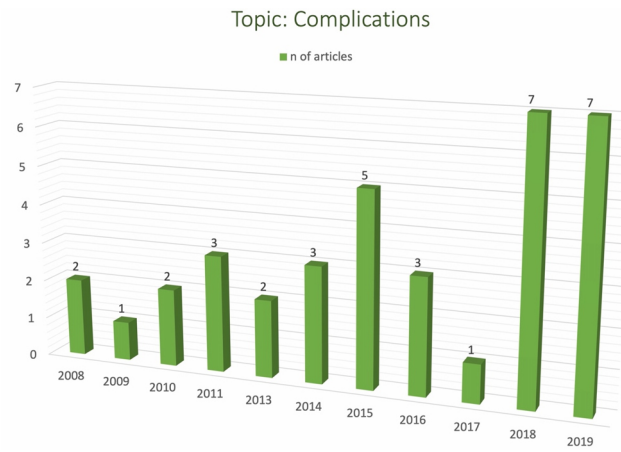


Figure 5. Complications-related articles: publication trend.

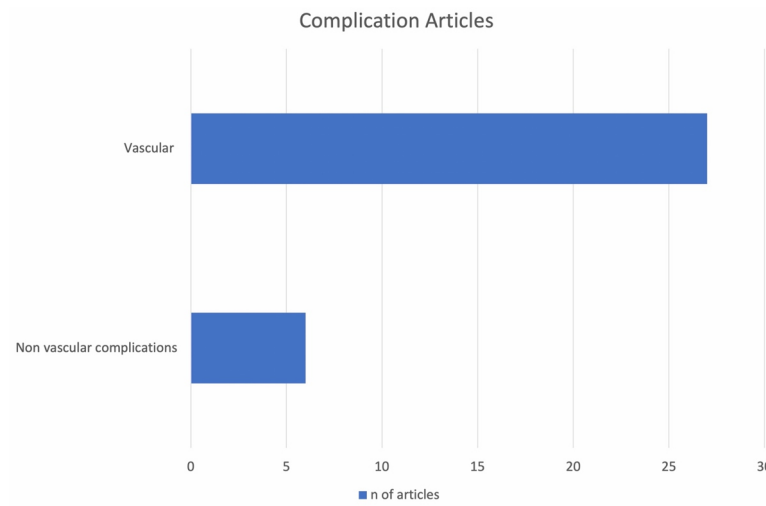


Figure 6. Complications-related articles: types of complication.

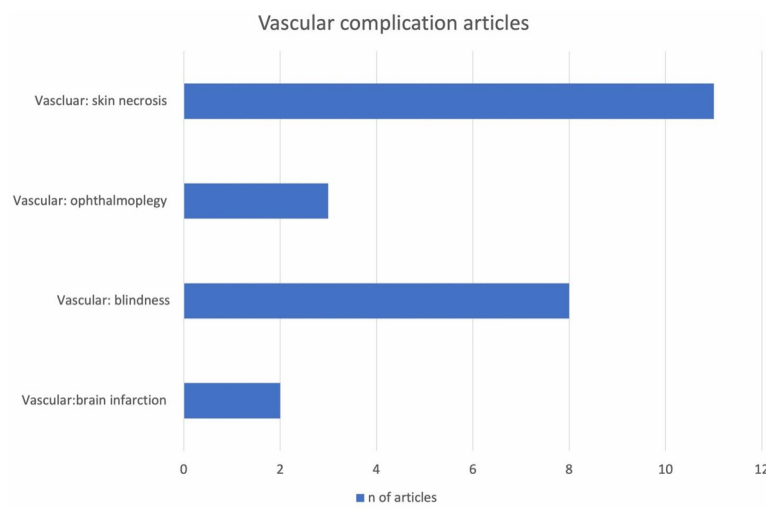


Figure 7. Vascular complications-related articles: types of complication.

Complications due to collagen^[103], acrylamide^[101], and silicone^[110] injections are poorly mentioned since these materials are no longer employed.

DATA REVISION

Starting from 2005 to 2010, Medical Nose Reshaping techniques that have been presented are: injecting botulinum toxin by Dayan^[53] and Redaelli^[5], grafting some adipose tissue by Cárdenas^[8], injecting hyaluronic acid by Beer^[55] and Redaelli^[5], collagen by De Lacerda^[56] and using other injectables by Rokhsar^[57], Braccini^[58] and Siclovan^[81], and finally by Tiryaki^[21] inserting threads.

Great efforts have been made in the following years to define safe and reliable techniques aimed at minimizing vascular risks, which still must be considered as an inner characteristic of every filler injection, but unfortunately extremely significant when treating nose deformities.

The majority of the literature has been written by Authors who published from 2010 up to 2019 about their personal methods, accompanied with complication-related papers in the same time interval. It is true to say that despite a thoughtful choice of materials, solid anatomical knowledge, and the use of a reliable technique, complications are more likely to occur when it is the nose that is being treated.

Regardless of the chosen method, sound knowledge of anatomy is essential for nasal reshaping. It is recommended to consult the paper by Saban *et al.* published in 2012^[47] about the medical and surgical application of nasal arterial vascular system, along with the previous study focused on the nasal superficial musculoaponeurotic system^[46]. These papers provide comprehensive details about the layers of nasal envelope, which can greatly benefit those undertaking MNR.

Thereafter, the interest toward that topic in nose reshaping dropped until 2016^[47], when there was a renewed focus on nasal vascular anatomy, driven by the upward trend of injection-related complications published since 2010^[48,49] and it kept steady in the following years.

The external nose blood supply is an anastomotic system supplied by branches of the ophthalmic and facial arteries presenting with many anatomic variations from patient to patient and even from one side to the opposite within the same patient. It lies within or above the mentioned Superficial Muscle-Aponeurotic layer along with the lymphatic net: starting cephalad from the internal carotid system, the dorsal nasal artery arises directly from the ophthalmic and runs over the nasal bones under the SMAS plane at the nasal root and then gradually gets more superficial as it runs down towards the tip and the external nasal artery, rising from the anterior ethmoid artery is the other major vessel of the upper part of the nose.

The lateral nasal artery is a branch of the facial artery; rising from the external carotid system, it proceeds medially above the alar groove to meet the columellar artery: they supply the alar wings and, together with the dorsal one, the nose tip as an arcade along the cephalic margin of the lateral crura. The columellar artery is a terminal branch of the superior labial artery that supplies the base of the nose. Although they are located above the muscle layer, small perforating vessels branch off to the lateral and dorsal nasal arteries running between the SMAS and the cartilaginous or bony surfaces.

This vascular anatomy, therefore, provides several anastomoses: the ones with the internal carotid system, which in case of retrograde embolism can result in brain infarction and blindness, whereas the ones with the external system lead to a geographic pattern of vascular imbalance which may result in skin necrosis, due to either direct embolization or to compression from product excess or soft tissue edema.

The anatomical structures involved must be evaluated with the objective of safety and efficiency, as for every surgical or non-surgical procedure on the face, encompassing all layers of the nasal superficial soft tissue envelope, from the surface down the skin, the subcutaneous tissue, the SMAS, the deep fat or so-called areolar layer, and finally perichondrium or periosteum.

It is mainly the nasal vessels and the nasal SMAS layer that must be considered when reshaping with injectables. Most of the arterial vasculature runs superficial to the nasal SMAS, while the deepest layers are almost vessels-free; therefore, the injections should be performed within the avascular plane, at the bony-cartilaginous contact. Regarding threads: the anatomic layers to use are conversely deeper; therefore, it is the SMAS that acts as the main layer, and nasal ligaments may represent an adequate structure for anchoring the threads to mobilize the malleable cartilages and attach their new position.

Nose deformities have been addressed with medical camouflage with fillers or botulinum toxin since the very first attempts^[3,4,8,53,54], but it is only after three years that a comprehensive approach has been codified by Redaelli A^[5].

Nowadays. Botulinum toxin injection allows to treat:

- Dynamic tip ptosis;
- Excessive columellar show.

The first is secondary to the action of an overactive and hyperactive depressor septi nasi muscle - its weakening rotates the tip upward and opens the nasolabial angle, while the latter is due to hyperactivity of the medial portion of the levator labii superioris alaeque Nasi, which can be chemo-denervated too.

By studying the published literature, nasal flaws to be addressed for reshaping with injectables are:

- Narrow naso-frontal angle;
- Mild to moderate dorsal hump;
- Dorsal concavity or shallow dorsum (Saddle nose);
- Contour irregularities or asymmetries (Crooked nose);
- Polly-beak deformity;
- Decreased tip projection or rotation;
- Alar base deficiency and other alar rim irregularities;
- Narrow naso-labial angle;
- Minor asymmetries or irregularities after primary rhinoplasty;

- External Nasal valve functional problem.

Given the additive nature of this camouflaging technique, proper patient selection must be carried out as the treatment of large, wide, and over-projected noses is contraindicated or may present with poor results.

Hyaluronic acid is injected gently and slowly using a needle with vertical inclination to decrease its subdermal course and prevent vessel injury, or through a cannula with the tip located deep to the nasal SMAS.

For dorsum deformities, it is recommended to inject above as well as below the lowest point in order to properly shape the dorsal hump.

Lateral deviations are treated with the same approach: in the mentioned sites, the additive approach is adopted to obtain camouflage of nasal defects.

While dorsum injection always enables indirect tip rotation due to skin envelope traction, direct tip treatment can widen the nasolabial angle too, and it is carried out by injecting the inferior border of the nasal spine, which supports the tip and weakens the depressor muscle through the elongation, thus resulting in pleasing tip rotation.

Whenever aimed at defining tip morphology, injectables are used as a shield graft to blunt the supratip break or to round the tip, by injecting the lateral dome.

Correction of post-surgical deformities requires further attention. Due to the vascular anatomy alterations and the inner feature of the remaining scar tissue, minimal injections of products and adequate waiting time after the surgical intervention are both mandatory^[3,8,14,119].

The above-mentioned techniques are nowadays mostly used for nose reshaping with hyaluronic acid and calcium hydroxyapatite, both capable of achieving a temporary camouflage of the addressed deformities.

When selecting the most suited material to be injected for nose reshaping, careful consideration must be given to its rheological and non-rheological properties. The first refers to the material's ability to exhibit characteristics of both a solid and a liquid, which are measured by the elastic coefficient G' (resistance to deformation) and the viscosity n^* (ability to withstand shear force), respectively.

High G' material is generally a performant filler, but may be stiffer, thus inducing greater trauma and inflammation upon injection. It is more likely to cause inflammation, edema, and even lumpiness when injected into thin-skinned noses.

Lower G' material has a more natural effect, but may be unable to withstand tissue deformation at injection, therefore resulting in an insufficient result after nose injection.

Materials with higher viscosity n^* present with great extrusion force and greater capability to not diffuse in tissues during facial movement^[4].

Both modules are proportional to concentration amount and any dilution will decrease them^[120,121].

Non-rheological properties of the injectable agent are mainly related to its hydrophilia and to the presence of lidocaine, which, as reported, also affects the rheological behavior of the agent^[36].

The eligible filling for nose reshaping agent should therefore have high G' and n^* , and be minimal hydrophilic as long as little volume is required to be injected in order to obtain a satisfying nose contouring.

Calcium hydroxyapatite is the only agent that would meet the ideal rheological criteria, while hyaluronic acid fillers do not; but unfortunately, it is not reversible, which is of major concern with injectables, and therefore hyaluronic acid remains nowadays the most widely injected agent^[120].

Fat, once harvested and centrifuged, could be injected; however, its rate of may request repeated treatment sessions^[121-125].

In 2019, Trivisonno *et al.* published a paper on the use of autologous fluid cartilage harvested and injected in the operating room to refine surgical rhinoplasty outcomes, similar to other forms of cartilage injectables^[86].

In the same year, a significant upgrade occurred: as surgical and medical fields were overlapping more and more, injectable nose reshaping started to be designed and performed from the perspective of surgical techniques and not only of anatomical landmarks and structures, in order to improve results safety and reliability^[14,70-74,126].

It is the Authors' opinion that this achievement is rooted in the trend that started in 2016 with the publication of medical nose job outcome evaluation^[77-79] and patient satisfaction papers^[76,80,81] which were similarly available for surgical rhinoplasty.

The option of using threads for nose reshaping, together with the surgical upgrade in the injection technique mentioned above, finally merge into a new outlook on "medical nose reshaping" which is what ultimately this treatment should be named, in the Author's opinion. Injectable or thread nose reshaping, nominally medical, must be therefore differentiated from rhinoplasty as the only surgical procedure.

This new conception will enable a clearer understanding of patients' needs and professional practice, pointing out the limits and opportunities of this range of procedures.

Nose reshaping can be effectively addressed using threads to correct:

- Narrow naso-frontal angle;
- Mild to moderate dorsal hump;
- Dorsal concavity or shallow dorsum (Saddle nose);
- contour irregularities or asymmetries (Crooked nose);

- Polly-beak deformity;
- Decreased tip projection or rotation;
- Alar base deficiency and other Alar rim irregularities;
- Narrow naso-labial angle;
- Minor asymmetries or irregularities after primary rhinoplasty;
- Nasal valve deficiencies (both internal and external).

When these flaws are either native or occur after primary rhinoplasty.

Discussing the technical details of this camouflaging technique is not the original purpose of this paper, partly because the technique has actually been recently codified^[127], but generally, it could be claimed that threads work as a mechanical scaffold, with loops and barbs as if they were an internal framework.

For every single thread, several passages are made to create a strut or as a graft: when volume enhancement is desired, then the greater the number of loops, the greater the enlargement will be due to thread volume.

Threads are better used in sites where tissue internal pressure would be more likely to press injected substances into adjacent areas, which would lead to an early loss of the strut-like effect of the injected material. Multiple threads insertion, or multiple loops of a longer thread, could instead enable greater correction thanks to their permanence in tissues. This gives initial mechanical strength, while in the meantime, tissues are healing around the thread, thus promoting further biological support^[25,26,126].

To date, it is remarkable that complications related to botulinum toxin have not been reported, while one published paper is focused on complications associated with thread lifting techniques on the nose due to the presence of previous prosthetic material insertion^[75] and complications related to nose thread lifting have only been reported in recent years^[127-129], coinciding with the increasing spread of this technique.

Even if not strictly related to cosmetic literature, it is of great importance to report that only three papers have been published so far about functional upper airway dynamics treated medically (internal and external valve impairment and empty nose syndrome).

The first ever paper was published by Redaelli *et al.* in 2012^[59], then Saban in 2014^[88] using threads. The most recent paper is from 2019^[68] and it is the first to report the use of carboxymethylcellulose^[68] to obtain the same outcome that would normally be achieved by cartilage grafts on the alar rim^[69], as recently codified by Sulamanideze *et al.*^[127].

Finally, based on the contents recorded in reviewed articles and the Authors' clinical experience, it could be advised to proceed with medical nose reshaping techniques as indicated, after a careful assessment of skin type and texture, in order to consider the way it will eventually drape after the procedure. After evaluation of the actual shape of nasal bones and the cartilaginous framework, as well as the presence of the potential irregularities to be corrected, it should bear in mind that no surgical dissection would take place:

- A narrow naso-frontal angle could be corrected either by filler injection or by inserting threads upward and downward from the procerus muscle, thus harvesting thread loops in the concavity to gain volume in the nose root to widen the angle;
- A mild to moderate dorsal hump could be treated by injecting fillers along the midline, above and below the hump in order to conceal it. When using threads, a hump is corrected by running multiple loops above and below it to project the overlying tissue of the low dorsum, thus concealing the deformity by camouflage. Even indirectly, the correction could be made by tissue heaping when the tip is lifted if desired;
- A saddle nose, with dorsal concavity or a shallow dorsum, is approached by carrying out multiple loops in the concavity to project the overlying tissue of the low dorsum, thus concealing the deformity by camouflage. Threads are to be preferred when the amount of filler to be injected appears to be too large and can therefore be displaced laterally due to tissue pressure; conversely, the barbs anchor the volume created by the loops in the site where they are implanted;
- Crooked nose and Polly-beak deformity are badly addressed with threads. These are therefore not indicated in such cases. Treating these deformities with filler injection requires extensive experience and excellent technical skills as they represent the most difficult challenges to be faced in medical nose reshaping, plus they often require surgical correction;
- A tip that is under-projected or under-rotated, with or without a narrow naso-labial angle, is always approached with botulinum toxin injection in the depressor nasi muscle. While it could be fully effective in the case of isolated dynamic tip, the position and the angle could be further improved with both filler injection or thread insertion: the filler is injected at the base and along the columella in order to strengthen and project the tip as would a columellar strut, and a small amount is injected below the tip, to better define its rotation. When threads are preferred, multiple threads are inserted from the tip cephalad along the midline and into the columella to create a framework that can maintain it in the elevated position by the barbs, while some extra loops in the tip also allow for further projection, acting as a columellar strut (the first) and as a shield graft (the second). In both cases, the weakened muscle provides longer-lasting results;
- Fillers should be avoided or at least be a second choice, driven by extensive experience, when treating alar base deficiency and other alar rim irregularities: the hazard of vascular complications when injecting in this area is high and the operator must be aware that it could be totally avoided by carrying out linear insertion of multiple threads above the lateral crura of the alar cartilage, that would act like an alar batten graft, and these are of course the ones to be recommended instead;
- Threads should be finally considered the first choice for any correction secondary to previous rhinoplasty: to avoid the danger arising from vascular impairment due to iatrogenic fibrosis and vascular net recovery. Injection of fillers for post-surgical nose correction requires adequate skills and must be performed knowing how to treat complications by dissolving the agent that can therefore only be hyaluronic acid.

All the treatments mentioned here could be carried out both by needle and cannula (fillers), while threads loaded on blunt cannulae have to be preferred since using threads on sharp needles could result in damage to the tip cartilages.

In the Authors' experience, hyaluronic acid should always be chosen for filling procedures as it is the only one to dissolve in case of any adverse event.

This review has indeed some limitations: only one paper among many is a randomized controlled study^[27] on nose reshaping with botulinum toxin for the treatment of plunging tips.

The level of evidence is therefore poor: other articles have directly reviewed the topic but non-systematically or not even in relation to the main complication-related topic.

To the best of the Authors' knowledge, this is the first literature review on comprehensive approaches to medical nose reshaping for non-surgical nose deformity correction. It has therefore been carried out following a very basic assumption: whenever a method to determine the true outcome, safety and reliability of treatments - something that is therefore beyond the mere judgment of patients and clinicians - is lacking, evidence has to be incorporated in daily clinical practice, drawing knowledge from case reports, pilot studies, up to available high-quality studies, as Evidence Based Medicine is essential to provide better answers for patients and physicians^[130].

CONCLUSIONS

Medical Nose Reshaping (MNR) can represent a reliable and effective camouflage technique, providing a high patient satisfaction rate.

The authors prefer the terms "medical" instead of "injectable", "liquid" or "non-surgical" and avoid calling this treatment "rhinoplasty", as that term should only be destined to the actual surgical procedure. While rhinoplasty remains the gold standard to correct nose defects; however, due to the market availability of different injectables, toxins and threads, along with the minimal invasiveness and short recovery time, many patients have benefited from MNR to correct specific deformities.

The debate about MNR remains ongoing due to insufficiently detailed indications and techniques in the past, along with numerous reports of mild to severe complications in the published literature.

In the Authors' experience, this treatment can bring great satisfaction to both patients and doctors when executed properly, primarily due to its immediate and long-lasting results. However, further refinement of this technique is required to ensure safe and reliable outcomes for patients.

Prospective, randomized controlled studies and systematic reviews of the literature are undoubtedly desirable as they will allow us to better standardize these procedures.

DECLARATIONS

Acknowledgments

The authors would like to thank Giulia Tanteri, an independent medical writer, who provided English-language editing and journal styling prior to submission.

Author's contributions

Made substantial contributions to the conception and design of the study, performed data analysis and interpretation: Diaspro A, Sulamanidze C

Verified the analytical methods, provided critical feedback, and helped shape the research, analysis, and manuscript: Pascali M, Bertossi D, Saban Y, Redaelli A

Contributed to the final manuscript: Diaspro A, Sulamanidze C, Pascali M, Bertossi D, Saban Y, Redaelli A

Availability of data and materials

Not applicable.

Financial support and sponsorship

None.

Conflict of interest

All authors declared that there are no conflicts of interest.

Ethical approval and consent to participate

Not applicable.

Consent for publication

Not applicable.

Copyright

© The Author(s) 2023.

REFERENCES

1. Hoffman K. Nose correction by palavit injection. *HNO* 1953;4:20. [PubMed](#)
2. Webster RC, Hamdan US, Gaunt JM, Fuleihan NS, Smith RC. Rhinoplastic revisions with injectable silicone. *Arch Otolaryngol Head Neck Surg* 1986;112:269-76. [DOI](#) [PubMed](#)
3. Stupak HD, Moulthrop TH, Wheatley P, Tauman AV, Johnson CM Jr. Calcium hydroxylapatite gel (Radiesse) injection for the correction of postrhinoplasty contour deficiencies and asymmetries. *Arch Facial Plast Surg* 2007;9:130-6. [DOI](#) [PubMed](#)
4. Gryskiewicz JM. Dorsal augmentation with AlloDerm. *Semin Plast Surg* 2008;22:90-103. [DOI](#) [PubMed](#) [PMC](#)
5. Redaelli A. Medical rhinoplasty with hyaluronic acid and botulinum toxin A: a very simple and quite effective technique. *J Cosmet Dermatol* 2008;7:210-20. [DOI](#) [PubMed](#)
6. Hilinski JM, Cohen SR. Soft tissue augmentation with ArteFill. *Facial Plast Surg* 2009;25:114-9. [DOI](#) [PubMed](#)
7. Cassuto D. The use of Dermicol-P35 dermal filler for nonsurgical rhinoplasty. *Aesthet Surg J* 2009;29:S22-4. [DOI](#) [PubMed](#)
8. Cárdenas JC, Carvajal J. Refinement of rhinoplasty with lipoinjection. *Aesthetic Plast Surg* 2007;31:501-5. [DOI](#) [PubMed](#)
9. Monreal J. Fat grafting to the nose: personal experience with 36 patients. *Aesthetic Plast Surg* 2011;35:916-22. [DOI](#)
10. Klinger F, Pajardi G, Vinci V, et al. Minimal Invasive rhinoplasty: fat injection for nasal dorsum contouring. *Ann Plast Surg* 2018;80:90. [DOI](#)
11. Giacomini PG, Rubino S, Mocella S, Pascali M, Di Girolamo S. Approach to the correction of drooping tip: common problems and solutions. *Acta Otorhinolaryngol Ital* 2017;37:295-302. [DOI](#) [PubMed](#) [PMC](#)
12. Boccieri A, Macro C, Pascali M. The use of spreader grafts in primary rhinoplasty. *Ann Plast Surg* 2005;55:127-31. [DOI](#) [PubMed](#)
13. Boccieri A, Pascali M. Septal crossbar graft for the correction of the crooked nose. *Plast Reconstr Surg* 2003;111:629-38. [DOI](#) [PubMed](#)
14. Segreto F, Marangi GF, Cerbone V, et al. Nonsurgical rhinoplasty: a graft-based technique. *Plast Reconstr Surg Glob Open* 2019;7:e2241. [DOI](#) [PubMed](#) [PMC](#)
15. DeLorenzi C. Complications of injectable fillers, part I. *Aesthet Surg J* 2013;33:561-75. [DOI](#) [PubMed](#)
16. Li KT, Huang YH, Chen CH, Chou LW. Delayed-onset cerebral infarction after cosmetic facial injection using hyaluronic acid. *J Formos Med Assoc* 2016;115:587-8. [DOI](#) [PubMed](#)
17. Yoon SS, Chang DI, Chung KC. Acute fatal stroke immediately following autologous fat injection into the face. *Neurology* 2003;61:1151-2. [DOI](#) [PubMed](#)
18. Kim EG, Eom TK, Kang SJ. Severe visual loss and cerebral infarction after injection of hyaluronic acid gel. *J Craniofac Surg* 2014;25:684-6. [DOI](#) [PubMed](#)
19. Lee S, Jung JH, Seo J, Kim EG. Ischemic stroke caused by a hyaluronic acid gel embolism treated with tissue plasminogen activator. *J Neurocritical Care* 2017;10:132-135. [DOI](#)
20. Manafi A, Barikbin B, Manafi A, Hamed ZS, Moghadam SA. Nasal alar necrosis following hyaluronic acid injection into nasolabial

- folds: a case report. *World J Plast Surg* 2015;4:74-8. [PubMed](#) [PMC](#)
21. Tiryaki KT. Shuttle lifting of the nose: a minimally invasive approach for nose reshaping. *Aesthet Surg J* 2010;30:176-83. [DOI](#)
 22. Guyuron B. Dynamics in rhinoplasty. *Plast Reconstr Surg* 2000;105:2257-9. [DOI](#) [PubMed](#)
 23. Gruber RP, Friedman GD. Suture algorithm for the broad or bulbous nasal tip. *Plast Reconstr Surg* 2002;110:1752-68. [PubMed](#)
 24. Helmy Y. Non-surgical rhinoplasty using filler, Botox, and thread remodeling: Retro analysis of 332 cases. *J Cosmet Laser Ther* 2018;20:293-300. [DOI](#)
 25. Kang SH, Moon SH, Kim HS. Nonsurgical rhinoplasty with polydioxanone threads and fillers. *Dermatol Surg* 2020;46:664-70. [DOI](#) [PubMed](#)
 26. Lee HY, Yang HJ. Rhinoplasty with barbed threads. *Plast Reconstr Surg Glob Open* 2018;6:e1967. [DOI](#) [PubMed](#) [PMC](#)
 27. Cigna E, Sorvillo V, Stefanizzi G, Fino P, Tarallo M. The use of botulinum toxin in the treatment of plunging nose: cosmetic results and a functional serendipity. *Clin Ter* 2013;164:e107-13. [DOI](#) [PubMed](#)
 28. Humphrey CD, Arkins JP, Dayan SH. Soft tissue fillers in the nose. *Aesthet Surg J* 2009;29:477-84. [DOI](#) [PubMed](#)
 29. Jasin ME. Nonsurgical rhinoplasty using dermal fillers. *Facial Plast Surg Clin North Am* 2013;21:241-52. [DOI](#) [PubMed](#)
 30. Kurkjian TJ, Ahmad J, Rohrich RJ. Soft-tissue fillers in rhinoplasty. *Plast Reconstr Surg* 2014;133:121e-6e. [DOI](#) [PubMed](#)
 31. Liew S, Scamp T, de Maio M, et al. Efficacy and safety of a hyaluronic acid filler to correct aesthetically detracting or deficient features of the asian nose: a prospective, open-label, long-term study. *Aesthet Surg J* 2016;36:760-72. [DOI](#) [PubMed](#) [PMC](#)
 32. Johnson ON 3rd, Kontis TC. Nonsurgical rhinoplasty. *Facial Plast Surg* 2016;32:500-6. [DOI](#) [PubMed](#)
 33. Thomas WW, Bucky L, Friedman O. Injectables in the nose: facts and controversies. *Facial Plast Surg Clin North Am* 2016;24:379-89. [DOI](#) [PubMed](#)
 34. Moon HJ. Use of fillers in rhinoplasty. *Clin Plast Surg* 2016;43:307-17. [DOI](#) [PubMed](#)
 35. Sahan A, Tamer F. Non-surgical minimally invasive rhinoplasty: tips and tricks from the perspective of a dermatologist. *Acta Dermatovenerol Alp Pannonica Adriat* 2017;26:101-3. [DOI](#) [PubMed](#)
 36. Wang LL, Friedman O. Update on injectables in the nose. *Curr Opin Otolaryngol Head Neck Surg* 2017;25:307-13. [DOI](#) [PubMed](#)
 37. Moon HJ. Injection rhinoplasty using filler. *Facial Plast Surg Clin North Am* 2018;26:323-30. [DOI](#) [PubMed](#)
 38. Singh P, Vijayan R, Nikkiah D. Filler rhinoplasty: evidence, outcomes, and complications. *Aesthet Surg J* 2018;38:NP165-7. [DOI](#) [PubMed](#)
 39. Jung GS. Clinical aesthetics of the nose for filler injection. *Facial Plast Surg* 2019;35:561-2. [DOI](#) [PubMed](#)
 40. Grunebaum LD, Bogdan Allemann I, Dayan S, Mandy S, Baumann L. The risk of alar necrosis associated with dermal filler injection. *Dermatol Surg* 2009;35 Suppl 2:1635-40. [DOI](#) [PubMed](#)
 41. Tracy L, Ridgway J, Nelson JS, Lowe N, Wong B. Calcium hydroxylapatite associated soft tissue necrosis: a case report and treatment guideline. *J Plast Reconstr Aesthet Surg* 2014;67:564-8. [DOI](#) [PubMed](#)
 42. Marumo Y, Hiraoka M, Hashimoto M, Ohguro H. Visual impairment by multiple vascular embolization with hydroxyapatite particles. *Orbit* 2018;37:165-70. [DOI](#) [PubMed](#)
 43. Sorensen EP, Council ML. Update in soft-tissue filler-associated blindness. *Dermatol Surg* 2020;46:671-7. [DOI](#) [PubMed](#)
 44. Bertossi D, Giampaoli G, Verner I, Pirayesh A, Nocini R, Nocini P. Complications and management after a nonsurgical rhinoplasty: a literature review. *Dermatol Ther* 2019;32:e12978. [DOI](#) [PubMed](#)
 45. Chatrath V, Banerjee PS, Goodman GJ, Rahman E. Soft-tissue filler-associated blindness: a systematic review of case reports and case series. *Plast Reconstr Surg Glob Open* 2019;7:e2173. [DOI](#) [PubMed](#) [PMC](#)
 46. Saban Y, Andretto Amodeo C, Hammou JC, Polselli R. An anatomical study of the nasal superficial musculoaponeurotic system: surgical applications in rhinoplasty. *Arch Facial Plast Surg* 2008;10:109-15. [DOI](#) [PubMed](#)
 47. Saban Y, Andretto Amodeo C, Bouaziz D, Polselli R. Nasal arterial vasculature: medical and surgical applications. *Arch Facial Plast Surg* 2012;14:429-36. [PubMed](#)
 48. Pilsel U, Anderhuber F. The external nose: the nasal arteries and their course in relation to the nasolabial fold and groove. *Plast Reconstr Surg* 2016;138:830e-5e. [DOI](#)
 49. Tansatit T, Moon HJ, Rungsawang C, et al. Safe planes for injection rhinoplasty: a histological analysis of midline longitudinal sections of the asian nose. *Aesthetic Plast Surg* 2016;40:236-44. [DOI](#)
 50. Tansatit T, Apinuntrum P, Phetudom T. Facing the worst risk: confronting the dorsal nasal artery, implication for non-surgical procedures of nasal augmentation. *Aesthetic Plast Surg* 2017;41:191-8. [DOI](#) [PubMed](#)
 51. Choi DY, Bae JH, Youn KH, et al. Topography of the dorsal nasal artery and its clinical implications for augmentation of the dorsum of the nose. *J Cosmet Dermatol* 2018;17:637-42. [DOI](#)
 52. Palomar-Gallego MA, Gómez-Esquer F, Gómez-Sánchez SM, Díaz-Gil G, Linares García-Valdecasas R. Influence of the topographic vascular distribution of the face on dermal filler accidents. *Dermatology* 2019;235:156-63. [DOI](#) [PubMed](#)
 53. Dayan SH, Kempiners JJ. Treatment of the lower third of the nose and dynamic nasal tip ptosis with Botox. *Plast Reconstr Surg* 2005;115:1784-5. [DOI](#) [PubMed](#)
 54. Ghavami A, Janis JE, Guyuron B. Regarding the treatment of dynamic nasal tip ptosis with botulinum toxin A. *Plast Reconstr Surg* 2006;118:263-4. [DOI](#) [PubMed](#)
 55. Beer KR. Nasal reconstruction using 20 mg/mL cross-linked hyaluronic acid. *J Drugs Dermatol* 2006;5:465-466. [PubMed](#)
 56. Lacerda DA, Zancanaro P. Filler rhinoplasty. *Dermatol Surg* 2007;33 Suppl 2:S207-S212. [DOI](#) [PubMed](#)
 57. Rokhsar C, Ciocon DH. Nonsurgical rhinoplasty: an evaluation of injectable calcium hydroxylapatite filler for nasal contouring.

- Dermatol Surg* 2008;34:944-6. DOI PubMed
58. Braccini F, Dohan Ehrenfest DM. La rhinoplastie médicale: de l'usage de la toxine botulique et des produits de comblement pour un remodelage atraumatique du nez [Medical rhinoplasty: rationale for atraumatic nasal modelling using botulinum toxin and fillers]. *Rev Laryngol Otol Rhinol* 2008;129:-233-238. PubMed
59. Redaelli A, Limardo P. Minimally invasive procedures for nasal aesthetics. *J Cutan Aesthet Surg* 2012;5:115-20. PubMed PMC
60. Turkmani MG, De Boule K. Excessive columellar show: causes, presentations and a new therapeutic approach with onabotulinum toxin A. *Dermatol Surg* 2013;39:464-7. DOI
61. Modrzyński M, Ignaciuk A. [The minimally invasive rhinoplasty with hyaluronic acid and botulinum toxin in a 49-year old woman]. *Otolaryngol Pol* 2010;64:324-7. DOI PubMed
62. Piggott JR, Yazdani A. Hyaluronic acid used for the correction of nasal deviation in an 18-year-old Middle Eastern man. *Can J Plast Surg* 2011;19:156-8. DOI
63. Tanaka Y, Matsuo K, Yuzuriha S. Westernization of the asian nose by augmentation of the retropositioned anterior nasal spine with an injectable filler. *Eplasty* 2011;11:e7. PubMed PMC
64. Kim P, Ahn JT. Structured nonsurgical Asian rhinoplasty. *Aesthetic Plast Surg* 2012;36:698-703. DOI PubMed
65. Wang YF, Wang CC, Liu KL. A woman's secret. Filler rhinoplasty with Radiesse (Merz Aesthetics, San Mateo, CA) and gold thread implantation. *Ann Emerg Med* 2013;62:224, 234. DOI
66. Tanaka Y. Oriental nose occidentalization and perinasal shaping by augmentation of the underdeveloped anterior nasal spine. *Plast Reconstr Surg Glob Open* 2014;2:e197. DOI PubMed PMC
67. Hedén P. Nasal reshaping with hyaluronic acid: an alternative or complement to surgery. *Plast Reconstr Surg Glob Open* 2016;4:e1120. DOI PubMed PMC
68. Borchard NA, Dholakia SS, Yan CH, Zarabanda D, Thamboo A, Nayak JV. Use of intranasal submucosal fillers as a transient implant to alter upper airway aerodynamics: implications for the assessment of empty nose syndrome. *Int Forum Allergy Rhinol* 2019;9:681-7. DOI PubMed
69. Cervelli V, Spallone D, Bottini JD, et al. Alar batten cartilage graft: treatment of internal and external nasal valve collapse. *Aesthetic Plast Surg* 2009;33:625-34. DOI
70. Jung GS, Chu SG, Lee JW, et al. A Safer Non-surgical filler augmentation rhinoplasty based on the anatomy of the nose. *Aesthetic Plast Surg* 2019;43:447-52. DOI
71. Mehta U, Fridirici Z. Advanced techniques in nonsurgical rhinoplasty. *Facial Plast Surg Clin North Am* 2019;27:355-65. DOI PubMed
72. Singh S. Practical tips and techniques for injection rhinoplasty. *J Cutan Aesthet Surg* 2019;12:60-2. PubMed PMC
73. Bertossi D, Lanaro L, Dell'Acqua I, Albanese M, Malchiodi L, Nocini PF. Injectable profiloplasty: forehead, nose, lips, and chin filler treatment. *J Cosmet Dermatol* 2019;18:976-84. DOI
74. Jung GS. Filler rhinoplasty based on anatomy: the dual plane technique. *JPRAS Open* 2019;20:94-100. DOI PubMed PMC
75. Kim HJ, Lee SJ, Lee JH, Kim SH, Suh IS, Jeong HS. Clinical features of skin infection after rhinoplasty with only absorbable thread (polydioxanone) in oriental traditional medicine: a case series study. *Aesthetic Plast Surg* 2020;44:139-47. DOI PubMed
76. Rauso R, Colella G, Zerbinati N, Salti G. Safety and early satisfaction assessment of patients seeking nonsurgical rhinoplasty with filler. *J Cutan Aesthet Surg* 2017;10:207-14. PubMed PMC
77. Bravo BSF, Bravo LG, Mariano Da Rocha C, et al. Evaluation and proportion in nasal filling with hyaluronic acid. *J Clin Aesthet Dermatol* 2018;11:36-40. PubMed PMC
78. Santorelli A, Marilino S. Non-surgical rhinoplasty with hyaluronic acid fillers: predictable results using software for the evaluation of nasal angles. *Aesthetic Plast Surg* 2020;44:919-26. DOI PubMed
79. Rho NK, Park JY, Youn CS, Lee SK, Kim HS. Early changes in facial profile following structured filler rhinoplasty: an anthropometric analysis using a 3-dimensional imaging system. *Dermatol Surg* 2017;43:255-63. DOI PubMed
80. Schuster B. Injection rhinoplasty with hyaluronic acid and calcium hydroxyapatite: a retrospective survey investigating outcome and complication rates. *Facial Plast Surg* 2015;31:301-7. DOI PubMed
81. Rosa L, Cerulli G, De Pasquale A. Psychological analysis of non-surgical rhinoplasty. *Aesthetic Plast Surg* 2020;44:131-8. DOI PubMed
82. Siclovan HR, Jomah JA. Injectable calcium hydroxylapatite for correction of nasal bridge deformities. *Aesthetic Plast Surg* 2009;33:544-8. DOI PubMed
83. Erol OO. Microfat grafting in nasal surgery. *Aesthet Surg J* 2014;34:671-86. DOI PubMed
84. Rivkin A. A prospective study of non-surgical primary rhinoplasty using a polymethylmethacrylate injectable implant. *Dermatol Surg* 2014;40:305-13. DOI PubMed
85. Chen L, Li SR, Yu P, Wang ZX. Comparison of artecoll, restylane and silicone for augmentation rhinoplasty in 378 chinese patients. *Clin Invest Med* 2014;37:E203-10. DOI
86. Trivisonno A, Cohen SR, Magalon G, et al. Fluid cartilage as new autologous biomaterial in the treatment of minor nose defects: clinical and microscopic difference amongst diced, crushed, and fluid cartilage. *Materials* 2019;12:1062. DOI PubMed PMC
87. Boccieri A, Marianetti TM, Pascali M. Crushed cartilage: a rescue procedure in rhinoplasty. *J Craniofac Surg* 2018;29:614-7. DOI PubMed
88. Saban Y, Javier de B, Massa M. Nasal lift-nasal valve lift and nasal tip lift-preliminary results of a new technique using noninvasive

- self-retaining unidirectional nasal suspension with threads. *Facial Plast Surg* 2014;30:661-9. DOI PubMed
89. Lee MJ, Sung MS, Kim NJ, Choung HK, Khwang SI. Eyelid mass secondary to injection of calcium hydroxylapatite facial filler. *Ophthalmic Plast Reconstr Surg* 2008;24:421-3. DOI PubMed
90. Inoue K, Sato K, Matsumoto D, Gonda K, Yoshimura K. Arterial embolization and skin necrosis of the nasal ala following injection of dermal fillers. *Plast Reconstr Surg* 2008;121:127e-8e. DOI PubMed
91. Colombo G, Caregnato P, Stifanese R, Ferrando G. A vast intranasal filler-induced granulomatous reaction: a case report. *Aesthetic Plast Surg* 2010;34:660-3. DOI PubMed
92. Sung MS, Kim HG, Woo KI, Kim YD. Ocular ischemia and ischemic oculomotor nerve palsy after vascular embolization of injectable calcium hydroxylapatite filler. *Ophthalmic Plast Reconstr Surg* 2010;26:289-91. DOI
93. Kim YJ, Kim SS, Song WK, Lee SY, Yoon JS. Ocular ischemia with hypotony after injection of hyaluronic acid gel. *Ophthalmic Plast Reconstr Surg* 2011;27:e152-5. DOI PubMed
94. Kim SG, Kim YJ, Lee SI, Lee CJ. Salvage of nasal skin in a case of venous compromise after hyaluronic acid filler injection using prostaglandin E. *Dermatol Surg* 2011;37:1817-9. DOI
95. Kang MS, Park ES, Shin HS, Jung SG, Kim YB, Kim DW. Skin necrosis of the nasal ala after injection of dermal fillers. *Dermatol Surg* 2011;37:375-80. DOI PubMed
96. Kim YJ, Choi KS. Bilateral blindness after filler injection. *Plast Reconstr Surg* 2013;131:298e-9e. DOI PubMed
97. Honart JF, Duron JB, Mazouz Dorval S, Rausky J, Revol M. [A case of nasal tip necrosis after hyaluronic acid injection]. *Ann Chir Plast Esthet* 2013;58:676-9. DOI PubMed
98. Kim SN, Byun DS, Park JH, et al. Panophthalmoplegia and vision loss after cosmetic nasal dorsum injection. *J Clin Neurosci* 2014;21:678-80. DOI
99. Lazzeri D, Spinelli G, Zhang YX, Nardi M, Lazzeri S. Panophthalmoplegia and vision loss after cosmetic nasal dorsum injection. *J Clin Neurosci* 2014;21:890. DOI PubMed
100. Lazzeri D, Agostini T, Figus M, Nardi M, Pantaloni M, Lazzeri S. Blindness following cosmetic injections of the face. *Plast Reconstr Surg* 2012;129:995-1012. DOI PubMed
101. Chang C, Lee SB. Unusual long-term complication of polyalkylimide hydrogel manifesting as nasal septal abscess. *J Craniofac Surg* 2015;26:e197-9. DOI
102. Chou CC, Chen HH, Tsai YY, Li YL, Lin HJ. Choroid vascular occlusion and ischemic optic neuropathy after facial calcium hydroxyapatite injection- a case report. *BMC Surg* 2015;15:21. DOI PubMed PMC
103. Kim SK, Kim JH, Hwang K. Skin necrosis of the nose after injection of ribose cross-linked porcine atelocollagen. *J Craniofac Surg* 2015;26:2211-2. DOI PubMed
104. Lin YC, Chen WC, Liao WC, Hsia TC. Central retinal artery occlusion and brain infarctions after nasal filler injection. *QJM* 2015;108:731-2. DOI PubMed
105. Alharethy S. Alterations in nasal sensibility following calcium hydroxyapatite dorsal augmentation. *J Craniofac Surg* 2018;29:e104-6. DOI PubMed
106. Vu PQ, Grob SR, Tao JP. Light perception vision recovery after treatment for calcium hydroxylapatite cosmetic filler-induced blindness. *Ophthalmic Plast Reconstr Surg* 2018;34:e189-92. DOI PubMed
107. Vidič M, Bartenjev I. An adverse reaction after hyaluronic acid filler application: a case report. *Acta Dermatovenerol Alp Pannonica Adriat* 2018;27:165-167. DOI PubMed
108. Bae IH, Kim MS, Choi H, Na CH, Shin BS. Ischemic oculomotor nerve palsy due to hyaluronic acid filler injection. *J Cosmet Dermatol* 2018;17:1016-8. DOI
109. Robati RM, Moeineddin F, Almasi-Nasrabadi M. The risk of skin necrosis following hyaluronic acid filler injection in patients with a history of cosmetic rhinoplasty. *Aesthet Surg J* 2018;38:883-8. DOI PubMed
110. Hu HC, Cho HY, Chiu YH. Dermatomyositis induced by filler rhinoplasty using liquid silicone. *JAMA Otolaryngol Head Neck Surg* 2020;146:205-6. DOI PubMed
111. Ansari ZA, Choi CJ, Rong AJ, Erickson BP, Tse DT. Ocular and cerebral infarction from periocular filler injection. *Orbit* 2019;38:322-4. DOI PubMed
112. Huang P, Liu A, Ren H, Xue K. Color doppler flow imaging of retrobulbar ocular blood flow changes in retinal artery occlusions caused by cosmetic facial filler injections. *Ophthalmic Plast Reconstr Surg* 2019;35:227-31. DOI PubMed
113. Cohen E, Yatziv Y, Leibovitch I, et al. A case report of ophthalmic artery emboli secondary to Calcium Hydroxylapatite filler injection for nose augmentation- long-term outcome. *BMC Ophthalmol* 2016;16:98. DOI PubMed PMC
114. Chae SY, Lee KC, Jang YH, Lee SJ, Kim DW, Lee WJ. A case of the migration of hyaluronic acid filler from nose to forehead occurring as two sequential soft lumps. *Ann Dermatol* 2016;28:645-7. DOI PubMed PMC
115. Chen W, Wu L, Jian XL, et al. Retinal branch artery embolization following hyaluronic acid injection: a case report. *Aesthet Surg J* 2016;36:NP219-24. DOI
116. Megías-Vericat JE, Ricart JM, Ribes-Artero H, Poveda JL. Prostaglandin Injection after arterial compromise related to hyaluronic acid filler. *Dermatol Surg* 2017;43:975-7. DOI PubMed
117. Wu S, Pan L, Wu H, et al. Anatomic study of ophthalmic artery embolism following cosmetic injection. *J Craniofac Surg* 2017;28:1578-81. DOI
118. Townshend A. Blindness after facial injection. *J Clin Aesthet Derm* 2016;9:e5-7. PubMed PMC

119. Bray D, Hopkins C, Roberts DN. Injection rhinoplasty: non-surgical nasal augmentation and correction of post-rhinoplasty contour asymmetries with hyaluronic acid: how we do it. *Clin Otolaryngol* 2010;35:227-30. DOI
120. Sundaram H, Voigts B, Beer K, Meland M. Comparison of the rheological properties of viscosity and elasticity in two categories of soft tissue fillers: calcium hydroxylapatite and hyaluronic acid. *Dermatol Surg* 2010;36 Suppl 3:1859-65. DOI PubMed
121. Michaels M, Eng MO. Rheological properties of several hyaluronic acid-based gels: a comparative study. *J Drug Dermatol* 2018;17:948-54. PubMed
122. Nguyen PS, Baptista C, Casanova D, Bardot J, Magalon G. [Autologous fat grafting and rhinoplasty]. *Ann Chir Plast Esthet* 2014;59:548-54. DOI PubMed
123. Kao WP, Lin YN, Lin TY, et al. Microautologous fat transplantation for primary augmentation rhinoplasty: long-term monitoring of 198 asian patients. *Aesthet Surg J* 2016;36:648-56. DOI PubMed PMC
124. Lin S, Hsiao YC, Huang JJ, et al. Minimal invasive rhinoplasty: fat injection for nasal dorsum contouring. *Ann Plast Surg* 2017;78:S117-23. DOI
125. Toriumi DM. Dorsal augmentation using autologous costal cartilage or microfat-infused soft tissue augmentation. *Facial Plast Surg* 2017;33:162-78. DOI PubMed
126. Bertossi D, Malchiodi L, Albanese M, Nocini R, Nocini P. Nonsurgical rhinoplasty with the novel hyaluronic acid filler vyc-251: results using a nasal grid approach. *Aesthet Surg J* 2021;41:NP512-20. DOI PubMed
127. Sulamanidze C, Lanfranchi L, Diaspro A. Thread lifting of the nose: fully comprehensive approach to the technique. *Plast Reconstr Surg Glob Open* 2023;11:e4907. DOI PubMed PMC
128. Kim KS, Min HJ. Benign nasal mass as a delayed complication of barbed thread rhinoplasty. *J Craniofac Surg* 2022;33:e503-5. DOI PubMed
129. Jin HR, Kim SJ. Presentation patterns and surgical management of the complications of thread rhinoplasty. *Clin Exp Otorhinolaryngol* 2022;15:247-53. DOI PubMed PMC
130. Eaves F 3rd, Pusic AL. Why evidence-based medicine matters to aesthetic surgery. *Aesthet Surg J* 2012;32:117-9. DOI PubMed