

Technical Note

Open Access



# Novel surgical technique of robot-assisted thoracoscopic esophagectomy in the lateral decubitus position

Itasu Ninomiya, Koichi Okamoto

Department of Gastroenterological Surgery, Kanazawa University, Kanazawa, Ishikawa 920-8641, Japan.

**Correspondence to:** Pro. Itasu Ninomiya, Department of Gastroenterological Surgery, Kanazawa University, 13-1 Takaramachi, Kanazawa, Ishikawa 920-8641, Japan. E-mail: ninoitasu@gmail.com

**How to cite this article:** Ninomiya I, Okamoto K. Novel surgical technique of robot-assisted thoracoscopic esophagectomy in the lateral decubitus position. *Mini-invasive Surg* 2022;6:33. <https://dx.doi.org/10.20517/2574-1225.2022.12>

**Received:** 20 Jan 2022 **First Decision:** 14 Mar 2022 **Revised:** 17 Mar 2022 **Accepted:** 29 Mar 2022 **Published:** 1 Jun 2022

**Academic Editor:** Giulio Belli **Copy Editor:** Peng-Juan Wen **Production Editor:** Peng-Juan Wen

## Abstract

We performed robot-assisted thoracoscopic esophagectomy in lateral decubitus position (LDP) with camera rotation and manual hand control assignment to reproduce the visualization and manipulation of open esophagectomy or thoracoscopic esophagectomy in LDP. Four robotic ports and two 12 mm assistant ports were placed. The camera image for the operator was vertically and horizontally inverted by camera rotation to create an operative view similar to that achieved under open thoracotomy. We used a forward-oblique viewing endoscope with a 30° down-facing orientation. The mediastinal view was obtained by single lung ventilation, artificial pneumothorax by carbon dioxide insufflation, and trachea retraction by the assistant. The right and left hands were assigned to any combination of two out of the three arms depending on the situation. The remaining arm was used as an assistant to create an adequate surgical view. The robotic platform is useful to manage aortic injury by direct suturing.

**Keywords:** Robotic surgery, esophageal cancer, lateral decubitus position (LDP)

## INTRODUCTION

Esophagectomy with regional lymphadenectomy plays a major role in esophageal cancer treatment. Thoracoscopic and laparoscopic minimally invasive esophagectomy procedures have been performed to reduce the surgical damage caused by esophageal surgery<sup>[1-3]</sup>. Recently, robot-assisted thoracoscopic



© The Author(s) 2022. **Open Access** This article is licensed under a Creative Commons Attribution 4.0 International License (<https://creativecommons.org/licenses/by/4.0/>), which permits unrestricted use, sharing, adaptation, distribution and reproduction in any medium or format, for any purpose, even commercially, as long as you give appropriate credit to the original author(s) and the source, provide a link to the Creative Commons license, and indicate if changes were made.



esophagectomy (RATE) has become a widely adopted esophageal surgery. We introduced RATE in the lateral decubitus position (LDP) with the four-arm da Vinci Xi robotic system (Intuitive Surgical Inc., Sunnyvale, CA) as a curative operative procedure in 2018. The videoscopic images and hand control manipulation in the previously reported RATE in LDP<sup>[4-17]</sup> are the same as those in RATE in the prone position (PP)<sup>[18-24]</sup>, where the arms for the right and left hands are introduced into the thoracic cavity from the cranial and caudal directions, respectively. We performed thoracoscopic esophagectomy (TE) in the LDP under the image rotated by 180°, where the left side was cranial and the upper side was ventral; this image is similar to the view under open thoracotomy<sup>[25]</sup>. We successfully reproduced the same endoscopic view and hand manipulation in RATE in the LDP as in our TE via inversion of the image with camera rotation and manual hand control assignment<sup>[26]</sup>.

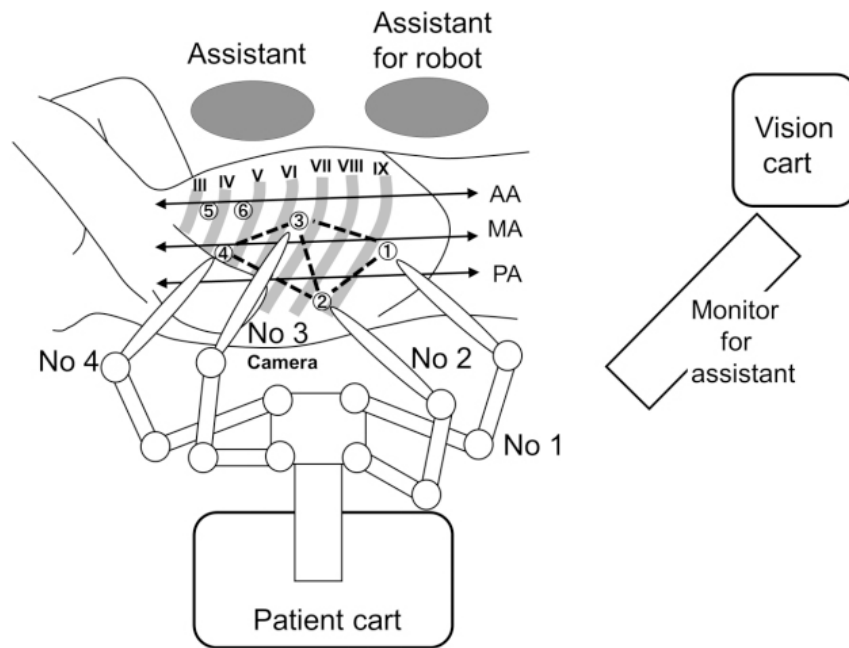
In this technical note, we present our surgical techniques of mediastinal dissection by RATE in LDP.

## OPERATIVE PROCEDURE

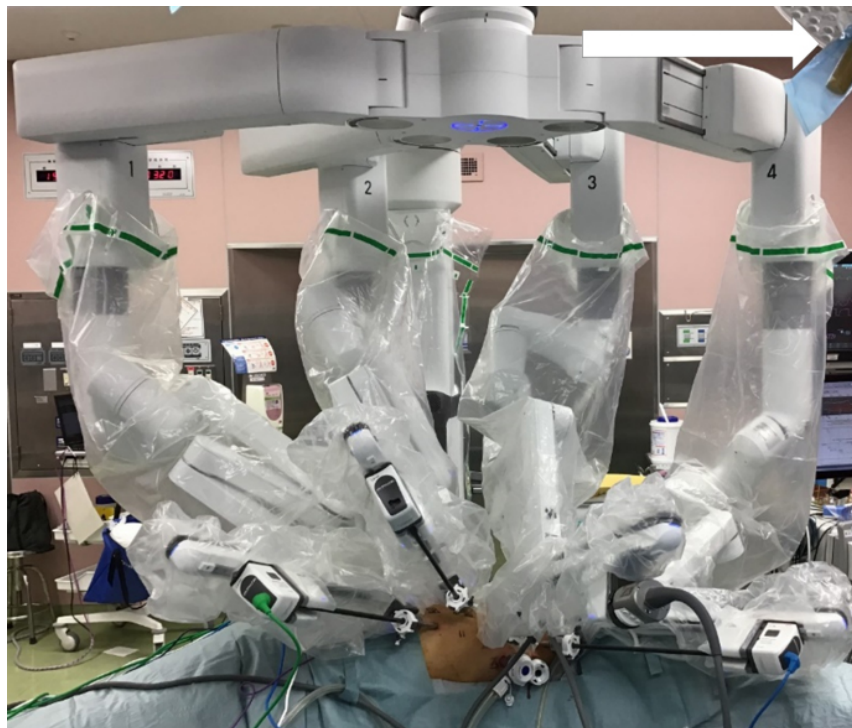As a radical surgical procedure for esophageal cancer, esophagectomy with three-field lymphatic dissection consisting of cervical, mediastinal, and abdominal dissections was performed. The operation was started from the thoracic procedure with RATE in LDP. After RATE, abdominal and supraclavicular cervical lymph node dissections were done simultaneously by two teams in the supine position. The abdominal lymphatic dissection was done by hand-assisted laparoscopic surgery. The gastric tube was selected as the primary reconstruction conduit and pulled up through the posterior mediastinum. The operation was finished with cervical anastomosis. In cases of non-curative resection, the retrosternal route was selected for elevation of the gastric tube to allow subsequent chemoradiotherapy of the residual tumor.

### Preparation of RATE in LDP

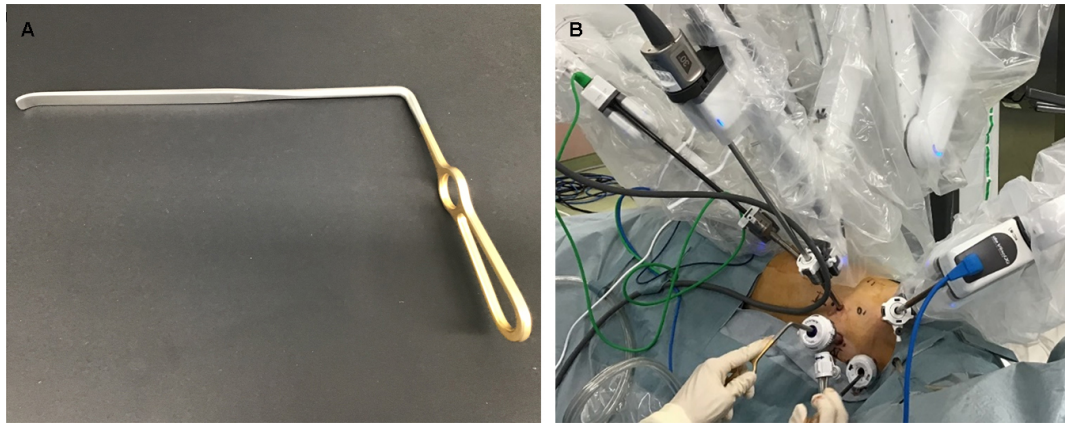
For the thoracic procedure, patients were placed in the left LDP after intubation with a left-side double-lumen tube. The patient body was tilted 30°-45° ventrally to prevent visual disturbance by the right lung. RATE was performed using the da Vinci Xi Surgical System (Intuitive Surgical Inc.). The patient cart was positioned on the dorsal side, with two assistants on the ventral side. An assistant retracted the lung and trachea with a tracheal retractor and dried the surgical field using suction. Another assistant exchanged the EndoWrist instruments (Intuitive Surgical Inc.). Four 8 mm robotic ports were placed; one in the 9th intercostal space (ICS) at the middle axillary line (AL) (Arm 1), one in the 8th ICS behind the posterior AL (Arm 2), one in the 6th ICS between the anterior and middle AL (Arm 3), and one in the 4th ICS at the middle AL (Arm 4). Two 12 mm assistant ports were placed in the 3rd ICS at anterior AL and the 4th ICS at anterior AL [Figure 1]. Ports 1-4 were connected to the corresponding robot arm [Figure 2]. The endoscope was held by Arm 3. The camera image for the operator was vertically and horizontally inverted by camera rotation to create an operative view similar to that achieved under open thoracotomy. We used a forward-oblique viewing endoscope with a 30° down-facing orientation. The right and left hands were assigned to Arms 1 and 4, Arms 2 and 4, or Arms 1 and 2, respectively, by manual hand control assignment depending on the situation. The remaining arm was used as an assistant arm. One of the assistant ports was connected to the valveless insufflation system (AirSeal; ConMed, Utica, NY) and used to achieve artificial pneumothorax with carbon dioxide insufflation at a pressure of 8 mmHg through an assistant port. The operator mainly used monopolar curved scissors in the right hand and a large bipolar grasper in the left hand. Organ retraction was done using Cadiere forceps held in the assistant arm. The assistant performed tracheal rotation using a narrow tracheal retractor inserted through the assistant port [Figure 3]. Dissection was done mainly using monopolar curved scissors, especially around the trachea and bronchus. A Vessel Sealer Extend (Intuitive Surgical Inc.) was used around the aorta, and it was occasionally used by the left hand during dissection at the left side of the middle and lower mediastinum. The image for the assistants



**Figure 1.** The trocar sites in the robot-assisted thoracoscopic esophagectomy in lateral decubitus position. Roman numerals show the rib numbers. Encircled numerals show the port sites. Ports 1-4 are the 8 mm da Vinci ports (Intuitive Surgical Inc.) connected to the corresponding robotic arms. Ports 5 and 6 are the 12 mm assistant ports. Port 6 is the AirSeal (ConMed) trocar. AA: Anterior axillary line; MA: middle axillary line; PA: posterior axillary line.



**Figure 2.** Final appearance after robot setup in robot-assisted thoracoscopic esophagectomy in lateral decubitus position. The patient cart is rolled in from the patient's dorsal side and docked to the robotic ports. Arrows indicate the cranial direction.



**Figure 3.** The trachea retractor insertable through the 12 mm port (A); and the usage of trachea retractor by an assistant (B).

was inverted horizontally and vertically.

#### **Dissection of right recurrent laryngeal nerve nodes**

Parietal pleura on the upper mediastinum was incised along with the right vagal nerve and right subclavian artery. After exposing the right side of the tracheal wall, the lymph nodes around the right recurrent laryngeal nerve (RLN) were dissected while preserving the right RLN [Figure 4A]. After the identification of right RLN by its running route, the dividing point of right RLN from the vagal nerve was exposed. Fatty tissue containing lymph nodes was grasped by Cadieere forceps held by Arm 2 as assistant arm [Figure 4B]. The esophageal branches from RLN were transected from the proximal side [Figure 4C]. Traction of lymphatic tissue to the caudal side by assistant arm and traction of subclavian artery to the cranial side by assistant enabled sufficient lymphatic dissection close to the lower pole of the thyroid gland [Figure 4D and E]. We consider the upper border of the dissection from thoracic cavity as the right inferior thyroid artery and lower pole of thyroid gland.

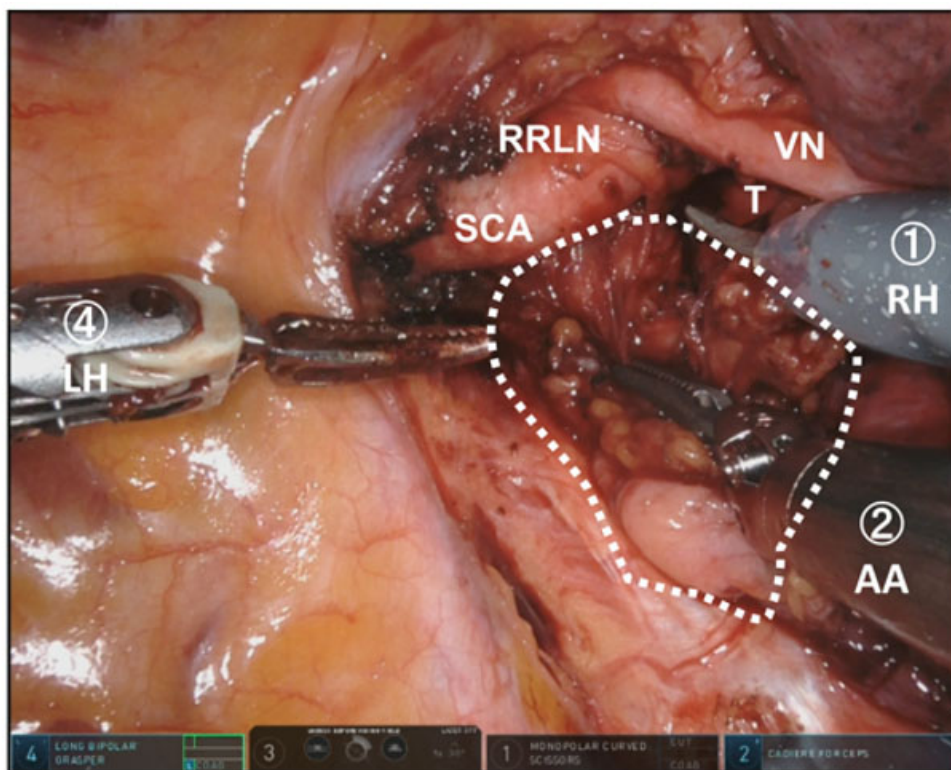
#### **Dissection of left RLN nodes**

To dissect the left RLN lymph nodes, the esophagus was isolated by cutting the esophago-tracheal ligament. The esophagus was taped and extracted dorsally by assistant Cadieere held by Arm 2. The trachea was rotated with a tracheal retractor by the assistant. Lymph nodes situated on the left side of the trachea were extracted by cutting the ventral border of the lymph nodes. We used a vessel sealer to prevent accidental bleeding [Figure 4F]. After the identification of left RLN ventral to the esophagus, we transected the vessels' flow into the left RLN lymph nodes at the level of aortic arch. We preserved several sympathetic cervical cardiac branches ventral to the left RLN. Then, we dissected the lymph nodes by exposing the left RLN with transecting the esophageal branches of left RLN from caudal to cranial side [Figure 4G]. Esophageal branches from the left inferior thyroid artery flow into the lymphatic tissue at the cervical-thoracic border. We transected these branches at their ventral inflow point by vessel sealer [Figure 4H]. After the isolation of left RLN, lymph nodes were retrieved by exposing the esophageal wall [Figure 4I and J]. The left main bronchus was extracted by trachea retractor to enlarge the subaortic area for dissection of the lymph nodes around the subaortic area to expose the dorsal side of left pulmonary artery [Figure 4K].

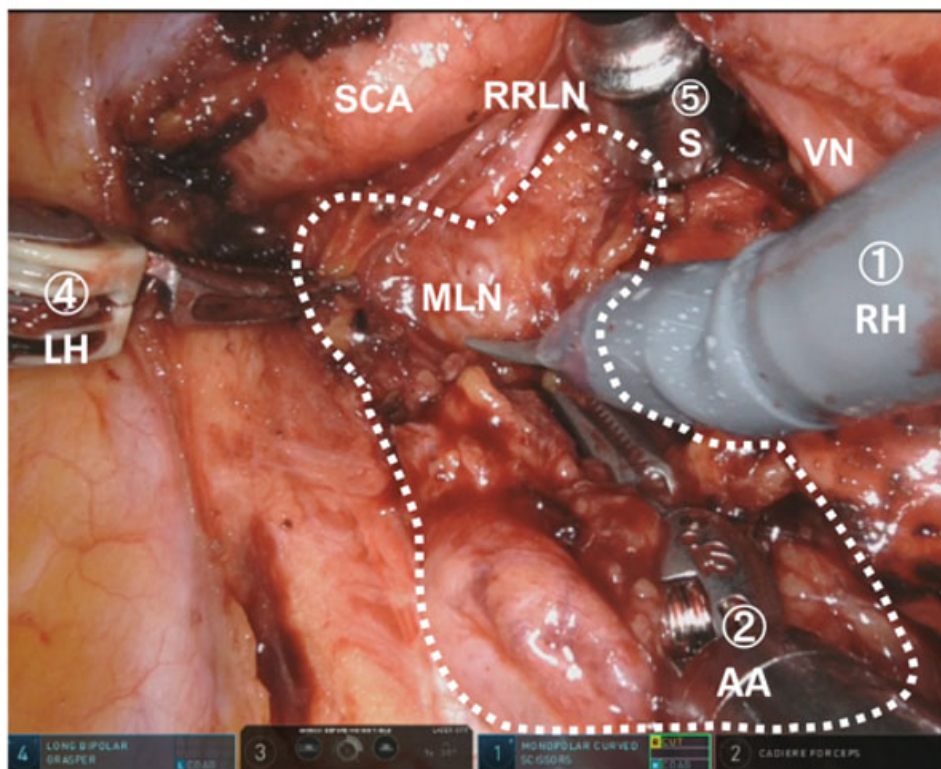
#### **Dissection of subcarinal area**

We exposed the right vagal nerve from cranial to caudal direction until the bronchial branches were branched from vagal nerve. The right bronchial artery was transected at its origin, and the peripheral branches of bronchial artery were transected at the cross point to vagal nerve. The vagal nerve was divided

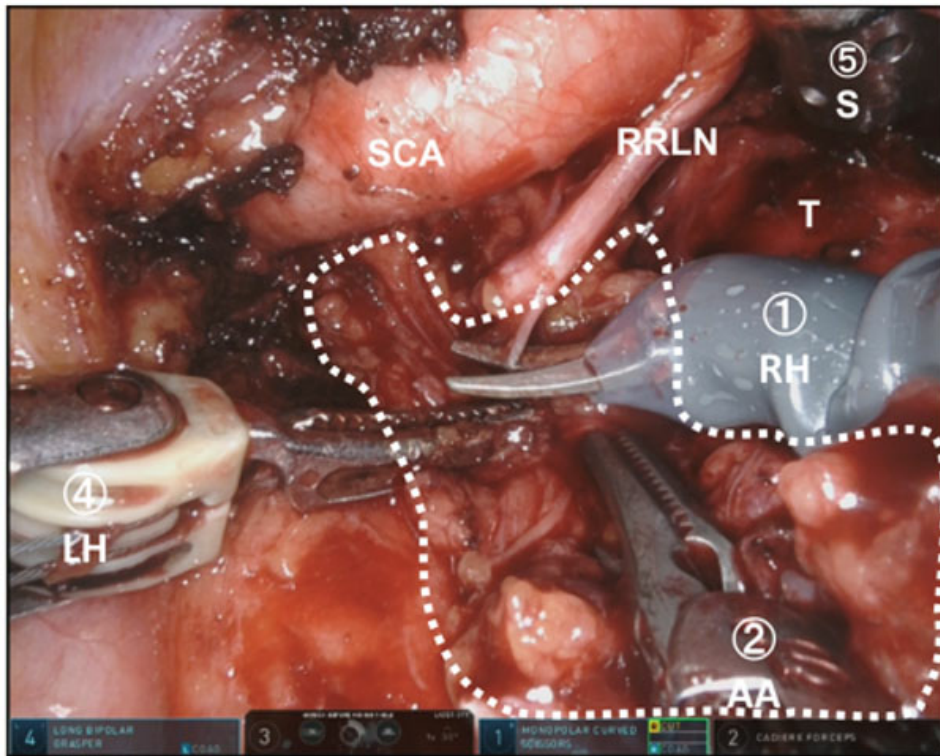
**A**



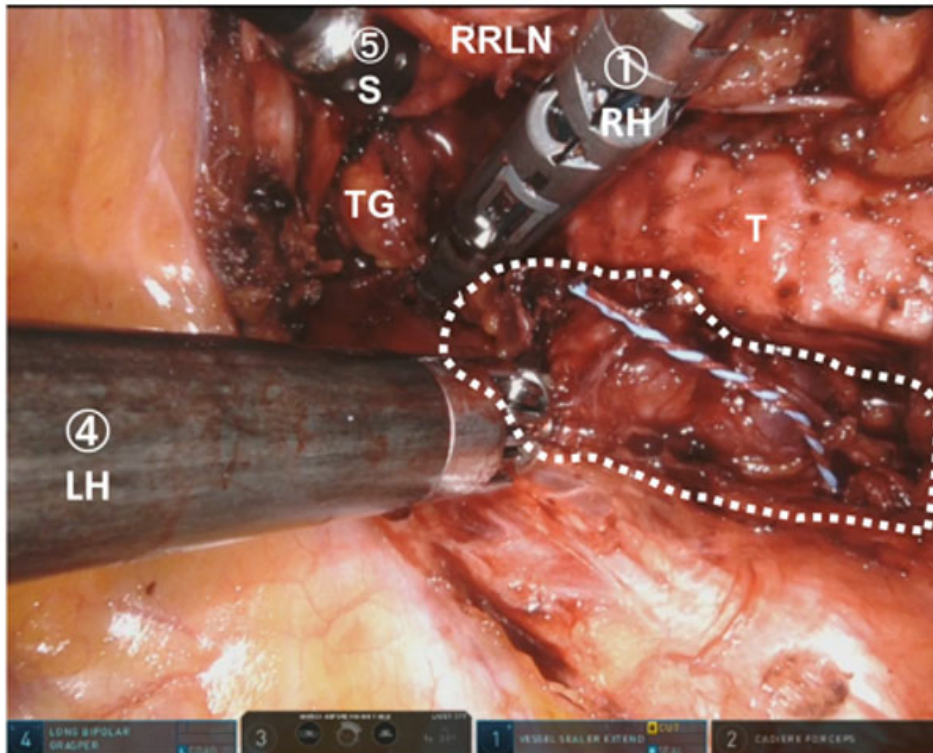
**B**

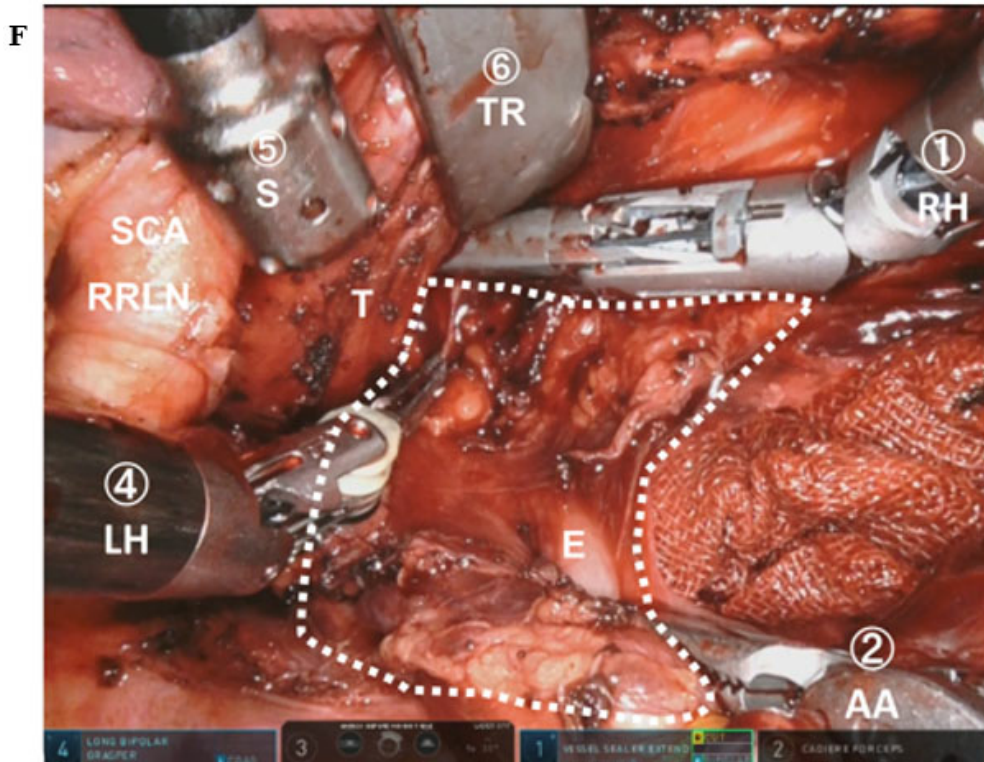
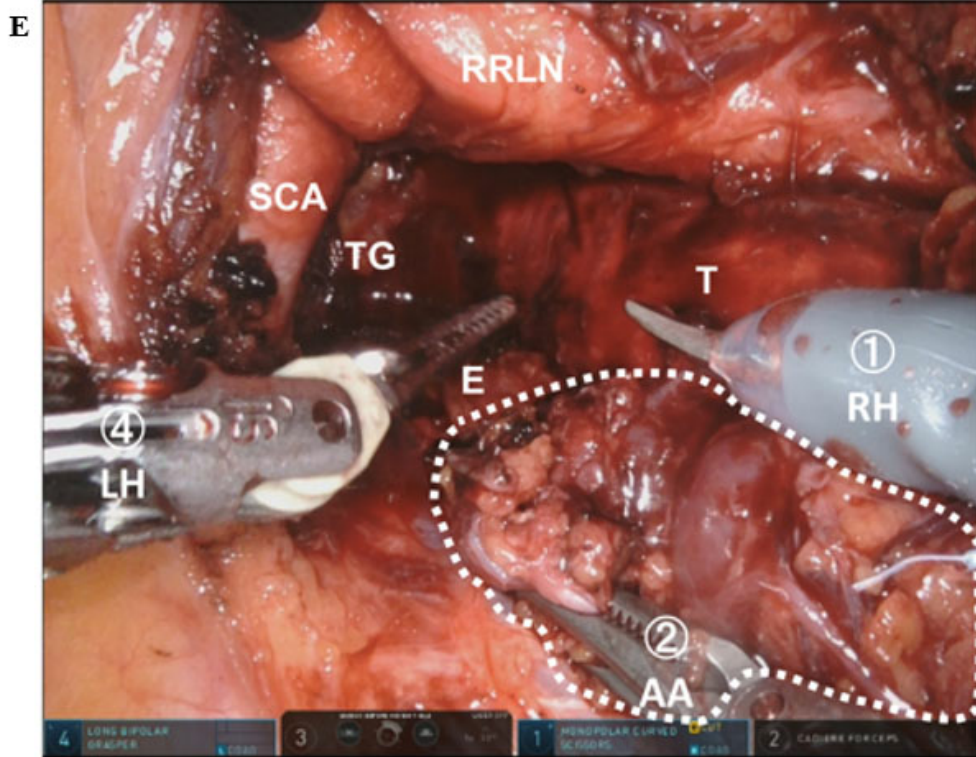


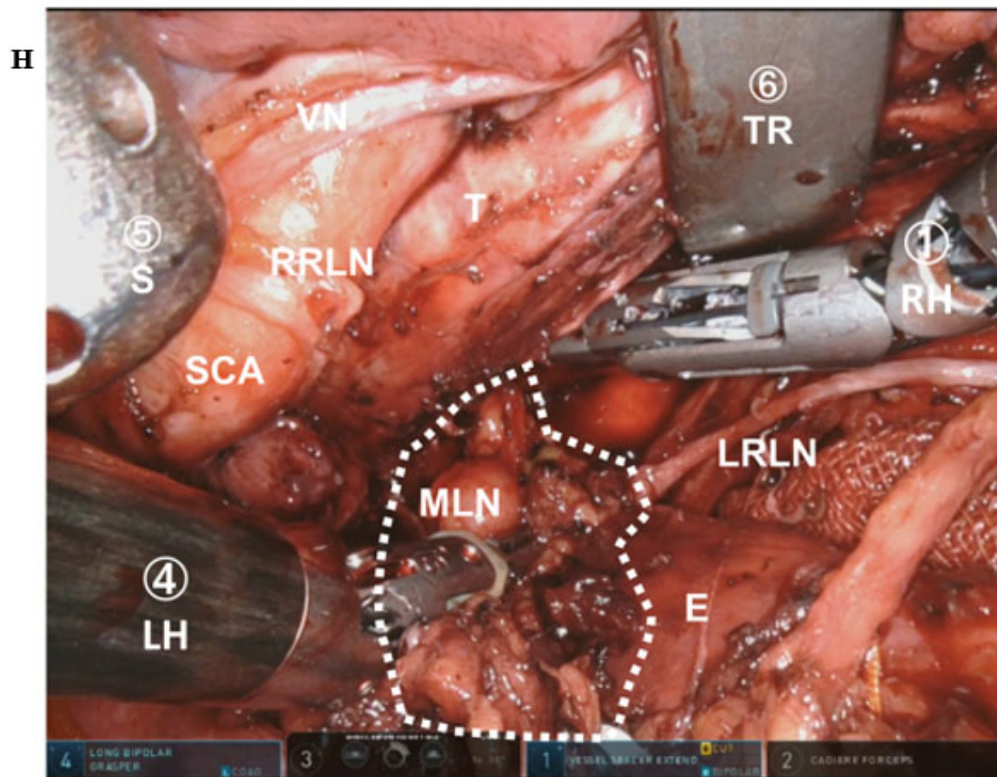
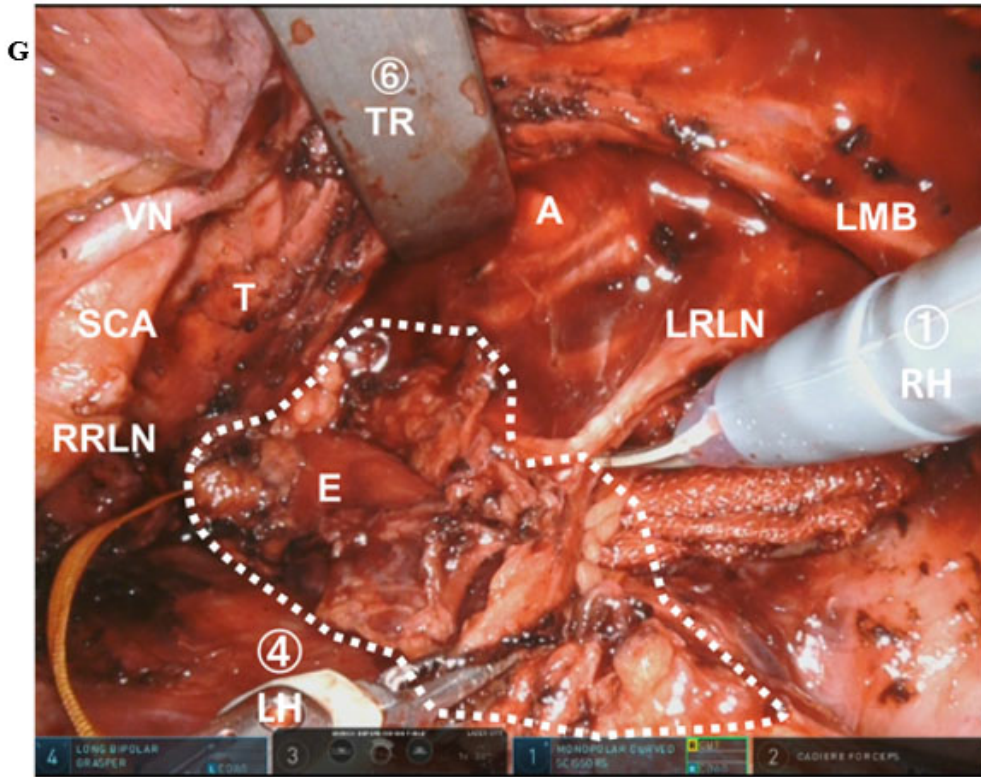
C



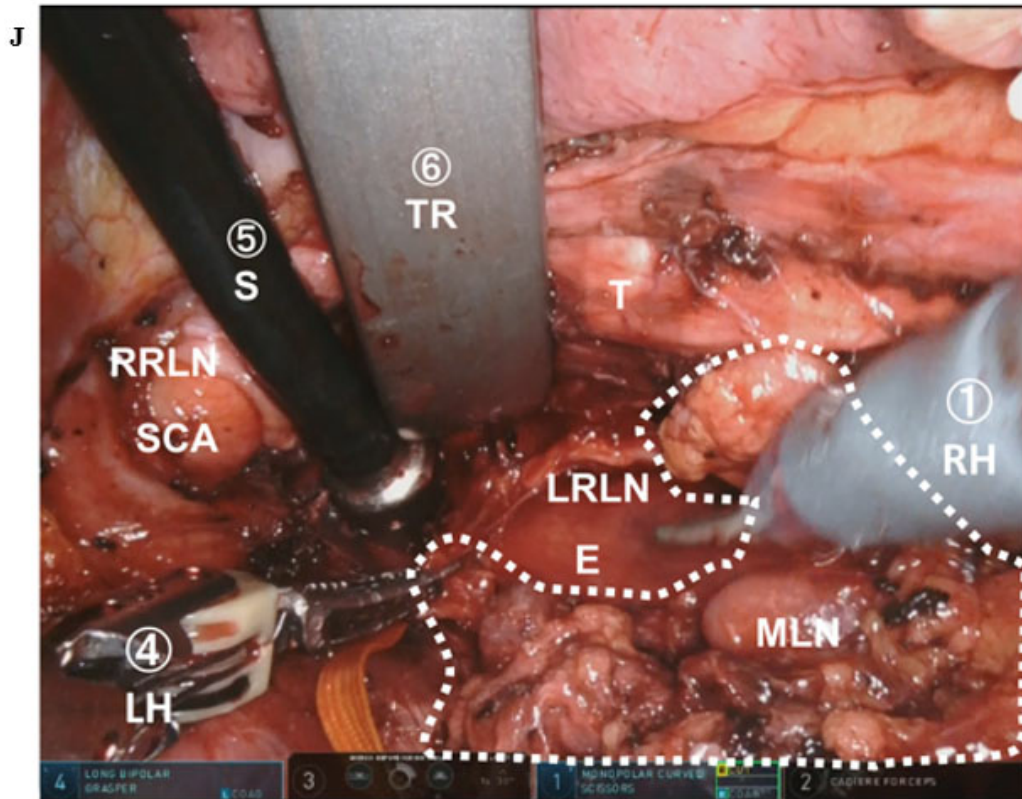
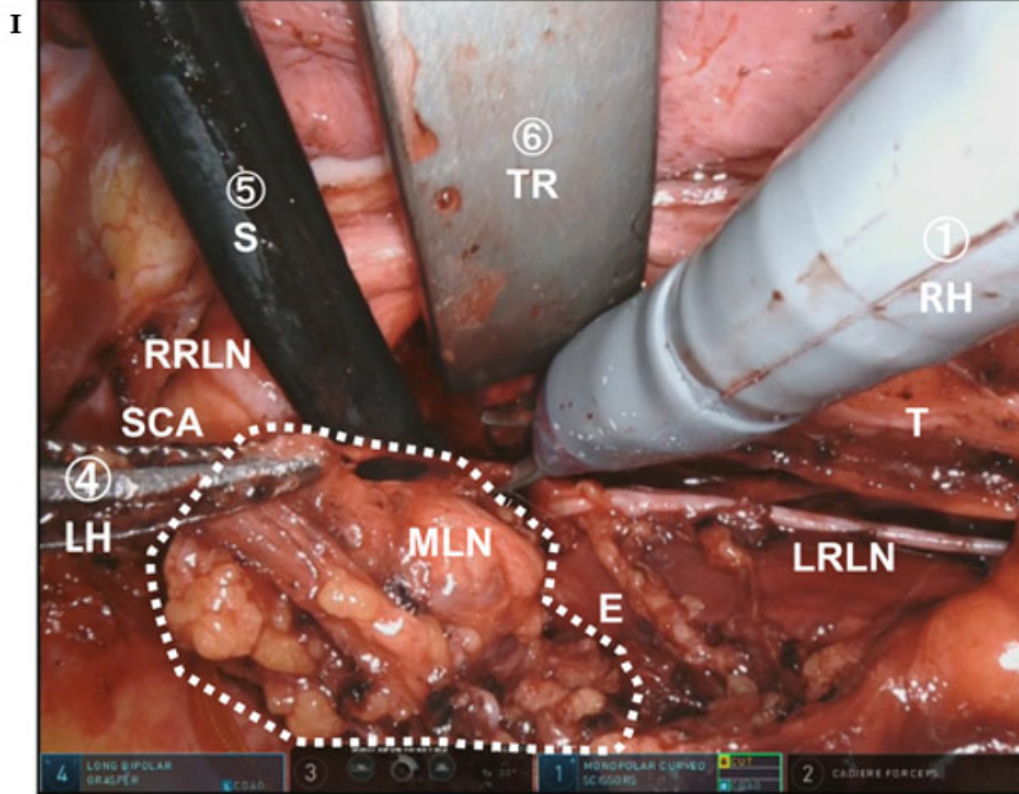
D

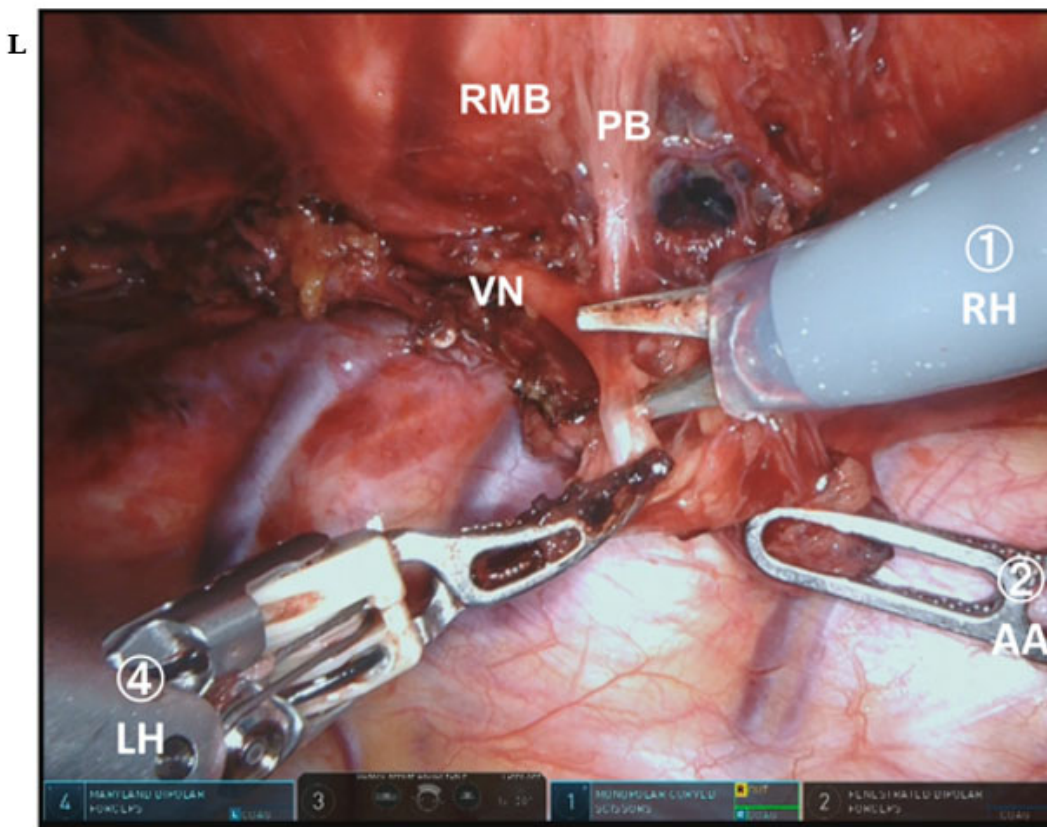
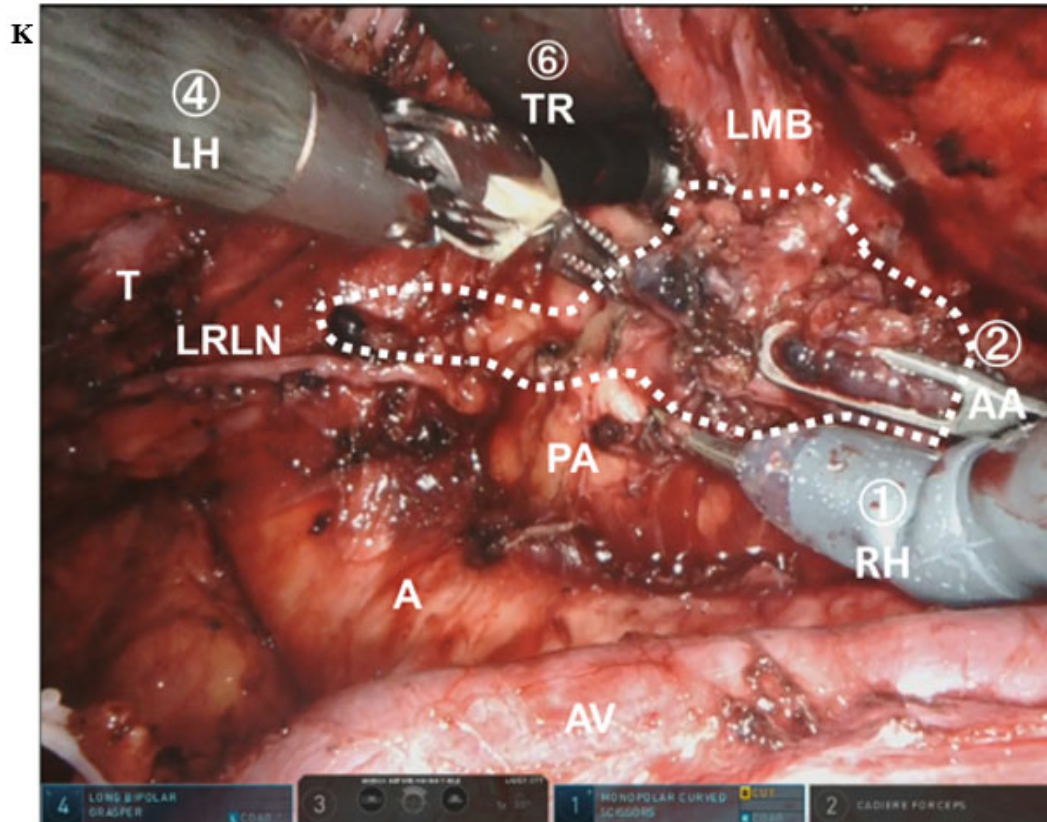




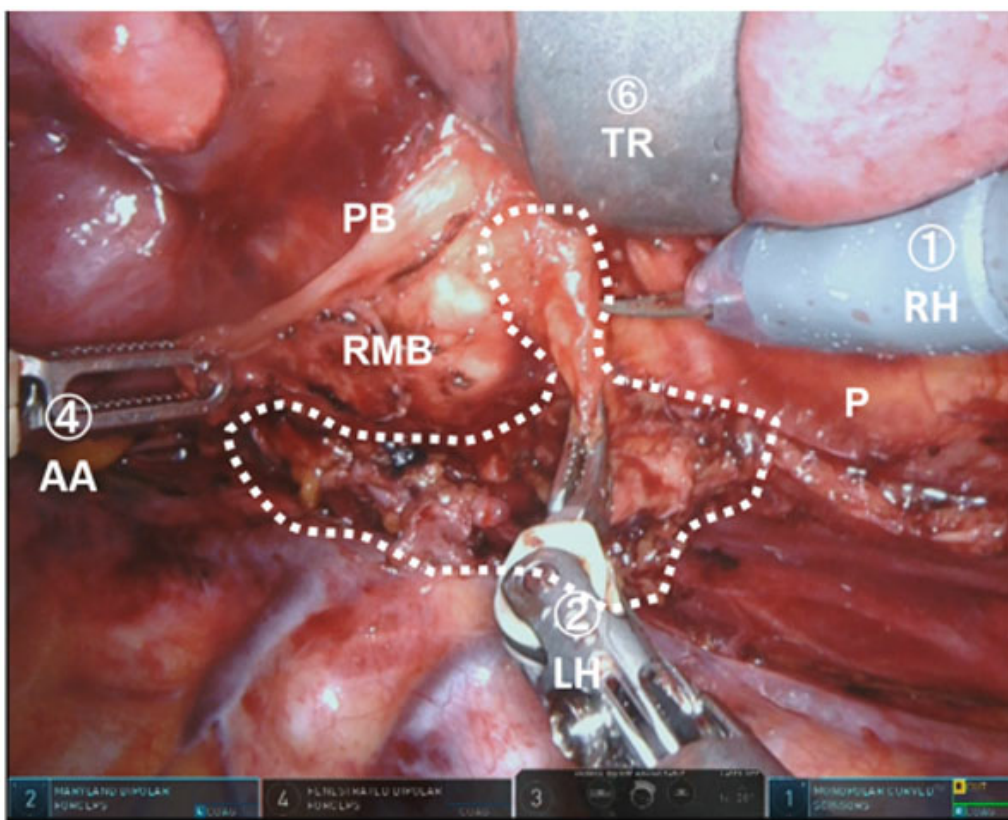




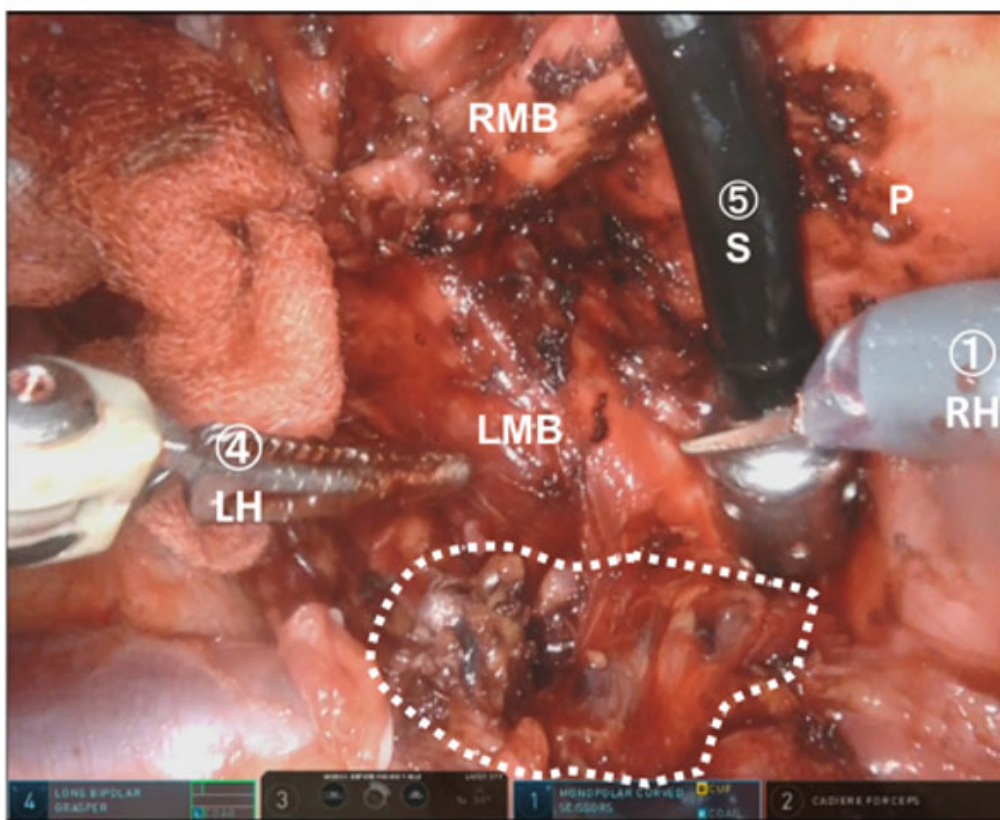


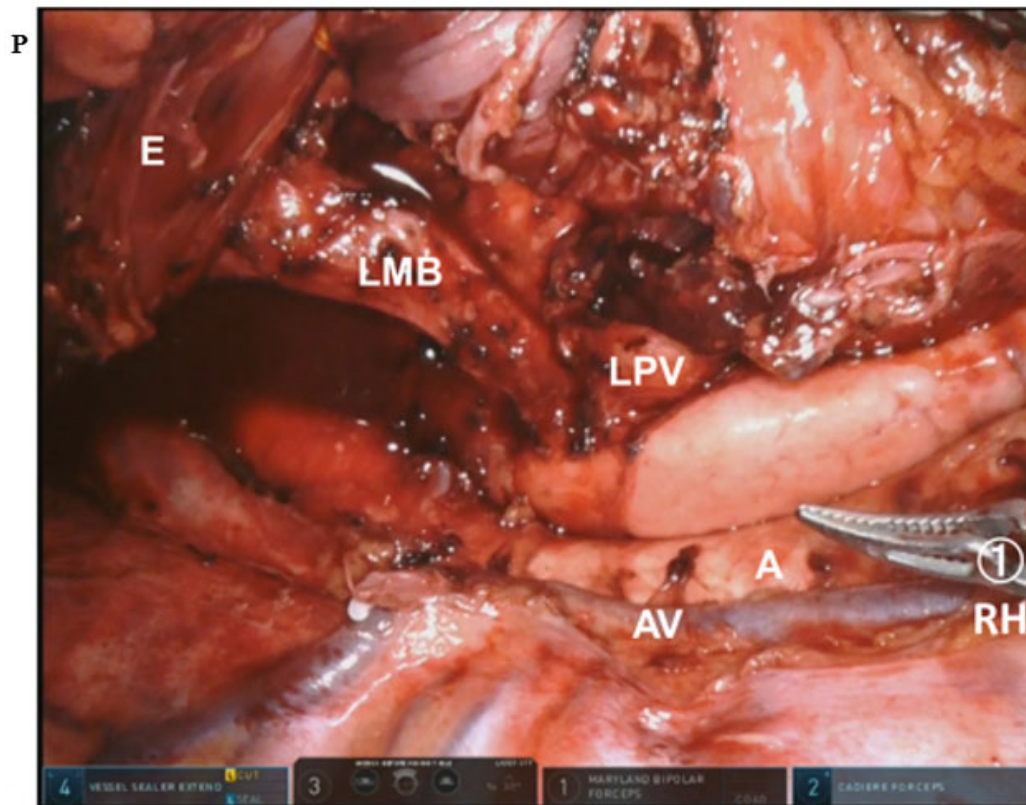
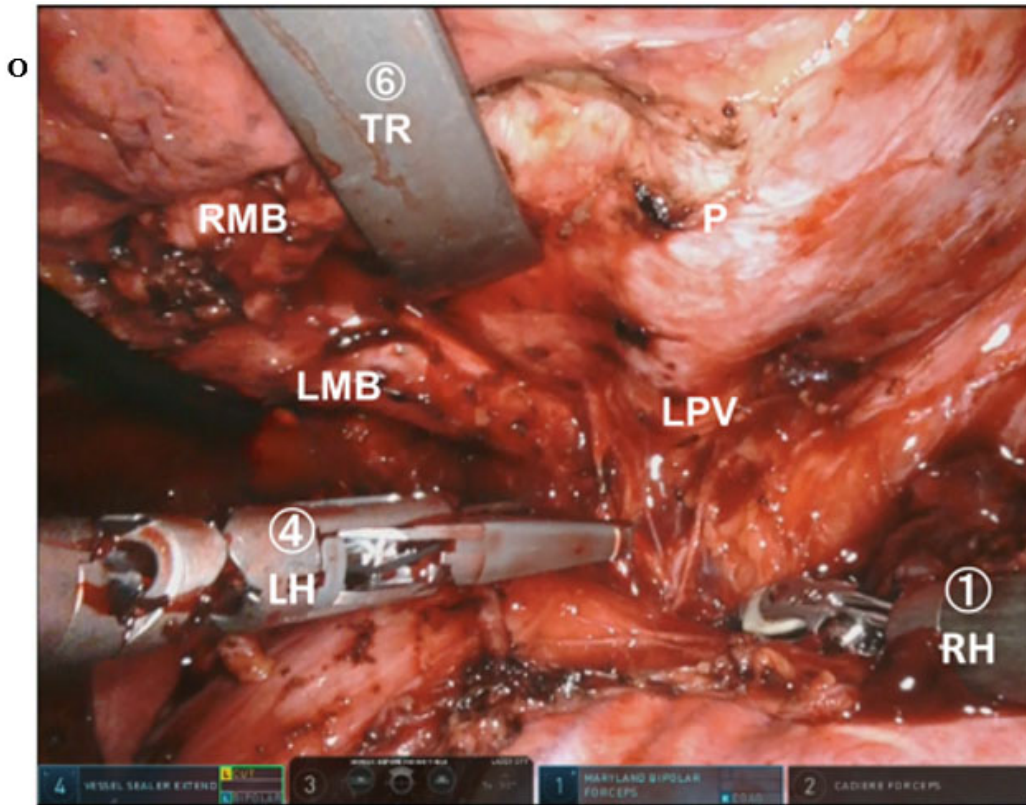


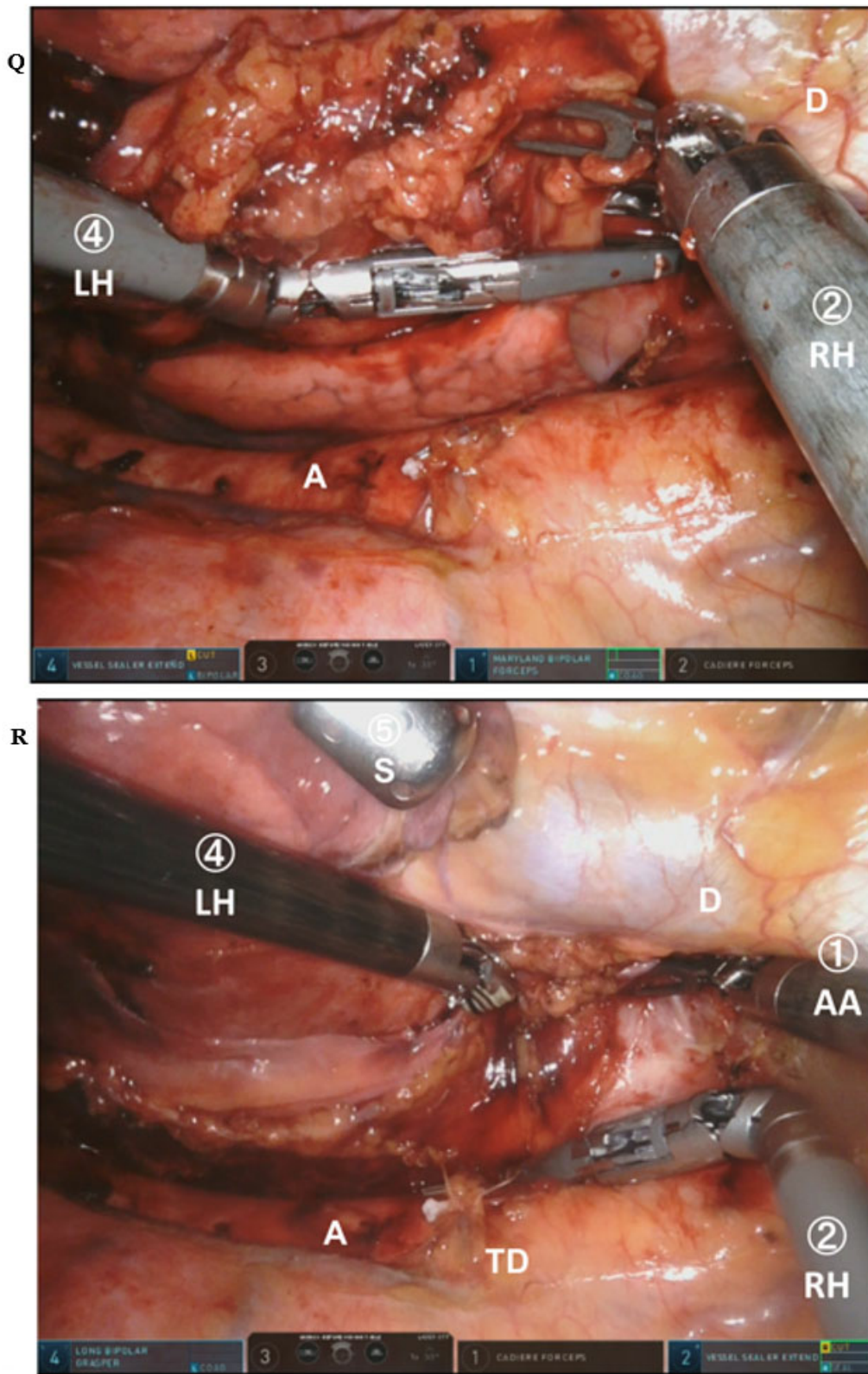
M



N







**Figure 4.** Mediastinal dissection procedure under robot-assisted thoracoscopic esophagectomy in: the right upper mediastinum (A-E); the left upper mediastinum (F-J); the sub-aortic arch area (K); the sub-carinal area (L-N); the left pulmonary hilum area (O,P); and the

lower mediastinum (Q,R). The robotic image is vertically and horizontally inverted by camera rotation to create a similar operative view to open thoracotomy. The left and upper sides of the monitor image are cranial and ventral, respectively. Encircled numeral corresponds to the port or arm number. The lymphatic tissue for dissection is encircled by a white dotted line. A: Aorta; AA: assistant arm; AV: azygos vein; D: diaphragm; E: esophagus; LH: left hand; LMB: left main bronchus; LRLN: left recurrent laryngeal nerve; MLN: metastatic lymph node; P: pericardium; PA: pulmonary artery; PB: pulmonary branch from vagal nerve; RH: right hand; RMB: right main bronchus; RRLN: right recurrent laryngeal nerve; S: suction; SCA: subclavian artery; T: trachea; TR: trachea retractor; VN: vagal nerve; TG: thyroid gland; LPV: left pulmonary vein; TD: thoracic duct.

just distal of the branching point of pulmonary branches [Figure 4L]. Subcarinal lymph nodes were dissected to expose the pericardium and bilateral main bronchus [Figure 4M and N].

### Dissection around left pulmonary hilum and lower mediastinum

To expose the left pulmonary hilum, we inserted a vessel sealer from cranial side and used it with the left hand [Figure 4O and P]. The usage of vessel sealer from cranial side enabled smooth dissection of left side of the mediastinum at middle and lower mediastinum [Figure 4Q]. For exhaustive dissection, we transected the thoracic duct and exposed the aortic wall by using a vessel sealer [Figure 4R].

### Postoperative outcomes

We performed RATE in LDP in 58 cases from July 2018 to May 2021. The average robot set-up time including port placement, console time, and thoracic blood loss was  $23.3 \pm 7.6$  min,  $255 \pm 64$  min, and  $135 \pm 126$  g, respectively. We experienced no conversion to thoracotomy regardless of the tumor stage. The majority of the patients, except those with stage IV disease, could achieve curative resection [Table 1]. We experienced a case with an accidental pull out of the esophageal branch from descending aorta during surgery. We successfully managed this serious aortic injury by direct suturing with the robotic platform [Figure 5].

Postoperative complications with Clavien-Dindo classification grade over 2 included 11 (19.0%) pneumonia, 4 (6.9%) recurrent laryngeal nerve palsy, 2 (3.4%) chylothorax, 14 (24.1%) anastomotic leakage, and 4 (6.9%) acute respiratory distress syndrome. There were no specific complications related to the use of a robot. We experienced one surgical mortality by postoperative aortic bleeding after a non-curative operation for advanced esophageal cancer with extensive aortic invasion.

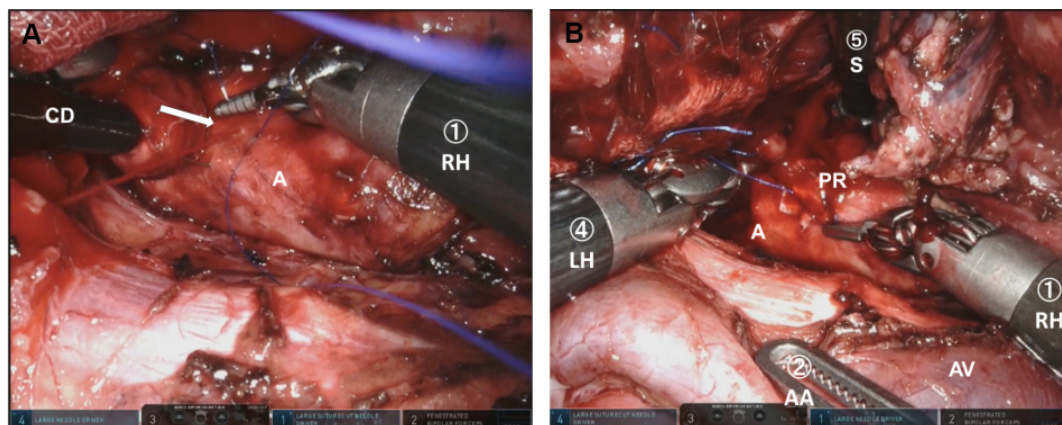
## DISCUSSION

Camera rotation and manual hand control assignment in RATE in the LDP reproduced the surgical view and manipulation achieved in open esophagectomy and TE in the LDP. In this manuscript, we present the actual dissection procedure for esophageal cancer. We performed RATE in LDP for safe management of intraoperative emergency and meticulous dissection of the upper mediastinum because LDP is recognized as the optimal position for emergency thoracotomy in patients with serious tracheobronchial or major vessel injuries<sup>[27,28]</sup>. Wide dissection is necessary in the long mediastinum for the curative surgery in esophageal cancer, unlike pelvic surgery for rectal and gynecological malignancies. In esophageal cancer surgery, upper mediastinal dissection is considered as the most important procedure because of the high incidence of metastasis around bilateral RLN, which should be manipulated gently to prevent postoperative hoarseness and mis-swallowing<sup>[29]</sup>. Thus, we focused on the upper mediastinal dissection in TE or RATE. Insertion of dissection scissors by the surgeon's right hand from the dorsal and caudal directions by TE in LDP enabled thorough dissection, especially in the left upper mediastinal region<sup>[27]</sup>. We can reproduce the dissection procedure of TE in LDP to perform RATE in LDP. Furthermore, the robotic platform has the advantage of enabling the surgeon to perform precise procedures in a deep narrow area such as the left side

**Table 1. Surgical outcomes of the 58 patients who underwent robot-assisted thoracoscopic esophagectomy**

Operation time (min), mean $\pm$ SD	
Total	609 $\pm$ 75
Thorax	309 $\pm$ 71
Robot setup time	23.3 $\pm$ 7.6
Console time	255 $\pm$ 64
Amount of blood loss (mL), mean $\pm$ SD	
Total	286 $\pm$ 187
Thorax	135 $\pm$ 126
No. of dissected lymph nodes, mean $\pm$ SD	
Total	58.3 $\pm$ 20.2
Thorax	27.1 $\pm$ 9.9
Conversion to thoracotomy, No. (%)	
	0 (0)
Curative resection according to pStage <sup>a</sup> , No. (%)	
pStage I ( <i>n</i> = 18) <sup>b</sup>	17 (94.4)
pStage II ( <i>n</i> = 9)	9 (100)
pStage III ( <i>n</i> = 17)	9 (100)
pStage IV ( <i>n</i> = 14)	8 (71.4)
Total ( <i>n</i> = 58)	51 (87.9)

<sup>a</sup>Tumor was staged according to the TNM classification of the American Joint Committee on Cancer and the Union Internationale Control le Cancer 8th edition; <sup>b</sup>one case with extensive oral intraepithelial spread within long-segment Barrett's esophagus showed positive oral margin. SD: Standard deviation; TNM: tumor nodes metastasis.



**Figure 5.** Hemostasis of bleeding from aorta by robotic platform: (A) direct suturing; and (B) hemostasis by ligation. Encircled numeral corresponds to the port or arm number. The arrow indicates the bleeding point. A: Aorta; AA: assistant arm; CD: cherry dissector; LH: left hand; PR: predjet; RH: right hand; S: suction; AV: azygos vein.

of the upper mediastinum due to the magnified three-dimensional view. Conversely, lower mediastinal dissection is easier with the patient in PP rather than in LDP because insertion of the dissection tool by the surgeon's right hand can be possible from the cranial direction in PP. However, there are no sensitive nerves to be preserved in lower mediastinum, and the metastasis in lower mediastinum is infrequent compared to in upper mediastinum<sup>[29]</sup>. Therefore, the dissection of lower mediastinum can be easily performed by using the surgeon's left hand in our procedure by RATE in LDP.

The most serious situation necessitating emergent thoracotomy include aorta and trachea-bronchial injury. We experienced one case of aortic bleeding by esophageal branch pull out during dissection around the aorta. This case was successfully managed without thoracotomy by direct suturing using 5-0 Prolene (Ethicon, Somerville, NJ, USA) with Cardiovascular Pledgets (Medtronic, Minneapolis, MN, USA). Only one additional port was inserted for the temporal hemostasis by compression with a cherry dissector. The robotic platform, with a three-dimensional view, articulation of instruments with seven degrees of freedom, tremor filtering, and hand control with a 3:1 motion scale, enabled direct suturing of the aorta and ligation with fine thread. Furthermore, the insertion of surgeon's right hand from caudal direction was ergonomically ideal for direct suturing of the aorta. It is noteworthy that the surgeon can choose any EndWrist usage by manual hand control assignment in the case of repairing aorta and/or trachea-bronchial injury in robotic surgery.

Many surgeons prefer PP to LDP when performing thoracoscopic esophagectomy and RATE because an adequate surgical view can be easily obtained without the assistant's effort. The limitation of RATE in LDP is the compressing of the lung and rotation of the trachea by an assistant using trachea retractor. Artificial pneumothorax by AirSeal insufflation system (ConMed) is useful in obtaining a good view without compressing the lung and diminishing the assistant's efforts. However, trachea retraction by the assistant is mandatory to retrieve left RLN lymph nodes situated left side of the trachea. Two-lung ventilation in PP using artificial pneumothorax may be ideal to expose lymph nodes around the trachea because trachea rotation can be easily performed with a soft single lumen tube, unlike the hard double-lumen tube used for single-lung ventilation<sup>[30]</sup>. We will try RATE with two-lung ventilation in the prone position set by bed rotation for current LDP with anterior tilting. Emergent thoracotomy may be easily performed by restoring body position with bed rotation. This modification may improve the easiness of left RLN dissection and contribute to a more meticulous dissection with reducing the assistant's effort. In addition, one of the ports for the assistant may be reduced.

## CONCLUSION

Our results indicate that RATE in LDP to reproduce the surgical view and manipulation consistent with open esophagectomy is useful for performing upper mediastinal dissection to secure emergent thoracotomy.

## DECLARATIONS

### Authors' contributions

Performed operation: Ninomiya I, Okamoto K

Written the manuscript: Ninomiya I

### Availability of data and materials

Not applicable.

### Financial support and sponsorship

None.

### Conflicts of interest

Both authors declared that there are no conflicts of interest.

### Ethical approval and consent to participate

All patients provided written informed consent before treatment, and the study was approved by the Ethics Committee of Kanazawa University Hospital. This work conforms to the guidelines set forth in the Helsinki Declaration of 1975 and later versions. This study was approved by Kanazawa University Hospital



(Approval No: 2019-295, June 19, 2020).

### Consent for publication

Not applicable.

### Copyright

© The Author(s) 2022.

### REFERENCES

1. Biere SS, van Berge Henegouwen MI, Maas KW, et al. Minimally invasive versus open oesophagectomy for patients with oesophageal cancer: a multicentre, open-label, randomised controlled trial. *Lancet* 2012;379:1887-92. DOI PubMed
2. Maas KW, Cuesta MA, van Berge Henegouwen MI, et al. Quality of life and late complications after minimally invasive compared to open esophagectomy: results of a randomized trial. *World J Surg* 2015;39:1986-93. DOI PubMed PMC
3. Yoshida N, Yamamoto H, Baba H, et al. Can minimally invasive esophagectomy replace open esophagectomy for esophageal cancer? *Ann Surg* 2020;272:118-24. DOI PubMed
4. van Hillegersberg R, Boone J, Draaisma WA, Broeders IA, Giezeman MJ, Borel Rinkes IH. First experience with robot-assisted thoracoscopic esophagolymphadenectomy for esophageal cancer. *Surg Endosc* 2006;20:1435-9. DOI PubMed
5. Weksler B, Sharma P, Moudgill N, Chojnacki KA, Rosato EL. Robot-assisted minimally invasive esophagectomy is equivalent to thoracoscopic minimally invasive esophagectomy. *Dis Esophagus* 2012;25:403-9. DOI PubMed
6. van der Sluis PC, Ruurda JP, van der Horst S, et al. Robot-assisted minimally invasive thoraco-laparoscopic esophagectomy versus open transthoracic esophagectomy for resectable esophageal cancer, a randomized controlled trial (ROBOT trial). *Trials* 2012;13:230. DOI PubMed PMC
7. Huang L, Onaitis M. Minimally invasive and robotic Ivor Lewis esophagectomy. *J Thorac Dis* 2014;6 Suppl 3:S314-21. DOI PubMed PMC
8. Amaral M, Pimiento J, Fontaine JP. Robotic esophagectomy: the Moffitt Cancer Center experience. *Ann Cardiothorac Surg* 2017;6:186-9. DOI PubMed PMC
9. Egberts JH, Stein H, Aselmann H, Hendricks A, Becker T. Fully robotic da Vinci Ivor-Lewis esophagectomy in four-arm technique-problems and solutions. *Dis Esophagus* 2017;30:1-9. DOI PubMed
10. Jin R, Xiang J, Han D, Zhang Y, Li H. Robot-assisted Ivor-Lewis esophagectomy with intrathoracic robot-sewn anastomosis. *J Thorac Dis* 2017;9:E990-3. DOI PubMed PMC
11. Nora I, Shridhar R, Meredith K. Robotic-assisted Ivor Lewis esophagectomy: technique and early outcomes. *Robot Surg* 2017;4:93-100. DOI PubMed PMC
12. van der Horst S, Weijs TJ, Ruurda JP, et al. Robot-assisted minimally invasive thoraco-laparoscopic esophagectomy for esophageal cancer in the upper mediastinum. *J Thorac Dis* 2017;9:S834-42. DOI PubMed PMC
13. Grimminger PP, Hadzijusufovic E, Ruurda JP, Lang H, van Hillegersberg R. The da Vinci Xi robotic four-arm approach for robotic-assisted minimally invasive esophagectomy. *Thorac Cardiovasc Surg* 2018;66:407-9. DOI PubMed
14. He H, Wu Q, Wang Z, et al. Short-term outcomes of robot-assisted minimally invasive esophagectomy for esophageal cancer: a propensity score matched analysis. *J Cardiothorac Surg* 2018;13:52. DOI PubMed PMC
15. Zhang Y, Xiang J, Han Y, et al. Initial experience of robot-assisted Ivor-Lewis esophagectomy: 61 consecutive cases from a single Chinese institution. *Dis Esophagus* 2018;31. DOI PubMed
16. Motoyama S, Sato Y, Wakita A, et al. Extensive lymph node dissection around the left laryngeal nerve achieved with robot-assisted thoracoscopic esophagectomy. *Anticancer Res* 2019;39:1337-42. DOI PubMed
17. Na KJ, Park S, Park IK, Kim YT, Kang CH. Outcomes after total robotic esophagectomy for esophageal cancer: a propensity-matched comparison with hybrid robotic esophagectomy. *J Thorac Dis* 2019;11:5310-20. DOI PubMed PMC
18. Kim DJ, Hyung WJ, Lee CY, et al. Thoracoscopic esophagectomy for esophageal cancer: feasibility and safety of robotic assistance in the prone position. *J Thorac Cardiovasc Surg* 2010;139:53-59.e1. DOI PubMed
19. Suda K, Ishida Y, Kawamura Y, et al. Robot-assisted thoracoscopic lymphadenectomy along the left recurrent laryngeal nerve for esophageal squamous cell carcinoma in the prone position: technical report and short-term outcomes. *World J Surg* 2012;36:1608-16. DOI PubMed
20. Puntambekar S, Kenawadekar R, Kumar S, et al. Robotic transthoracic esophagectomy. *BMC Surg* 2015;15:47. DOI PubMed PMC
21. Somashekhar SP, Jaka RC. Total (transthoracic and transabdominal) robotic radical three-stage esophagectomy-initial indian experience. *Indian J Surg* 2017;79:412-7. DOI PubMed PMC
22. Osaka Y, Tachibana S, Ota Y, et al. Usefulness of robot-assisted thoracoscopic esophagectomy. *Gen Thorac Cardiovasc Surg* 2018;66:225-31. DOI PubMed
23. Daiko H, Oguma J, Fujiwara H, et al. Robotic esophagectomy with total mediastinal lymphadenectomy using four robotic arms alone in esophageal and esophagogastric cancer (RETML-4): a prospective feasibility study. *Esophagus* 2021;18:203-10. DOI PubMed
24. Shirakawa Y, Noma K, Maeda N, Tanabe S, Sakurama K, Fujiwara T. Microanatomy-based standardization of left upper mediastinal

- lymph node dissection in thoracoscopic esophagectomy in the prone position. *Surg Endosc* 2021;35:349-57. DOI PubMed
25. Ninomiya I, Osugi H, Fujimura T, et al. Results of video-assisted thoracoscopic surgery for esophageal cancer during the induction period. *Gen Thorac Cardiovasc Surg* 2008;56:119-25. DOI PubMed
  26. Ninomiya I, Okamoto K, Yamaguchi T, et al. Optimization of robot-assisted thoracoscopic esophagectomy in the lateral decubitus position. *Esophagus* 2021;18:482-8. DOI PubMed
  27. Ninomiya I, Okamoto K, Fujimura T, Fushida S, Osugi H, Ohta T. Oncologic outcomes of thoracoscopic esophagectomy with extended lymph node dissection: 10-year experience from a single center. *World J Surg* 2014;38:120-30. DOI PubMed
  28. Markar SR, Wiggins T, Antonowicz S, Zacharakis E, Hanna GB. Minimally invasive esophagectomy: lateral decubitus vs. prone positioning; systematic review and pooled analysis. *Surg Oncol* 2015;24:212-9. DOI PubMed
  29. Udagawa H, Ueno M, Shinohara H, et al. The importance of grouping of lymph node stations and rationale of three-field lymphadenectomy for thoracic esophageal cancer. *J Surg Oncol* 2012;106:742-7. DOI PubMed
  30. Saikawa D, Okushiba S, Kawata M, et al. Efficacy and safety of artificial pneumothorax under two-lung ventilation in thoracoscopic esophagectomy for esophageal cancer in the prone position. *Gen Thorac Cardiovasc Surg* 2014;62:163-70. DOI PubMed