

Review

Open Access



# Principles of reconstruction. Like with like and flap thinning: two essential tools

Davide Ciclamini<sup>1</sup>, Leopoldo Arioli<sup>2</sup>, Francesco Giacalone<sup>1</sup>, Bruno Battiston<sup>1</sup> , Francesca Fissore<sup>1</sup>

<sup>1</sup>S.C. Orthopaedic and Traumatology II - Hand and Microsurgery Surgery Unit, AOU "Città della Salute e della Scienza di Torino", Turin 10100, Italy.

<sup>2</sup>"Sapienza" University of Rome - Orthopaedic and Traumatology Department of Sant'Andrea University Hospital, Rome 00189, Italy

**Correspondence to:** Dr. Davide Ciclamini, S.C. Orthopaedic and Traumatology II - Hand and Microsurgery Surgery Unit, AOU "Città della Salute e della Scienza di Torino", Via Zuretti 29, Turin 10100, Italy. E-mail: dciclamini@cittadellasalute.to.it

**How to cite this article:** Ciclamini D, Arioli L, Giacalone F, Battiston B, Fissore F. Principles of reconstruction. Like with like and flap thinning: two essential tools. *Plast Aesthet Res* 2023;10:62. <https://dx.doi.org/10.20517/2347-9264.2022.132>

**Received:** 18 Nov 2022 **First Decision:** 4 Sep 2023 **Revised:** 2 Oct 2023 **Accepted:** 30 Oct 2023 **Published:** 6 Nov 2023

**Academic Editors:** Raymund E. Horch, Adrian Dragu **Copy Editor:** Yanbing Bai **Production Editor:** Yanbing Bai

## Abstract

The "like with like" and the "flap thinning" are two workhorse principles the surgeon must keep in mind to achieve a functional and cosmetic reconstruction of the hand. These principles are underpinned by a thorough knowledge of anatomy and functional hand units, with a wide range of reconstructive procedures that must be finalized to the necessity of the impaired structures. "Like with like" means that a lost tissue must be replaced with another one that can be compared in appearance and function. In addition, good cosmetic is often associated with good function because the complex attempt to get a proper aesthetic always traduces itself into a better functional reconstruction. "Flap thinning" is essential because soft tissue injuries of the hand represent a more difficult reconstructive challenge than similar injuries elsewhere, and the need for thin tissue to wrap the superficial noble structures of the hand is constant. However, the procedure of thinning a flap can be dangerous and must adhere to the vascular architecture of the flap. This paper aims to review and briefly summarize the current literature in this field.

**Keywords:** Hand reconstruction, like-to-like flap, flap thinning



© The Author(s) 2023. **Open Access** This article is licensed under a Creative Commons Attribution 4.0 International License (<https://creativecommons.org/licenses/by/4.0/>), which permits unrestricted use, sharing, adaptation, distribution and reproduction in any medium or format, for any purpose, even commercially, as long as you give appropriate credit to the original author(s) and the source, provide a link to the Creative Commons license, and indicate if changes were made.



## INTRODUCTION

The management and reconstruction of soft tissue defects of the hand require a proper "mental approach", like that of an experienced handicraftsman. Experience, art, ability with your hands, a sense of beauty, and a sense of usefulness come together to help accomplish the task. This surgery aims to get both a functional and an aesthetical repair of tissue losses. The "like with like" principle summarizes unifying functional and aesthetic aspects. Unfortunately, the characteristics of the skin of the hand are particular, meaning that the function of the hand is very advanced and specific. As a fact, few other tissues around can replace the hand tissues without impairing function and at the same time mimicking its aesthetic properly. Therefore, thin flaps are always a prerequisite in hand repair. Given that a thin flap is not always the first choice for multiple reasons, the "flap thinning" technique helps optimize the transferred tissue to mimic and shape the hand skin.

## AESTHETIC AND FUNCTION

The aesthetic of the hand is well-known, depending mainly on its proportions, as described by Jakubietz *et al.*<sup>[1]</sup>. Painting of ancient artists such as Michelangelo, Leonardo Da Vinci, and others depicted wonderfully the correct proportions of the hand. The soft tissue envelope with a valid quantity of subcutaneous fat creates visible grooves, concavities, and prominences. The palmar skin is clear, hairless, sensible, thick and fixed, adherent to the palmar fascia, thus allowing the grip of the objects. On the opposite side, the dorsal skin is darker, partially hairy, less based on refined sensibility, relatively thin, pliable and extensible, allowing for movements of flexion and extensions, and tends to get even thinner with aging.

The function of the hand is always the main issue, typically not questioned when it comes to reconstruction. Del Pinal has described how to get a correct functional reconstruction of the hand for bone and soft tissues<sup>[2]</sup>. He also primarily affirms that a patient will use a mutilated/reconstructed hand only if it is tolerable to him/her, thus strongly connecting the functional results to the aesthetic aspects. In a reasonable prospect, the soft tissue reconstruction should allow the correct functioning of the bone (residual finger, hand cascade, tripod hand, amputated rays and stumps) and mobile structures (free or fused joints, residual flexor and extensor tendons). It should also apport the necessary sensibility, mainly in the fingers and palm. Flaps should also respect the main characteristics of palmar (thickness, fixed) and dorsal (thinness, elasticity) skin when possible.

## LIKE WITH LIKE

Considering these principles, trading function for a better appearance is not an option. Nevertheless, good cosmetic is often associated with good function because the complex attempt to get a proper aesthetic always traduces itself into a better functional reconstruction. Here is where "like with like" comes in handy.

### Palmar aspect

The surgeon must finalize the reconstruction of the palm and the palmar skin of the fingers to enable a pain-free grip, prevent adherence, and restore sensibility. At the same time, he should avoid loose skin, bulkiness, and complete numbness. Fasciocutaneous flaps with an excessive layer of fatty tissue, causing the "savonnage" effect (a French word meaning slipping or gliding) and looseness of the grip, should be avoided.

The skin of the fingers is the most difficult to reproduce because it perfectly wraps the shape of the fingers, giving adherence but also flexibility. There is no source of similar tissue in the body apart from the toes. As such, degloving injuries of fingers are the most difficult to repair, whereas amputated fingers can be replaced with toe transfers, thus obtaining a more cosmetic and functional hand. Adani *et al.* defined a clear

general guideline that is still a standard for degloving injuries of fingers: the replantation, when possible, gives the best results<sup>[3-7]</sup>. The original tissue of the patient is a wealth that, once lost, can never be achieved again. Toe transfer is a second option, especially for thumb reconstruction. Wrap-around<sup>[8]</sup> (CIT) or trimmed-toe<sup>[9]</sup> (CIT) flaps can also be a valuable option for some cases of amputated or degloved fingers, allowing excellent coverage with fewer donor site morbidity, since the P1 of the toe is preserved. Flaps with the best "like with like" principles are the last resource for multiple long fingers degloving. In the case of fingers, when possible, the best "like with like" always comes with a local flap from the hand or adjacent fingers. A pedicled reverse flow dorsal intermetacarpal artery propeller flap, even of considerable size, is a good option and relatively respects the "like with like" principle. Reverse dorsal digital island adipofascial flaps, like those described by Del Bene<sup>[10]</sup>, with or without split-thickness skin grafts (STSG), are ideal for slight palmar loss of the substance of fingers. When finding a local flap is impossible, a functional flap is the island pedicled reverse flow radial forearm flap, even though it is already a significant compromise for both the functional and the aesthetic aspects. Small free flaps or arterialized venous free flaps harvested from the volar part of the forearm, especially in thin patients, are suitable for volar reconstructions of fingers<sup>[11]</sup> [Figures 1, 2 and 3]. They can also provide sensory function when a superficial cutaneous nerve branches in the flap. In degloving finger injuries, it is virtually impossible to restore the sensibility. The avulsion of nerve pedicles sometimes results in the absence of innervation. In the case of the presence of nerve pedicles, even a primary nerve repair gives poor results, mainly out of the mechanism of injury and the different innervation of the transferred tissues.

The skin of the hand palm is thick, sensible and adherent, but fortunately, its shape is more straightforward to retrieve, and sensibility is less necessary compared to fingertips. Furthermore, in superficial injuries, a well-vascularized palm bed makes the reconstruction relatively simple since a full-thickness skin graft gives optimal results regarding adherence, proper thickness, and flexibility<sup>[12]</sup>. CIT. Tubiana, in 1996, described the functional cutaneous units of the palm<sup>[13]</sup>: the mobile units and the adherent ones, thus guiding the search for the best-replacing tissue. He also defined the units of tactile gnosis, distinguishing between primary, secondary, and tertiary regions of touch. Consequently, he prioritized the areas where the surgeon must restore the best sensibility from those areas of the palm where a lighter sensation is enough. However, in more profound and more extensive injuries, when tendons, vessels and nerves need to be covered, free muscle flaps with STSG are a valuable option. The gracilis free flap with STSG is optimal, with fast dissection time and minimal donor site morbidity. The initial bulkiness of muscle flaps does not represent a limit since denervated muscles get thinner over a short time. Unfortunately, sensibility remains an issue in free muscle flap reconstructions. The most extensive and complete palm loss of substance can benefit from the best "like with like" reconstruction of the palm. The medial plantar free flap is the gold standard to restore a perfect palm, with skin entirely similar to the palm skin and excellent sensibility thanks to the medial plantar nerve. Adani *et al.*<sup>[14]</sup> and Ono *et al.*<sup>[15]</sup> (CIT) summarized a clear reconstructive ladder of hand tissues with its major aims [Tables 1 and 2].

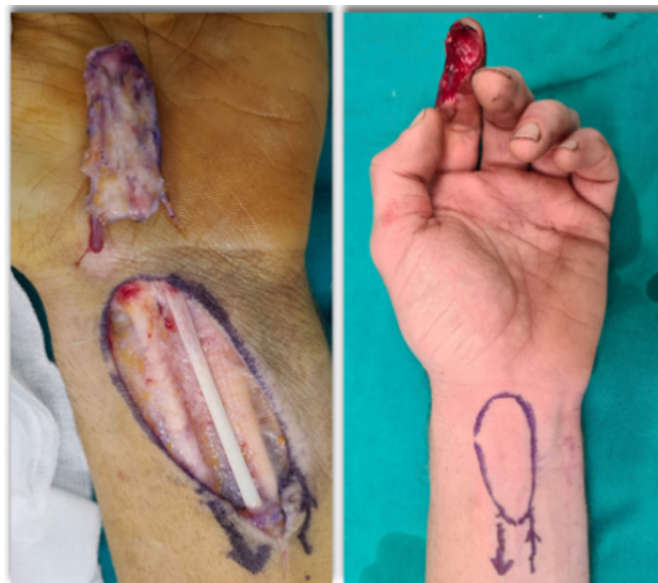It is challenging to achieve functional and aesthetic results in extensive degloving injuries of the whole palm and fingers, and the main goal remains the salvage of the limb. In eastern people, the free anterolateral thigh (ALT) perforator flap is an advantageous choice due to the inherent thin tissue characteristics of individuals in this region. On the other hand, the distal inferior epigastric perforator flap (DIEP flap) is more of an opportunity in Western people since it can be harvested over the Scarpa fascia, giving a thinner flap compared to the ALT. The superficial circumflex iliac artery flap (SCIP), the lateral arm flap (LAF), and the dorsalis pedis flap (DPF) are an option. The profunda artery perforator (PAP) flap can also be a very good alternative for large coverage of the hand, minimizing aesthetic damage, especially in young females, since sometimes the scars left by the ALT flaps are fairly acceptable<sup>[16]</sup>. (CIT) Syndactyly of all fingers is often

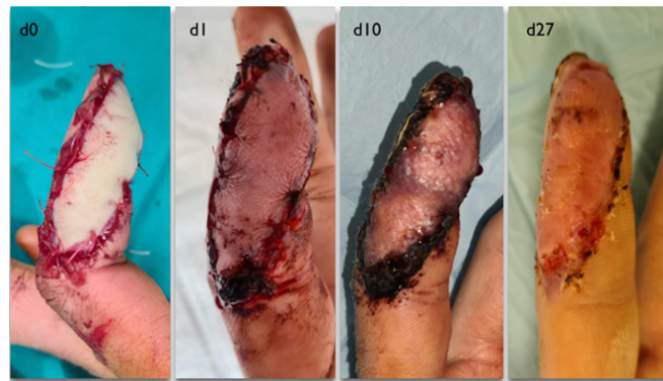**Table 1. Palm: reconstructive ladder and major aims**

Size / Wound	Tool	Sensibility	Stability	Stability and sensibility	Like to like	Donor site morbidity
Graftable	Skin graft with or without dermal substitute/ healing by second intention		x			
Small	Primary closure or local flaps			x	x	
Medium	Pedicle flaps (radial, ulnar and posterior interosseous flaps, and other perforator-based flaps)		x		x	x
	Free plantar flap			x	x	x
Large	anterolateral thigh flap (ALTF), the superficial circumflex iliac artery perforator flap (SCIPF)					
	Lateral arm flap (LAF) and Dorsalis pedis flap	x				x
	Gracilis muscle flap + graft		x			
	Free fascial flaps (temporal,serratus, radial fascial)		x			x

**Table 2. Dorsum: reconstructive ladder and major aims**

Size / Wound	Tool	Thin	Loose	Mobile	Like to like	Donor site morbidity
Graftable	Skin graft with or without dermal substitute/ healing by second intention	x				
Small	Primary closure or local flaps	x	x	x		
Medium	Pedicle flaps (radial, ulnar and posterior interosseous flaps, and other perforator-based flaps) also at fascial plane	x			x	x
Large	anterolateral thigh flap (ALTF), the superficial circumflex iliac artery perforator flap (SCIPF)		x	x		
	Lateral arm flap (LAF)	x	x	x		x
	Free fascial flaps (temporal,serratus, radial fascial)	x	x	x		x

**Figure 1.** Venous free flap for volar index soft tissue loss.



**Figure 2.** Evolution of venous flap postoperatively, day 1, day 10, and end of 3rd week.

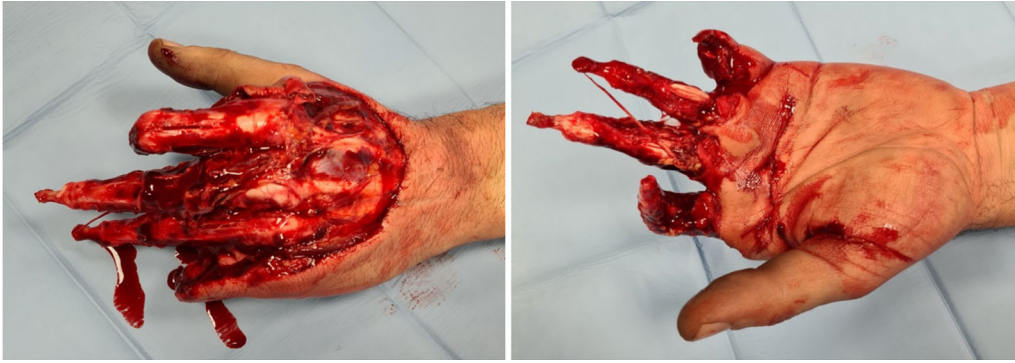

**Figure 3.** Aesthetic and functional outcome of venous flap at 2 months after surgical procedure.

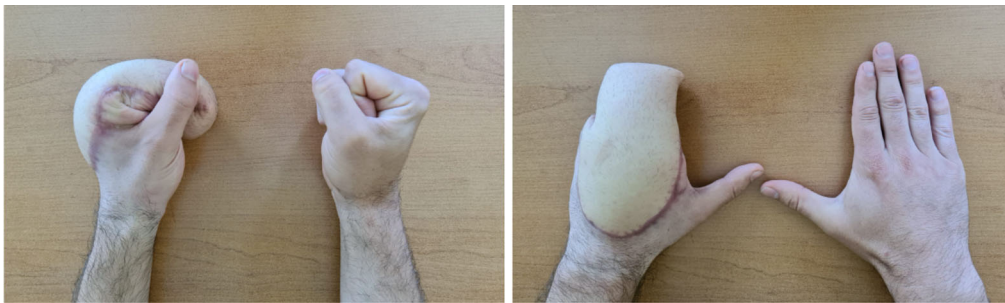
necessary for these reconstructions. We perform the separation of post-reconstructive syndactylies no earlier than a year after the trauma, giving patients time to get used to the new hand. Patients often prefer to keep syndactyly as they consider it a more functional hand [Figures 4 and 5]. Sensibility always remains the main drawback in huge degloving injury reconstruction.

### Dorsal aspect

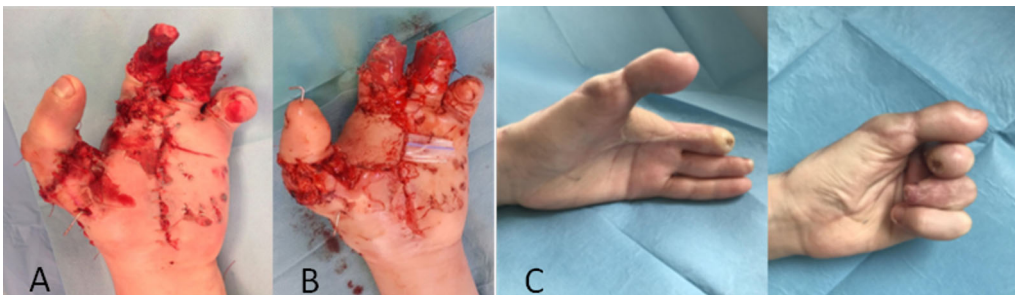
The dorsal skin of the hand and fingers is hairy, thin, pliable, and extensible, allowing flexion and extension of the fingers - the sensibility is no longer an issue. Thus, the surgeon must finalize the research of the ideal tissue mainly to thinness (for aesthetic reasons) and extensibility (for functional reasons). Therefore, the "like with like" principle gets far more manageable for the dorsal aspect. Skin grafts are not used here, except for some selected cases (e.g., coverage of the donor site of a kite flap, or coverage of relatively small defects where secondary graft retraction may not impair the extensor tendons gliding)<sup>[17]</sup> CIT, due to the poor aesthetic outcome and the risk of retraction, which is the main risk to be avoided. However, suppose a skin graft has to be applied. In that case, dermal substitutes with an FTSK over a well-vascularized bed may be helpful to minimize graft retraction and offer a thin reconstructive solution [Figure 6]. Deeper and larger wounds require free flaps. As per extensive palmar reconstruction of degloving injuries, the ALT flap is always too thick in Western people unless in very thin morphotypes. Therefore, ALT thinning during or



**Figure 4.** Degloving hand trauma



**Figure 5.** Thin ALT free flap at 1 year postoperative.



**Figure 6.** Degloved III-IV fingers (A). Coverage with dermal substitute and FTSK (B). Result after 6 months (C)

after flap harvesting can be an option, even though a wide pyramid area sometimes remains around the perforator piercing the fascia. The sandwich fascial ALT (SALT) free flap, raised harvesting between the Scarpa's fascia and the crural fascia, described by Cherubino *et al.*<sup>[18]</sup>, could offer a valuable option when choosing this reconstructive option. When harvested over the Scarpa's fascia, the DIEP flap provides a large tissue size and respects thinness and extensibility principles, especially in thin patients. Pure fascial flaps (like free temporal, serratus, or radial fascial flaps) are helpful, even though their use seems to become less frequent. Muscle flaps with STSG are always too bulky, and retraction over time represents a disadvantage in this scenario.

## FLAP THINNING

Unlike other regions of the body, which have a large skin surface, and subcutaneous and muscular tissue, allowing easy primary or secondary skin closure, the hand has nerves and tendons just beneath the skin

surface. Furthermore, interaction with the surrounding environment needs highly coordinated actions of a mobile and sensitive hand. Consequently, soft tissue injuries of the hand represent a more difficult reconstructive challenge for the surgeon than similar injuries elsewhere<sup>[19-21]</sup> - one of the main reasons for such a problematic condition is the need for thin tissue to wrap the superficial noble structures of the hand. Knowledge of vascular anatomy is fundamental to achieving this goal. Its development has inevitably led to innovations in flap design and clinical application, enabling improved aesthetic and functional results that today go beyond simply filling the defective area. The evolution of the flaps has followed a linear progression, primarily due to the pioneering studies of vascular anatomy<sup>[22-29]</sup> - flap thinning techniques rely on a deep and accurate knowledge of the most superficial vasculature of flaps.

Several thin loco-regional and free flaps are suitable for covering the hand, such as the cross-finger flap, kite flap, dorsal metacarpal artery flap, pedicled radial forearm flap, pedicled medial arm flap, pedicled and free posterior interosseous flap, medial plantar flap, and lateral arm fascia flap with a skin graft<sup>[30-32]</sup>. Unfortunately, other flaps with thick subcutaneous tissues are too bulky for upper-limb reconstruction. Nevertheless, many large and bulky flaps sometimes represent an inevitable choice in case of significant size defects. The flap-thinning technique was introduced in the 1960s to address this problem. Since then, this technique has been the focus of much attention and is still undergoing continuous evolution. However, secondary debulking procedures (fatty layer direct excision or liposuction some months after the first surgery) are still widespread. Some drawbacks include additional costs, impaired vascularization of the subdermal plexus, and multiple surgical stages.

A combination of improvements in surgical techniques and an appropriate description of the anatomy of the vascularization of flaps led to the elevation of a thinner flap in one stage. The flap can be harvested thinly from the beginning of the procedure by modifying the dissection plane or, once harvested, can be thinned through the removal of fat located at the superficial or deep fascial level. However, this procedure can be dangerous if performed without understanding the basic vasculature of the flap. Nakajima *et al.*, in 1998<sup>[28]</sup>, performed a three-dimensional analysis of the integument to understand this anatomy better. They divided the integument into three different layers: the deep and superficial adipofascial layer, below and above the superficial fascia, respectively, and the dermis. Based on this division of the skin, they classified the vascularisation of the skin and, consequently, the skin flaps into six types, providing basic knowledge about the characteristics of each type of flap and the method of defatting. Flaps with type IV (thoracodorsal artery, thoracoacromial artery, and deep inferior epigastric artery) and VI (perforators of the latissimus dorsi and gluteus maximus muscles) vasculature are ideal for flap thinning, according to Nakajima<sup>[28]</sup> and Park<sup>[33]</sup>. In this study, it appears that the DIEP flap can be thinned more effectively than, for example, the most discussed ALT flap, categorized as type III. However, many studies describe the harvest of even ultra-thin ALT flaps, but mainly from Asian countries<sup>[34]</sup>. Following cadaveric studies, some Authors do not suggest one-stage thinning of the ALT flap in the Western population, as this could lead to ischemia and skin necrosis<sup>[35]</sup> (CIT).

Since flap thinning began to be discussed, there has been confusion over the terminology used to talk about thin and super-thin flaps. There is no consensus regarding the definition of these terms in the literature. In 2021, Rios *et al.*<sup>[36]</sup> proposed a classification to provide a better understanding of the concepts [Table 3]<sup>[36]</sup>. In their literature review about supra-fascial free flaps, Rios *et al.*<sup>[36]</sup> also underlined the critical importance of preoperative imaging planning in flaps dissected above the deep or superficial fascia. Identifying a vascular pattern by CT-angiography<sup>[37]</sup> and ultra-high frequency ultrasound preoperatively<sup>[38]</sup> and hand-held acoustic Doppler or duplex ultrasound<sup>[37,38]</sup> allows us to recognize the perforating vessels in the supra-fascial plane. This preoperative awareness helps flap harvest, improves flap survival, shortens the operating time,

**Table 3. Flap classification based on dissection level by Rios *et al.*<sup>[36]</sup>**

	<b>Flap dissection</b>
Subfascial	below the deep muscle fascia
Suprafascial	above the deep muscle fascia and below the superficial adipose fascia
Thin	on the plane of the superficial adipose fascia
Super thin	above the superficial adipose fascia
Pure skin perforator flaps	only skin and subdermal plexus vessels

and allows thinner flaps with lower donor site morbidity<sup>[36-38]</sup>. Park<sup>[39]</sup> underlined two critical concepts in thinning procedures: the flap size and the defatting extension. Concerning the first item, he reported results of various clinical studies from which it emerges that the safe dimension of a thin flap is 17-18 cm<sup>[40]</sup>. As per the defatting extension, the second point has no clear answer in literature<sup>[39,41,42]</sup>. Many studies reported that preserving adipose tissue approximately 3 cm from the pedicle could be sufficient to protect intra-adiposal branches<sup>[28,43-45]</sup>.

## CONCLUSIONS

The "like to like" and the "flap thinning" are two workhorse principles the surgeon must keep in mind to achieve a functional and cosmetic reconstruction of the hand. In addition, the knowledge of functional cutaneous units of palm and units of tactile gnosis, together with palmar and dorsal skin characteristics, can prioritize the reconstruction. When larger-sized substance losses jeopardize the flap choice, knowledge of the architecture of the different layers of tissue helps to transform bulky flaps into more well-shaped tools. Remember that no tissue can replace the original one: a mean replantation is often better than a perfect secondary reconstruction.

## DECLARATIONS

### Authors' contributions

Made a substantial contribution to writing different sections of the paper: Ciclamini D, Fissore F, Arioli L

Provided literature research and analysis: Giacalone F, Battiston B

Provided clinical cases and pictures: Ciclamini D, Battiston B

Provided help revising the paper before submission: Fissore F, Ciclamini D

### Availability of data and materials

Not applicable.

### Financial support and sponsorship

None.

### Conflicts of interest

All authors declared that there are no conflicts of interest.

### Ethical approval and consent to participate

The study does not need the review board's approval since no ethical issues are involved. It is a review paper. Informed consent was obtained from the patients involved in this manuscript.

### Consent for publication

The study obtained WRITTEN consent from patients (Figures 1-5). The related files are in the clinical documentation of our institution and typically can not be copied or sent to editorial boards. Nevertheless,



written informed consent for publication was obtained.

## Copyright

© The Author(s) 2023.

## REFERENCES

1. Jakubietz RG, Jakubietz MG, Kloss D, Gruenert JG. Defining the basic aesthetics of the hand. *Aesthetic Plast Surg* 2005;29:546-51. [DOI](#) [PubMed](#)
2. del Piñal F. Severe mutilating injuries to the hand: guidelines for organizing the chaos. *J Plast Reconstr Aesthet Surg* 2007;60:816-27. [DOI](#)
3. Adani R, Castagnetti C, Landi A. Degloving injuries of the hand and fingers. *Clin Orthop Relat Res* 1995;314:19-25. [PubMed](#)
4. Ciclamini D, Tos P, Magistroni E, et al. Functional and subjective results of 20 thumb replantations. *Injury* 2013;44:504-7. [DOI](#)
5. Giardi D, Crosio A, Rold ID, et al. Long-term clinical results of 33 thumb replantations. *Injury* 2020;51 Suppl 4:S71-6. [DOI](#)
6. Ciclamini D, Panero B, Titolo P, Tos P, Battiston B. Particularities of hand and wrist complex injuries in polytrauma management. *Injury* 2014;45:448-51. [DOI](#) [PubMed](#)
7. Bueno RA Jr, Battiston B, Ciclamini D, Titolo P, Panero B, Tos P. Replantation: current concepts and outcomes. *Clin Plast Surg* 2014;41:385-95. [DOI](#) [PubMed](#)
8. Morrison WA, O'Brien BM, MacLeod AM. Thumb reconstruction with a free neurovascular wrap-around flap from the big toe. *J Hand Surg Am* 1980;5:575-83. [DOI](#) [PubMed](#)
9. Wei FC, Chen HC, Chuang CC, Noordhoff MS. Reconstruction of the thumb with a trimmed-toe transfer technique. *Plast Reconstr Surg* 1988;82:506-15. [DOI](#) [PubMed](#)
10. Del Bene M, Petrolati M, Raimondi P, Tremolada C, Muset A. Reverse dorsal digital island flap. *Plast Reconstr Surg* 1994;93:552-7. [DOI](#)
11. Yan H, Brooks D, Ladner R, Jackson WD, Gao W, Angel MF. Arterialized venous flaps: a review of the literature. *Microsurgery* 2010;30:472-8. [DOI](#) [PubMed](#)
12. Pensler JM, Steward R, Lewis SR, Herndon DN. Reconstruction of the burned palm: full-thickness versus split-thickness skin grafts--long-term follow-up. *Plast Reconstr Surg* 1988;81:46-9. [DOI](#) [PubMed](#)
13. Davis TRC. Examination of the Hand and Wrist Edited by R. Tubina, J.M. Thomine and E. Mackin. *J Hand Surg* 1996;21:289-90. [DOI](#)
14. Adani R, Tang JB, Elliot D. Soft and tissue repair of the hand and digital reconstruction. *J Hand Surg Eur Vol* 2022;47:89-97. [DOI](#) [PubMed](#)
15. Ono S, Sebastin SJ, Ohi H, Chung KC. Microsurgical flaps in repair and reconstruction of the hand. *Hand Clin* 2017;33:425-41. [DOI](#) [PubMed](#)
16. Boriani F, Sassu P, Atzeni M, Buckley C, Figus A. The profunda artery perforator flap for upper limb reconstruction: a case report and literature review on the flap applications in reconstruction. *Microsurgery* 2022;42:714-21. [DOI](#) [PubMed](#) [PMC](#)
17. Gloster HM Jr, Daoud MS, Roenigk RK. The use of full-thickness skin grafts for the repair of defects on the dorsal hand and digits. *Dermatol Surg* 1995;21:953-9. [DOI](#) [PubMed](#)
18. Cherubino M, Stocco C, Ronga M, et al. Comparisons of fascio-cutaneous anterolateral thigh and sandwich fascial ALT free flap in the distal extremity reconstruction. *Microsurgery* 2020;40:452-9. [DOI](#) [PubMed](#)
19. Friedrich JB, Katolik LI, Vedder NB. Soft tissue reconstruction of the hand. *J Hand Surg Am* 2009;34:1148-55. [DOI](#) [PubMed](#)
20. Miller EA, Friedrich J. Soft tissue coverage of the hand and upper extremity: the reconstructive elevator. *J Hand Surg Am* 2016;41:782-92. [DOI](#) [PubMed](#)
21. Saint-Cyr M, Gupta A. Indications and selection of free flaps for soft tissue coverage of the upper extremity. *Hand Clin* 2007;23:37-48. [DOI](#) [PubMed](#)
22. Cormack GC, Lamberty BG. Fasciocutaneous vessels. Their distribution on the trunk and limbs, and their clinical application in tissue transfer. *Anat Clin* 1984;6:121-31. [DOI](#) [PubMed](#)
23. Taylor GI, Palmer JH. The vascular territories (angiosomes) of the body: experimental study and clinical applications. *Br J Plast Surg* 1987;40:113-41. [DOI](#) [PubMed](#)
24. Taylor GI, Caddy CM, Watterson PA, Crock JG. The venous territories (venosomes) of the human body: experimental study and clinical implications. *Plast Reconstr Surg* 1990;86:185-213. [DOI](#) [PubMed](#)
25. Taylor GI, Palmer JH. 'Angiosome theory'. *Br J Plast Surg* 1992;45:327-8. [DOI](#) [PubMed](#)
26. Morris SF, Taylor GI. Predicting the survival of experimental skin flaps with a knowledge of the vascular architecture. *Plast Reconstr Surg* 1993;92:1352. [PubMed](#)
27. Tang M, Yin Z, Morris SF. A pilot study on three-dimensional visualization of perforator flaps by using angiography in cadavers. *Plast Reconstr Surg* 2008;122:429-37. [DOI](#) [PubMed](#)
28. Nakajima H, Minabe T, Imanishi N. Three-dimensional analysis and classification of arteries in the skin and subcutaneous adipofascial tissue by computer graphics imaging. *Plast Reconstr Surg* 1998;102:748-60. [DOI](#) [PubMed](#)

29. Pignatti M, Tos P, Garusi C, et al. A sequence of flaps and dissection exercises in the living model to improve the learning curve for perforator flap surgery. *Injury* 2020;51 Suppl 4:S22-30. [DOI](#)
30. Chen HC, Buchman MT, Wei FC. Free flaps for soft tissue coverage in the hand and fingers. *Hand Clinics* 1999;15:541-54. [DOI](#) [PubMed](#)
31. Battiston B, Ciclamini D, Tang JB. Compound or specially designed flaps in the lower extremities. *Clin Plast Surg* 2020;47:535-46. [DOI](#) [PubMed](#)
32. Battiston B, Vasario G, Ciclamini D, Rollero L, Tos P. Reconstruction of traumatic losses of substance at the elbow. *Injury* 2014;45:437-43. [DOI](#) [PubMed](#)
33. Park SO, Chang H, Imanishi N. Anatomic basis for flap thinning. *Arch Plast Surg* 2018;45:298-303. [DOI](#) [PubMed](#) [PMC](#)
34. Jeong HH, Hong JP, Suh HS. Thin elevation: a technique for achieving thin perforator flaps. *Arch Plast Surg* 2018;45:304-13. [DOI](#) [PubMed](#) [PMC](#)
35. Alkureishi LW, Shaw-Dunn J, Ross GL. Effects of thinning the anterolateral thigh flap on the blood supply to the skin. *Br J Plast Surg* 2003;56:401-8. [DOI](#)
36. Rios S, Falguera-uceda MI, Dean A, Heredero S. Suprafascial free flaps: classification and comprehensive review of the literature. *Craniofac Trauma Reconstr* 2021;6:247275122110205. [DOI](#)
37. Heredero S, Sanjuan A, Falguera MI, Dean A, Ogledzki M. The thin profunda femoral artery perforator flap for tongue reconstruction. *Microsurgery* 2020;40:117-24. [DOI](#) [PubMed](#)
38. Visconti G, Hayashi A, Yoshimatsu H, Bianchi A, Salgarello M. Ultra-high frequency ultrasound in planning capillary perforator flaps: preliminary experience☆. *J Plast Reconstr Aesthet Surg* 2018;71:1146-52. [DOI](#) [PubMed](#)
39. Park BY. Flap thinning: defatting after conventional elevation. *Arch Plast Surg* 2018;45:314-8. [DOI](#) [PubMed](#) [PMC](#)
40. Koshima I, Fukuda H, Yamamoto H, Moriguchi T, Soeda S, Ohta S. Free anterolateral thigh flaps for reconstruction of head and neck defects. *Plast Reconstr Surg* 1993;92:421-8; discussion 429-30. [DOI](#) [PubMed](#)
41. Luo S, Raffoul W, Luo J, et al. Anterolateral thigh flap: a review of 168 cases. *Microsurgery* 1999;19:232-8. [PubMed](#)
42. Kimata Y, Uchiyama K, Ebihara S, Nakatsuka T, Harii K. Anatomic variations and technical problems of the anterolateral thigh flap: a report of 74 cases. *Plast Reconstr Surg* 1998;102:1517-23. [DOI](#) [PubMed](#)
43. Nojima K, Brown SA, Acikel C, et al. Defining vascular supply and territory of thinned perforator flaps: part I. Anterolateral thigh perforator flap. *Plast Reconstr Surg* 2005;116:182-93. [DOI](#)
44. Agostini T, Lazzeri D, Spinelli G. Anterolateral thigh flap thinning: techniques and complications. *Ann Plast Surg* 2014;72:246-52. [DOI](#) [PubMed](#)
45. Kimura N, Satoh K. Consideration of a thin flap as an entity and clinical applications of the thin anterolateral thigh flap. *Plast Reconstr Surg* 1996;97:985-92. [PubMed](#)