

Review

Open Access



The benefit of combined radiofrequency and ultrasound to enhance surgical and nonsurgical outcomes for the face and neck

Christine A. Catinis¹, Suneel Chilukuri²

¹Department of Medicine, Louisiana State University School of Medicine, New Orleans, LA 70112, USA.

²Refresh Dermatology, Department of Dermatology, Baylor College of Medicine, Houston, TX 77081, USA.

Correspondence to: Prof. Suneel Chilukuri, Refresh Dermatology, Department of Dermatology, Baylor College of Medicine, Houston, TX 77081, USA. E-mail: chilukuri@refreshdermatology.com

How to cite this article: Catinis CA, Chilukuri S. The benefit of combined radiofrequency and ultrasound to enhance surgical and nonsurgical outcomes for the face and neck. *Plast Aesthet Res* 2020;7:9. <http://dx.doi.org/10.20517/2347-9264.2019.68>

Received: 4 Dec 2019 **First Decision:** 27 Dec 2019 **Revised:** 6 Feb 2020 **Accepted:** 20 Feb 2020 **Published:** 28 Feb 2020

Science Editors: John Yousif Kai, O. Kaye **Copy Editor:** Jing-Wen Zhang **Production Editor:** Tian Zhang

Abstract

As people live longer and stay healthier, many want to look as youthful as they feel. The general population continues to explore nonsurgical options to augment and possibly delay traditional rhytidectomy. Herein, we present a unique nonsurgical option to enhance our current modalities of neuromodulators and fillers commonly used on the face and neck. In addition, we discuss the ideal application of this technology including treatment times and intervals between treatments.

Keywords: Facelift, neck lift, nonsurgical, radiofrequency, ultrasound, fillers, Botox, neurotoxin

INTRODUCTION

Perhaps one of the most noticeable indicators of a person's age is the appearance of one's skin, particularly of the face and neck. Aging skin progressively becomes more wrinkled due to a loss of elasticity and volume over time. Other physical manifestations include uneven texture and discoloration due to sun damage. The increase in skin laxity is multifactorial and can be attributed to intrinsic factors, such as genetics, as well as extrinsic factors, such as UV exposure, gravity, and tobacco use^[1].

Physicians have traditionally relied on invasive procedures such as surgery and ablative skin resurfacing to combat the unwanted effects of skin aging. Over the last decade, however, noninvasive techniques have



© The Author(s) 2020. **Open Access** This article is licensed under a Creative Commons Attribution 4.0 International License (<https://creativecommons.org/licenses/by/4.0/>), which permits unrestricted use, sharing, adaptation, distribution and reproduction in any medium or format, for any purpose, even commercially, as long as you give appropriate credit to the original author(s) and the source, provide a link to the Creative Commons license, and indicate if changes were made.



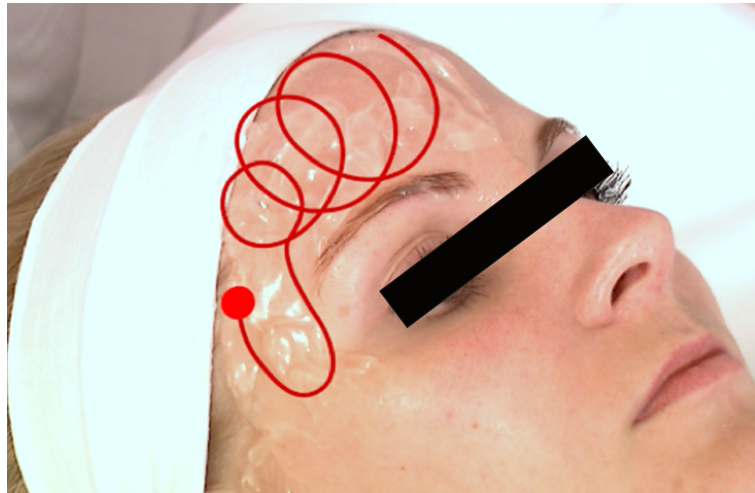


Figure 1. Treatment was started at the center part of the forehead and moved to the temporal region using slow, overlapping circular motions

greatly increased in popularity due to their effectiveness in improving skin laxity, while also minimizing recovery time, risk of adverse effects, and cost^[2,3]. Such noninvasive methods include radiofrequency (RF), ultrasound (US), and a variety of other energy-based and mechanical devices.

The application of RF to the skin generates heat at the level of the dermis by generating an oscillating current within the target tissue. The controlled heating of the dermis leads to the denaturation of the helical structure of collagen and an inflammatory response with subsequent activation of fibroblasts. As the collagen undergoes repair and remodeling, the dermal health improves with decreased skin laxity and increased elasticity^[4-7].

Ultrasound similarly induces dermal collagen synthesis and remodeling through the production of heat. The emission of sound waves through the tissue causes molecules to oscillate, which results in the production of thermal energy^[4,8].

Although the use of RF and US as individual modalities for the treatment of skin laxity has proven to be effective, the unique combination of the two in one handpiece allows shorter treatment times with more consistent results in our practice. The mechanical energy of ultrasound increases blood flow in the target tissue, which causes higher conductivity of the tissue and leads in homogenous heating of the area. In addition, ultrasound increases cell permeability, allowing the radiofrequency to have even more effect on fibroblast stimulation. The following details our modified treatment protocol that has improved patient outcomes.

METHODS

After applying a ground pad opposite to the upper right back, the facial skin was cleaned with one pass with alcohol-soaked gauze and then one pass with acetone-soaked gauze. Ultrasonic gel was applied and a combined radiofrequency and ultrasound applicator (small handpiece of the Exilis Ultra by BTL Industries Inc., Boston, MA) was used to heat the facial skin to a therapeutic temperature of 41-43 °C within 1-1.5 min. With very slow sweeping motions with downward pressure, the right forehead, temple, medial and lateral cheek, and jawline (maximum of 10 cm × 10 cm area) were treated, as shown in [Figures 1 and 2]. Settings for the forehead and temple were power of 90 and duty factor of 80. Settings for the cheek and jawline were power of 90 and duty factor of 100. After reaching therapeutic temperature, these areas were treated for a

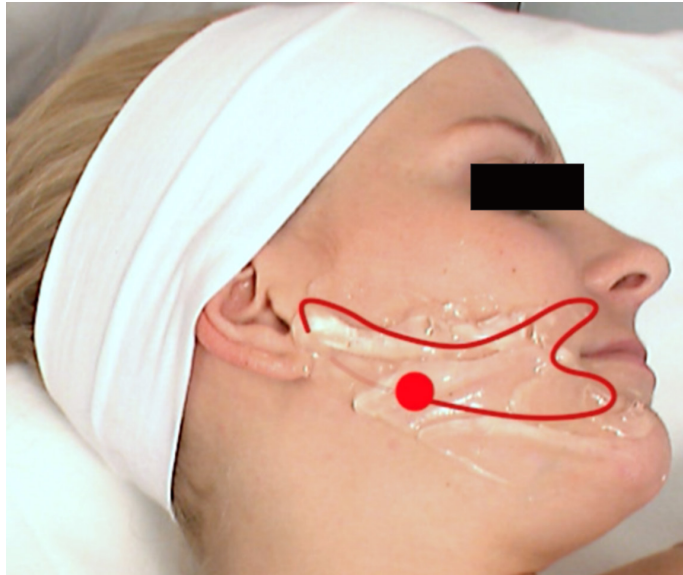


Figure 2. The applicator tip must be kept perpendicular to the treatment area while performing a very slow, large sweeping motion with some downward pressure. The soft tissue above the mandible was treated while avoiding direct treatment over the bone itself to ensure tolerability

total of 10 min. The contralateral forehead, temple, medial and lateral cheek, and jawline were then treated with the same protocol. The initial area was again heated to 41-43 °C and re-treated for 6 min at therapeutic temperature. The ultrasound gel was removed, and the patients were allowed to resume their routine skincare after 4 h. Included patients had no skin care regimen changes for a minimum of three months and were asked to refrain from altering their regimen until completion of the 12-month study. This protocol was repeated after two weeks. The results were examined at 3, 6, and 12 months post second treatment.

RESULTS

In total, 30 patients (all women, age range of 40-55, mean age of 49) were treated over a 1-year period. Patient surveys showed 100% satisfaction at three months after the initial two treatments and 93% satisfaction at 6 months. Patients felt that their skin was “brighter” and “less saggy”. No complications were seen. In addition, all patients found the procedure tolerable. A pain scale of 0 (no discomfort) to 5 (worst pain imaginable) was utilized. The average rating was 1.8.

[Figure 3](#) is an example of a patient three months after undergoing two treatments spaced two weeks apart.

DISCUSSION

The best aesthetic outcomes in the treatment of age-related skin laxity of the face and neck often arise from a combination of modalities over time. These modalities include invasive approaches such as surgery and noninvasive methods including RF, US, and injectable neuromodulators and fillers. The surgical facelift is considered the gold standard in the treatment of age-related skin laxity due to its long-lasting results^[9,10]. However, technological innovation is providing physicians and patients with novel noninvasive approaches. These new approaches have similar efficacy in combating skin laxity and have more favorable safety profiles. Regardless of which modality is chosen, the results of both invasive and noninvasive techniques can be enhanced and maintained by a combination of RF and US.

Radiofrequency exerts its effects by generating an oscillating electrical current within the target tissue. The current promotes collisions between ions and molecules in the dermal layer of the skin, leading to the

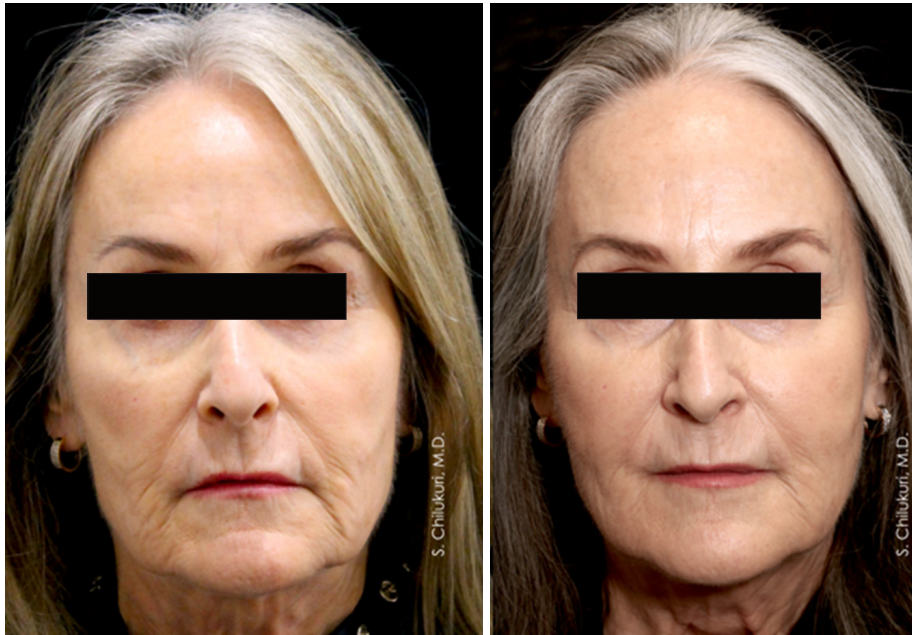

Figure 3. The right photo shows the patient three months after her second treatment with the protocol

formation of heat. In this way, RF produces thermal injury in the dermis, while preserving the integrity of the epidermis^[4,5]. The controlled heating of the dermis induces immediate collagen denaturation and subsequent fibroblast activation, leading to synthesis of new collagen and elastin fibers^[4,6,7]. The heat-induced contraction of the dermal layer tightens the skin while also increasing skin elasticity. The extent of tissue remodeling and contraction is dependent on a number of different variables. These include the depth of energy delivery, the time the desired temperature is maintained, the conductivity of the target tissue, and the frequency used^[4]. It has also been shown that the heat generated by RF can induce apoptosis of subcutaneous adipocytes^[4,8,11]. This finding has led to the extensive use of RF in body contouring and fat reduction, in addition to the treatment of skin laxity.

A novel two-treatment protocol using radiofrequency was proposed by McDaniel *et al.*^[12] in 2014. Each treatment began with 6 min on the lower face (sub malar region to the mandible), followed by treatment of the submentum for 4 min. The lower face was then treated again for 6 min, with 3 min spent on the sub malar region and 3 min spent on the mandible. Next, the submentum was treated again for 4 min. These steps were then repeated on the contralateral face. The two treatments were spaced 10-14 days apart. This approach demonstrated a marked improvement in skin laxity in the majority of subjects. The treatments were well tolerated by patients, with no reported side effects. Ninety-two percent of subjects showed measurable improvement in the tightness of their skin after being evaluated three months post-treatment, demonstrating that maintaining a lower skin temperature over a longer period of time produces more favorable results. The data obtained in this study also confirmed an overall improvement in skin density (19% increase in three months) as well as improvements in dermal collagen and elastin deposition.

Ultrasound functions through the emission of high frequency sound waves within the tissue. The propagating sound waves excite charged molecules in the dermal layer and cause them to oscillate. By increasing the energy of the underlying molecules, US results in the generation of heat in a similar manner to RF, leading to collagen denaturation and remodeling^[4,8]. When administered in combination with RF, US aids in efficiently and evenly dissipating the thermal energy to deeper skin layers by altering tissue resistance^[4].

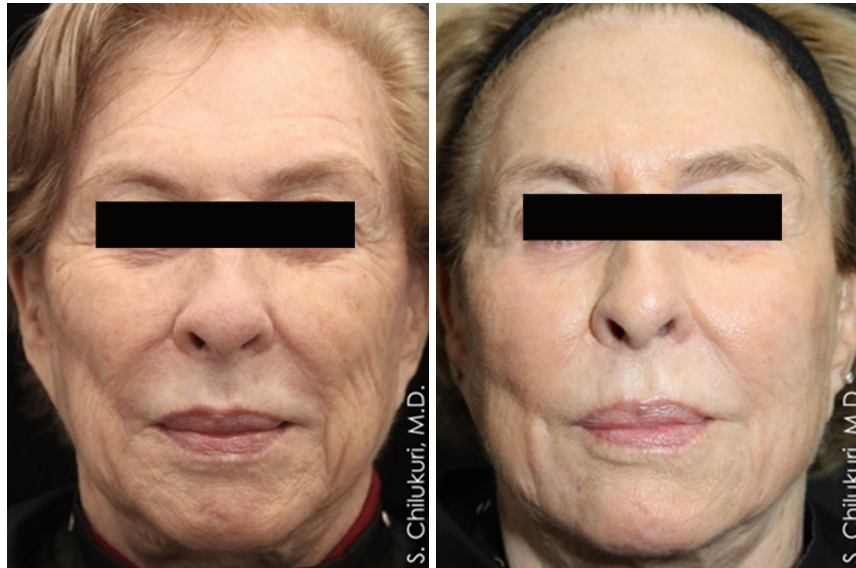

Figure 4. This patient is 83 years old in the left photo and 88 years old in the right photo. She was treated with the protocol described in the Method Section and then continued with single quarterly treatments. During this five-year interval, she only received a total of 1.5 cc of hyaluronic acid filler. The only other treatment she received during that time is neuromodulators

Combined focused monopolar RF and US in a single applicator improves noninvasive treatment of skin laxity and fat reduction^[5]. The mechanical energy of ultrasound increases blood flow in the target tissue, which causes higher conductivity of the tissue and leads in homogenous heating of the area. The other effect is to increase cell permeability - the mechanical energy or mechanical emission to the cells increases their responsivity to the treatment and the metabolic rate in the target area enables a faster and better response. The combined effect allows more rapid, uniform heating of the skin.

After reviewing the literature, we developed a modified treatment protocol using combined RF and US that has shown significant improvement in the maintenance and enhancement of both surgical and nonsurgical rejuvenation of the face and neck. We enhanced the double injury protocol first suggested by McDaniel *et al.*^[12]. The advantage of a slightly longer protocol (10 min *vs.* 6 min) to uniformly heat the collagen to the ideal therapeutic temperature of 41-42 °C has proven to be comfortable and safe for the patient. By pausing for approximately 10 min before treating a second time for 6 min during the same visit, the chance of overheating and permanently denaturing collagen is reduced. After this initial injury, inflammatory cells including neutrophils and macrophages remove cellular debris before the second phase of repair begins. The tissue proliferation phase utilizes growth factors to increase fibroblast activity and subsequent collagen production. This second phase typically peaks at Day 6 or 7 with inflammatory cell response decreasing by Days 11-14. By repeating the RF/US protocol at two weeks, we suspect a sustained inflammatory response leads to greater tissue remodeling. In our practice, we performed a pilot split face study where one side of the face was treated with four sessions while the other side was treated according to the Method Section above. No visible difference was noted in 2D photography. When compared to other radiofrequency devices with protocols recommending three to five treatments, patients are pleased that fewer treatments are needed to obtain similar clinical results. In clinical practice, we routinely re-assess patients at three months after the second treatment and determine if he or she would benefit from another combined RF/US treatment or if other modalities can be utilized to enhance outcomes. We have found that our need for injectable fillers and collagen-stimulators has decreased in those patients who are receiving maintenance treatments 2-4 times per year. One such patient is the 88-year-old woman in [Figure 4](#).

There are several limitations to this unfunded pilot study. Only thirty subjects were treated, and no FDA-approved photometric scale was utilized. Biopsies were not performed to histologically quantify collagen

and elastin improvement. Future prospective studies with double-blinded investigators are indicated. In addition, there are numerous devices that may improve skin quality. Direct comparisons to these devices may be useful for physicians and health care providers.

We found this revised treatment protocol provides significant improvement in combating age-related changes in the face and neck, as a primary treatment, as post-surgical maintenance, and/or as enhancement to neuromodulators and fillers. The advantage of this device is that there is no down time, as seen with ablative lasers. However, in those patients with deep rhytids and severe actinic damage, laser resurfacing may be utilized first and the combined RF/US can be used to consistently enhance and maintain results. As with all aesthetic medicine, protocols should be customized to best benefit the patient.

DECLARATIONS

Authors' contributions

Made substantial contributions to conception and design of the study and performed data analysis and interpretation: Chilukuri S

Drafted the article and revised it critically for important intellectual content: Catinis CA

Availability of data and materials

Not applicable.

Financial support and sponsorship

None.

Conflicts of interest

Both authors declared that there are no conflicts of interest.

Ethical approval and consent to participate

Not applicable.

Consent for publication

Consent was obtained for all patients.

Copyright

© The Author(s) 2020.

REFERENCES

1. Shah AR, Kennedy PM. The aging face. *Med Clin North Am* 2018;102:1041-54.
2. Chilukuri S, Lupton J. "Deep Heating" noninvasive skin tightening devices: review of effectiveness and patient satisfaction. *J Drugs Dermatol* 2017;16:1262-6.
3. Fritz M, Counters JT, Zelickson BD. Radiofrequency treatment for middle and lower face laxity. *Arch Facial Plast Surg* 2004;6:370-3.
4. Chilukuri S, Denjean D, Fouque L. Treating multiple body parts for skin laxity and fat deposits using a novel focused radiofrequency device with an ultrasound component: safety and efficacy study. *J Cosmet Dermatol* 2017;16:476-9.
5. Bonjorno AR, Gomes TB, Pereira MC, de Carvalho CM, Gabardo MCL, et al. Radiofrequency therapy in esthetic dermatology: a review of clinical evidences. *J Cosmet Dermatol* 2019;19:278-81.
6. Zelickson BD, Kist D, Bernstein E, Brown DB, Ksenzenko S, et al. Histological and ultrastructural evaluation of the effects of a radiofrequency-based nonablative dermal remodeling device: a pilot study. *Arch Dermatol* 2004;140:204-9.
7. Weiss RA. Noninvasive radio frequency for skin tightening and body contouring. *Semin Cutan Med Surg* 2013;32:9-17.
8. Fabi SG. Noninvasive skin tightening: focus on new ultrasound techniques. *Clin Cosmet Investig Dermatol* 2015;8:47-52.
9. Jones BM, Lo SJ. How long does a face lift last? Objective and subjective measurements over a 5-year period. *Plast Reconstr Surg* 2012;130:1317-27.
10. Hammoudeh ZS, Stevens WG. Nonsurgical adjuncts following facelift to achieve optimal aesthetic outcomes: "icing on the cake". *Clin Plast Surg* 2019;46:613-23.

11. McDaniel D, Fritz K, Machovcova A, Bernardy J. A focused monopolar radiofrequency causes apoptosis: a porcine model. *J Drugs Dermatol* 2014;13:1336-40.
12. McDaniel D, Weiss R, Weiss M, Mazur C, Griffen C. Two-treatment protocol for skin laxity using 90-Watt dynamic monopolar radiofrequency device with real-time impedance intelligence monitoring. *J Drugs Dermatol* 2014;13:1112-7.