


Original Article

Open Access



# Pressure resistance evaluation in esophagojejunostomy using the transorally inserted anvil (OrVil™)

Suguru Yamauchi<sup>1,2</sup> , Satoshi Kanda<sup>1</sup>, Hajime Orita<sup>1</sup>, Yutaro Yoshimoto<sup>1</sup>, Akira Kubota<sup>1</sup>, Kenki Tsuda<sup>1</sup>, Yukinori Yube<sup>1</sup>, Sanae Kaji<sup>1</sup>, Malcolm V. Brock<sup>2</sup>, Shinji Mine<sup>1</sup>, Tetsu Fukunaga<sup>1</sup>

<sup>1</sup>Department of Esophageal and Gastroenterological Surgery, Juntendo University Faculty of Medicine, Tokyo 113-8431, Japan. <sup>2</sup>Department of Surgery, Johns Hopkins University School of Medicine, Baltimore, MD 21287, USA.

**Correspondence to:** Dr. Suguru Yamauchi, Department of Esophageal and Gastroenterological Surgery, Juntendo University Faculty of Medicine, 3-1-3 Hongo, Bunkyo-Ku, Tokyo 113-8431, Japan. E-mail: s.yamauchi.gk@juntendo.ac.jp

**How to cite this article:** Yamauchi S, Kanda S, Orita H, Yoshimoto Y, Kubota A, Tsuda K, Yube Y, Kaji S, Brock MV, Mine S, Fukunaga T. Pressure resistance evaluation in esophagojejunostomy using the transorally inserted anvil (OrVil™). *Mini-invasive Surg* 2023;7:17. <https://dx.doi.org/10.20517/2574-1225.2022.116>

**Received:** 16 Dec 2022 **First Decision:** 7 Apr 2023 **Revised:** 10 Apr 2023 **Accepted:** 19 Apr 2023 **Published:** 10 May 2023

**Academic Editors:** Fernando A. M. Herbella, Itasu Ninomiya, Giulio Belli **Copy Editor:** Ke-Cui Yang **Production Editor:** Ke-Cui Yang

## Abstract

**Aim:** The transorally inserted anvil (OrVil™) is often selected for esophagojejunostomy after total laparoscopic gastrectomy due to its versatility. During anastomosis with OrVil™, it is possible to select a double stapling technique (DST) or a hemi-double technique (HDST) by overlapping the linear stapler and the circular stapler, although there has been no report on the anastomotic strength. Thus, an animal experiment was conducted and verified this study.

**Methods:** This experiment used 10 fresh porcine esophageal and jejunal specimens. Two models were created: a model in which the rod is placed at the center of the esophageal transection line (DST model) and a model in which the rod is placed at the lateral end of the esophageal transection line (HDST model). A pressure gage was inserted into the anastomosed intestine while continuously measuring pressure to determine the leakage site and leakage pressure.

**Results:** The leakage site in both the DST ( $n = 5$ ) and HDST models ( $n = 5$ ) were at the staple overlapping with a leakage pressure of  $151.2 \pm 14.2$  mmHg in the DST model and  $148.2 \pm 6.3$  mmHg in the HDST model ( $P = 0.678$ ). When the leakage site was repaired with hand-sewn sutures and conducted remeasuring pressure, leakage was observed from the contralateral crossing in the DST model and the leakage pressure was  $155.8 \pm 12.2$  mmHg. In the



© The Author(s) 2023. **Open Access** This article is licensed under a Creative Commons Attribution 4.0 International License (<https://creativecommons.org/licenses/by/4.0/>), which permits unrestricted use, sharing, adaptation, distribution and reproduction in any medium or format, for any purpose, even commercially, as long as you give appropriate credit to the original author(s) and the source, provide a link to the Creative Commons license, and indicate if changes were made.



HDST model, all models were capable of withstanding 300-mmHg pressures.

**Conclusion:** HDST with a single staple intersection is beneficial for esophagojejunostomy, in terms of pressure resistance, and the repairing suture at the staple intersection can increase pressure resistance.

**Keywords:** Esophagojejunostomy, gastric cancer, reconstruction, OrVil™, double stapling, hemi- double stapling, pressure resistance

## INTRODUCTION

Several mechanical stapling model devices have been used in various gastrointestinal surgery, especially laparoscopic surgery. Laparoscopic distal gastrectomy has been widely performed in Japan and East Asian countries in recent years as a minimally invasive operation for gastric cancer. Laparoscopic total gastrectomy (LTG) has also been performed for gastric cancers mainly located in the upper and third of the stomach and esophagogastric junction<sup>[1]</sup>. However, LTG has not been a standard procedure for gastric cancer due to the technical difficulties associated with procedures<sup>[2]</sup>. Esophagojejunostomy is the most difficult and crucial procedure involved in LTG. Esophagojejunal anastomotic leakage is considered to be one of the most serious complications after total gastrectomy (TG)<sup>[3]</sup>. The reported esophagojejunal anastomotic leakage rates after TG vary from 0.9% to 17%<sup>[4]</sup>. Esophagojejunal anastomotic leakage has a negative impact on postoperative outcomes by increasing pulmonary complications, length of time to resume oral intake, median hospital stay length, anastomotic stricture risk, and the need for re-operation. Esophagojejunal anastomotic leakage is the leading cause of mortality-related death after this procedure<sup>[5]</sup>. Furthermore, esophagojejunal anastomotic leakage is an independent prognostic factor for poor survival after gastric cancer surgery<sup>[6]</sup>. Intracorporeal circular stapling esophagojejunostomy using OrVil™ was developed to simplify the reconstruction procedure after TG<sup>[7]</sup>. Circular stapling esophagojejunostomy is the most frequently performed reconstruction method in conventional TG in laparotomy. Surgeons are accustomed to using circular staplers, achieving stable results in conventional surgery; hence, several groups have reported circular staplers use in LTG, and esophagojejunostomy with a circular stapler is indicated for LTG as well as laparotomy. When performing anastomosis with OrVil™, we can choose the double stapling technique (DST) or the hemi-double stapling technique (HDST), depending on the rod out position. This difference has important implications, such as whether a linear stapler and a circular stapler overlap in two or one places. It has been reported that this staple intersection may cause anastomotic leakage and stenosis, although there are no actual reports of OrVil™ use and direct comparison between DST and HDST<sup>[8,9]</sup>. In this study, porcine was used to focus on the pressure resistance of DST and HDST in esophagojejunostomy using OrVil™.

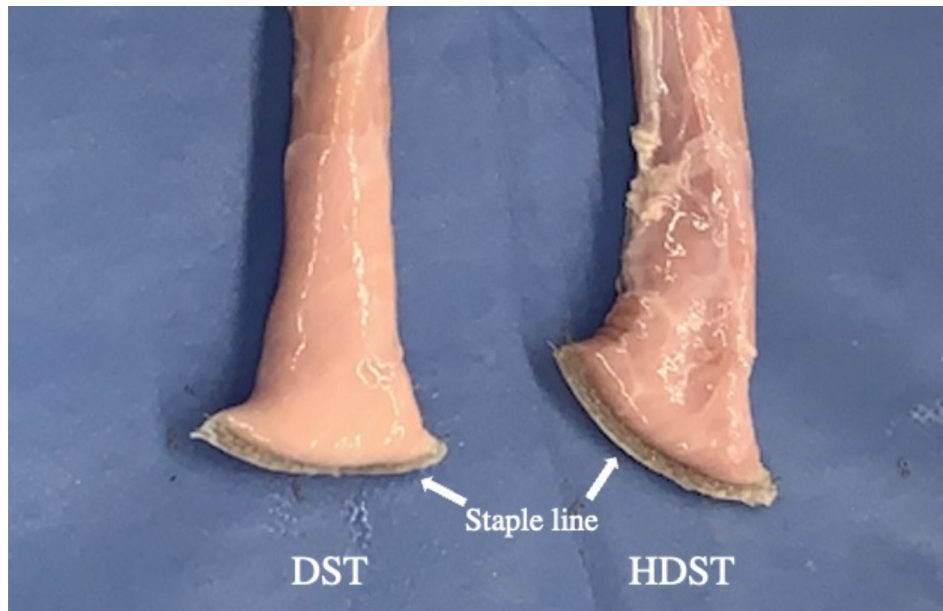
## METHODS

### Materials

The esophagus and jejunum from adult edible porcine were used in this study. Tokyo Shibaura Organ Co, Ltd. provided the organs. After specimens were sacrificed, they were refrigerated at 4 °C and thawed naturally 3-4 h prior to the start of the experiment. The esophagus and jejunum were each 20 cm and 30 cm in length, respectively, and 10 models each were prepared.

### Surgical instruments

A powered linear stapler (Signia™ Powered stapling System with Tri-Staple™ technology reloads [Covidien, USA]) was used for esophagectomy and jejunostomy. Transorally inserted anvil (OrVil™; Covidien, USA) and DST series™ EEA™ XL 25 staple device (Covidien, USA) were used for esophagojejunostomy. Sonicision™ Curved Jaw (Covidien, USA) was used to dissect the intestine as an ultrasonic dissection



**Figure 1.** Esophagotomy. A 60-mm linear stapler was used to dissect the esophagus. In the DST case, the dissection was made orthogonally to the esophagus, whereas in HDST, the dissection was made at a slight angle to the esophageal long axis. DST: double stapling technique; HDST: hemi-double technique.

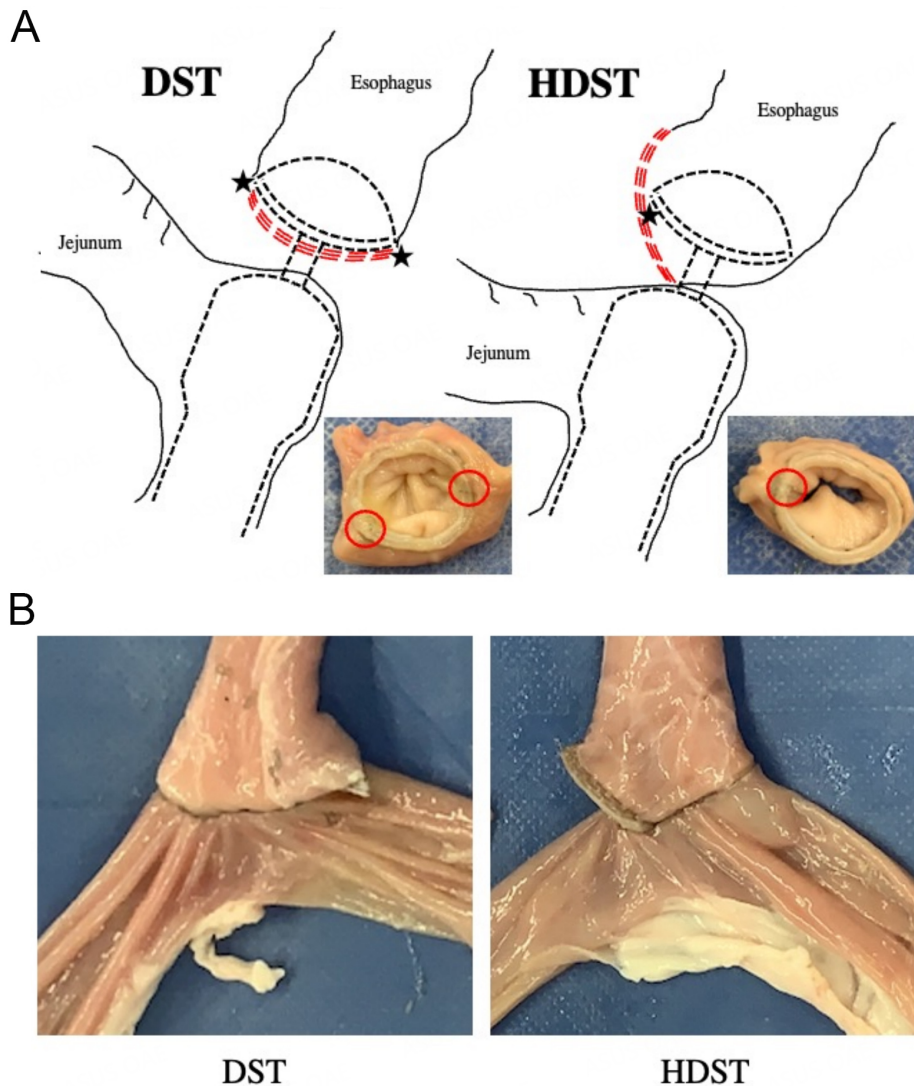
system. A 3-0 Polysorb™ (Covidien, USA) was used to reinforce the sutures at the anastomotic leakage point.

### Esophagojejunostomy

A 60-mm linear stapler (LS) was used to dissect the esophagus and jejunum. In the DST case, dissection was made orthogonally to the esophagus, whereas in HDST, dissection was made at a slight angle to the esophageal long axis [Figure 1]. The OrVil™ was inserted into the oral esophageal lumen and the tube tip was guided to the esophageal staple stump. In DST, a small hole was created at the center of the esophageal transection line with a laparoscopic ultrasonic dissection system. In HDST, a small hole was created at the lateral end of the esophageal transection line. The guide tube was pulled out through the small hole until the anvil reached the esophageal stump. When the center rod's plastic collar came out, then, one side of the anvil holding thread was cut and the tube from the anvil was removed. Consequently, the anvil was fixed to the esophageal stump. An incision was made at the blind end of the jejunum and the EEA™ circular stapler (CS) was inserted into the jejunum. The CS insertion length into the jejunum was approximately 10 cm and it was fixed with a vessel loop. The CS' center rod was pulled out from the center of the jejunum. The anvil and CS were connected and fired [Figure 2A]. The blind end of the jejunum was closed with a 60-mm LS to complete the esophagojejunostomy [Figure 2B].

### Pressure resistance evaluation

A 16-Fr catheter tip was placed near the esophageal-jejunal lumen anastomosis. Each side of the esophagus and jejunum was clamped by Pean forceps. The electronic manometer and tubing for the air installation were connected and the anastomosis was submerged in water [Figure 3]. Air was then blown into the intestine with a syringe. An electronic manometer (PG-100; Copal Electronics, Tokyo, Japan) was used to measure leakage pressure at the moment the air leak began. The anastomotic region's leakage pressure was indicated by the presence of air bubbles [Movie 1]. Pressure resistance was defined as leakage pressure. Simultaneously, the area where the leakage occurred was confirmed and recorded visually. Next, the site

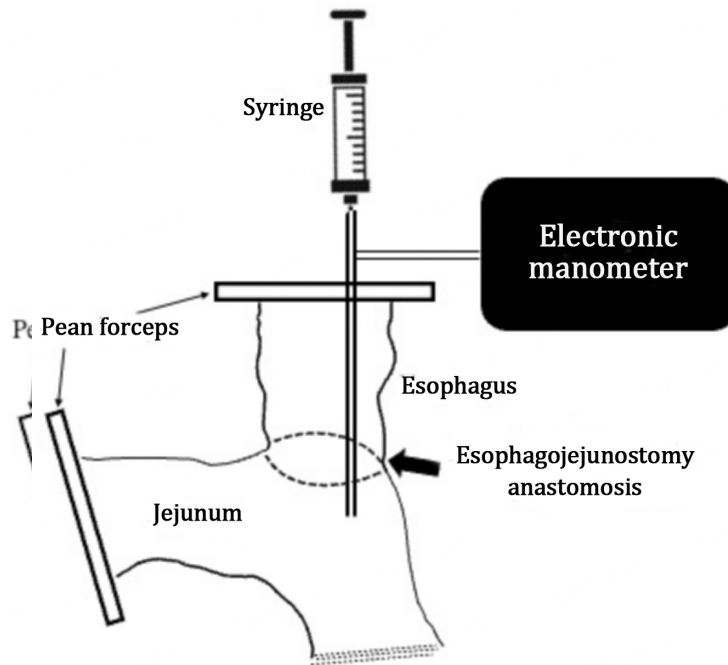


**Figure 2.** (A) Schematic of DST and HDST with OrVil™. The black star symbol indicates staple intersections (overlapping). DST creates two intersections on each side, while HDST creates only one; (B) esophagojejunostomy. DST: double stapling technique; HDST: hemi-double technique.

where anastomotic leakage was observed was then repaired with hand-sewn sutures using absorbable braided sutures. Pressure resistance was reevaluated using the same procedure. In the present study, the pressure resistance capacity was evaluated to be up to 300 mmHg. All procedures were performed by the same surgeon and leakage evaluations were reviewed simultaneously by three surgeons. This experiment was first compared between the HDST and DST models, and then between the repaired DST model (rDST model) and the repaired HDST model (rHDST model).

### Statistical analysis

The JMP software version 16.0.0 (Cary, NC: SAS Institute Inc.) was used to perform statistical analysis. In descriptive statistics, continuous data were shown as mean  $\pm$  SD. Two-sided *P* values  $< 0.05$  was considered to be statistically significant. The data in each group were compared using the unpaired *t* test.



**Figure 3.** Pressure resistance evaluation system.

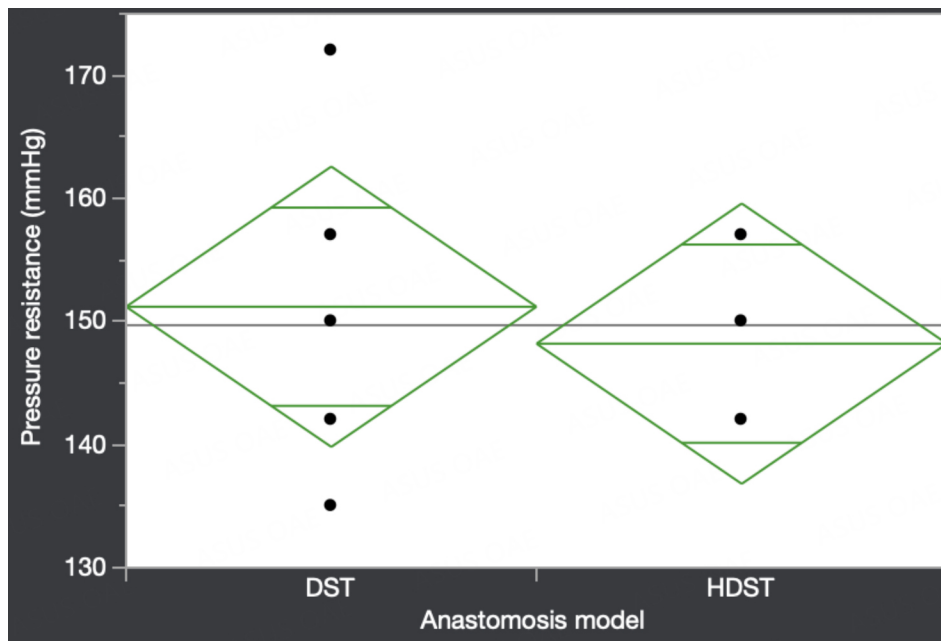
## RESULTS

All experiments were able to measure pressure resistance without failure. In all evaluations, the anastomotic leakage site was at the staple intersection; the DST model showed no left-right difference in the two staple intersections. All rDST models showed leakage at the opposite intersection of the repaired staple intersection. The leakage pressures in the HDST and DST group comparisons are summarized in [Figure 4](#). The pressure resistance with the DST group was  $151 \pm 14.2$  mmHg and the pressure resistance with the HDST group was  $148 \pm 6.3$  mmHg ( $P = 0.667$ ). Pressure resistance in the rHDST and rDST group comparisons are summarized in [Figure 5](#). The rHDST was capable of withstanding a pressure of 300 mmHg in all cases, and the pressure resistance with the rDST group was  $155 \pm 12.2$  mmHg ( $P < 0.001$ ).

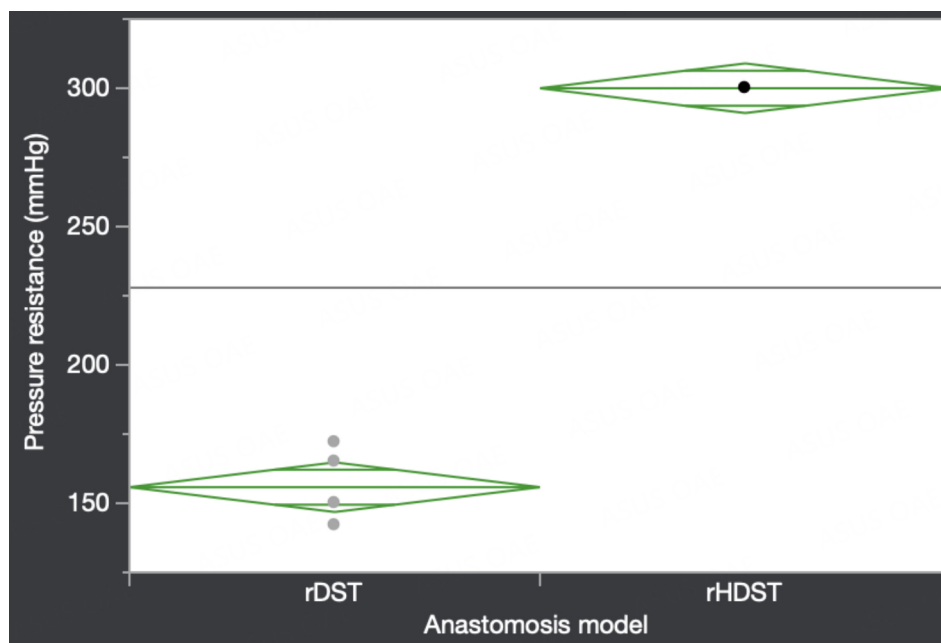
## DISCUSSION

In this esophagojejunostomy pressure resistance study using OrVil™, two novel findings were demonstrated. Firstly, there is no difference in pressure resistance between DST and HDST. However, staple intersections can cause anastomotic leakage. Secondly, the pressure resistance can be increased by repairing and HDST with a single intersection is useful from a surgical technique standpoint.

There have been no reports on esophagojejunostomy in terms of its pressure resistance, as well as on basic studies such as this current study on gastrointestinal anastomosis using the OrVil™ anastomosis device. Esophagojejunostomy is considered to be the most difficult and crucial procedure involved in LTG. Esophagojejunal anastomotic leakage is also considered to be one of the most serious complications after TG<sup>[3]</sup>. The reported esophagojejunal anastomotic leakage rates after TG vary from 0.9% to 17%<sup>[4]</sup>. Esophagojejunal anastomotic leakage has a negative impact on postoperative outcomes by increasing pulmonary complications, length of time to resume oral intake, median hospital stay duration, anastomotic stricture risk, the need for re-operation, and the leading cause of mortality-related death after this procedure<sup>[5]</sup>. Even “minor” leaks, which are associated with few or no physiologic signs or symptoms of



**Figure 4.** Comparison of the DST and HDST models pressure resistance. Dots represent individual data points, the straight line in the center of the diamond indicates the mean value for each model, the vertical length of the diamond represents the 95% confidence interval of the population mean for each model, and the height of the diamond is proportional to the square root of the sample size. The lines that appear above and below the mean line indicate the overlap marks to visually aid in understanding the significant difference. DST: double stapling technique; HDST: hemi-double stapling technique.



**Figure 5.** Comparison of the rDST and rHDST models pressure resistance. Dots represent individual data points, the straight line in the center of the diamond indicates the mean value for each model, the vertical length of the diamond represents the 95% confidence interval of the population mean for each model, and the height of the diamond is proportional to the square root of the sample size. The lines that appear above and below the mean line indicate the overlap marks to visually aid in understanding the significant difference. rDST: repaired double stapling technique; HDST: repaired hemi-double stapling technique.



sepsis, can lead to a protracted recovery course. Moreover, esophagojejunal anastomotic leakage is an independent prognostic factor for poor survival after gastric cancer surgery<sup>[6]</sup>.

The major factors in the difficulty of the esophagojejunostomy procedure after TG are securing a field of surgical view and procedure complexity. Specifically, esophageal junctional cancer and esophageal invasion of the upper gastric cancer, which have been increasing in recent years, often require mediastinal anastomosis, requiring more sophisticated surgical techniques.

In TG, there are currently various esophagojejunostomy types, including linear-stapled and circular-stapled reconstruction methods, especially for minimally invasive procedures, such as laparoscopic and robot-assisted surgery. Murakami *et al.* compared the linear-stapled and circular-stapled reconstruction methods for esophagojejunostomy in the propensity score-matched analysis and reported that the linear-stapled method had a lower stenosis risk, but there was no consensus on which intracorporeal esophagojejunostomy type was the best method for anastomotic leakage and other anastomosis-related complications<sup>[10]</sup>.

The OrVil<sup>TM</sup> is a commonly used device for circular-stapled esophagojejunostomy. OrVil<sup>TM</sup> can be reconstructed in almost the same procedure as laparotomy and can be used for anastomosis at a higher position and additional esophageal resection regardless of the patient's body type, and it has the advantage of not requiring complicated suturing operations. In cases where LSs are not indicated, the OrVil<sup>TM</sup> would be helpful in performing a standard esophagojejunostomy. When performing anastomosis with OrVil<sup>TM</sup>, we can choose DST or HDST depending on the rod out position. This difference has important implications, such as whether a LS and a CS overlap in two or one places. This staple intersection has been reported to cause anastomotic leakage and stenosis, but there have been no reports of actual OrVil<sup>TM</sup> use and direct comparison between DST and HDST, which is why we conducted this study<sup>[8,9]</sup>.

From the results of this study, there was no significant difference in pressure resistance between DST and HDST and leakage was observed at the staple intersection in all experiments. Experimental data obtained on fresh cadavers with the medial esophageal clamped portion have revealed that a 150-mmHg pressure was able to produce a tear at the gastroesophageal junction level<sup>[11]</sup>. Vomiting is an increased intraesophageal pressure sign involved in normal postoperative TG management, although such high pressures are rarely sustained and may not be a clinically problematic pressure tolerance. Postoperative placement of a nasogastric tube in situations where there are remaining concerns about the mechanical strength of the anastomosis could be an option to reduce the risk of anastomotic leakage through decompression. However, animal studies have shown that anastomotic leakage appears to be closely connected to the freshly completed intestinal anastomosis strength, and the bursting pressure is considered to be the most important factor in assessing the fresh intestinal suture line's quality<sup>[12]</sup>. Hendriks *et al.* reported that anastomotic burst pressure reflects anastomotic strength and higher burst pressure relates to stronger anastomosis less than 1 week preoperatively<sup>[13]</sup>. This also requires appropriate pressure resistance capacity in esophagojejunostomy after TG.

There have been many reports on the possible anastomotic leakage risk at the intersection in gastrointestinal surgery using medical staples. Roumen *et al.* reported that the lateral intersecting staple lines of the DST have structurally weak spots using pig small intestines and the experimental study in the small intestines of pigs by Kawasaki *et al.* demonstrated that the CS intersection and a LS may be a critical point for the DST method<sup>[14,15]</sup>. Additionally, several clinical studies have shown that the cause of anastomotic complication in esophagojejunostomy using DST or HDST is thought to be tension at the

anastomotic site due to traction on the Roux limb<sup>[9,16]</sup> or ischemia at the site where the staple lines meet, both of which might lead to fibrosis<sup>[9]</sup>. These results show that taking care of staple intersections is a very important surgical technique aspect. In fact, surgeons often attempt to increase their strength by reinforcing sutures. The results of this study, especially the rHDST, demonstrate that the repairing suture increases the pressure resistance capacity. Although the repairing suture at the leakage site in this study differs from the reinforcing suture applied at the staple intersection of the anastomosis during the actual surgery, based on strict definition, Kawasaki *et al.* also reported that reinforcing sutures improved the pressure resistance, with results similar to this study<sup>[15]</sup>. In rDST, leakage occurred from the contralateral staple intersections at the same pressures as before repair. As it has been previously shown that staple intersections can result in leaks, and considering that HDST has fewer intersections that are easier to reinforce, the rDST may have been able to withstand the same high pressures as rHDST, although no experiments were performed after reinforcing sutures at the two intersections. Judging from the reinforcing stitches number, HDST has one staple intersection, which is simpler and more useful compared to DST. Ozima *et al.* described a similar conclusion to this study with laparoscopic sigmoidectomy<sup>[8]</sup>. As mentioned earlier, esophagojejunostomy after TG has operative view and difficulty in maneuverability concerns; thus, the surgical technique should be more procedure-less.

The limitation of the study was that the results might not be generalizable to live human tissue because dead porcine esophagus and small bowel were used. Anastomotic leakage in animal experiments depends on a variety of parameters, including tissue thickness, collagen content, blood flow, oxygen delivery, improper staple selection, ischemia, and tension. Furthermore, we have not been able to evaluate patient factors that are clinically problematic for anastomotic leakage, such as malnutrition, diabetes, steroid use, liver and kidney dysfunction, and preoperative chemotherapy and radiation therapy. However, the current study only focused on the pressure resistance aspect<sup>[14,17,18]</sup>. Nevertheless, the anastomotic mechanical strength is a primary factor to be considered in the use of medical devices and was the main objective of this study. Further *in vivo* studies, including factors related to anastomotic leakage, are needed in the future. Also, the model might have some degree of subjectivity owing to the use of an analog system to measure the leak pressure, even though three observers participated. Instruments that can objectively assess anastomotic leakage should be developed further. Moreover, although the present study focused on esophagojejunostomy with OrVil™, comparing it with other reconstruction methods, such as overlap methods using linear staplers, which have been developed, could provide clearer results and contribute to improving surgical outcomes of esophagojejunostomy after TG.

In conclusion, HDST with a single-staple intersection is beneficial for esophagojejunostomy in terms of pressure resistance and the repairing suture at the staple intersection can increase pressure resistance.

## DECLARATIONS

### Authors' contributions

Writing of the manuscript: Yamauchi S, Orita H, Yoshimoto Y, Tsuda K, Kubota A, Yube Y, Kaji S

Performing the procedures and analyzing the data: Yamauchi S, Kanda S, Orita H

Conception and design of this work: Mine S, Brock MV, Fukunaga T

### Availability of data and materials

Not applicable.

### Financial support and sponsorship

None.



### Conflicts of interest

All authors declared that there are no conflicts of interest.

### Ethical approval and consent to participate

Not applicable.

### Consent for publication

Not applicable.

### Copyright

© The Author(s) 2023.

## REFERENCES

1. Gastric Cancer Association. Japanese gastric cancer treatment guidelines 2018 (5th edition). *Gastric Cancer* 2021;24:1-21. DOI PubMed PMC
2. Gong W, Li J. Combat with esophagojejunal anastomotic leakage after total gastrectomy for gastric cancer: a critical review of the literature. *Int J Surg* 2017;47:18-24. DOI PubMed
3. Makuuchi R, Irino T, Tanizawa Y, Bando E, Kawamura T, Terashima M. Esophagojejunal anastomotic leakage following gastrectomy for gastric cancer. *Surg Today* 2019;49:187-96. DOI PubMed
4. Inokuchi M, Otsuki S, Fujimori Y, Sato Y, Nakagawa M, Kojima K. Systematic review of anastomotic complications of esophagojejunostomy after laparoscopic total gastrectomy. *World J Gastroenterol* 2015;21:9656-65. DOI PubMed PMC
5. Sierzega M, Kolodziejczyk P, Kulig J. Impact of anastomotic leakage on long-term survival after total gastrectomy for carcinoma of the stomach. *Br J Surg* 2010;97:1035-42. DOI PubMed
6. Tokunaga M, Tanizawa Y, Bando E, Kawamura T, Terashima M. Poor survival rate in patients with postoperative intra-abdominal infectious complications following curative gastrectomy for gastric cancer. *Ann Surg Oncol* 2013;20:1575-83. DOI PubMed
7. Jeong O, Park YK. Intracorporeal circular stapling esophagojejunostomy using the transorally inserted anvil (OrViI) after laparoscopic total gastrectomy. *Surg Endosc* 2009;23:2624-30. DOI PubMed
8. Ojima E, Ikeda T, Noguchi T, et al. Laparoscopic sigmoidectomy using a hemi-double-stapling technique. *Surg Laparosc Endosc Percutan Tech* 2014;24:e41-2. DOI PubMed
9. Zuiki T, Hosoya Y, Kaneda Y, et al. Stenosis after use of the double-stapling technique for reconstruction after laparoscopy-assisted total gastrectomy. *Surg Endosc* 2013;27:3683-9. DOI
10. Murakami K, Obama K, Tsunoda S, et al. Linear or circular stapler? *Surg Endosc* 2020;34:5265-73. DOI
11. Mackler SA. Spontaneous rupture of the esophagus; an experimental and clinical study. *Surg Gynecol Obstet* 1952;95:345-56. DOI PubMed
12. Arnold W, Shikora SA. A comparison of burst pressure between buttressed versus non-buttressed staple-lines in an animal model. *Obes Surg* 2005;15:164-71. DOI
13. Hendriks T, Mastboom WJ. Healing of experimental intestinal anastomoses. Parameters for repair. *Dis Colon Rectum* 1990;33:891-901. DOI PubMed
14. Roumen RM, Rahusen FT, Wijnen MH, Croiset van Uchelen FA. "Dog ear" formation after double-stapled low anterior resection as a risk factor for anastomotic disruption. *Dis Colon Rectum* 2000;43:522-5. DOI PubMed
15. Kawasaki K, Fujino Y, Kanemitsu K, et al. Experimental evaluation of the mechanical strength of stapling techniques. *Surg Endosc* 2007;21:1796-9. DOI
16. Kinoshita T, Gotohda N, Kato Y, Takahashi S, Konishi M, Kinoshita T. Laparoscopic proximal gastrectomy with jejunal interposition for gastric cancer in the proximal third of the stomach: a retrospective comparison with open surgery. *Surg Endosc* 2013;27:146-53. DOI PubMed
17. Hardacre JM, Mendoza-Sagaon M, Murata K, Talamini MA. Use of a cauterizing laparoscopic linear stapler in intestinal anastomosis. *Surg Laparosc Endosc Percutan Tech* 2000;10:128-32; discussion 133. PubMed
18. Mery CM, Shafi BM, Binyamin G, Morton JM, Gertner M. Profiling surgical staplers: effect of staple height, buttress, and overlap on staple line failure. *Surg Obes Relat Dis* 2008;4:416-22. DOI PubMed