

Review

Open Access



# The role of immune checkpoint inhibitors and/or Yttrium-90 radioembolization in the management of hepatocellular carcinoma: challenges of treatment sequence

Samantha M. Ruff, Timothy M. Pawlik

Department of Surgery, Division of Surgical Oncology, The Ohio State University Wexner Medical Center and James Comprehensive Cancer Center, Columbus, OH 43210, USA.

**Correspondence to:** Prof. Timothy M. Pawlik, Department of Surgery, Division of Surgical Oncology, The Ohio State University Wexner Medical Center and James Comprehensive Cancer Center, 395 W. 12th Ave Suite 670, Columbus, OH 43210, USA. E-mail: tim.pawlik@osumc.edu

**How to cite this article:** Ruff SM, Pawlik TM. The role of immune checkpoint inhibitors and/or Yttrium-90 radioembolization in the management of hepatocellular carcinoma: challenges of treatment sequence. *Hepatoma Res* 2024;10:33. <https://dx.doi.org/10.20517/2394-5079.2024.59>

**Received:** 7 Apr 2024 **First Decision:** 15 Jul 2024 **Revised:** 2 Aug 2024 **Accepted:** 12 Aug 2024 **Published:** 21 Aug 2024

**Academic Editor:** Giuliano Ramadori **Copy Editor:** Ting-Ting Hu **Production Editor:** Ting-Ting Hu

## Abstract

Hepatocellular carcinoma (HCC) is an aggressive primary liver cancer secondary to chronic liver disease or cirrhosis. In the setting of chronic inflammation, the liver's tightly regulated immune system is disrupted, resulting in immune cell fatigue. This makes the liver vulnerable to tumorigenesis. Surgery and/or transplantation offer the best long-term survival for patients diagnosed with early HCC. Unfortunately, patients commonly develop recurrent or metastatic disease. Some patients will present with unresectable HCC or liver dysfunction. As such, locoregional therapy options may be limited. Research is focused on leveraging the distinctive liver immune microenvironment and its role in HCC carcinogenesis for the development of more effective systemic therapies. Given the success of immunotherapy in treating advanced HCC, the scientific community is looking to expand the indications of immunotherapy to the neoadjuvant and/or adjuvant setting and in combination with other locoregional therapies. We herein review the most recent data on the use of neoadjuvant or adjuvant immunotherapy and its combination with Yttrium-90 (Y90) radioembolization for HCC for curative intent.

**Keywords:** Hepatocellular carcinoma, immunotherapy, Yttrium-90, Y90, radioembolization



© The Author(s) 2024. **Open Access** This article is licensed under a Creative Commons Attribution 4.0 International License (<https://creativecommons.org/licenses/by/4.0/>), which permits unrestricted use, sharing, adaptation, distribution and reproduction in any medium or format, for any purpose, even commercially, as long as you give appropriate credit to the original author(s) and the source, provide a link to the Creative Commons license, and indicate if changes were made.



## INTRODUCTION

Hepatocellular carcinoma (HCC) is an aggressive primary liver cancer often secondary to chronic liver disease or cirrhosis. The liver primarily filters waste from the blood and sustains body homeostasis. For this reason, the liver maintains an immunotolerant environment so that it can effectively recognize and respond to pathogens and toxins while tolerating dietary and bacterial products. However, chronic inflammation disrupts this well-balanced and regulated system, thereby leading to immune cell fatigue. Subsequently, the liver becomes vulnerable to tumorigenesis<sup>[1]</sup>.

Surgery and/or transplantation confer the best outcomes for patients diagnosed with early HCC. Unfortunately, many patients develop locally recurrent or distant metastatic disease<sup>[2]</sup>. Furthermore, many patients will present with advanced HCC or liver dysfunction, thereby limiting locoregional therapeutic options<sup>[2]</sup>. In turn, research is focused on manipulating the distinct liver immune microenvironment and its role in HCC carcinogenesis for the development of more effective systemic therapies. The landmark IMbrave150 trial was the first to establish a survival benefit with immunotherapy for HCC<sup>[3,4]</sup>. This trial demonstrated that combination atezolizumab [programmed death ligand 1 (PD-L1) inhibitor] and bevacizumab [vascular endothelial growth factor (VEGF) inhibitor, a targeted therapy] conferred a survival advantage over sorafenib for advanced HCC. The HIMALAYA trial subsequently demonstrated a survival benefit with tremelimumab [cytotoxic T-lymphocyte-associated protein 4 (CTLA-4) inhibitor] and durvalumab (PD-L1 inhibitor) vs. sorafenib in advanced HCC<sup>[5]</sup>. Updated guidelines reflect the significance of these trials and now recommend immunotherapy as the standard of care for advanced HCC<sup>[2]</sup>.

The efficacy of immunotherapy for advanced HCC has led to a shift in research focus. More recent trials are focused on expanding indications for immune checkpoint inhibitors to the neoadjuvant and/or adjuvant setting, as well as in combination with other locoregional therapies. Treatment with liver-directed therapy, like Yttrium-90 (Y90) radioembolization, could prime the liver tumor microenvironment to increase the effectiveness of immunotherapy<sup>[6]</sup>. We herein review the most recent data on neoadjuvant or adjuvant immunotherapy and its use in combination with Y90 radioembolization for patients with HCC.

## INDICATIONS FOR SURGERY

Current guidelines recommend that patients with preserved liver function, no portal hypertension, acceptable future liver remnant (FLR), and resectable tumors be evaluated for surgery<sup>[2,7]</sup>. Extra-hepatic metastases are a contra-indication for surgery<sup>[7]</sup>. While ideal surgical candidates are those with solitary tumors and no major vascular invasion, some guidelines have expanded these criteria in highly selected patients<sup>[2,7]</sup>. For multifocal disease, the barcelona clinic liver cancer (BCLC) guidelines do not recommend surgery, only transplantation or ablation<sup>[2]</sup>. On the other hand, the Japan Society of Hepatology Clinical Practice Guidelines recommend that only multifocal disease consisting of  $\leq 3$  nodules be considered for resection<sup>[8]</sup>. These recommendations remain controversial given the elevated post-operative recurrence risk among patients with major vascular invasion or multifocal disease.

## IMMUNE CHECKPOINTS

Membrane proteins called immune checkpoints bind immune cell receptors and regulate the immune response through stimulation or inhibition<sup>[9]</sup>. Immune checkpoints help regulate and suppress autoreactivity of the immune system. Cancer cells manipulate these mechanisms to evade the immune system by upregulating inhibitor protein expression and downregulating stimulatory protein expression<sup>[10]</sup>. Additionally, T cell exhaustion, decreased production of helper cytokines, and reduced T cell proliferation can lead to enhanced carcinogenesis<sup>[11]</sup>. Immune checkpoint inhibitors (ICIs) are monoclonal antibodies that impede these interactions and thereby restore T cell antitumor function<sup>[11]</sup>. These drugs are often better

tolerated than cytotoxic chemotherapy. Two immune checkpoints, CTLA-4 and PD-L1, are frequently targeted in patients with HCC [Figure 1].

#### CTLA-4

The family of B7 ligands on antigen-presenting cells (APCs) bind different T cell receptors to exert their effect on the immune system. When these ligands bind T cell receptor CD28, a second stimulatory signal and a pro-inflammatory state are induced<sup>[13]</sup>. However, when bound to the CTLA-4 T cell receptor, T cell expansion is decreased to prevent binding with CD28. Through manipulation of the pathway, cancer cells create a suppressed immune environment and T cell exhaustion<sup>[13,14]</sup>.

#### PD-L1

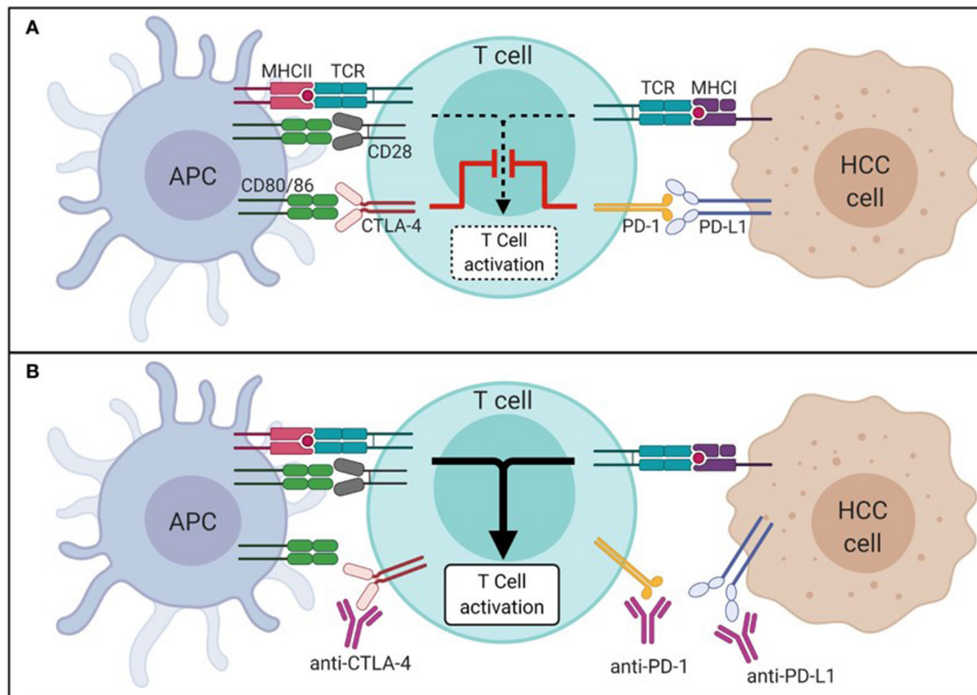
PD-L1 is a ligand expressed in answer to pro-inflammatory cytokines. PD-L1 binds the PD-1 receptor on multiple immune cells. This process results in the inhibition of T cell migration, proliferation, and cytotoxin secretion. Cancer cells upregulate the expression of PD-L1 to subdue the immune environment<sup>[15]</sup>. Furthermore, PD-L1 and PD-1 overexpression has been demonstrated in chronically inflamed livers<sup>[16,17]</sup>.

### NEOADJUVANT IMMUNOTHERAPY FOR RESECTABLE HCC

Even after curative intent resection, HCC has a high risk of recurrence. Recurrent disease may represent disseminated micrometastatic disease that is not detectable at surgery. Alternatively, recurrent disease can signify *de novo* primary tumors in a chronically inflamed or cirrhotic liver. Neoadjuvant treatment for resectable HCC could potentially treat the micrometastatic disease and delay recurrence. Additionally, the effects of immunotherapy may be enhanced in the neoadjuvant setting since the *in vivo* tumor provides neoantigens to prime the T cells. After resection, treatment response can be assessed on the pathologic specimen to guide future systemic therapy decisions in the setting of recurrent or metastatic disease.

A phase II trial evaluating perioperative cemiplimab (PD-1 inhibitor) was recently published<sup>[18]</sup>. This study included 21 patients who all had resectable disease. Among the 20 patients who underwent resection, seven had significant responses on final pathology (4 with > 70% necrosis, 3 with partial response). A different phase II trial evaluated perioperative camrelizumab (PD-1 inhibitor) in combination with apatinib (VEGF inhibitor) for resectable HCC<sup>[19]</sup>. The one-year recurrence-free survival among patients who underwent resection ( $n = 17$ ) was 53.9%. In yet another randomized trial, patients with resectable HCC received perioperative (i.e., pre-and/or post-operative) nivolumab (PD-1 inhibitor) or nivolumab and ipilimumab (CTLA-4 inhibitor)<sup>[20]</sup>. This phase II trial primarily accessed safety. Both cohorts of patients tolerated the treatment well and had acceptable toxicity levels, although the study saw a higher rate of grade 3 and 4 adverse events in the nivolumab/ipilimumab cohort (43% vs. 23%). Importantly, while 7 of 27 patients did not proceed to surgery, the reasons were not secondary to adverse events. The estimated median progression-free survival (PFS) was 9.4 months (nivolumab cohort) vs. 19.5 months (nivolumab and ipilimumab cohort). Additionally, about one-third of patients in each arm had > 70% pathologic response.

Currently, the PRIME-HCC trial is studying neoadjuvant nivolumab and ipilimumab in patients with resectable HCC defined as BCLC stage 0 or A who are ineligible for liver transplantation<sup>[2,21]</sup>. On interim analysis, with 17 patients enrolled, neoadjuvant nivolumab/ipilimumab was shown to be safe and did not delay liver resection. Among 13 patients with available radiologic assessment, the objective response rate (ORR) was 23%. At the time of the initial analysis, 9 patients had undergone surgical resection, with 7 achieving a pathologic response. There was some discordance noted between pathologic and radiographic response, which suggests that the process of evaluating response in immunotherapy-based trials may need to be adjusted.



**Figure 1.** Mechanism of immune checkpoints in HCC in the absence (A) and presence (B) of ICI. This figure was re-printed with copyright permission from Mohr *et al.*<sup>[12]</sup>. HCC: Hepatocellular carcinoma; ICI: Immune checkpoint inhibitors; APC: antigen-presenting cell; MHC: major histocompatibility complex; TCR: T cell receptor; CTLA-4: cytotoxic T-lymphocyte-associated protein 4; PD-1: programmed cell death 1 protein; PD-L1: programmed death-ligand 1.

Despite best efforts to select patients appropriately for an oncologic operation, recurrence among patients with HCC remains high. The high incidence of recurrence may be due to early dissemination of micrometastatic disease or *de novo* disease after resection in the setting of a chronically inflamed or cirrhotic liver. Given the success of immunotherapy in the setting of advanced HCC, immunotherapy may play a role in the neoadjuvant setting. While current trials have shown that immunotherapy can be safely given in the neoadjuvant setting for resectable disease, they were not sufficiently powered to demonstrate differences in long-term outcomes. Therefore, larger, multi-center, randomized trials will be necessary to determine if neoadjuvant immunotherapy for resectable HCC confers a survival benefit.

## IMMUNOTHERAPY TO DOWNSTAGE HCC

While data are limited, there are promising studies that suggest ICIs may downstage patients with unresectable HCC and make individuals eligible for locoregional therapies. This approach may be effective because the *in vivo* tumor provides neoantigens that prime T cells, thereby augmenting the efficacy of ICIs. In a retrospective study, Zhu *et al.* evaluated 63 cases of unresectable HCC who received a combination of a tyrosine kinase inhibitor (TKI, lenvatinib or apatinib) and PD-1 inhibitor (pembrolizumab or camrelizumab)<sup>[22]</sup>. Among these patients, ten individuals proceeded surgery with an R0 resection within three months of starting treatment and six had a complete response on final pathology. On follow-up (median 11.2 months), eight had no recurrent disease, one had recurrent tumor, and one passed away from an adverse event. In another retrospective review, Zhang *et al.* evaluated cases of HCC with vascular invasion<sup>[23]</sup>. All patients were treated with a PD-1 inhibitor and TKI. Among ten patients identified for inclusion in this study, eight were downstaged and underwent a resection. One patient had a complete pathologic response and the other seven patients had partial responses; recurrence free survival(RFS) at one year was 75%.

In a phase I, single-arm trial, cabozantinib (TKI) and nivolumab (PD-1 inhibitor) were used to treat patients with borderline resectable HCC<sup>[24]</sup>. Patients had either a solitary tumor > 5 cm, unilobar multifocal disease (> 3 tumors or multifocal disease with a tumor > 3 cm), bilobar tumors, or high-risk tumors (size > 3 cm with vascular invasion). Among the 15 patients enrolled, 12 underwent an R0 resection and five had a major response on final pathology. Of note, those with a pathologic response also showed more T effector cells. These retrospective studies and one prospective clinical trial demonstrate that in appropriately selected patients, ICIs may result in downstaging, resection, and improved long-term outcomes. Larger studies to better delineate which patients will best respond to ICIs are needed to select patients for different ICI-based regimens guided by underlying tumor factors and predicted response.

### ADJUVANT IMMUNOTHERAPY FOR RESECTABLE HCC

Five-year recurrence ranges from 70%-80% for patients with HCC<sup>[25]</sup>. Currently, there is only one published trial assessing adjuvant immunotherapy for resectable HCC. IMbrave050 is a multi-center, phase III randomized controlled trial that compared adjuvant atezolizumab (PD-L1 inhibitor) and bevacizumab (VEGF inhibitor) to surveillance in patients with HCC who underwent curative-intent resection or ablation<sup>[26,27]</sup>. Patients included in this study were considered to have “high risk” features of recurrence, which included tumors > 5 cm, > 3 tumors, microvascular invasion, minor macrovascular invasion, or grade 3/4 pathology. While the final results are pending, the interim analysis of 668 patients (334 in each arm) was shared in 2023<sup>[27]</sup>. At follow-up (median 17.4 months), the study demonstrated improved recurrence-free survival with adjuvant therapy (HR 0.72,  $P = 0.012$ ). There are several active phase III studies currently assessing adjuvant immunotherapy for high-risk HCC following curative-intent locoregional therapy (e.g., surgery or ablation) (NCT04102098, NCT03847428, NCT03383458, NCT03867084, NCT04639180).

### IMMUNOTHERAPY AND MOLECULAR PATHOLOGICAL EPIDEMIOLOGY

Molecular pathological epidemiology is an area of research that evaluates how nutrition, environmental exposures, the microbiome, and other exogenous factors can influence the pathology, genome, epigenome, transcriptome, proteome, and metabolome of healthy and neoplastic cells. These data may provide insight into differing treatment responses among tumors. Immunotherapy exogenous factors may impact the healthy immune cells and their ability to interact with tumor cells or effectiveness in the setting of immune checkpoint inhibitors<sup>[28]</sup>. Furthermore, there is some evidence that obesity, medications (e.g., antibiotics, proton pump inhibitors, steroids), underlying genetic differences, gut microbiome, and dietary choices (e.g., fiber intake, alcohol) may impact the efficacy of immune checkpoint inhibitor therapy<sup>[29]</sup>. Given the unique immune microenvironment and its role in HCC, this area of research is particularly important. These data on exogenous factors should be collected as part of clinical trials in future studies to help guide physicians in counseling and selecting patients who will derive the most benefit from immunotherapy. It has the potential to improve prediction of response and adverse reactions to targeted or immune-based therapies.

### IMMUNOTHERAPY AND LOCOREGIONAL THERAPY

Locoregional therapies can lead to a peripheral immune response by inducing cell death and turning the tumor into an *in situ* vaccine<sup>[30-33]</sup>. Damage-associated molecular patterns (DAMPs) are released after cell death, taken up by dendritic cells, presented to T cells, and subsequently stimulate the release of interleukin-2 (IL-2) and cause T cell expansion. These T cells are specifically targeted against the patient cancer cells<sup>[34-36]</sup>. While this reignites the immune system and its natural antitumor effects, this is only a transient effect. As such, recurrence after locoregional ablation remains as high as 50%-70%<sup>[6]</sup>. However, the pro-inflammatory state after locoregional therapy may improve the effectiveness of immune checkpoint inhibitors. This synergistic effect is still being investigated in trials.

## Y90 RADIOEMBOLIZATION

Trans-arterial therapies are a key component of the multidisciplinary management of HCC. The liver parenchyma is mainly supplied by the portal vein, but the hepatic artery primarily supplies blood and nutrients to HCC tumors. Trans-arterial therapies take advantage of this relationship by selectively embolizing and/or delivering therapy through the hepatic artery to avoid compromising portal circulation to the healthy liver parenchyma.

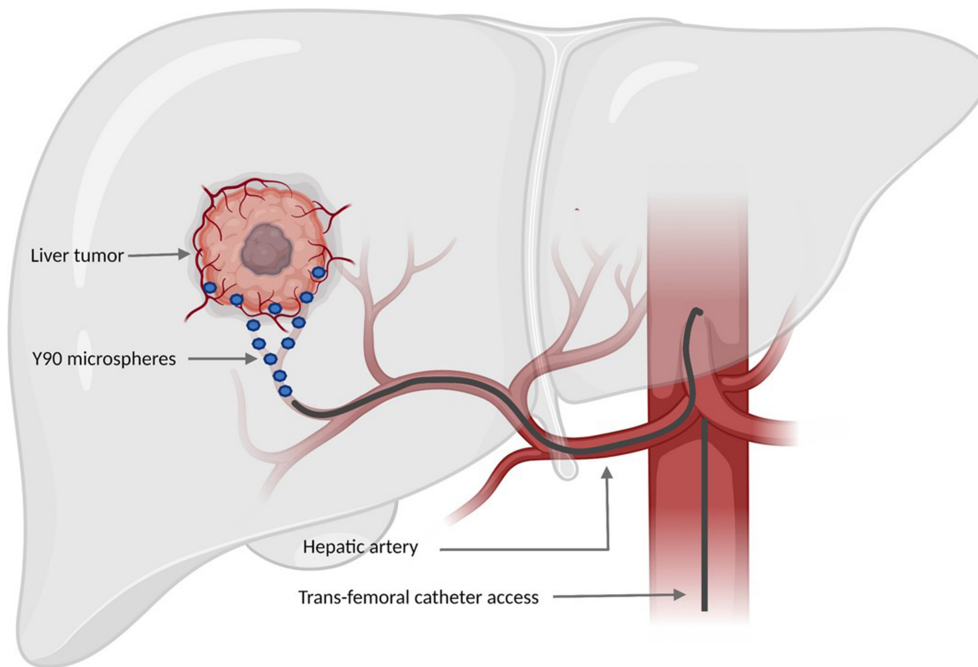
Trans-arterial radioembolization (TARE) with Y90 microspheres delivers small, radioactive beads through the hepatic artery to the tumor [Figure 2]. Y90 radioembolization (Y90 RE) is not traditionally used for patients with resectable HCC since resection or transplantation confers a better long-term survival outcome. Locoregional therapy may be beneficial among patients as an effective translational therapy prior to transplantation or resection<sup>[37]</sup>. Additionally, Y90 RE has been demonstrated to improve median time to progression among early- to intermediate-stage HCC compared with other locoregional therapies such as trans-arterial chemoembolization<sup>[38]</sup>. However, these benefits are not always observed in those with advanced or high-risk HCC (e.g., portal vein thrombosis, multifocal disease, macrovascular invasion)<sup>[39-41]</sup>. Given recent advancements in systemic therapy for HCC with ICIs, there may be a way to leverage Y90 RE-induced immunogenic cell death to enhance the effectiveness of ICIs.

### Immunotherapy and Y90

Recently, there has been increased focus on the immunologic impact of Y90 RE. Chew *et al.* used time-of-flight mass cytometry and next-generation sequencing to analyze the immune landscape of tumor tissue and peripheral blood before and after Y90 RE in patients with HCC<sup>[43]</sup>. Tumor-infiltrating lymphocytes (TILs) after Y90 RE demonstrated signs of local immune activation and next-generation sequencing confirmed the upregulation of genes involved in the immune system. When comparing peripheral blood mononuclear cells pre- and post-Y90 RE, there was an increase in antigen-presenting cells and TNF- $\alpha$  on CD8+ and CD4+ T cells. In a follow-up study, Rivoltini *et al.* assessed immune phenotypes in the blood of patients with intermediate to advanced HCC and preserved hepatic function<sup>[44]</sup>. The investigators confirmed that Y90 RE altered the immune system. Furthermore, these immunomodulatory effects peaked 1 month after treatment and then decreased at the 3- and 6-month time points. Because the immunomodulatory effects of Y90 are transient, the timing of ICIs will be critical to the success of multidisciplinary treatment strategies.

Several small, retrospective studies have demonstrated the potential benefits of Y90 RE in combination with ICIs for patients with HCC, but there is still a dearth of prospective data<sup>[45-48]</sup>. Tai *et al.* evaluated the use of Y90 RE and nivolumab started on post-procedure day 21 among 36 patients with Child-Pugh A cirrhosis and advanced HCC who were not candidates for curative-intent surgery<sup>[49]</sup>. The objective response rate was 30.6%. A similar phase II single-arm trial evaluated 42 patients with intermediate to advanced HCC who were treated with Y90 RE followed by nivolumab on post-procedure day 21. Roughly one-half of patients had serious adverse events and the objective response rate was 41.5%. Four patients were downstaged such that partial hepatectomy was feasible; the median time to progression was 8.8 months and the median OS was 20.9 months. A retrospective review compared the radiographic response and survival of 44 patients treated with Y90 RE within 4 weeks of initiation of ICI or a tyrosine kinase inhibitor therapy<sup>[50]</sup>. This study demonstrated that patients with HCC who received Y90 and ICI had better imaging responses and fewer adverse events than individuals treated with Y90 and tyrosine kinase inhibitors. There was no difference in median PFS or OS.

A recently published pilot study evaluated the use of ICIs with Y90 RE for patients with localized HCC<sup>[51]</sup>. Localized HCC with poor prognosis was defined as patients who were not a candidate for liver transplant or



**Figure 2.** Image of Y90 RE procedure. This figure was re-printed with copyright permission from ref.<sup>[42]</sup>. Y90: Yttrium-90; RE: radioembolization.

surgery in the setting of portal vein thrombus, multifocal disease, or diffuse disease. Most patients had Child-Pugh A liver disease (96%). Between 2017 and 2020, 27 patients were enrolled and treated with perioperative pembrolizumab (PD-1 inhibitor). Y90 RE was performed 7-10 days after initiating pembrolizumab. Median progression-free survival was 9.95 months and overall survival was 27.3 months. The combination of pembrolizumab and Y90 RE was safe and tolerable.

### ONGOING CLINICAL TRIALS WITH Y90 RE

There are open clinical trials evaluating ICIs and Y90 RE. The EMERALD-Y90 trial is a phase II study for unresectable HCC assessing the efficacy and safety of durvalumab, bevacizumab, and Y90 RE (NCT0604099). The ROWAN study is a phase II single-arm trial evaluating durvalumab, tremelimumab, and Y90 RE in patients with HCC not eligible for surgery, ablation, or liver transplant (NCT05063565). The phase II IMMWIN trial is assessing the efficacy of durvalumab and tremelimumab with either Y90 RE or DEB-TACE (NCT04522544). Patients in this trial with intermediate-stage HCC will be randomized to one of the two arms. An early phase I trial (NCT03812562) is evaluating recurrence after neoadjuvant nivolumab and Y90 in patients undergoing surgery. Another single-arm pilot study (NCT03099564) is evaluating the use of pembrolizumab and Y90 RE in patients with localized, poor prognosis HCC (e.g., portal vein thrombus, multifocal disease, or diffuse disease). The SOLID trial is a phase II study comparing Y90 RE with and without bevacizumab/atezolizumab for patients with unresectable HCC.

### CONCLUSION

Hepatic resection and transplantation are the cornerstone curative-intent therapies for HCC. Most patients, however, will develop recurrent disease, and therefore, there needs to be an increased focus on identifying ways to prolong disease-free recurrence and improve overall survival. Given the distinct liver microenvironment and efficacy of ICIs among patients with advanced disease, expanding the indications to early- and intermediate-stage HCC is an important area of inquiry. Early data suggest that ICIs may be

effective in the neoadjuvant or adjuvant setting to prolong disease-free recurrence. Data related to neoadjuvant therapy is primarily derived from small, phase II trials that are not powered to detect differences in long-term survival. Furthermore, the interim analysis of the IMbrave050 study is the only published phase III clinical trial data related to adjuvant therapy that focused on highly selected patients with “high-risk” disease. Formal recommendations for neoadjuvant and adjuvant ICIs for patients with resectable HCC are still evolving and will need to be supported by data from larger, multi-center, prospective trials that evaluate efficacy in different patient populations with different drug combinations. Providers should seek to enroll patients in neoadjuvant or adjuvant ICI therapy clinical trials to improve accrual and assist in correlative tissue studies.

Data suggest that there is a synergistic effect between locoregional therapies (e.g., Y90 RE) and ICIs. This work has been primarily focused on patients with locally advanced disease not amenable to resection or transplantation. Pre-clinical work and analysis of tissue/blood samples have demonstrated that the immunomodulatory effects of Y90 RE likely peak at 1 month and then start to decrease. Because these effects are transient, the timing of ICI therapy will be critical to take full advantage of the Y90 RE-induced immunogenic cell death. Most data are based on early-phase clinical trials, and more work is needed to inform new treatment strategies for patients with more advanced diseases. Future studies should seek to better understand the indications for ICIs in the neo- and adjuvant setting, as well as in combination therapy with locoregional therapies.

## DECLARATIONS

### Authors' contributions

Contributed to the writing, editing, and revision of this manuscript: Ruff SM, Pawlik TM

### Availability of data and materials

Not applicable.

### Financial support and sponsorship

None.

### Conflicts of interest

Both authors declared that there are no conflicts of interest.

### Ethical approval and consent to participate

Not applicable.

### Consent for publication

Not applicable.

### Copyright

© The Author(s) 2024.

## REFERENCES

1. Robinson MW, Harmon C, O'Farrelly C. Liver immunology and its role in inflammation and homeostasis. *Cell Mol Immunol* 2016;13:267-76. DOI PubMed PMC
2. Reig M, Forner A, Rimola J, et al. BCLC strategy for prognosis prediction and treatment recommendation: the 2022 update. *J Hepatol* 2022;76:681-93. DOI PubMed PMC
3. De Castro T, Jochheim LS, Bathon M, et al. Atezolizumab and bevacizumab in patients with advanced hepatocellular carcinoma with impaired liver function and prior systemic therapy: a real-world experience. *Ther Adv Med Oncol* 2022;14:17588359221080298. DOI



[PubMed](#) [PMC](#)

4. Finn RS, Qin S, Ikeda M, et al; IMbrave150 investigators. Atezolizumab plus bevacizumab in unresectable hepatocellular carcinoma. *N Engl J Med* 2020;382:1894-905. [DOI](#) [PubMed](#)
5. Abou-Alfa GK, Lau G, Kudo M, et al. Tremelimumab plus durvalumab in unresectable hepatocellular carcinoma. *NEJM Evidence* 2022;8:EVID0a2100070. [DOI](#) [PubMed](#)
6. Llovet JM, De Baere T, Kulik L, et al. Locoregional therapies in the era of molecular and immune treatments for hepatocellular carcinoma. *Nat Rev Gastroenterol Hepatol* 2021;18:293-313. [DOI](#) [PubMed](#)
7. Benson AB 3rd, Abrams TA, Ben-Josef E, et al. NCCN clinical practice guidelines in oncology: hepatobiliary cancers. *JNCCN* 2009;7:350-91. [DOI](#) [PubMed](#) [PMC](#)
8. Kokudo N, Takemura N, Hasegawa K, et al. Clinical practice guidelines for hepatocellular carcinoma: the japan society of hepatology 2017 (4th jsh-hcc guidelines) 2019 update. *Hepatology Res* 2019;49:1109-13. [DOI](#) [PubMed](#)
9. Franzin R, Netti GS, Spadaccino F, et al. The use of immune checkpoint inhibitors in oncology and the occurrence of AKI: where do we stand? *Front Immunol* 2020;11:574271. [DOI](#) [PubMed](#) [PMC](#)
10. He X, Xu C. Immune checkpoint signaling and cancer immunotherapy. *Cell Res* 2020;30:660-9. [DOI](#) [PubMed](#) [PMC](#)
11. Gao Y, Ouyang Z, Yang C, et al. Overcoming T cell exhaustion via immune checkpoint modulation with a dendrimer-based hybrid nanocomplex. *Adv Healthc Mater* 2021;10:e2100833. [DOI](#)
12. Mohr R, Jost-Brinkmann F, Özdirik B, et al. Lessons from immune checkpoint inhibitor trials in hepatocellular carcinoma. *Front Immunol* 2021;12:652172. [DOI](#) [PubMed](#) [PMC](#)
13. Rotte A. Combination of CTLA-4 and PD-1 blockers for treatment of cancer. *J Exp Clin Cancer Res* 2019;38:255. [DOI](#) [PubMed](#) [PMC](#)
14. Wu Y, Guo Y, Huang A, Zheng P, Liu Y. CTLA-4-B7 interaction is sufficient to costimulate T cell clonal expansion. *J Exp Med* 1997;185:1327-35. [DOI](#) [PubMed](#) [PMC](#)
15. Onuma AE, Zhang H, Huang H, Williams TM, Noonan A, Tsung A. Immune checkpoint inhibitors in hepatocellular cancer: current understanding on mechanisms of resistance and biomarkers of response to treatment. *Gene Expr* 2020;20:53-65. [DOI](#) [PubMed](#) [PMC](#)
16. Kassel R, Cruise MW, Iezzoni JC, Taylor NA, Pruett TL, Hahn YS. Chronically inflamed livers up-regulate expression of inhibitory B7 family members. *Hepatology* 2009;50:1625-37. [DOI](#) [PubMed](#) [PMC](#)
17. Wang BJ, Bao JJ, Wang JZ, et al. Immunostaining of PD-1/PD-Ls in liver tissues of patients with hepatitis and hepatocellular carcinoma. *World J Gastroenterol* 2011;17:3322-9. [DOI](#) [PubMed](#) [PMC](#)
18. Marron TU, Fiel MI, Hamon P, et al. Neoadjuvant cemiplimab for resectable hepatocellular carcinoma: a single-arm, open-label, phase 2 trial. *Lancet Gastroenterol Hepatol* 2022;7:219-29. [DOI](#) [PubMed](#) [PMC](#)
19. Xia Y, Tang W, Qian X, et al. Efficacy and safety of camrelizumab plus apatinib during the perioperative period in resectable hepatocellular carcinoma: a single-arm, open label, phase II clinical trial. *J Immunother Cancer* 2022;10:e004656. [DOI](#) [PubMed](#) [PMC](#)
20. Kaseb AO, Hasanov E, Cao HST, et al. Perioperative nivolumab monotherapy vs. nivolumab plus ipilimumab in resectable hepatocellular carcinoma: a randomised, open-label, phase 2 trial. *Lancet Gastroenterol Hepatol* 2022;7:208-18. [DOI](#) [PubMed](#) [PMC](#)
21. D'alesio A, Pai M, Spalding D, et al. Preliminary results from a phase Ib study of neoadjuvant ipilimumab plus nivolumab prior to liver resection for hepatocellular carcinoma: the PRIME-HCC trial. *JCO* 2022;40:4093. [DOI](#)
22. Zhu XD, Huang C, Shen YH, et al. Downstaging and resection of initially unresectable hepatocellular carcinoma with tyrosine kinase inhibitor and anti-PD-1 antibody combinations. *Liver Cancer* 2021;10:320-9. [DOI](#) [PubMed](#) [PMC](#)
23. Zhang W, Hu B, Han J, et al. Surgery after conversion therapy with PD-1 inhibitors plus tyrosine kinase inhibitors are effective and safe for advanced hepatocellular carcinoma: a pilot study of ten patients. *Front Oncol* 2021;11:747950. [DOI](#) [PubMed](#) [PMC](#)
24. Ho WJ, Zhu Q, Durham J, et al. Neoadjuvant cabozantinib and nivolumab converts locally advanced HCC into resectable disease with enhanced antitumor immunity. *Nat Cancer* 2021;2:891-903. [DOI](#) [PubMed](#) [PMC](#)
25. Xu XF, Xing H, Han J, et al. Risk factors, patterns, and outcomes of late recurrence after liver resection for hepatocellular carcinoma: a multicenter study from china. *JAMA Surg* 2019;154:209-17. [DOI](#) [PubMed](#) [PMC](#)
26. Hack SP, Spahn J, Chen M, et al. IMbrave 050: a phase III trial of atezolizumab plus bevacizumab in high-risk hepatocellular carcinoma after curative resection or ablation. *Future Oncol* 2020;16:975-89. [DOI](#) [PubMed](#)
27. Chow P, Chen M, Cheng A, et al. Abstract CT003: IMbrave050: Phase 3 study of adjuvant atezolizumab + bevacizumab vs. active surveillance in patients with hepatocellular carcinoma (HCC) at high risk of disease recurrence following resection or ablation. *Cancer Research* 2023;83:CT003. [DOI](#)
28. Ogino S, Nowak JA, Hamada T, Milner DA Jr, Nishihara R. Insights into pathogenic interactions among environment, host, and tumor at the crossroads of molecular pathology and epidemiology. *Annu Rev Pathol* 2019;14:83-103. [DOI](#) [PubMed](#) [PMC](#)
29. Gunjur A, Manrique-Rincón AJ, Klein O, et al. 'Know thyself' - host factors influencing cancer response to immune checkpoint inhibitors. *J Pathol* 2022;257:513-25. [DOI](#) [PubMed](#) [PMC](#)
30. Hiroishi K, Eguchi J, Baba T, et al. Strong CD8<sup>+</sup> T-cell responses against tumor-associated antigens prolong the recurrence-free interval after tumor treatment in patients with hepatocellular carcinoma. *J Gastroenterol* 2010;45:451-8. [DOI](#) [PubMed](#)
31. Nobuoka D, Motomura Y, Shirakawa H, et al. Radiofrequency ablation for hepatocellular carcinoma induces glypican-3 peptide-specific cytotoxic T lymphocytes. *Int J Oncol* 2012;40:63-70. [DOI](#) [PubMed](#)
32. Hansler J, Wissniowski TT, Schuppan D, et al. Activation and dramatically increased cytolytic activity of tumor specific T

- lymphocytes after radio-frequency ablation in patients with hepatocellular carcinoma and colorectal liver metastases. *World J Gastroenterol* 2006;12:3716-21. [DOI](#) [PubMed](#) [PMC](#)
33. Ayaru L, Pereira SP, Alisa A, et al. Unmasking of alpha-fetoprotein-specific CD4<sup>+</sup> T cell responses in hepatocellular carcinoma patients undergoing embolization. *J Immunol* 2007;178:1914-22. [DOI](#) [PubMed](#)
  34. Rapoport BL, Anderson R. Realizing the clinical potential of immunogenic cell death in cancer chemotherapy and radiotherapy. *Int J Mol Sci* 2019;20:959. [DOI](#) [PubMed](#) [PMC](#)
  35. Basu S, Binder RJ, Suto R, Anderson KM, Srivastava PK. Necrotic but not apoptotic cell death releases heat shock proteins, which deliver a partial maturation signal to dendritic cells and activate the NF-kappa B pathway. *Int Immunol* 2000;12:1539-46. [DOI](#) [PubMed](#)
  36. Roberts EW, Broz ML, Binnewies M, et al. Critical Role for CD103<sup>+</sup>/CD141<sup>+</sup> dendritic cells bearing CCR7 for tumor antigen trafficking and priming of T cell immunity in melanoma. *Cancer Cell* 2016;30:324-36. [DOI](#) [PubMed](#) [PMC](#)
  37. Salem R, Johnson GE, Kim E, et al. Yttrium-90 radioembolization for the treatment of solitary, unresectable HCC: the LEGACY Study. *Hepatology* 2021;74:2342-52. [DOI](#) [PubMed](#) [PMC](#)
  38. Salem R, Gordon AC, Mouli S, et al. Y90 radioembolization significantly prolongs time to progression compared with chemoembolization in patients with hepatocellular carcinoma. *Gastroenterology* 2016;151:1155-63.e2. [DOI](#)
  39. Ali R, Gabr A, Abouchaleh N, et al. Survival analysis of advanced HCC treated with radioembolization: comparing impact of clinical performance status vs. vascular invasion/metastases. *Cardiovasc Intervent Radiol* 2018;41:260-9. [DOI](#) [PubMed](#)
  40. Abouchaleh N, Gabr A, Ali R, et al. <sup>90</sup>Y radioembolization for locally advanced hepatocellular carcinoma with portal vein thrombosis: long-term outcomes in a 185-patient cohort. *J Nucl Med* 2018;59:1042-8. [DOI](#) [PubMed](#)
  41. Vilgrain V, Pereira H, Assenat E, et al. Efficacy and safety of selective internal radiotherapy with yttrium-90 resin microspheres compared with sorafenib in locally advanced and inoperable hepatocellular carcinoma (SARAH): an open-label randomised controlled phase 3 trial. *Lancet Oncol* 2017;18:1624-36. [DOI](#) [PubMed](#)
  42. Viñal D, Minaya-Bravo A, Prieto I, Feliu J, Rodriguez-Salas N. Yttrium-90 transarterial radioembolization in patients with gastrointestinal malignancies. *Clin Transl Oncol* 2022;24:796-808. [DOI](#) [PubMed](#)
  43. Chew V, Lee YH, Pan L, et al. Immune activation underlies a sustained clinical response to Yttrium-90 radioembolisation in hepatocellular carcinoma. *Gut* 2019;68:335-46. [DOI](#) [PubMed](#) [PMC](#)
  44. Rivoltini L, Bhoori S, Camisaschi C, et al. Y<sup>90</sup>-radioembolisation in hepatocellular carcinoma induces immune responses calling for early treatment with multiple checkpoint blockers. *Gut* 2023;72:406-7. [DOI](#) [PubMed](#) [PMC](#)
  45. Zhan C, Ruohoniemi D, Shanbhogue KP, et al. Safety of combined Yttrium-90 radioembolization and immune checkpoint inhibitor immunotherapy for hepatocellular carcinoma. *J Vasc Interv Radiol* 2020;31:25-34. [DOI](#) [PubMed](#)
  46. Marinelli B, Cedillo M, Pasik SD, et al. Safety and efficacy of locoregional treatment during immunotherapy with nivolumab for hepatocellular carcinoma: a retrospective study of 41 interventions in 29 patients. *J Vasc Interv Radiol* 2020;31:1729-38.e1. [DOI](#) [PubMed](#)
  47. Yu Q, Wang Y, Ungehusri E, et al. Combination of transarterial radioembolization with atezolizumab and bevacizumab for intermediate and advanced staged hepatocellular carcinoma: a preliminary report of safety and feasibility. *J Interv Med* 2023;6:187-93. [DOI](#) [PubMed](#) [PMC](#)
  48. Villalobos A, Dabbous HH, Little O, et al. Safety and efficacy of concurrent atezolizumab/bevacizumab or nivolumab combination therapy with Yttrium-90 radioembolization of advanced unresectable hepatocellular carcinoma. *Curr Oncol* 2023;30:10100-10. [DOI](#) [PubMed](#) [PMC](#)
  49. Tai D, Loke K, Gogna A, et al. Radioembolisation with Y90-resin microspheres followed by nivolumab for advanced hepatocellular carcinoma (CA 209-678): a single arm, single centre, phase 2 trial. *Lancet Gastroenterol Hepatol* 2021;6:1025-35. [DOI](#) [PubMed](#)
  50. Garcia-Reyes K, Gottlieb RA, Menon KM, et al. Radioembolization plus immune checkpoint inhibitor therapy compared with radioembolization plus tyrosine kinase inhibitor therapy for the treatment of hepatocellular carcinoma. *J Vasc Interv Radiol* 2024;35:722-30.e1. [DOI](#) [PubMed](#)
  51. Yu S, Yu M, Keane B, et al. A pilot study of pembrolizumab in combination with Y90 radioembolization in subjects with poor prognosis hepatocellular carcinoma. *Oncologist* 2024;29:270-e413. [DOI](#) [PubMed](#) [PMC](#)