

Original Article

Open Access



Protective benefit of minimally invasive liver surgery for hepatocellular carcinoma prior to transplant

Simone Khouzam¹, Duilio Pagano², Marco Barbara², Vito Di Marco³, Giada Pietrosi², Marco Maringhini⁴, Marco Canzonieri², Sergio Calamia², Salvatore Gruttadauria^{2,5}

¹Sidney Kimmel Medical College, Thomas Jefferson University, Philadelphia, PA 19107, USA.

²Department for the Treatment and Study of Abdominal Diseases and Abdominal Transplantation, IRCCS-ISMETT (Istituto di Ricovero e Cura a Carattere Scientifico-Istituto Mediterraneo per I Trapianti e Terapie ad Alta Specializzazione), UPMC (University of Pittsburgh Medical Center), via E. Tricomi 5, Palermo 90127, Italy.

³Sezione di Gastroenterologia e Epatologia, Dipartimento Biomedico di Medicina Interna e Specialistica, University of Palermo, Palermo 90128, Italy.

⁴Medicina Interna, Università di Palermo/ISMETT, Via del Vespro 129, Palermo 90127, Italy.

⁵Department of Surgery and Medical and Surgical Specialties, University of Catania, Catania 95124, Italy.

Correspondence to: Prof. Salvatore Gruttadauria, Department for the Treatment and Study of Abdominal Diseases and Abdominal Transplantation, IRCCS-ISMETT (Istituto di Ricovero e Cura a Carattere Scientifico-Istituto Mediterraneo per I Trapianti e Terapie ad Alta Specializzazione), UPMC (University of Pittsburgh Medical Center), Palermo 90127, Italy.
E-mail: sgruttadauria@ISMETT.edu

How to cite this article: Khouzam S, Pagano D, Barbara M, Di Marco V, Pietrosi G, Maringhini M, Canzonieri M, Calamia S, Gruttadauria S. Protective benefit of minimally invasive liver surgery for hepatocellular carcinoma prior to transplant. *Hepatoma Res* 2022;8:9. <https://dx.doi.org/10.20517/2394-5079.2021.147>

Received: 21 Dec 2021 **First Decision:** 14 Jan 2022 **Revised:** 28 Jan 2022 **Accepted:** 22 Feb 2022 **Published:** 2 Mar 2022

Academic Editor: Guang-Wen Cao **Copy Editor:** Xi-Jun Chen **Production Editor:** Xi-Jun Chen

Abstract

Aim: The purpose of this study is to assess the benefit of laparoscopic liver resection (LLR) for hepatocellular carcinoma (HCC) given recurrence and future need for liver transplantation (LT).

Methods: Data on liver resections were gathered from the Istituto di Ricovero e Cura a Carattere Scientifico-Istituto Mediterraneo per i Trapianti e Terapie ad alta specializzazione (IRCCS-ISMETT) from 2003-2021. A retrospective analysis of 1408 consecutive adult patients who had a liver resection was performed with categorization based on the underlying disease process. A sub-analysis studied the 291 patients who had an LLR with an intention to transplant approach after LLR.

Results: From 2012 to 2020, ISMETT's mean annual LLR rate was 45%. Data suggests that a laparoscopic approach to iterative surgical treatment for HCC has demonstrated protective benefits. Compared to open surgery or LT, LLR is protective against the risk of de-listing, post-transplant patient death, tumor recurrence, adhesions,



© The Author(s) 2022. **Open Access** This article is licensed under a Creative Commons Attribution 4.0 International License (<https://creativecommons.org/licenses/by/4.0/>), which permits unrestricted use, sharing, adaptation, distribution and reproduction in any medium or format, for any purpose, even commercially, as long as you give appropriate credit to the original author(s) and the source, provide a link to the Creative Commons license, and indicate if changes were made.



and bleeding in a cirrhotic patient. Kaplan Meier's analysis showed no difference between post-LT survival curves for those with prior open abdominal surgery or LLR ($P = 0.658$).

Conclusion: Laparoscopic surgery has important protective advantages over laparotomy surgery for the surgical treatment of HCC, particularly since treatment is not always curative. LLR can be considered a bridge therapy for transplantation, ensuring less crowding of waiting lists, a desirable condition in areas of donor storage.

Keywords: Laparoscopic, liver resection, hepatocellular carcinoma, minimally invasive liver surgery

INTRODUCTION

The clinical entity of hepatocellular carcinoma (HCC) is responsible for 80%-90% of primary liver cancers, and it is the third leading cause of cancer-related death worldwide^[1]. The challenge in management arises from being able to deliver a curative treatment without precipitating further liver decompensation. The surgical options for curative treatment are defined as liver resection (LR), liver transplantation (LT), and ablation modalities. These treatments have been associated with a median overall survival of ≥ 60 months, with a 5-year survival rate approaching 70%^[2]. However, HCC recurrence (RHCC) develops in nearly 70% of patients within five years after initial resection.

While LT is the definitive treatment of these curative treatment options, the possibility of recurrence, waiting list times, and limited organ supply require consideration of LR prior to LT. Italy's organ allocation system uses the ISO score, a blended model of urgency, utility, and transplant benefit^[3,4]. Given the high likelihood of RHCC, post-transplant recurrence and outcomes must be considered^[5,6]. It is necessary to delineate the first-line laparoscopic surgical approach with the second-line surgical options for RHCC, particularly those requiring LT. Here we report a series of HCC patients' management and treatments at the ISMETT center (Mediterranean Institute for Transplantation and Highly Specialized Therapies) with an intention to transplant approach after laparoscopic liver resection (LLR).

METHODS

Our retrospective analysis studied 1408 adult patients who had a liver resection at our institute from January 2003 until November 2021, with categorization based on the underlying disease process. The etiologic categories were HCC, colorectal liver metastasis, non-colorectal liver metastasis, biliary cancer, benign tumor, living liver donor, trauma, and others. In addition, a sub-analysis studied the 291 patients who had an LLR, also known as minimal invasive liver surgery (MILS), were categorized in the same manner as the larger cohort, except there was no categorization of trauma or other as MILS is not indicated in those circumstances. All data were collected using the electronic database and processed retrospectively. The diagnosis of HCC was made in the period before being listed for LT following the criteria of the main AASLD and EASL-EORTC Clinical Practice Guidelines^[7,8].

The surgical treatment option was made after a careful multidisciplinary evaluation of the patient and considering staging, tumor location, and residual liver function^[9]. All patients in the study were included in the list after radiological confirmation of compliance with the Milan criteria (single nodule ≤ 5 cm or up to 3 nodules each ≤ 3 cm, in the absence of macrovascular infiltration and distant metastases). In some doubtful cases, it was also necessary to perform a biopsy examination. Patients with a diagnosis of HCC initially outside the Milan criteria were included in the list only after being treated with loco-regional techniques (bridge-therapy), managing to obtain a down-staging of the HCC, thus falling within the Milan criteria, and after maintaining the criteria for at least six months. Bridge-therapy techniques were limited to transarterial

chemoembolization and microwave thermal ablation with no surgical intervention until they were within the Milan criteria.

From the inclusion in the waiting list time until the moment of LT, all patients underwent clinical-laboratory checks every three months, with blood chemistry tests and alpha-fetoprotein (AFP) level, and instrumental every six months by means of abdominal computed tomography (CT) with contrast medium and/or magnetic resonance imaging (MRI) with hepato-specific contrast agent. After LT, all patients underwent a follow-up protocol that included AFP levels, chest x-ray and abdomen CT with contrast medium, and/or MRI with hepato-specific contrast medium every six months. In case of ascertained or suspected recurrence of intrahepatic and/or extrahepatic HCC, other investigations were performed: liver MRI, chest CT, bone scan, ultrasound-guided biopsy, or positron emission tomography. The survival curve between LT patients who underwent pre-transplant LLR, and any open abdominal surgery was calculated according to the Kaplan-Meier method, with the log-rank - test used to compare the curves. Data were analyzed using SPSS version 22.0 (SPSS Inc., Chicago, IL, USA) and MedCalc (MedCalc Software, Mariakerke, Belgium).

RESULTS

Study population

Of the 1408 patients who underwent liver resection, 291 underwent a minimally invasive approach and 1117 underwent an open approach. For the entire liver resection group, 29% had HCC, 31% had colorectal liver metastasis, 13% had benign tumors, 12% were living liver donors, 9% had biliary cancer, 5% had non-colorectal liver metastasis, 1% had trauma, and 0% had other indications.

Comparative in the MILS cohort, 53% had HCC, 19% had benign cancer, 14% had colorectal liver metastasis, 7% had biliary cancer, 4% were living liver donors, and 3% had non-colorectal liver metastasis as the indication for liver resection. Of note, the HCC indication was nearly double in the MILS cohort compared to the overall total group.

HCC laparoscopic liver resections

HCC was the main indication for liver resection in both groups, with 63% ($n = 258$) performed open *vs.* 37% performed minimal invasively ($n = 149$) as the average rate from 2003 to 2021. To better assess the current rate of MILS resection, the resection rate was separated into two time periods: 2003 to 2011 and 2012 to 2020. The mean annual rate from 2003 to 2011 was 7%, whereas it was 45% from 2012 to 2020, with a significant inflection point in 2012 [Figure 1].

Of the laparoscopic hepatic resections for HCC ($n = 149$), hepatitis C virus accounted for 67% of the primary cause of HCC with hepatitis B virus at 12%, non-alcoholic steatohepatitis at 12%, alcohol at 5%, and other at 4%. Furthermore, the types of resections were classified as either major or minor. Major resections are defined as any resection of three contiguous segments, including open right hepatectomy ($n = 3$) and laparoscopic left hepatectomy ($n = 1$). Minor resections included bisegmentectomy ($n = 8$), not including left lobectomy ($n = 1$), segmentectomy ($n = 15$), wedge resection of 2 nodules ($n = 12$), and wedge resection of 1 nodule ($n = 110$). The segments involved in these types of resections appeared to be evenly distributed aside from segment 1, which was never involved. Segment 2 accounted for 21% ($n = 31$), segment 3 accounts for 19% ($n = 29$), segment 4 account for 13% ($n = 19$), segment 5 account for 22% ($n = 33$), segment 6 accounted for 25% ($n = 38$), and segment 7 accounted for 19% ($n = 28$). As some HCC resections involved multiple segments, each segment was included in the count.

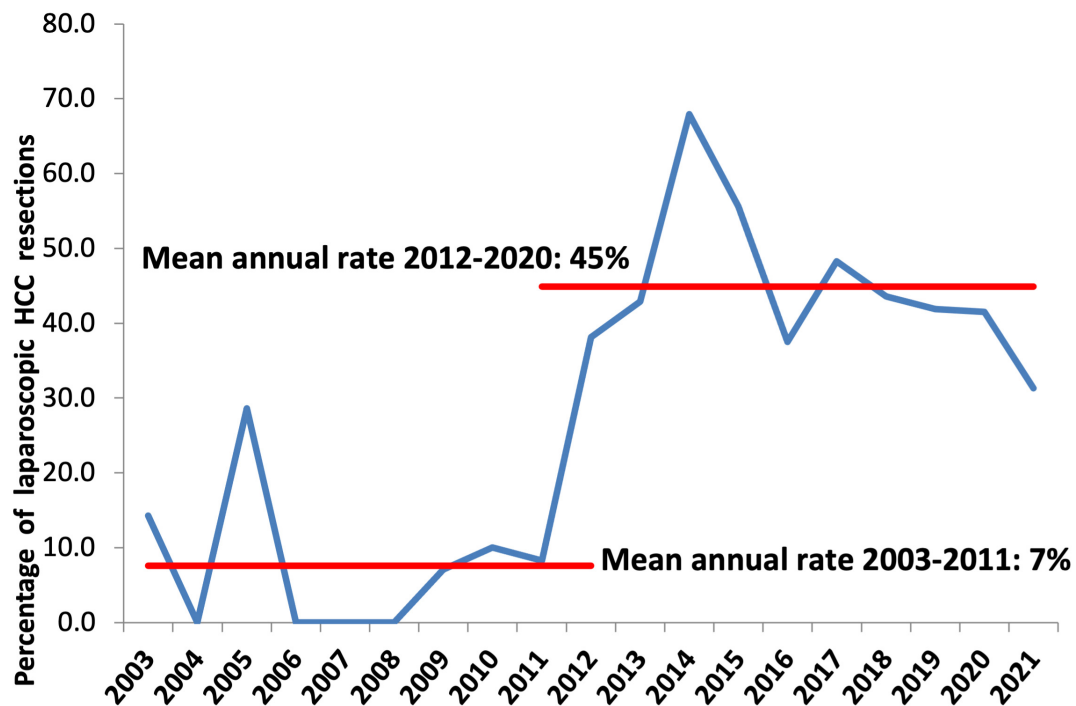


Figure 1. We present the annual percentages of laparoscopic HCC resection at our center with the mean annual rate calculated from the period of 2003 to 2011 as 7% and 2012 to 2020 as 45%. HCC: Hepatocellular carcinoma.

No differences were detected in terms of patient survival curve between LT patients who underwent pre-transplant LLR and any open abdominal surgery, such as LR or colectomy, according to the Kaplan-Meier analysis ($P = 0.658$, [Figure 2](#)). The most common LR complication noted was a biliary leak ($n = 4$; 1.37%). In the LLR cohort, there was only one grade B biliary leak (0.07%), whereas in the open cohort, there were 3 biliary leaks (1.16%), of which there was 1 grade A, 1 grade B, and 1 grade C biliary leak.

HCC Microwave thermal ablation

At our center, 87 patients with HCC underwent microwave thermal ablations from 2003 to 2021. This treatment option is an alternative to surgical resection or liver transplant for those who do not qualify for surgical resection or transplant due to comorbid risk factors, disease progression, or do not wish for a surgical procedure. The HCC lesions treated were found in all segments: segment 1 ($n = 1$), segment 2 ($n = 4$), segment 3 ($n = 4$), segment 4 ($n = 11$), segment 5 ($n = 8$), segment 6 ($n = 12$), segment 7 ($n = 24$), segment 8 ($n = 23$).

HCC recurrence treatment options

Despite initial hepatic resection with preserved liver function, the majority of patients had a recurrence of HCC. From 2013 to 2021, 563 patients had a first-line surgical treatment for HCC, with 31 patients receiving second-line surgical treatment. A minimally invasive approach was taken in 178 out of the 563 first-line approaches [[Figure 3](#)]. Of the 14 patients who underwent a subsequent LT, there were 9 who previously underwent LR.

DISCUSSION

Liver resection and transplantation are the best treatments in terms of radicality for HCC and its recurrences^[10]. Given the high relapse rate, it is essential to consider the hepatocellular carcinoma resection

Liver Transplant after Minimally-Invasive Liver Surgery

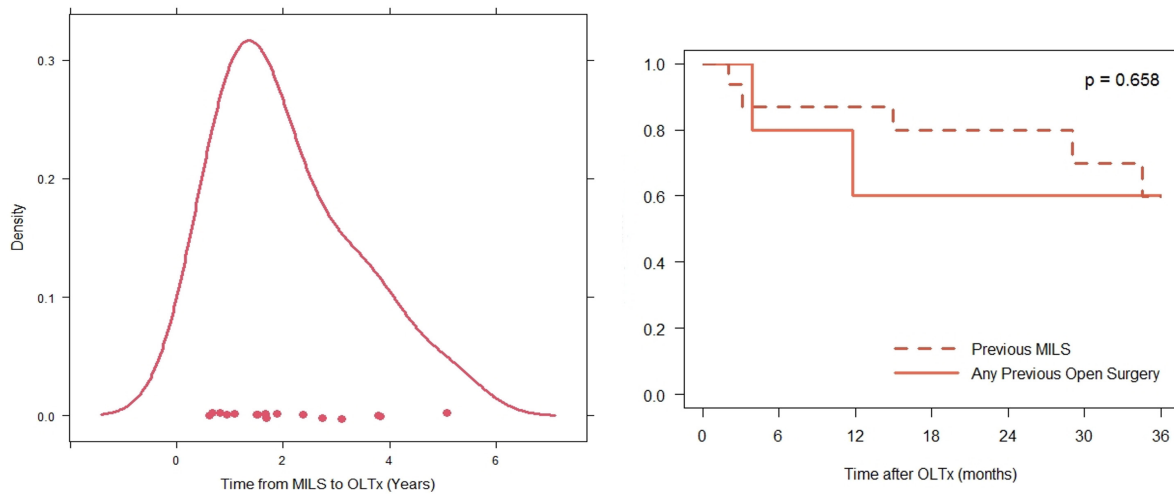


Figure 2. Time from MILS to liver transplant and Kaplan Meier curve comparing overall survival post-OLT after previous open surgery or previous MILS. OLT: Orthotopic liver transplant; MILS: minimally invasive liver surgery.

Iterative HCC Surgical Treatments (2013-2021, N=563 pts)

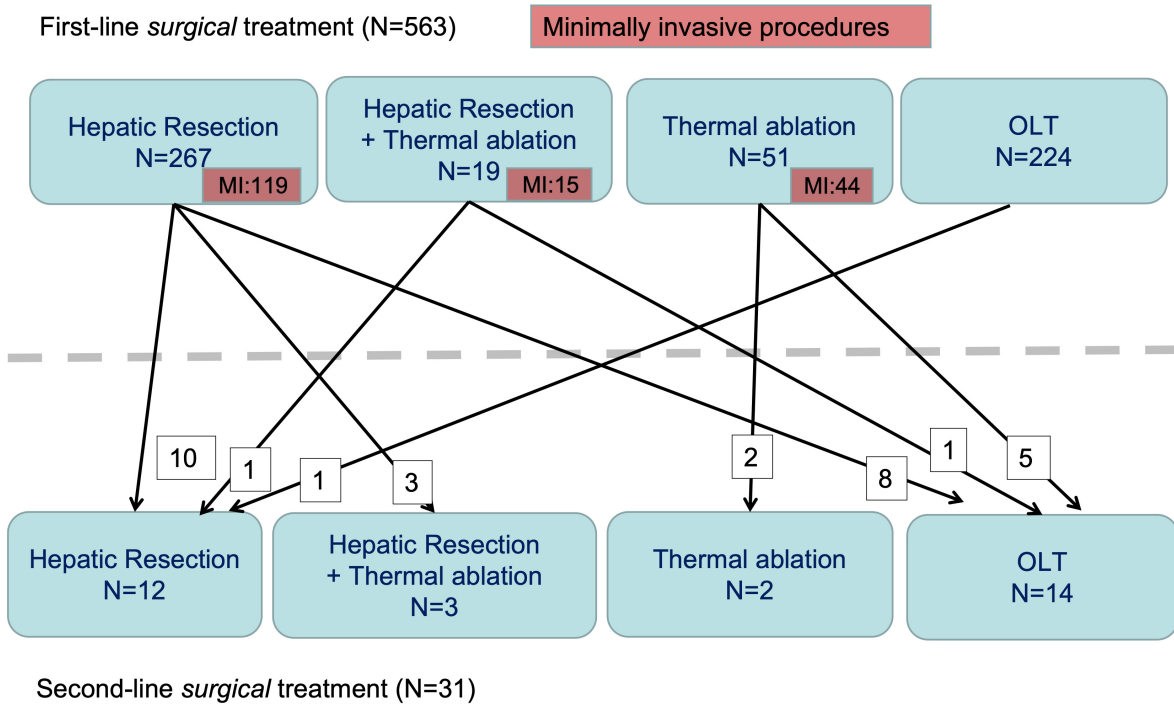


Figure 3. Diagram of first- and second-line surgical treatments for HCC from 2013 to 2021. HCC: Hepatocellular carcinoma; OLT: orthotopic liver transplantation.

as the first potential series intervention. Laparoscopic surgery has become the gold standard for treating HCC since the 2010s and changes in Italian national guidelines^[11-16]. The inflection point of LLR in 2012 at

our center correlates with the timeframe of the acceptance of LLR specifically for HCC patient outcomes. Moreover, reducing abdominal wall trauma with less resulting pain, less bleeding, and ascetic are well-known advantages of laparoscopy. Another significant advantage of laparoscopic surgery is reducing postoperative adhesions, making subsequent surgical approaches simpler and safer^[17]. The surgical indication for laparoscopy can be extended to more complex patients with more advanced liver disease. Still, LR, when feasible, and LT, when indicated, remain the best radical treatments even in the treatment for RHCC. For this reason, it becomes increasingly important to perform LLR whenever possible. LLR determines fewer postoperative adhesions and poses the best conditions for resection and transplant reoperations.

LLR in advanced cirrhosis is safe and provides optimal long-term survival for select patients with HCC. While the benefits of LLR in Child-Turcotte-Pugh (CTP) cirrhotic patients for HCC have been well known, it still remains unclear for Child-Pugh B cirrhosis, the superior benefits of MILS over laparotomy HCC resection were recently demonstrated for patients without preoperative portal hypertension and score of CTP B7 cirrhosis^[18]. By using the IWATE classification, the complexity and extent of LR are determined^[19,20]. Long-term survival is most impacted by patient comorbidities, age, degree of underlying liver disease, and high-quality oncologic surgery with > 2 comorbidities, older age, grade 3-4 disease, regional lymph node metastasis (N1), and hepatectomy with microscopic exposure of tumor margins (R1) as predictors of worse overall survival^[21-27]. RHCC can be developed in entirely different settings, and it depends on the first-line therapy which was chosen. An immunosuppressive regimen needs to be adopted in LT recipients, and the presence of extrahepatic disease can dramatically direct patients to systemic therapies. LR and thermal ablation remain the surgical choices that offer a high probability of complete and potentially curative response for HCC recurrence^[9,27-29].

Clinical, pathological, and genetic factors affect and predict HCC progression. Clinically higher serum bilirubin levels, in addition to pathological evidence of more nodules and larger nodules, were predictors of HCC recurrence. While at a genetic level, loss of phosphate and tensin homolog loci heterozygosity has been demonstrated with a lower risk of HCC recurrence and a protective effect of specific AI mutations for the risk of HCC recurrence^[30-32]. Given the recurrence rates of HCC, the pathways of iterative surgical treatment must be considered. The role of MILS is of particular interest as a bridge for salvage liver transplantation (SLT). An intention-to-treat survival analysis demonstrated that MILS resection was associated with a lower risk of SLT failure and death after SLT *vs.* open surgery (74% and 71% risk reduction, respectively), mitigating the higher operative morbidity in SLT seen in previous studies. These results were confirmed with a propensity score matching a balanced population for the type of resections and tumor size, but most laparoscopic LRs were wedge or segmentectomies^[33].

The data collected from our institute confirm the advantages of laparoscopic surgery in the first surgical treatment of HCC. In fact, over 80% of patients who have undergone reoperation had undergone a first laparoscopic operation even though there are fewer laparoscopic interventions than laparotomies overall. This underlines that the first laparoscopic approach guarantees better chances of reoperation. A similar observation can be made for patients who have a better chance of transplant due to their age and clinical conditions. However, it is important to consider the small sample size of OLT as a second-line surgical treatment after MILS. This number is expected to grow due to the increased prevalence of MILS and the changes in Italy's organ allocation score since 2018^[4,34-36].

Contrary to the past evidence, prior surgery does not represent an absolute contraindication to liver transplantation, especially if the first surgery is laparoscopic. In our institute, the vast majority of patients

transplanted after a first surgical treatment of hepatocellular carcinoma had performed laparoscopic surgery. The adhesions found intraoperatively in no case compromised or complicated the hepatectomy during transplantation. This allows us to consider laparoscopic liver resection as a bridge therapy for transplantation, ensuring less crowding of waiting lists, a desirable condition in certain areas dealing with a shortage of donors. Although the number of transplants performed in patients already operated on is very small, there are many patients who, undergoing LLR, will have no contraindications or difficulties in carrying out a transplant procedure.

Laparoscopy, compared to an open approach, is associated with similar oncological results and better short-term outcomes. Minimally invasive liver surgery preserves the abdominal wall, minimizes peritoneal trauma, and decreases overall complication rates. In addition, there are fewer liver complications such as ascites and liver failure, decreased pedicle clamping time, and shorter postoperative hospital stays compared to open LR^[17]. For HCC patients, LLR prior to LT provides the benefit of significantly reduced de-listing and death after LT.

In conclusion, liver resection is the gold-standard treatment for HCC, second to liver transplantation, but long-term outcomes post-resection are poor due to high recurrence rates. As for intrahepatic recurrence, repeat hepatectomy is still considered to be one of the most important potential curative therapies. The possibility of needing to reoperate a patient who has already undergone hepatic-resective surgery for HCC is high. For this reason, it becomes increasingly important to perform laparoscopic surgery whenever possible. Laparoscopy determines fewer postoperative adhesions, thus posing the best conditions for both hepatic-resective and transplant reoperation.

DECLARATIONS

Authors' contributions

Made substantial contributions to conception and design of the study and performed data analysis and interpretation: Pagano D, Khouzam S, Barbara M, Di Marco V, Pietrosi G, Maringhini M, Canzonieri M, Calamia S, Gruttadauria S

Performed data acquisition, as well as provided administrative, technical, and material support: Pagano D, Khouzam S, Gruttadauria S

Availability of data and materials

Not applicable.

Financial support and sponsorship

Sources of support: departmental sources.

Conflicts of interest

All authors declared that there are no conflicts of interest.

Ethical approval and consent to participate

The research has been performed in accordance with the Declaration of Helsinki. The study "Protective benefit of minimally invasive liver surgery for hepatocellular carcinoma prior to transplant" published in *Hepatoma Research* was approved by the sectional Ethical Committee of IRCCS ISMETT, and the committee's reference number is: IRRB/42/16. Informed consent was obtained from the patients to use their medical records for research and publication and attached as Related Files.

Consent for publication

Written consent was obtained from the patient and institution.

Copyright

© The Author(s) 2022.

REFERENCES

1. Yang JD, Roberts LR. Epidemiology and management of hepatocellular carcinoma. *Infect Dis Clin North Am* 2010;24:899-919, viii. DOI PubMed PMC
2. Llovet JM, Kelley RK, Villanueva A, et al. Hepatocellular carcinoma. *Nat Rev Dis Primers* 2021;7:6. DOI PubMed
3. Cillo U, Vitale A, Polacco M, Fasolo E. Liver transplantation for hepatocellular carcinoma through the lens of transplant benefit. *Hepatology* 2017;65:1741-8. DOI PubMed
4. Khouzam S, Pagano D, Barbàra M, et al. Impact of Italian score for organ allocation system on deceased donor liver transplantation: a monocentric competing risk time-to-event analysis. *Transplant Proc* 2019;51:2860-4. DOI PubMed
5. Shimamura T, Goto R, Watanabe M, Kawamura N, Takada Y. Liver transplantation for hepatocellular carcinoma: how should we improve the thresholds? *Cancers (Basel)* 2022;14:419. DOI PubMed PMC
6. Gruttadauria S, di Francesco F, Vizzini GB, et al. Early graft dysfunction following adult-to-adult living-related liver transplantation: predictive factors and outcomes. *World J Gastroenterol* 2009;15:4556-60. DOI PubMed PMC
7. Vogel A, Cervantes A, Chau I, et al; ESMO Guidelines Committee. Hepatocellular carcinoma: ESMO Clinical Practice Guidelines for diagnosis, treatment and follow-up. *Ann Oncol* 2018;29:iv238-55. DOI PubMed
8. Vogel A, Cervantes A, Chau I, et al. Correction to: "hepatocellular carcinoma: ESMO Clinical Practice Guidelines for diagnosis, treatment and follow-up". *Ann Oncol* 2019;30:871-3. DOI PubMed
9. Gruttadauria S, Pagano D, Corsini LR, et al. Impact of margin status on long-term results of liver resection for hepatocellular carcinoma: single-center time-to-recurrence analysis. *Updates Surg* 2020;72:109-17. DOI PubMed
10. Kudo M, Han KH, Ye SL, et al. A changing paradigm for the treatment of intermediate-stage hepatocellular carcinoma: Asia-Pacific primary liver cancer expert consensus statements. *Liver Cancer* 2020;9:245-60. DOI PubMed PMC
11. Sato T, Kondo F, Ebara M, et al. Natural history of large regenerative nodules and dysplastic nodules in liver cirrhosis: 28-year follow-up study. *Hepatol Int* 2015;9:330-6. DOI PubMed PMC
12. Coelho FF, Kruger JA, Fonseca GM, et al. Laparoscopic liver resection: experience based guidelines. *World J Gastrointest Surg* 2016;8:5-26. DOI PubMed PMC
13. Tranchart H, Di Giuro G, Lainas P, et al. Laparoscopic resection for hepatocellular carcinoma: a matched-pair comparative study. *Surg Endosc* 2010;24:1170-6. DOI PubMed
14. Lee KF, Chong CN, Wong J, Cheung YS, Wong J, Lai P. Long-term results of laparoscopic hepatectomy versus open hepatectomy for hepatocellular carcinoma: a case-matched analysis. *World J Surg* 2011;35:2268-74. DOI PubMed
15. van Dam RM, Wong-Lun-Hing EM, van Breukelen GJ, et al; ORANGE II Study Group. Open versus laparoscopic left lateral hepatic sectionectomy within an enhanced recovery ERAS[®] programme (ORANGE II-trial): study protocol for a randomised controlled trial. *Trials* 2012;13:54. DOI PubMed PMC
16. Le Roux F, Rebibo L, Cosse C, et al. Benefits of laparoscopic approach for resection of liver tumors in cirrhotic patients. *J Laparoendosc Adv Surg Tech A* 2018;28:553-61. DOI PubMed
17. Allaire M, Goumard C, Lim C, Le Cleach A, Wagner M, Scatton O. New frontiers in liver resection for hepatocellular carcinoma. *JHEP Rep* 2020;2:100134. DOI PubMed PMC
18. Troisi RI, Berardi G, Morise Z, et al. Laparoscopic and open liver resection for hepatocellular carcinoma with Child-Pugh B cirrhosis: multicentre propensity score-matched study. *Br J Surg* 2021;108:196-204. DOI PubMed
19. Krenzien F, Wabitsch S, Haber P, et al. Validity of the Iwate criteria for patients with hepatocellular carcinoma undergoing minimally invasive liver resection. *J Hepatobiliary Pancreat Sci* 2018;25:403-11. DOI PubMed
20. Ortiz Galindo SA, Haber PK, Benzing C, et al. Safety of intermittent Pringle maneuver during minimally invasive liver resection in patients with hepatocellular carcinoma with and without cirrhosis. *Langenbecks Arch Surg* 2022;407:235-44. DOI PubMed PMC
21. Vega EA, Kutlu OC, Joechle K, De La Cruz N, Ko D, Conrad C. Preoperative prognosticators of safe laparoscopic hepatocellular carcinoma resection in advanced cirrhosis: a propensity score matching population-based analysis of 1799 western patients. *J Gastrointest Surg* 2019;23:1157-65. DOI PubMed
22. Yu W, Rong W, Wang L, Wu F, Xu Q, Wu J. R1 hepatectomy with exposure of tumor surface for centrally located hepatocellular carcinoma. *World J Surg* 2014;38:1777-85. DOI PubMed
23. Gruttadauria S, Pagano D, Liotta R, et al. Liver volume restoration and hepatic microarchitecture in small-for-size syndrome. *Ann Transplant* 2015;20:381-9. DOI PubMed
24. Scilletta R, Pagano D, Spada M, et al. Comparative analysis of the incidence of surgical site infections in patients with liver resection for colorectal hepatic metastases after neoadjuvant chemotherapy. *J Surg Res* 2014;188:183-9. DOI PubMed
25. Gruttadauria S, Saint Georges Chaumet M, Pagano D, et al. Impact of blood transfusion on early outcome of liver resection for colorectal hepatic metastases. *J Surg Oncol* 2011;103:140-7. DOI PubMed
26. Gruttadauria S, Pagano D, Luca A, Gridelli B. Small-for-size syndrome in adult-to-adult living-related liver transplantation. *World J Gastroenterol* 2010;16:5011-5. DOI PubMed PMC
27. Gruttadauria S, Parikh V, Pagano D, et al. Early regeneration of the remnant liver volume after right hepatectomy for living donation: a multiple regression analysis. *Liver Transpl* 2012;18:907-13. DOI PubMed
28. Enomoto S, Tamai H, Shingaki N, et al. Assessment of hepatocellular carcinomas using conventional magnetic resonance imaging

- correlated with histological differentiation and a serum marker of poor prognosis. *Hepatol Int* 2011;5:730-7. DOI PubMed PMC
29. Kim SS, Lee S, Kim MJ. Prognostic factors of gadoteric acid-enhanced MRI for postsurgical outcomes in multicentric hepatocellular carcinoma. *Eur Radiol* 2021;31:3405-16. DOI PubMed
 30. Gruttadauria S, Barbera F, Conaldi PG, et al. Clinical and molecular-based approach in the evaluation of hepatocellular carcinoma recurrence after radical liver resection. *Cancers (Basel)* 2021;13:518. DOI PubMed PMC
 31. Bae JJ, Rho JW, Lee TJ, et al. Loss of heterozygosity on chromosome 10q23 and mutation of the phosphatase and tensin homolog deleted from chromosome 10 tumor suppressor gene in Korean hepatocellular carcinoma patients. *Oncol Rep* 2007;18:1007-13. PubMed
 32. Fujiwara Y, Hoon DS, Yamada T, et al. PTEN / MMAC1 mutation and frequent loss of heterozygosity identified in chromosome 10q in a subset of hepatocellular carcinomas. *Jpn J Cancer Res* 2000;91:287-92. DOI
 33. Levi Sandri GB, Lai Q, Ravaioli M, et al. The role of salvage transplantation in patients initially treated with open versus minimally invasive liver surgery: an intention-to-treat analysis. *Liver Transpl* 2020;26:878-87. DOI PubMed
 34. Aldrighetti L, Ratti F, Cillo U, et al; Italian Group of Minimally Invasive Liver Surgery (I GO MILS). Diffusion, outcomes and implementation of minimally invasive liver surgery: a snapshot from the I Go MILS (Italian Group of Minimally Invasive Liver Surgery) Registry. *Updates Surg* 2017;69:271-83. DOI PubMed
 35. Gruttadauria S, Tropea A, Pagano D, et al. Mini-invasive approach contributes to expand the indication for liver resection for hepatocellular carcinoma without increasing the incidence of posthepatectomy liver failure and other perioperative complications: a single-center analysis. *J Laparoendosc Adv Surg Tech A* 2016;26:439-46. DOI PubMed
 36. Levi Sandri GB, Colasanti M, Aldrighetti L, et al; I Go MILS Group on HCC. Is minimally invasive liver surgery a reasonable option in recurrent HCC? *Updates Surg* 2022;74:87-96. DOI PubMed