

Case Report

Spontaneous intracranial hypotension complicated with cerebral venous thrombosis and subdural effusion: a case report

Murali Krishna Menon¹, Thara Prathap², Muhammed Jasim Abdul Jalal³

¹Department of Neurology, Lakeshore Hospital and Research Centre, Ernakulam 682040, Kerala, India.

²Department of Radiology, Lakeshore Hospital and Research Centre, Ernakulam 682040, Kerala, India.

³Department of Family Medicine, Lakeshore Hospital and Research Centre, Ernakulam 682040, Kerala, India.



Dr. Muhammed Jasim Abdul Jalal, a family physician, trained in general medicine, general surgery, women and child health and preventive medicine. He believes in the concept of medical care with a preventive and holistic approach. He has special interest in clinical neurology.

ABSTRACT

Spontaneous intracranial hypotension treatment can be complicated by concomitant cerebral venous thrombosis and subdural hematoma. A 48 years old male, presenting orthostatic headache and neck pain for 1 month displayed sagittal sinus thrombosis and bilateral subdural effusions, as well as extradural fluid collection at T3-T8 level, upon magnetic resonance imaging. Cerebrospinal fluid opening pressure was 50 mmH₂O, and a leak was confirmed at C2-C3 level by computed tomography (CT) myelogram. The presence of subdural hematoma precluded anticoagulation treatments. An autologous epidural blood patch at C2-C3 level under CT guidance improved the patient's condition, remaining free of residual symptoms or recurrence at six-month follow-up.

Key words: Spontaneous intracranial hypotension; cerebral venous thrombosis; subdural effusion; autologous epidural blood patch

INTRODUCTION

Orthostatic headache, low cerebrospinal fluid (CSF) pressure, and noninterrupted diffuse pachymeningeal enhancement observed upon magnetic resonance imaging (MRI) of the brain, characterize spontaneous intracranial hypotension (SIH). The estimated annual incidence of this uncommon disorder is 5 per 100,000, and its cause lies in spontaneous CSF leaks that result in CSF hypovolemia and hypotension (CSF opening pressure < 60 mmH₂O).^[1] CSF composition may be normal or show increased protein content and

pleocytosis.

SIH cases occasionally present with concomitant subdural effusions and, more rarely, cerebral venous thrombosis (CVT) (2% of patients).^[3] The most characteristic brain MRI finding in SIH is diffuse pachymeningeal enhancement, that is caused by an increase in venous blood volume secondary to the loss of CSF pressure.^[4] This alteration can lead to subdural hematoma and CVT through two main mechanisms: (1) SIH is associated with rostrocaudal sagging of the brain due to the loss of CSF buoyancy,^[4] resulting in a negative intracranial pressure gradient that may damage the venous endothelial lining by stretching the cerebral vessels, and can produce tears in bridging

Corresponding Author: Dr. Muhammed Jasim Abdul Jalal, Department of Family Medicine, Lakeshore Hospital and Research Centre, Nettoor.P.O., Maradu, NH 47-Byepass. Ernakulam 682040, Kerala, India. E-mail: poolspuff@gmail.com

Access this article online

Quick Response Code:



Website:
http://nnjournal.net

DOI:
10.20517/2347-8659.2015.35

This is an open access article distributed under the terms of the Creative Commons Attribution-NonCommercial-ShareAlike 3.0 License, which allows others to remix, tweak, and build upon the work non-commercially, as long as the author is credited and the new creations are licensed under the identical terms.

For reprints contact: service@oapublish.com

How to cite this article: Menon MK, Prathap T, Jalal MJA. Spontaneous intracranial hypotension complicated with cerebral venous thrombosis and subdural effusion: a case report. *Neuroimmunol Neuroinflammation* 2016;3:104-8.

Received: 06-09-2015; **Accepted:** 05-12-2015

veins in the dural border cell layer, causing them to rupture and leading to subdural hematoma; (2) the loss of CSF volume reduces absorption of CSF into the cerebral venous sinuses, resulting in increased blood viscosity in the venous compartment,^[5] which could contribute to dural sinus thrombosis in patients with risk factors for thrombosis. The general consensus is that CVT should be treated with heparin, since a meta-analysis concluded that this treatment is safe and is associated with a clinical trend (not statistically significant) of reduction in the risk of death and dependency. Thus, most of the reported SIH patients with CVT have been treated with anticoagulation so far along with bed rest, hydration and epidural blood patches (EBP) [Table 2].^[6-14] On the other hand, cases of large subdural hemorrhage require surgical drainage and treatment of the underlying cause of SIH. Most SIH patients without other complications recover after bed rest with foot end elevation, hydration and steroid therapy. Nevertheless, the mainstay of SIH treatment is the application of EBP at the CSF-leak site (injection of 10-20 mL of autologous blood into the spinal epidural space).^[15] Relief of symptoms, particularly orthostatic headache, is often dramatic after EBP, and if it fails it can be repeated. On the other hand, direct EBP at the cervical area is challenging due to the narrow space of region and its proximity to important neural structures, therefore, this treatment is not performed in all cervical-leak cases. With this case report we aimed to provide further evidence that

EBP is a feasible and efficient treatment for SIH with CSF leak in the cervical area, subdural hematoma and CVT.

CASE REPORT

A 48 years old Indian male presented with headache and neck pain of 1 month duration. The patient had severe occipital headache with visual analogue score of 9. The headache worsened in the upright position and was completely relieved after lying down. The patient was otherwise normal, without any significant past clinical history.

On examination, the patient was conscious, oriented and afebrile, with a pulse rate of 82 beats per minute and blood pressure of 130/80 mmHg. Eye movements were normal in all directions and there was no sign of nystagmus. Both pupils were equal and reactive to light. Cranial nerve and fundus examinations were also normal and no motor weakness or sensory loss was present. Flexor plantar response was positive and bilateral. No signs of meningeal irritation nor focal neurological deficits were found.

T2 weighted sequences from the MRI of the brain showed bilateral symmetrical fronto-parietal and occipital subdural effusions [Figure 1A], while T1 weighted sequences unveiled sagittal sinus thrombosis [Figure 1B]. T2 sequences from the spine MRI revealed elliptical high signal extra axial collection posterior to the spinal cord at T3 to T8 level, which was suggestive of CSF leak [Figure 2].

A lumbar puncture with CSF manometry was performed under aseptic conditions, finding a CSF opening pressure of 50 mmH₂O. CSF content analysis [Table 1] showed elevated proteins [normal CSF protein ranges from 20-40 mg/dL]. CT myelography revealed extradural contrast extravasation at C2-C3 level [Figure 3A].

Vasculitic work-up yielded negative results for anti-nuclear antibody, anti-double stranded DNA antibody, perinuclear anti-neutrophil cytoplasmic antibody, cytoplasmic anti-neutrophil cytoplasmic antibody and anti-phospholipid antibody. Thrombophilia screening resulted also negative, as anti-thrombin, protein C and protein S were normal. Factor V Leiden

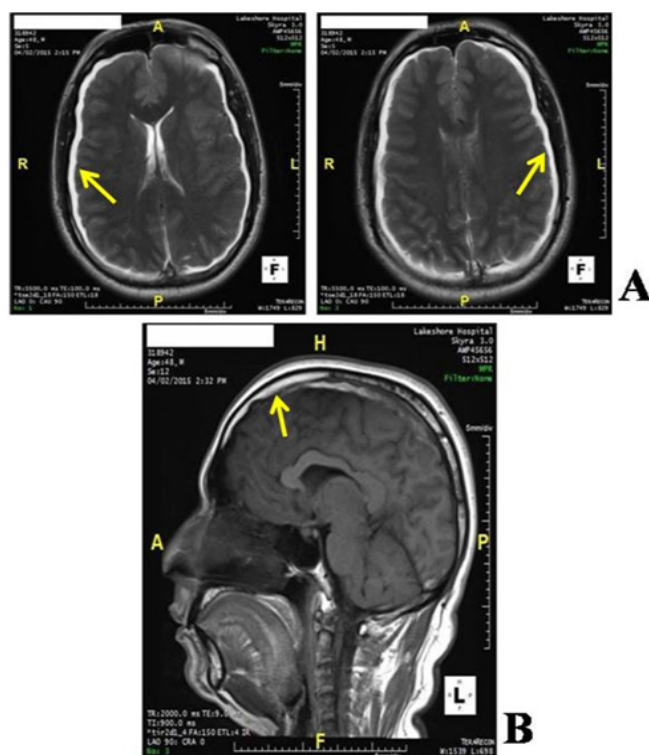


Figure 1: MRI brain. (A) T2 weighted sequences showing bilateral symmetrical fronto-parietal and occipital subdural effusions (as marked by the arrow); (B) T1 weighted sequences showing sagittal sinus thrombosis (as marked by the arrow)

Table 1: Cerebrospinal fluid analysis	
Parameters	Results
CSF colour	Clear fluid, no xanthochromia, no turbidity
CSF pressure	50 mmH ₂ O
CSF protein	315 mg/dL
CSF sugar	93 mg/dL
CSF cell count	Occasional RBCs only

CSF: cerebrospinal fluid; RBCs: red blood cells

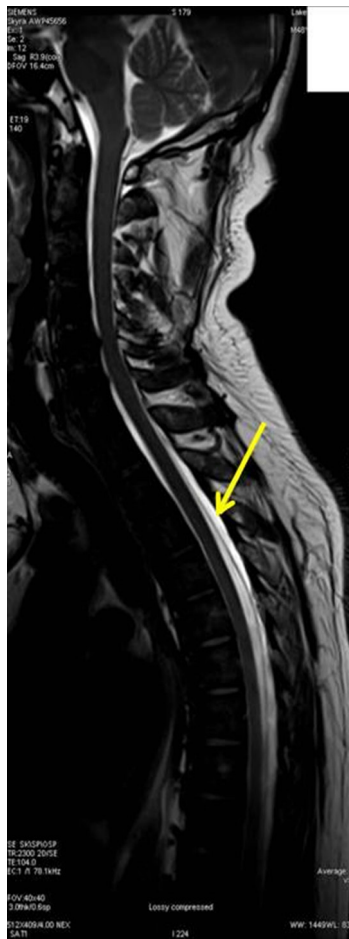

Figure 2: T2 sagittal sequence from the spine MRI showing elliptical high signal extra axial collection posterior to the spinal cord at T3 to T8 level (as marked by the arrow, suggestive of CSF leak)

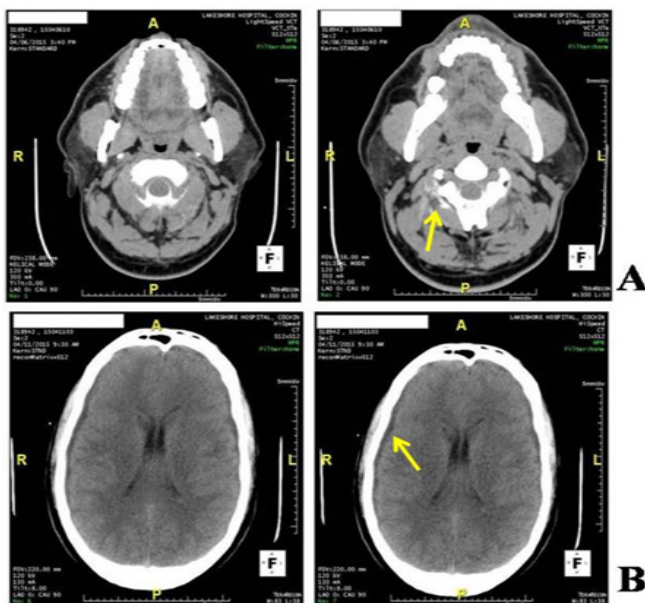


Figure 3: CT. (A) Myelography showing extradural contrast extravasation at C2-C3 level (as marked by the arrow); (B) plain CT brain after epidural blood patch showing mild reduction in the extent of subdural effusions (as marked by the arrow)

mutation was also not detected.

The patient was advised complete bed rest with foot end elevation and to remain adequately hydrated.

Anticoagulation for CVT was precluded since he had bilateral subdural effusions and CVT was secondary to SIH. After 24 h of bed rest and adequate hydration, since the patient was very much symptomatic, a cervical autologous epidural blood patch with 10 mL of blood was performed under CT guidance and achieved the resolution of the symptoms within a week without worsening the CVT. Brain CT taken on day 5 following epidural blood patch showed mild reduction in the extent of subdural effusions [Figure 3B]. In addition, the patient showed no residual symptoms or recurrence at six-month follow-up.

DISCUSSION

Literature clearly defines clinical signs, typical MRI findings and treatment options of SIH.^[3] In an intact cranium, the total intracranial volume must be constant according to the Monroe-Kellie hypothesis.^[4] SIH usually occurs due to spontaneous CSF leaks in the inferior cervical and superior thoracic spine. Mechanical stress, meningeal diverticula and connective tissue diseases have been reported as the potential risk factors for the development of SIH.

The Monroe-Kellie hypothesis states that the decrease in intracranial blood volume is compensated by the dilatation of the cerebral veins.^[4] Furthermore, CSF loss reduces the CSF absorption into the cerebral venous sinuses leading to an increase in blood viscosity in the cerebral compartment.

In our patient, epidural blood patch was performed earlier within 24 h of conservative therapy since the patient was very much symptomatic and SIH was complicated with subdural effusions and CVT.

In 2015, Kapoor and Ahmed did a comprehensive electronic literature search to include studies that reported on performance of cervical EBPs in patients with CSF leak at the cervical level.^[16] Their review provides Class II level of evidence that cervical EBPs are safe and effective in relieving positional headache due to CSF leak. A total of 15 studies, reporting on 19 patients were included. All patients presented with a headache that increased in the standing position, and improved in the supine position. All patients were identified to have a CSF leak at the cervical level. Eight patients first underwent a lumbar EBP, without complete, long-term relief. All these patients, along with 11 patients who did not undergo a lumbar EBP prior to cervical EBP, reported complete, long-term pain relief. EBPs were mostly done in the prone position, using imaging guidance. An average of 5-8 mL of autologous blood was injected in the epidural space. No major neurological complications were

Table 2: All the reported data of patients with cerebral venous thrombosis and spontaneous intracranial hypotension in whom the site of cerebrospinal fluid leak was demonstrated.

Authors	Year	Age	Gender	OP	Location of CSF leak	AC	EBP
Flemming and Link ^[6]	2005	31	M	?	Cervical/Thoracic	Yes	No
Kataoka <i>et al.</i> ^[7]	2007	45	M	40	Cervical/Thoracic	Yes	Yes
Albayram <i>et al.</i> ^[8]	2007	45	M	?	Thoracic	Yes	Yes
Wang <i>et al.</i> ^[9]	2007	33	F	80	Cervical	No	Yes
Tan <i>et al.</i> ^[10]	2008	26	F	50	Thoracic	Yes	Yes
Schievink and Maya ^[11]	2008	32	M	0	Thoracic	Yes	Yes
Schievink and Maya ^[11]	2008	43	M	40	Thoracic	Yes	Yes
Yoon <i>et al.</i> ^[12]	2011	26	M	50	Cervical	No	Yes
Dangra <i>et al.</i> ^[13]	2011	35	M	?	Cervical	Yes	No
M. C. Garcia-Carreira <i>et al.</i> ^[14]	2014	29	F	30	Thoracic	Yes	Yes
M. C. Garcia-Carreira <i>et al.</i> ^[14]	2014	54	M	20	Thoracic	Yes	Yes
Present Case	2015	48	M	50	Cervical	No	Yes

CSF: cerebrospinal fluid; OP: opening pressure (mm H₂O); AC: anticoagulation; EBP: epidural blood patch; age (years); M: male; F: female.

reported in any patient.

In 2014, Garcia-Carreira *et al.*^[14] described two cases of spontaneous intracranial hypotension associated with cerebral venous thrombosis. In one case, extensive cerebral venous thrombosis involved the superior sagittal sinus and multiple cortical cerebral veins. In the other case, only a right frontoparietal cortical vein was involved. When spontaneous intracranial hypotension and cerebral venous thrombosis occur together, it raises difficult practical questions about the treatment of these two conditions. In most reported cases, spontaneous intracranial hypotension was treated conservatively and cerebral venous thrombosis was treated with anticoagulation. Garcia-Carreira *et al.*^[14] supported aggressive treatment of the underlying cerebrospinal fluid leak.

Again in 2015, Wang E and Wang D reported a case of successful treatment of a patient with spontaneous intracranial hypotension correlated with MRI finding of cerebrospinal fluid (CSF) leak with extradural collection at the upper cervical spinal level.^[17] This patient received two lumbar epidural blood patches without lasting relief. Later on, the radiographic evidence of prominent CSF leak with extradural fluid collection was noted at C1-2 level. The patient was then treated with a cervical epidural blood patch, which provided headache pain relief lasting 6 months. A second cervical epidural blood patch was performed, and the patient was headache free since then.

Table 2 shows all the reported data of patients with cerebral venous thrombosis and spontaneous intracranial hypotension in whom the site of cerebrospinal fluid leak was demonstrated. All these patients who received EBP responded very well and was symptom free during the follow up.

There remain some controversies in treatment of SIH complicated with CVT. Primary conservative management of SIH accompanied by anticoagulation for CVT is usually advised. If the symptoms of SIH

persist even after bed rest and adequate hydration, epidural blood patching could be considered. Anticoagulation for CVT can be withheld till the symptoms of SIH get controlled. The mortality of CVT is 5% but with SIH, it can be increased. Therefore firstly SIH should be treated.

In 2013, Güler *et al.*^[18] reported a case of cerebral venous thrombosis accompanying with intracranial hypotension. They advocated anticoagulation for this patient only after SIH symptoms resolved. CVT is not reported in any SIH case after the resolution of symptoms. So, in our patient we tried to treat the primary cause, SIH and hence anticoagulation was precluded. We advocate primary treatment of the underlying spinal CSF leak, particularly when symptoms of SIH persist. In our patient, we did an autologous epidural blood patch at the site of CSF leak under CT guidance and the patient improved. In addition, the patient had no residual symptoms or recurrence at six-month follow-up. We think that our case can add additional information to the literature regarding the management of CVT in SIH.

Financial support and sponsorship

Nil.

Conflicts of interest

There are no conflicts of interest.

REFERENCES

- Schievink WI. Spontaneous spinal cerebrospinal fluid leaks. *Cephalalgia* 2008;28:1345-56.
- Schievink WI. Spontaneous spinal cerebrospinal fluid leaks and intracranial hypotension. *JAMA* 2006;295:2286-96.
- Mokri B. The Monroe-Kellie hypothesis: applications in CSF volume depletion. *Neurology* 2001;56:1746-8.
- Fabricius J, Klotz JM, Hofmann E, Behr R, Neumann-Haefelin T. Cerebral venous thrombosis and subdural hematoma: complications of spontaneous intracranial hypotension. *Fortschr Neurol Psychiatr* 2012; 80:599-601.
- Flemming KD, Link MJ. Spontaneous CSF leak complicated by venous thrombosis and dural arteriovenous fistula. *Cephalalgia* 2005; 25:751-3.
- Kataoka H, Tanizawa E, Ueno S. Spontaneous intracranial

- hypotension is associated with a risk of venous sinus thrombosis and subdural hematoma. *Cerebrovasc Dis* 2007;23:315-7.
7. Albayram S, Tasmali KM, Gunduz A. Can spontaneous intracranial hypotension cause venous sinus thrombosis? *J Headache Pain* 2007; 8:200-1.
 8. Wang YF, Fuh JL, Lirng JF, Chang FC, Wang SJ. Spontaneous intracranial hypotension with isolated cortical vein thrombosis and subarachnoid hemorrhage. *Cephalalgia* 2007;27:1413-7.
 9. Tan K, Venketasubramanian N, Hwang CY, Lim CC. My headache does not get better when I lie down: spontaneous intracranial hypotension complicated by venous thrombosis. *Headache* 2008;48:149-52.
 10. Schievink WI, Maya MM. Cerebral venous thrombosis in spontaneous intracranial hypotension. *Headache* 2008; 48:1511-9.
 11. Yoon KW, Cho MK, Kim YJ, Lee SK. Sinus thrombosis in a patient with intracranial hypotension: a suggested hypothesis of venous stasis. *Interv Neuroradiol* 2011;17:248-51.
 12. Dangra VR, Sharma YB, Bharucha NE, Deopujari CE. An interesting case of headache. *Ann Indian Acad Neurol* 2011;14:130-2.
 13. Garcia-Carreira MC, Vergé DC, Branera J, Zauner M, Herrero JE, Tió E, Perpinyà GR. Cerebral venous thrombosis in two patients with spontaneous intracranial hypotension. *Case Rep Neurol Med* 2014;2014:528268.
 14. Kim BW, Jung YJ, Kim MS, Choi BY. Chronic subdural hematoma after spontaneous intracranial hypotension: a case treated with epidural blood patch on c1-2. *J Korean Neurosurg Soc* 2011;50:274-6.
 15. Kapoor SG, Ahmed S. Cervical epidural blood patch--A literature review. *Pain Med*. 2015; 16:1897-904.
 16. Wang E, Wang D. Successful treatment of spontaneous intracranial hypotension due to prominent cervical cerebrospinal fluid leak with cervical epidural blood patch. *Pain Med* 2015;16:1013-8.
 17. Güler S, Deniz Ç, Utku U, Kehaya S. A case of cerebral venous thrombosis accompanying with intracranial hypotension: headache that changing character. *Agri* 2013;25:141-4.