

Review

Open Access



Soft-tissue management and reconstruction of lower-extremity trauma

Sammy Othman¹, Saïd C. Azoury², Kevin M. Klifto³, L. Scott Levin⁴, Stephen J. Kovach⁵

¹Department of Plastic and Reconstructive Surgery, Northwell Health, New York, NY 1075, USA.

²Division of Plastic and Reconstructive Surgery, Department of Surgery, Memorial Sloan Kettering Cancer Center, New York, NY 1075, USA.

³Division of Plastic and Reconstructive Surgery, Department of Surgery, University of Missouri, Columbia, MO 65211, USA.

⁴Department of Orthopedic Surgery, University of Pennsylvania, Philadelphia, PA 19104, USA.

⁵Division of Plastic and Reconstructive Surgery, Department of Surgery, University of Pennsylvania, Philadelphia, PA 19104, USA.

Correspondence to: Dr. Sammy Othman, Department of Plastic and Reconstructive Surgery, Northwell Health, 2000 Marcus Ave New Hyde Park, New York, NY 1075, USA. E-mail: Sothman@northwell.edu; sothman13@gmail.com

How to cite this article: Othman S, Azoury SC, Klifto KM, Levin LS, Kovach SJ. Soft-tissue management and reconstruction of lower-extremity trauma. *Plast Aesthet Res* 2022;9:29. <https://dx.doi.org/10.20517/2347-9264.2021.135>

Received: 19 Dec 2021 **First Decision:** 15 Feb 2022 **Revised:** 15 Feb 2022 **Accepted:** 24 Feb 2022 **Published:** 9 Apr 2022

Academic Editor: Matthew L Iorio **Copy Editor:** Xi-Jun Chen **Production Editor:** Xi-Jun Chen

Abstract

Soft-tissue management and subsequent salvage of the lower extremity following trauma has long presented difficult challenges to the plastic surgeon. Trauma to the lower extremity can produce long-term sequelae consisting of psychological trauma, functional deficits, and increased costs to the healthcare system. Avoiding incorrect management is important, and is compounded by the fact that few guidelines exist on appropriate treatment and patient counseling. This study aims to describe the authors' experience at a large limb salvage center in order to further delineate management strategies.

Keywords: Reconstructive surgery, trauma, lower extremity, microsurgery, soft-tissue

INTRODUCTION

Composite lower extremity reconstruction has long presented delicate challenges to surgeons and requires a comprehensive multidisciplinary approach. Defects, most often secondary to trauma and oncology, necessitate appropriate diagnostic strategies and timely interventions if limb salvage is to be successful. The



© The Author(s) 2022. **Open Access** This article is licensed under a Creative Commons Attribution 4.0 International License (<https://creativecommons.org/licenses/by/4.0/>), which permits unrestricted use, sharing, adaptation, distribution and reproduction in any medium or format, for any purpose, even commercially, as long as you give appropriate credit to the original author(s) and the source, provide a link to the Creative Commons license, and indicate if changes were made.



burden of lower extremity trauma, in particular, cannot be overstated. In 2005, it was found that 1.6 million people living in the United States suffer from lower extremity loss, with the number projected to double in the coming years^[1]. Nearly 50% of cases of lower extremity loss are due to traumatic etiology^[1]. Furthermore, even in those with salvaged limbs, there exists a long-term functional deficit, with the psychological burden to patients, and costs to both the patient and the health care system^[2,3].

The role of the plastic surgeon in lower extremity reconstruction in larger centers largely centers upon ensuring adequate soft-tissue coverage. This is often particularly challenging in the setting of traumatic defects, as local soft-tissue can be limited, necessitating the utilization of free tissue transfer^[4,5]. Regardless, selecting the optimal method per clinical scenario is a critical junction between limb salvage and the need for amputation. The urgency in achieving limb salvage was highlighted by The 2002 Lower Extremity Assessment Project, which showed that outcomes might be similar between those who undergo limb salvage and those necessitating amputation^[6]. Thus, the question of salvage *vs.* amputation remains nuanced and must be considered within the context of several factors. In 2009, the British Association of Plastic, Reconstructive and Aesthetic Surgeons and British Orthopaedic Association published guidelines for open limb fractures, though this has not been widely adopted as definitive^[7]. There remains very little objective and widely applicable data regarding the appropriate treatment algorithm in relation to a patient-centered approach^[8]. Furthermore, given the difficulty presented by many of these cases, some centers lack the adequate means or personnel to appropriately treat the traumatic lower extremity^[9].

Despite advances in the role of the plastic surgeon, as well as leaps made in wound care management, such as the development of negative pressure wound therapy (NPWT), limb salvage remains a difficult clinical scenario. The use of free tissue transfer for reconstruction has the highest flap failure and complication rates of any anatomic region and may result in amputation secondarily^[10]. Failed limb salvage remains an unfortunate outcome that results in functional deficits, psychological trauma, and an increasingly elevated cost burden^[3,6]. Avoiding incorrect management is important, and is compounded by the fact that few guidelines exist on appropriate treatment and patient counseling. This study aims to describe the authors' experience at a large limb salvage center in order to further delineate management strategies.

DIAGNOSIS, MULTIDISCIPLINARY COLLABORATION, AND INITIAL APPROACHES

The general approach to lower extremity trauma requires a thorough examination and appropriate diagnosis of deficits and treatment strategies. This is facilitated by experts of several disciplines, including, but not limited to, trauma surgeons, vascular surgeons, orthopedic surgeons, and plastic surgeons. The ever-growing orthoplastic approach, a term coined by Dr. L. Scott Levin and Dr. Sterling Bunnell, incorporates philosophies of orthopedic and plastic surgeons for management of traumatic lower extremity injuries, and has been shown to improve outcomes^[11,12].

At the authors' institution, a thorough physical examination helps guide the next steps of management. Every patient receives radiographic imaging to evaluate bony structure and stability. The role of vascular imaging is less liberalized, indicated in the setting of an equivocal physical examination that introduces the potential or suspicion for vessel injury. In this situation, the authors employ computer-topographic angiography, outlining the presence of major vessel injury [i.e., anterior tibial, posterior tibial (PT), and peroneal artery]. This serves the purpose of not only involving vascular surgeons, but also in the pre-operative planning if microsurgical intervention is necessary for soft-tissue restoration.

In the case of obvious vascular injury, the vascular surgeon must emergently be consulted if not done so already to avoid an ischemic limb. Even so, vascular injuries should promptly be identified as this also

serves a role in successful soft-tissue coverage through increased tissue vascularization as well as providing recipient sites in the case where a free flap may be necessary.

Simultaneously, orthopedic surgeons will address bony defects. In order to optimize the wound bed and soft-tissue efficiency, collaboration at this stage is crucial; the goals for soft-tissue coverage in concordance with orthopedic planning will ensure an appropriate pathway in the initial stages, particularly in the complex patient. Regardless, this phase begins with bony restoration. Oftentimes, the defects will necessitate hardware for bony restoration by orthopedic surgeons. Unfortunately, even with proper collaboration, communication, and pre-operative planning, this may require additional debridement or discontinuity of native soft-tissue in order to ensure bony correction^[8,11,13,14]. This is highlighted in the setting of prolonged orthopedic rehabilitation, as further soft-tissue coverage may be required. Regardless, the expected phases of recovery can be planned for with early onset collaboration and planning.

When collaboration is ensured, the plastic surgeon must optimize the wound bed and surrounding soft-tissue regardless of the repair strategy. Early debridement is essential for success, as multiple studies have indicated that warding off potential infection, or minimizing already-seeded harmful microbes, increases the rate of salvage of bone and soft-tissue, as well as overall limb preservation^[15]. The authors advocate for meticulous debridement as needed (i.e., save tissue that can be saved), as this helps facilitate definitive reconstruction by minimizing the ultimate area of the final defects. It goes without saying that this can be the difference between a local flap and more invasive procedures such as the recruitment of a free flap or staged local reconstruction. Anecdotally, we find that this collaboration and open communication with expert colleagues in other disciplines facilitate these goals^[8].

TISSUE TEMPORIZATION

Once the initial repair and debridement have commenced, the authors aim for immediate reconstruction. However, oftentimes, the setting of extensive trauma will not allow for immediate reconstruction. This can be for several reasons - the complicated trauma patient may require several urgent interventions prior to lower extremity intervention, i.e., life over limb. Secondly, extensive defects may present to centers lacking the microsurgical expertise necessary to address the extent of soft-tissue coverage^[4,5,14]. Finally, orthopedic and vascular intervention may require staged approaches that complicate the ability to achieve definitive coverage^[16]. The late Dr. Godina^[17], a pioneer across plastic surgery and in the realm of limb salvage and lower extremity trauma, advocated for early soft-tissue coverage within three days of presentation in his landmark article published in 1986. Though this long held up as an important tenant of limb salvage, subsequent advances in wound care, microbial management, and soft-tissue temporization have made it possible to achieve strong outcomes in a delayed fashion.

In recent years, several studies from high-volume trauma institutions, including our own, have advocated for anywhere between 7-90 days in achieving strong outcomes^[18,19]. Central to this principle has been the advent of the wound vacuum and NPWT. In brief, NPWT facilitates increased blood flow and infection mitigation within the wound bed, helping to provide some of the advantages of soft-tissue coverage. Subsequently, this may allow for “ladder stepdown”, where initial careful debridement and subsequent granulation can minimize defect size to allow for local tissue options that were previously untenable^[18,20]. The early application of NPWT has been shown to increase reconstructive success; however, this necessitates several important caveats - early debridement and clearance of gross infection and necrotic tissue are crucial to maximizing NPWT success^[21]. Further, the use of NPWT over exposed bone, tendon, nerves, or blood vessels must be met with careful consideration, and is most often times not indicated. This is especially true in the setting of osteomyelitis. In these situations, wounds can be temporized through a

variety of methods, including traditional wet-to-dry with appropriate antibiotic-impregnated dressings, antibiotic beads, and/or selective coverage. However, the authors reiterate that early debridement is the most adequate and important first step to optimal wound bed preparation.

Though the authors outline their principles in delayed coverage, the authors advocate for immediate reconstruction when possible. This helps reduce patient morbidity and hospital course, improves cost-analysis and health care savings, and may be associated with improved outcomes. Furthermore, even in wounds with adequate debridement and tissue temporization, the bacterial burden is prone to increase over time, and unnecessary delays to definitive coverage should be avoided.

DEFINITIVE COVERAGE

Once adequate debridement and tissue temporization have taken place, the plastic surgeon must evaluate the existing wound bed for reconstructive options. Though several options may be feasible, the role of the plastic surgeon is to take the clinical scenario into context to select the most appropriate modality.

Local tissue and dermal matrices

Several options exist for local tissue rearrangement as well as dermal matrices, skin grafts, or multiple combinations therein, often correlated with the famed “reconstructive ladder”^[22]. More defects are often amenable to skin grafting and dermal wound matrices. This has been enhanced in the setting of NPWT; when temporizing tissue, and allowing increased granulation, an appropriate wound bed can be established^[21].

The authors utilize dermal wound matrices whenever possible to avoid free tissue transfer, particularly in the lower extremity where oftentimes adjacent soft-tissue is scarce, and to avoid a more invasive procedure, and we have found good success in a variety of settings^[23-26]. Indeed, we prefer local tissue, though when this is not possible, or when there is scarcity of tissue, or in cases with a well-vascularized and clean wound bed, the authors will utilize skin grafts and dermal wound matrices. Other times, local tissue rearrangement for lower extremity salvage may lack the aesthetic match that patients seek in comparison to full-thickness skin grafting and dermal wound matrices^[27]. Further, the utilization of local tissue requires smaller wounds of healthy patients with lower comorbid risk factors for delayed wound healing (i.e., non-smoker, non-diabetic) in order to succeed^[28]. For these reasons, the authors again pivot to dermal wound matrices as a powerful adjunct option. However, several cases preclude its use. Wounds with active infection or questionable need for secondary re-operation are not strong candidates for these reconstructive modalities. Our institution has found good outcomes in this setting, indicating that dermal wound matrices can often show equivalent or better outcomes to their local- and free-flap counterparts^[25,26]. However, in situations with extensive vessel, nerve, and/or bony exposure, skin-grafting and dermal wound matrices are likely lesser options, with many surgeons opting to avoid these altogether in this context.

Several freestyle, random pattern local flap options, as well as named vessel local flap options, are available for reconstruction dependent upon the location of the defect as well as the adjacent zone of injury. The authors prefer these pedicled flaps, particularly the fasciocutaneous variety, for defects requiring likely future re-operation and those without filling defects or extensive dead space^[29]. In the setting of trauma, where local tissue may be lost or unusable, delayed elevation techniques may be necessary to ensure flap survival and maximize the area of coverage. When harvesting random pattern flaps, the authors utilize hand-held Doppler probes to ensure adequate vascularity in the harvesting of the flap. These include rotational, transposition, and advancement flaps. The advantage of these local flaps is they can be used anywhere along the extremity where the anatomy and injury permits, as well as saves tissue except in some

cases requiring secondary skin grafting to the donor site, though this is much less common in the lower extremity reconstruction^[30]. One popular flap design is the propeller flap, allowing for distal or proximal coverage at significant lengths when rotated 180°. However, the authors prefer to avoid this flap where possible, as we have not seen high success rates as others have reported in the literature, likely due to the tenuous nature of the flap design mixed with the inflammatory milieu presenting in acute trauma settings^[31].

Named local flaps, particularly myofascial and myocutaneous based flaps, are well described in the literature based on the area of defects. The gastrocnemius has long been a workhorse in lower extremity reconstruction of the proximal third of the leg, owing to its wide reach, muscular bulk, and reliable anatomy, most commonly whence harvesting the medial head based on the medial sural artery. The soleus flap is traditionally taught as a useful tool for middle-leg trauma and dead space defects requiring the filling. Recently, it has also been described as useful for some distal defects, increasing its flexibility^[32,33]. The soleus has multiple dominant vascular pedicles dependent upon location, from proximal to distal being peroneal and PT, which also for this versatility and ability to harvest for various defects.

One named fasciocutaneous flap that introduces flexibility for both proximal and distal defects is the medial sural artery perforator flap^[34]. As mentioned, this can be particularly advantageous when smaller 3-dimensional defects are present that do not warrant free flap reconstruction. Additionally, for proximal defects, perhaps reaching the knee, the anterolateral thigh (ALT) flap has been described successfully as a “reverse ALT”, though its usage for this purpose requires retrograde based perforation and is often not the first choice for this purpose^[35-37]. Additionally, in the traumatic setting, the zone of injury can be extended to the distal blood supply, compromising the perforators on which the flap is based upon.

Unfortunately, for defects of the distal third, the traditional teaching is that these are often limited in the local tissue options available. Recent years have demonstrated this to be more of an archaic dogma, though it can be argued that wide range adoption of local options is still in its infancy given the difficulty and limited soft-tissue available to this area, especially when factoring in tissue loss that can accompany traumatic defects. However, when tissue is available, beyond the above-discussed options, some authors have detailed success utilizing several named perforator flaps based upon the peroneal artery, medial sural, and lateral sural arteries^[34,38].

Free tissue transfer

When dermal matrices and local tissue options are not feasible, it is then the authors will pivot to free tissue transfer. This can be for several indications, including, but not limited to, extensive tissue loss, inadequate wound beds, wounds requiring multiple future re-operation, and exposure of critical structures. When selecting a recipient site, factors that must be taken into consideration include the anatomic location of defect and the status of vascular perfusion. It has been suggested that vascular injury may serve as a surrogate for severity of defect, and injury to the posterior tibial artery, in particular, may be associated with worsened limb-salvage and flap-based outcomes, including flap failure^[19,39]. The posterior tibial artery is the most commonly selected recipient target for free flap reconstruction. Further, anastomosis outside the zone of injury or at a disease-free site is paramount to successful free tissue transfer in the lower extremity^[40].

The traditional teaching for free tissue transfer centers upon the debate between muscle-based and fascia-based free flaps. The initial school of thought was that muscle flaps may be better for filling dead space, particularly in infection-prone areas, and thus they were traditionally the preferred choice for most lower extremity trauma requiring free tissue reconstruction. However, recent research, including our own, has demonstrated that the clinical scenario should guide flap selection, and that each flap type has its preferred

modality^[41-43].

One indication for a fasciocutaneous flap is determined by the presence of orthopedic hardware. More specifically, fasciocutaneous flaps have greater ease of re-elevation, and when extensive orthopedic revision and re-operation is expected, the authors opt for these fasciocutaneous flaps^[44] [Figure 1]. This not only helps during the re-operative process, but also facilitates the time to definitive coverage, as anticipating re-operation may lend paucity in some surgeons in harvesting an immediate muscle flap due to the difficulty of re-insetting, instead opting for various tissue temporization techniques, which in turn may lead to worsened outcomes secondary to reduced time of vascularized soft-tissue coverage^[5,30,44]. Indeed, we have found that although Dr. Godina's original findings may not be as applicable to the current era, the general principles remain that extensive delays are likely associated with flap failure and loss of limb salvage^[18,20]. Again, the importance of open collaboration is highlighted. Similarly, when the three-dimensional volume of the defect is not extensive, we opt for the fasciocutaneous flap due to ease of harvest and general reduced donor site morbidity, pivoting on the fact that outcomes are at least likely equal in these scenarios.

Options for fasciocutaneous flaps are plentiful. The free ALT, with or without a cuff of vastus lateralis, is a traditionally used flap with a workhorse reputation, versatility, and ease of inset and re-elevation, and has been shown to be a powerful tool for an abundance of defects. One major limiting factor is that lower extremity trauma may preclude its use, as the zone of injury can extend to the soft-tissue surface area of the flap, or vascular damage can render the micro-vasculature inappropriate for use^[35-37,45-47]. Furthermore, orthopedic fixation may extend proximally, which also limits its use. Although the authors prefer the ALT, the scapular/parascapular fasciocutaneous or fascial flaps have also been documented with strong success^[45,48]. This also provides the unique opportunity to create a versatile number of chimeric flaps with vascularized muscle, bone, and nerve as necessary. However, the operative time and relative rare indication for chimeric components in lower extremity trauma may lend these flaps to be less desirable for this purpose. The tensor fascia lata flap has also been used for reconstruction of the lower extremity with good success. We also have used the lateral arm flap, though the teaching of this flap has dwindled in recent years. Additionally, the superficial circumflex iliac artery flap (SCIP flap) has been shown to be versatile for many purposes, though the strongest and most abundant literature comes from the Asian population, and its validity in the western-based population is less documented due to increased obesity^[49,50].

When considering myofascial or myocutaneous flaps, the free latissimus dorsi flap has been well documented for a number of defects owing to its broad bulk^[44,45]. An additional benefit is the possibility of neurotization if necessary, though this is a less likely use in lower extremity trauma; regardless, the option exists to attempt to restore meaningful function. A free rectus abdominis flap has also been documented with great success, and oftentimes, the microsurgeon will have good experience with the anatomy surrounding the harvest of this flap^[5,45,51,52]. However, the donor site morbidity may give pause to some given the potential for bulge and/or subsequent hernia occurrence, which can present its own difficult reconstructive challenges in the future. Similarly, for smaller defects, the free serratus flap has also been documented successfully. A free gracilis is an additional possibility, though, like the ALT flap discussed above, it may be precluded due to trauma and/or orthopedic intervention. However, this option also provides the ability for neurotization as needed^[51].

ADVANCES IN WOUND CARE

Many of the approaches discussed in this article are the culmination of experience and standard of care. Several future directions are possible in order to enhance the likelihood of success and optimize the odds of adequate soft-tissue and bony recovery and regeneration. The use of growth factors is previously

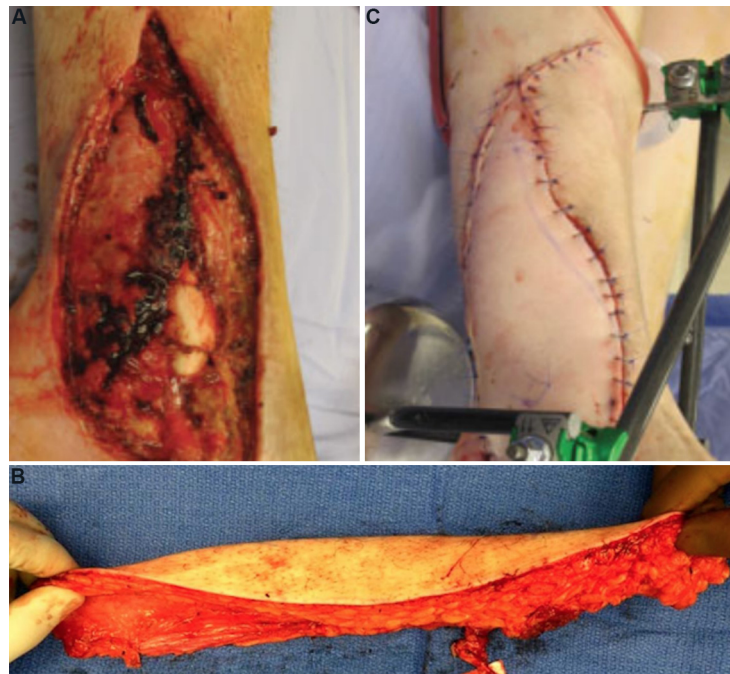


Figure 1. (A) Traumatic ankle fracture with extensive soft-tissue loss of the distal third of the leg. (B) Raised anterolateral thigh flap for coverage. (C) Flap inset for complete coverage with external fixator for bony stabilization.

documented for a variety of pathologies, including orthopedic bone healing, traumatic, and diabetic wounds^[53-55]. The current evidence indicates a role for traumatic lower extremity injury to enhance healing through the recruitment of increased blood flow and soft-tissue component migration. This may seem to indicate that these can safely be used in the setting of lower extremity trauma. More specifically, these factors compose various bone regeneration and soft-tissue growth factors, such as platelet-derived growth factor, vascular endothelial growth factor, and fibroblast growth factor. However, the evidence for support of these factors is thus far limited, with only small experiences published and wide range applicability low. Though these appear to have a role in healing and traumatic injury, the use of these factors expands, clear indications will come to fruition to guide their use.

CONCLUSION

A scoping review of lower extremity trauma indicates that an innumerable number of management strategies and approaches are employed dependent on surgeon preference, center resources, and institution and national guidelines. While many of these factors cannot be controlled, we advocate for the general and necessary tenants to remain, and these often fall under the skill level of nearly all plastic and reconstructive surgeons as well as most institutions. These fall under several general categories that are stressed early and often. Open collaboration between colleagues managing the trauma patient will facilitate appropriate planning, save time, and lend to the use of operation and re-operation when necessary. Success requires early debridement and tissue temporization when the plan the definitive reconstruction is delayed; however, immediate reconstruction is likely beneficial when possible. Finally, numerous successful options exist for definitive reconstruction that are selected by surgeon experience, center resources, and clinical scenario.

DECLARATIONS

Authors' contributions

Made substantial contributions to conception and design of the study and performed data analysis, acquisition, writing, and interpretation: Othman S, Azoury SC, Klifto KM, Levin LS, Kovach SJ

Provided administrative, technical, and material support: Levin LS, Kovach SJ

Availability of data and materials

Not applicable.

Financial support and sponsorship

None.

Conflicts of interest

All authors declared that there are no conflicts of interest.

Ethical approval and consent to participate

Not applicable.

Consent for publication

Not applicable.

Copyright

© The Author(s) 2022.

REFERENCES

1. Ziegler-Graham K, MacKenzie EJ, Ephraim PL, Trivison TG, Brookmeyer R. Estimating the prevalence of limb loss in the United States: 2005 to 2050. *Arch Phys Med Rehabil* 2008;89:422-9. DOI PubMed
2. Mundy LR, Klassen A, Grier AJ, et al. Identifying factors most important to lower extremity trauma patients: key concepts from the development of a patient-reported outcome instrument for lower extremity trauma, the LIMB-Q. *Plast Reconstr Surg* 2020;145:1292-301. DOI PubMed
3. MacKenzie EJ, Bosse MJ, Kellam JF, et al. Early predictors of long-term work disability after major limb trauma. *J Trauma* 2006;61:688-94. DOI PubMed
4. Xiong L, Gazyakan E, Kremer T, et al. Free flaps for reconstruction of soft tissue defects in lower extremity: a meta-analysis on microsurgical outcome and safety. *Microsurgery* 2016;36:511-24. DOI PubMed
5. Pederson WC, Grome L. Microsurgical reconstruction of the lower extremity. *Semin Plast Surg* 2019;33:54-8. DOI PubMed PMC
6. Bosse MJ, MacKenzie EJ, Kellam JF, et al. An analysis of outcomes of reconstruction or amputation after leg-threatening injuries. *N Engl J Med* 2002;347:1924-31. DOI PubMed
7. Nanchahal J. Standards for the management of open fracture of the lower limb. London: Royal Society of Medicine Press Limited; 2009.
8. Azoury SC, Stranix JT, Othman S, et al. Outcomes following soft-tissue reconstruction for traumatic lower extremity defects at an orthoplastic limb salvage center: the need for Lower Extremity Guidelines for Salvage (L.E.G.S.). *Orthoplastic Surgery* 2021;3:1-7. DOI
9. Klifto KM, Azoury SC, Othman S, Klifto CS, Levin LS, Kovach SJ. Direct admission versus transfer to a tertiary hospital for definitive management of lower extremity injuries: Systematic review and meta-analysis. *J Trauma Acute Care Surg* 2021;90:756-65. DOI PubMed
10. Piwnica-Worms W, Stranix JT, Othman S, et al. Risk factors for lower extremity amputation following attempted free flap limb salvage. *J Reconstr Microsurg* 2020;36:528-33. DOI PubMed
11. Klifto KM, Azoury SC, Othman S, Klifto CS, Levin LS, Kovach SJ. The value of an orthoplastic approach to management of lower extremity trauma: systematic review and meta-analysis. *Plast Reconstr Surg Glob Open* 2021;9:e3494. DOI PubMed PMC
12. Levin LS. The reconstructive ladder. An orthoplastic approach. *Orthop Clin North Am* 1993;24:393-409. PubMed
13. Boriani F, Ul Haq A, Baldini T, et al. Orthoplastic surgical collaboration is required to optimise the treatment of severe limb injuries: a multi-centre, prospective cohort study. *J Plast Reconstr Aesthet Surg* 2017;70:715-22. DOI PubMed
14. Lerman OZ, Kovach SJ, Levin LS. The respective roles of plastic and orthopedic surgery in limb salvage. *Plast Reconstr Surg* 2011;127 Suppl 1:215S-27S. DOI PubMed
15. Gustilo RB, Anderson JT. JSBS classics. Prevention of infection in the treatment of one thousand and twenty-five open fractures of long bones. Retrospective and prospective analyses. *J Bone Joint Surg Am* 2002;84:682. DOI PubMed
16. Patel KM, Seruya M, Franklin B, Attinger CE, Ducic I. Factors associated with failed hardware salvage in high-risk patients after microsurgical lower extremity reconstruction. *Ann Plast Surg* 2012;69:399-402. DOI PubMed

17. Godina M. Early microsurgical reconstruction of complex trauma of the extremities. *Plast Reconstr Surg* 1986;78:285-92. [DOI PubMed](#)
18. Lee ZH, Stranix JT, Rifkin WJ, et al. Timing of microsurgical reconstruction in lower extremity trauma: an update of the Godina paradigm. *Plast Reconstr Surg* 2019;144:759-67. [DOI PubMed](#)
19. Othman S, Stranix JT, Piwnica-Worms W, et al. Microvascular free tissue transfer for reconstruction of complex lower extremity trauma: Predictors of complications and flap failure. *Microsurgery* 2021. [DOI PubMed](#)
20. Karanas YL, Nigriny J, Chang J. The timing of microsurgical reconstruction in lower extremity trauma. *Microsurgery* 2008;28:632-4. [DOI PubMed](#)
21. Liu DS, Sofiadellis F, Ashton M, MacGill K, Webb A. Early soft tissue coverage and negative pressure wound therapy optimises patient outcomes in lower limb trauma. *Injury* 2012;43:772-8. [DOI PubMed](#)
22. Azoury SC, Bauder A, Souza JM, et al. Expanding the top rungs of the extremity reconstructive ladder: targeted muscle reinnervation, osseointegration, and vascularized composite allotransplantation. *Plast Aesthet Res* 2020;7:4. [DOI](#)
23. Othman S, Lukowiak T, Shakir S, et al. Bilayer wound matrix-based cutaneous scalp reconstruction: a multidisciplinary case control analysis of factors associated with reconstructive success and failure. *J Plast Reconstr Aesthet Surg* 2021;74:3008-14. [DOI PubMed](#)
24. Othman S, Shakir S, Azoury SC, et al. Utility of dermal wound matrices compared with local-tissue rearrangement and free flap reconstruction for oncologic scalp wounds: a multidisciplinary dual matched-pair analysis. *Plast Reconstr Surg* 2022;149:469-80. [DOI PubMed](#)
25. Kozak GM, Hsu JY, Broach RB, et al. Comparative effectiveness analysis of complex lower extremity reconstruction: outcomes and costs for biologically based, local tissue rearrangement, and free flap reconstruction. *Plast Reconstr Surg* 2020;145:608e-16e. [DOI PubMed PMC](#)
26. Shakir S, Messa CA 4th, Broach RB, et al. Indications and limitations of bilayer wound matrix-based lower extremity reconstruction: a multidisciplinary case-control study of 191 wounds. *Plast Reconstr Surg* 2020;145:813-22. [DOI PubMed PMC](#)
27. Bhullar DS, Karupiah SV, Aljawadi A, et al. Local flaps vs. free flaps for complex lower limb fractures: effect of flap choice on patient-reported outcomes. *J Orthop* 2020;17:91-6. [DOI PubMed PMC](#)
28. Adams C, Keating J, Court-brown C. Cigarette smoking and open tibial fractures. *Injury* 2001;32:61-5. [DOI PubMed](#)
29. Hallock GG. Local fasciocutaneous flaps for cutaneous coverage of lower extremity wounds. *J Trauma* 1989;29:1240-4. [DOI PubMed](#)
30. Pontén B. The fasciocutaneous flap: its use in soft tissue defects of the lower leg. *Br J Plast Surg* 1981;34:215-20. [DOI PubMed](#)
31. Bekara F, Herlin C, De Runz A, Boccara D, Chaput B. Free or perforator-pedicled propeller flaps in lower extremity reconstruction: defining the coverage failure. *J Reconstr Microsurg* 2017;33:e2-3. [DOI PubMed](#)
32. Islam MS, Hossain MT, Uddin MN, Chowdhury MR, Hasan MS. Wound coverage of infected open fracture of distal third of tibia by distally based medial hemi-soleus muscle flap. *Mymensingh Med J* 2018;27:798-804. [PubMed](#)
33. Song P, Pu LLQ. The soleus muscle flap: an overview of its clinical applications for lower extremity reconstruction. *Ann Plast Surg* 2018;81:S109-16. [DOI PubMed](#)
34. Al-Himdani S, Din A, Wright TC, Wheble G, Chapman TWL, Khan U. The medial sural artery perforator (MSAP) flap: a versatile flap for lower extremity reconstruction. *Injury* 2020;51:1077-85. [DOI PubMed](#)
35. Hsu CC, Loh CYY, Wei FC. The anterolateral thigh perforator flap: its expanding role in lower extremity reconstruction. *Clin Plast Surg* 2021;48:235-48. [DOI PubMed](#)
36. Park JE, Rodriguez ED, Bluebond-Langer R, et al. The anterolateral thigh flap is highly effective for reconstruction of complex lower extremity trauma. *J Trauma* 2007;62:162-5. [DOI PubMed](#)
37. Yildirim S, Avci G, Aköz T. Soft-tissue reconstruction using a free anterolateral thigh flap: experience with 28 patients. *Ann Plast Surg* 2003;51:37-44. [DOI PubMed](#)
38. Sugg KB, Schaub TA, Concannon MJ, Cederna PS, Brown DL. The reverse superficial sural artery flap revisited for complex lower extremity and foot reconstruction. *Plast Reconstr Surg Glob Open* 2015;3:e519. [DOI PubMed PMC](#)
39. Haddock NT, Weichman KE, Reformat DD, Kligman BE, Levine JP, Saadeh PB. Lower extremity arterial injury patterns and reconstructive outcomes in patients with severe lower extremity trauma: a 26-year review. *J Am Coll Surg* 2010;210:66-72. [DOI PubMed](#)
40. Stranix JT, Borab ZM, Rifkin WJ, et al. Proximal versus distal recipient vessels in lower extremity reconstruction: a retrospective series and systematic review. *J Reconstr Microsurg* 2018;34:334-40. [DOI PubMed](#)
41. Cho EH, Shammas RL, Carney MJ, et al. Muscle versus fasciocutaneous free flaps in lower extremity traumatic reconstruction: a multicenter outcomes analysis. *Plast Reconstr Surg* 2018;141:191-9. [DOI PubMed](#)
42. Lee ZH, Abdou SA, Daar DA, et al. Comparing outcomes for fasciocutaneous versus muscle flaps in foot and ankle free flap reconstruction. *J Reconstr Microsurg* 2019;35:646-51. [DOI PubMed](#)
43. Paro J, Chiou G, Sen SK. Comparing muscle and fasciocutaneous free flaps in lower extremity reconstruction--does it matter? *Ann Plast Surg* 2016;76 Suppl 3:S213-5. [DOI](#)
44. Bolletta A, Corrado R, Chen H. Advances in microsurgery for upper and lower extremity reconstruction and limb preservation. *Plast Aesthet Res* 2019;6:22. [DOI](#)
45. Kang MJ, Chung CH, Chang YJ, Kim KH. Reconstruction of the lower extremity using free flaps. *Arch Plast Surg* 2013;40:575-83. [DOI PubMed PMC](#)

46. Kim SW, Kim KN, Hong JP, Park SW, Park CR, Yoon CS. Use of the chimeric anterolateral thigh free flap in lower extremity reconstruction. *Microsurgery* 2015;35:634-9. [DOI](#) [PubMed](#)
47. Yildirim S, Gideroğlu K, Aköz T. Anterolateral thigh flap: ideal free flap choice for lower extremity soft-tissue reconstruction. *J Reconstr Microsurg* 2003;19:225-33. [DOI](#) [PubMed](#)
48. Bigdeli AK, Thomas B, Falkner F, Radu CA, Gazyakan E, Kneser U. Microsurgical reconstruction of extensive lower extremity defects with the conjoined parascapular and latissimus dorsi free flap. *Microsurgery* 2020;40:639-48. [DOI](#) [PubMed](#)
49. Hong JP. The superficial circumflex iliac artery perforator flap in lower extremity reconstruction. *Clin Plast Surg* 2021;48:225-33. [DOI](#) [PubMed](#)
50. Messa CA 4th, Carney MJ 3rd, Tantillo K, et al. Characteristics of the superficial circumflex iliac artery perforator flap in a western population and a practice approach for free flap reconstruction. *J Reconstr Microsurg* 2021;37:486-91. [DOI](#) [PubMed](#)
51. Pu LL. A comprehensive approach to lower extremity free-tissue transfer. *Plast Reconstr Surg Glob Open* 2017;5:e1228. [DOI](#) [PubMed](#) [PMC](#)
52. Zeiderman MR, Pu LLQ. Contemporary approach to soft-tissue reconstruction of the lower extremity after trauma. *Burns Trauma* 2021;9:tkab024. [DOI](#) [PubMed](#) [PMC](#)
53. Akita S, Akino K, Tanaka K, Anraku K, Hirano A. A basic fibroblast growth factor improves lower extremity wound healing with a porcine-derived skin substitute. *J Trauma* 2008;64:809-15. [DOI](#) [PubMed](#)
54. Wetzell B, McLean JB, Dorsch K, Moore MA. A 24-month retrospective update: follow-up hospitalization charges and readmissions in US lumbar fusion surgeries using a cellular bone allograft (CBA) versus recombinant human bone morphogenetic protein-2 (rhBMP-2). *J Orthop Surg Res* 2021;16:680. [DOI](#) [PubMed](#) [PMC](#)
55. Yamakawa S, Hayashida K. Advances in surgical applications of growth factors for wound healing. *Burns Trauma* 2019;7:10. [DOI](#) [PubMed](#) [PMC](#)