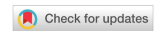

Technical Note

Open Access



# Standardization and short-term outcomes of robot-assisted minimally invasive esophagectomy in the semi-prone position

Hirotochi Kikuchi<sup>1</sup> , Eisuke Booka<sup>1</sup>, Ryoma Haneda<sup>1</sup> , Tomohiro Murakami<sup>1</sup>, Tomohiro Matsumoto<sup>1</sup>, Yoshihiro Hiramatsu<sup>2</sup> , Hiroya Takeuchi<sup>1</sup>

<sup>1</sup>Department of Surgery, Hamamatsu University School of Medicine, Hamamatsu 431-3192, Japan.

<sup>2</sup>Department of Perioperative Functioning Care and Support, Hamamatsu University School of Medicine, Hamamatsu 431-3192, Japan.

**Correspondence to:** Dr. Hiroya Takeuchi, Department of Surgery, Hamamatsu University School of Medicine, 1-20-1 Handayama, Chuo-ku, Hamamatsu 431-3192, Japan. E-mail: takeuchih@hama-med.ac.jp

**How to cite this article:** Kikuchi H, Booka E, Haneda R, Murakami T, Matsumoto T, Hiramatsu Y, Takeuchi H. Standardization and short-term outcomes of robot-assisted minimally invasive esophagectomy in the semi-prone position. *Mini-invasive Surg* 2024;8:8. <https://dx.doi.org/10.20517/2574-1225.2023.88>

**Received:** 23 Jul 2023 **First Decision:** 26 Apr 2024 **Revised:** 23 May 2024 **Accepted:** 5 Jun 2024 **Published:** 11 Jun 2024

**Academic Editors:** Farid Gharagozloo, Giulio Belli **Copy Editor:** Pei-Yun Wang **Production Editor:** Pei-Yun Wang

## Abstract

Robot-assisted minimally invasive esophagectomy (RAMIE) has recently been developed and is increasingly performed for thoracic esophageal and esophagogastric junction (EGJ) cancers. At our institute, we performed RAMIE in the semi-prone position using the da Vinci Xi system with two- or three-field lymphadenectomy in 91 patients with resectable thoracic esophageal or EGJ cancers between October 2018 and March 2023. During this period, we improved and standardized the surgical procedures to perform precise and safe mediastinal lymphadenectomies and minimize postoperative complications. The rates of major operative morbidities (C-D grade,  $\geq$  I) were acceptable (recurrent laryngeal nerve paralysis, 6.6%; pneumonia, 9.9%; atelectasis, 6.7%; anastomotic leak, 14.3%). Both operative and 30-day mortality rates were 0%. In this technical note, we present our standardized surgical techniques for RAMIE in the semi-prone position for esophageal and EGJ cancers.

**Keywords:** Robot, da Vinci, esophagectomy, lymphadenectomy, esophageal cancer



© The Author(s) 2024. **Open Access** This article is licensed under a Creative Commons Attribution 4.0 International License (<https://creativecommons.org/licenses/by/4.0/>), which permits unrestricted use, sharing, adaptation, distribution and reproduction in any medium or format, for any purpose, even commercially, as long as you give appropriate credit to the original author(s) and the source, provide a link to the Creative Commons license, and indicate if changes were made.



## INTRODUCTION

Esophageal cancer is one of the leading causes of cancer-related deaths worldwide<sup>[1]</sup>. In the Asia-Pacific region, including Japan, the vast majority of esophageal cancers are squamous cell carcinomas (SCC) located in the thoracic esophagus. The incidence of esophagogastric junction (EGJ) cancer has increased in recent years, with most of them being adenocarcinomas (ADCs)<sup>[2]</sup>. Esophagectomy with two- or three-field lymphadenectomy plays a major role in treating resectable thoracic esophageal and EGJ cancers<sup>[3]</sup>. However, esophagectomy is a highly invasive procedure that can lead to severe postoperative morbidities including pulmonary complications. Therefore, minimally-invasive esophagectomy (MIE) with a thoracoscopic and/or laparoscopic approach has been developed and widely performed worldwide and reportedly contributed to decreasing pulmonary complications<sup>[3-5]</sup>. Recently, robot-assisted MIE (RAMIE) has made rapid progress and has become widespread in its use in Japan since its insurance approval in 2018<sup>[3,6]</sup>. At our institute, we implemented RAMIE in the semi-prone position using the da Vinci Xi system (Intuitive Surgical Inc., Sunnyvale, CA, USA) in October 2018 and improved and standardized surgical procedures to perform curative, precise, and safe mediastinal lymphadenectomy and minimize postoperative complications.

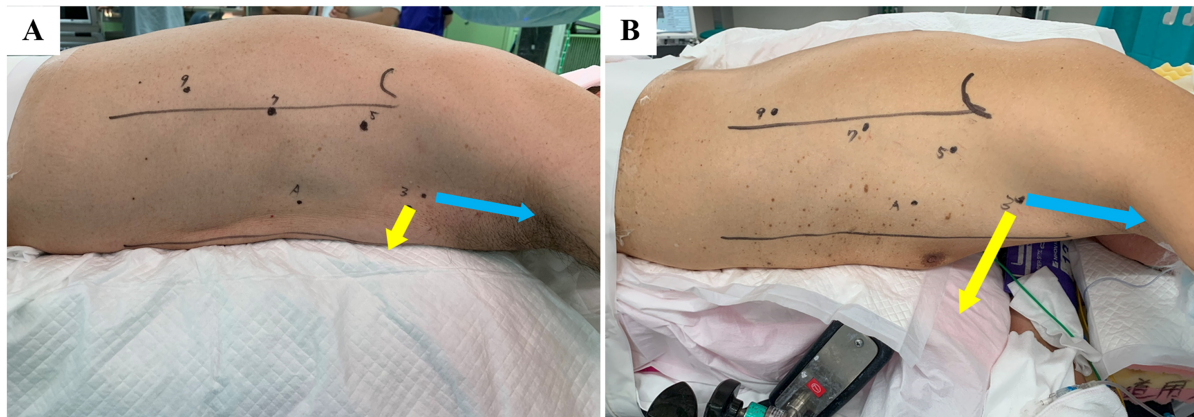
In this technical note, we present standardized surgical techniques and short-term outcomes of RAMIE in the semi-prone position for esophageal and EGJ cancers.

## SURGICAL PROCEDURES

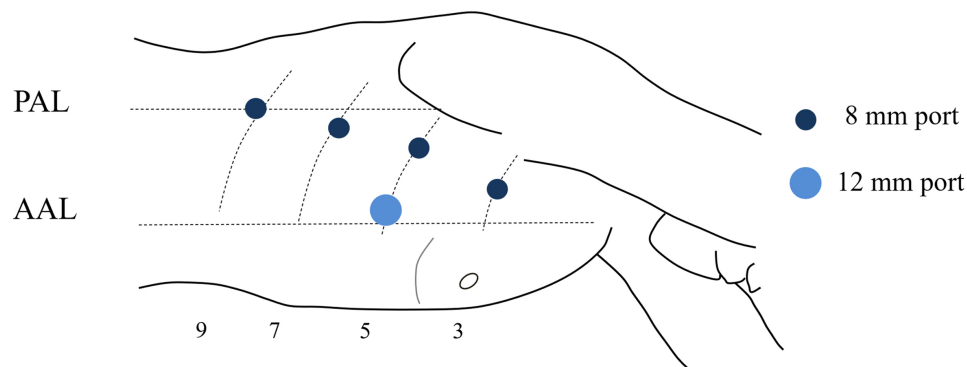
We performed RAMIE with two- or three-field lymphadenectomy in 91 patients with resectable thoracic esophageal or EGJ cancers between October 2018 and March 2023. All RAMIEs were performed under general anesthesia using a single-lumen endotracheal tube, and selective intubation was performed to block the right lung. Following thoracic RAMIE, laparoscopic or open abdominal and cervical procedures were performed. Bilateral cervical lymphadenectomy was performed for advanced and superficial SCC located in the middle or upper thoracic esophagus, except for patients with high surgical risk and those registered in a clinical trial [the Japan Clinical Oncology Group (JCOG) 2013] and assigned for esophagectomy without prophylactic supraclavicular node dissection. The gastric conduit was mainly used for reconstruction in the one-stage surgery, and the right colon was used in the second-stage surgery for patients with concomitant gastric cancer or a history of gastrectomy. The posterior mediastinal route was mainly used for reconstruction with the gastric conduit. The retrosternal or subcutaneous route was selected in some cases because of their advanced tumor stage or poor general condition. The subcutaneous route was used for reconstruction with the right colon. The cervical esophagus and gastric conduit or terminal ileum were anastomosed using hand-suturing techniques. A feeding jejunostomy or gastrostomy was routinely performed following reconstruction.

### Patient position

Patients were originally placed on the operating table in a semi-prone position, with the right side of the upper body slightly elevated on a bolster [Figure 1A]. Since June 2021, we have changed the patient placement to a hybrid position by combining the left lateral decubitus and prone positions, which have been used for conventional MIE at our institute<sup>[7]</sup>. The patients were placed in the left semi-prone position, and the operating table was rotated to simulate the left lateral decubitus position for open thoracotomy in an emergency. They were moved to the semi-prone position by rotating the operating table, and then a slight head-up position was made for RAMIE [Figure 1B]. Compared with the original semi-prone position, the modified semi-prone position created a larger space between the anterior chest and the operating table (yellow arrows, Figure 1A and B) and a slightly longer distance between the right arm and the fourth port (blue arrows, Figure 1A and B), which increased the working space of the assistant surgeon outside the patient and reduced the collision of the robotic fourth arm with the patient's right arm.



**Figure 1.** Patient position. (A) The original semi-prone position was created by placing the patient on the operating table in a prone position with the right side of the upper body slightly elevated on a bolster; (B) The modified semi-prone position was created by rotating the operating table in the hybrid position combining the left lateral decubitus and prone positions. Compared to the original semi-prone position (A), the modified semi-prone position (B) created a larger space between the anterior chest and the operating table (yellow arrows) and a slightly longer distance between the right arm and the fourth port (blue arrows).

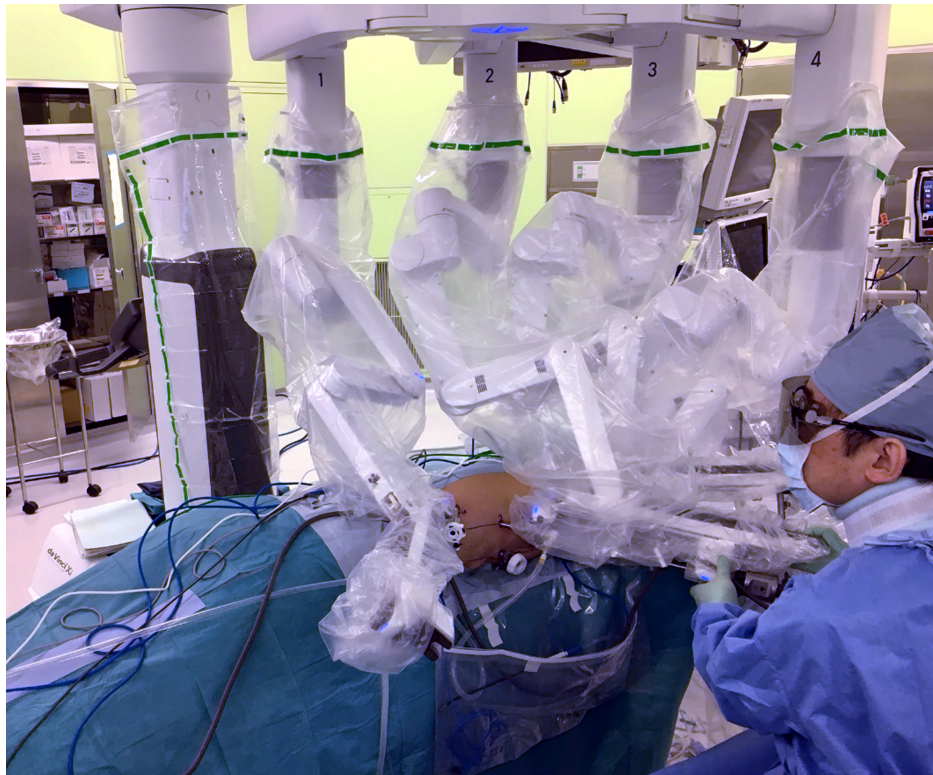


**Figure 2.** Thoracoscopic port placement for robot-assisted minimally invasive esophagectomy in the semi-prone position. The numbers indicate the intercostal spaces. PAL: Posterior axillary line; AAL: anterior axillary line.

### Port set-up and docking

Four 8-mm robotic ports and one 12-mm conventional port were designed to be placed at a distance of  $> 7$  cm [Figure 2]. A camera port (second arm) was placed on the ventral side of the posterior axillary line (PAL) of the 7th intercostal space (ICS). The other ports for the first, third, and fourth arms were designed around the PAL of the 9th or 10th ICS, on the ventral side of the PAL of the 5th ICS, and on the dorsal side of the anterior axillary line (AAL) of the 3rd ICS, respectively. In cases of prominent vertebral spurs, the first and third ports were placed on the ventral side to prevent collisions with the vertebrae. An assistant port was placed on the dorsal side of the AAL at the 5th ICS. Two assistant surgeons were positioned on the right side of the patient. The first port was inserted at the 7th ICS via a direct small thoracotomy, and the other ports were placed under direct thoracoscopic vision after lung deflation by an artificial pneumothorax using carbon dioxide at a pressure of 8 mmHg.

The patient cart of the da Vinci Xi system was placed on the upper left side of the patient [Figure 3]. The second robotic arm was connected to the 8-mm port at the 7th ICS, and a 30° camera was inserted in the down-facing orientation. Targeting was performed at the dorsal end of the azygos vein arch as a basic target anatomy. The first, third, and fourth arms were connected to the 8-mm port at the 9th, 5th, and 3rd ICSs,



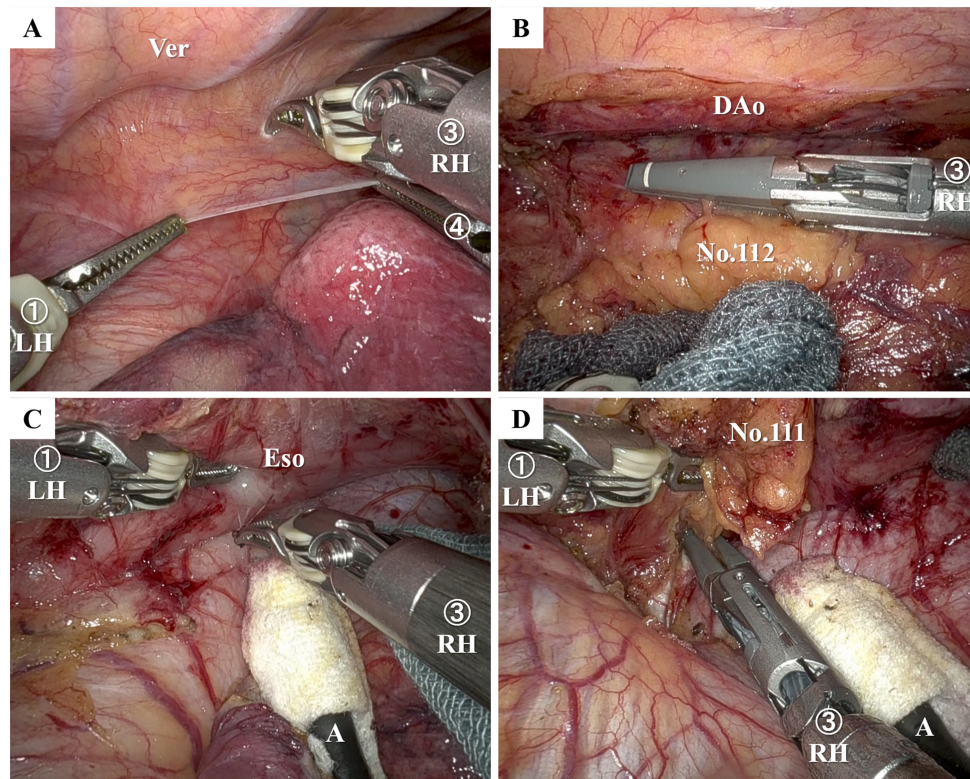
**Figure 3.** Intraoperative images of robot-assisted minimally invasive esophagectomy in the semi-prone position. The patient cart of the da Vinci Xi system was placed on the upper left side of the patient.

respectively. The console surgeon mainly used a bipolar fenestrated grasper in the left hand and Maryland bipolar forceps or an extended vessel sealer (Intuitive Surgical Inc.) in the right hand. Organ retraction was performed using Cadere Forceps at the fourth arm. The first assistant surgeon used a flexible suction retractor to create the operation fields in the middle and lower thoracic regions and employed a thoracocotton (Kenmedico Co. Ltd., Saitama, Japan) with a stainless-steel shaft to press or rotate the trachea and the right bronchus.

### Dissection of the lower mediastinum

The parietal pleura on the dorsal side of the esophagus in the lower mediastinum was first incised using Maryland bipolar forceps [Figure 4A], and small vessels connecting the descending aorta and esophagus were cut and sealed using a vessel sealer. Lymph node no. 112 was dissected from the descending aorta and left pleura or combined with the left pleura [Figure 4B]. On the ventral side of the esophagus, the right and left crus of the diaphragm were exposed, the right lower pulmonary ligament was excised, and a dissectible layer comprising coarse connective tissues between the esophagus and pericardium or the right pulmonary vein was traced caudally to lymph node no. 111. The esophagus was retracted to the dorsal side using Cadere forceps on the fourth robotic arm, and the pericardium was gently pressed and ventrally retracted by the first assistant surgeon using a flexible suction retractor covered with a Lapaclear D cover (Hakujiji Co., Ltd., Tokyo, Japan) [Figure 4C]. The ventral bottom of lymph node no. 111 was dissected using a vessel sealer to reduce postoperative effusion [Figure 4D]. The thoracic duct was generally preserved, except in cases with locally advanced tumors invading the thoracic duct.





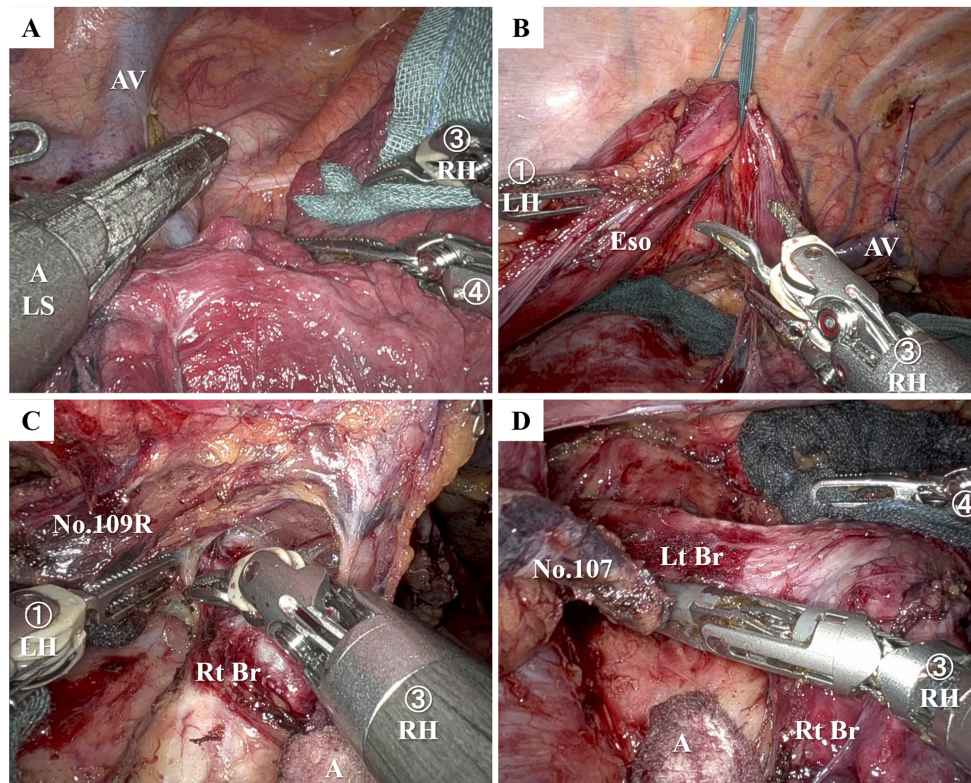
**Figure 4.** Intraoperative views of lower mediastinal lymphadenectomy in robot-assisted minimally invasive esophagectomy in the semi-prone position. (A) Parietal pleura on the dorsal side of the esophagus was incised using Maryland bipolar forceps; (B) Lymph node no. 112 was dissected from the descending aorta and the left pleura using a vessel sealer; (C) Coarse connective tissues between the lower esophagus and the pericardium were dissected using Maryland bipolar forceps. The pericardium was gently pressed and ventrally retracted by an assistant surgeon using a flexible suction retractor with a Lapaclear D cover (Hakujiji Co., Ltd); (D) Lymph node no. 111 was dissected using a vessel sealer. A: Assistant; DAo: descending aorta; Eso: esophagus; LH: left hand; RH: right hand; Ver: vertebra.

### Dissection of the middle mediastinum

The mediastinal pleura was dissected cranially to the upper mediastinum, and the azygos vein arch was excised using a linear stapler with a closed staple height of 1.0 mm inserted from the assistant port [Figure 5A]. The dorsal end of the azygos vein arch was ligated using an Endoloop PDS II (ETHICON, Cincinnati, OH, USA) and retracted dorsally to the nearby ICS. At our institute, the right bronchial artery was generally excised to prevent blind injury with the pulled-up gastric conduit within the posterior mediastinal reconstruction route following esophagectomy. The esophagus was retracted using a Teflon tape below the tracheal bifurcation [Figure 5B]. The right vagus nerve was dissected below the right bronchus, and lymph node no. 109R was dissected using Maryland bipolar forceps or a vessel sealer [Figure 5C]. After dissecting the upper mediastinum and cutting the upper thoracic esophagus, lymph node nos. 107 and 109L were dissected using Maryland bipolar forceps or a vessel sealer [Figure 5D].

### Dissection of the upper mediastinum

The parietal pleura on the ventral side of the upper thoracic esophagus was incised along the right vagus nerve using Maryland bipolar forceps, and the right vagus nerve was taped and gently retracted with vessel loops. Fatty tissues containing lymph node no. 106recR were dissected from the right side of the tracheal cartilage and the right subclavian artery using Maryland bipolar forceps. Subsequently, no. 106recR lymphadenectomy was performed using Maryland bipolar forceps or Potts scissors on the right hand [Figure 6A]. Fatty tissues containing lymph node no. 106recL were dissected from the left side of the



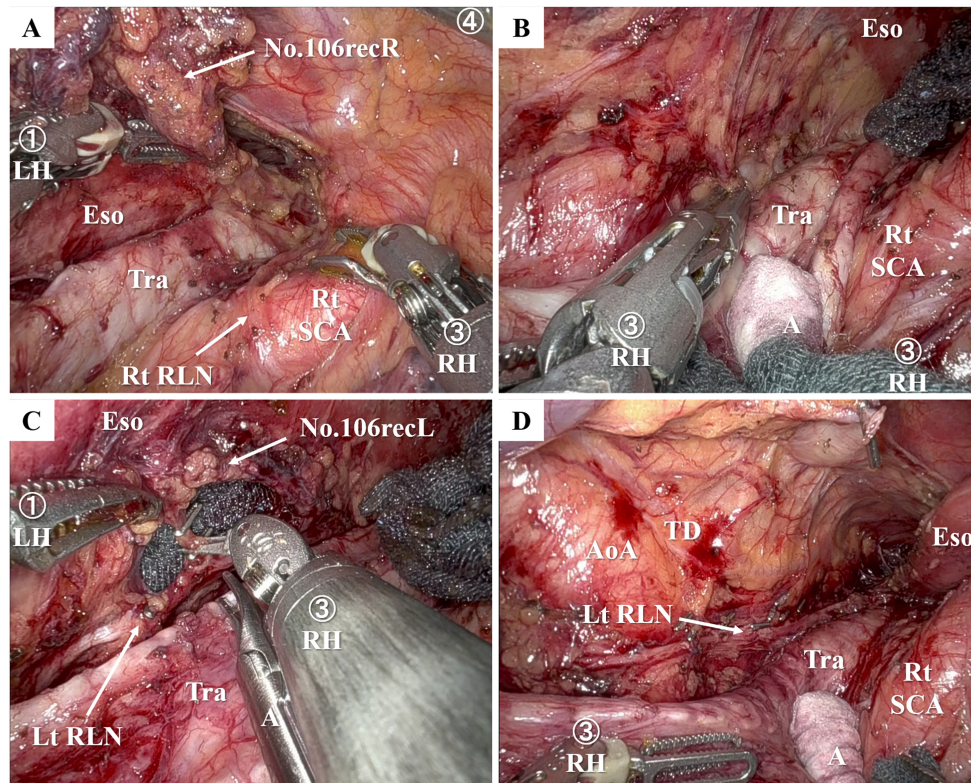
**Figure 5.** Intraoperative views of middle mediastinal lymphadenectomy in robot-assisted minimally invasive esophagectomy in the semi-prone position. (A) The azygos vein arch was excised using a linear stapler; (B) The middle thoracic esophagus was retracted using a Teflon tape below the tracheal bifurcation; (C) Lymph node no. 109R was dissected using Maryland bipolar forceps or a vessel sealer; (D) Lymph node nos. 107 and 109L were dissected using Maryland bipolar forceps or a vessel sealer. A: Assistant; AV: azygos vein; Eso: esophagus; LH: left hand; LS: linear stapler; Lt Br: left bronchus; RH: right hand; Rt Br: right bronchus.

tracheal cartilage using Maryland bipolar forceps or a vessel sealer. Small vessels connecting the tracheal edge and dissected tissues were carefully isolated from the membrane between the trachea and esophagus and sealed with bipolar devices [Figure 6B]. Following dissection of lymph node no. 106recL tissues from the trachea, the left recurrent laryngeal nerve (RLN) was isolated from the dissected tissue. The dissecting tissue was generally flipped dorsally to the esophagus using long bipolar forceps on the left hand and Maryland bipolar forceps on the right. Small vessels around the left RLN were clipped by the first assistant and cut using Potts scissors with the right hand [Figure 6C]. To prevent intraoperative injury of the RLN and postoperative RLN paralysis, no. 106recL lymphadenectomy was performed by keeping the left RLN at its original position as much as possible, cutting the esophageal branch of the RLN as early as possible, and prohibiting or minimizing the use of energy devices around the RLN as necessary. After dissecting lymph node no. 106recL from the middle and upper portions of the left RLN, the upper thoracic esophagus was cut using a linear stapler, and 106recL lymphadenectomy around the aortic arch with or without no. 106tbL lymphadenectomy was performed [Figure 6D].

## POSTOPERATIVE MANAGEMENT

The patients usually remain intubated and managed under sedation in the intensive care unit (ICU) on the day of the surgery. Extubation is performed on postoperative day (POD) 1, and the patients are transferred to a general ward on POD 2 if their conditions are stable. Enteral nutrition is initiated from the day of surgery with the continuous administration of a component nutrient. Oral intake usually starts after



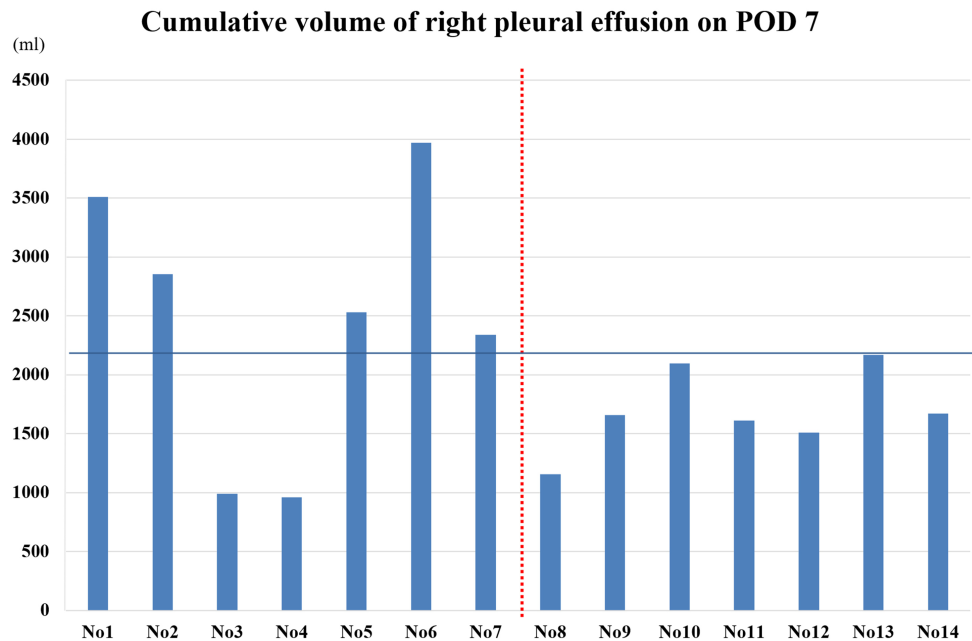


**Figure 6.** Intraoperative views of upper mediastinal lymphadenectomy along the bilateral recurrent laryngeal nerves. (A) Operative field after lymphadenectomy around the right recurrent laryngeal nerve; (B) Dissection of fat tissues containing lymph nodes no. 106recL from the left side of the trachea using Maryland bipolar forceps or a vessel sealer; (C) Clipping and cutting of small vessels around the left recurrent laryngeal nerve using Potts scissors; (D) Operation field after lymphadenectomy around the left recurrent laryngeal nerve. A: Assistant; AoA: aortic arch; Eso: esophagus; LH: left hand; LS: linear stapler; Lt RLN: left recurrent laryngeal nerve; RH: right hand; Rt RLN: right recurrent laryngeal nerve; Rt SCA: right subclavian artery; TD: thoracic duct; Tra: trachea.

evaluating for anastomotic leakage using computed tomography (CT) scan and gastrointestinal contrast imaging and for swallowing function through a swallowing videofluorography on POD 7.

## SHORT-TERM OUTCOMES

We performed RAMIE followed by reconstruction with a gastric conduit ( $n = 84$ ) or second-stage reconstruction with a right colon conduit ( $n = 7$ ) in 91 patients with resectable thoracic esophageal or EGJ cancer between October 2018 and March 2023. Their median age was 68 [interquartile range (IQR) 60-72]. The histological types were SCC (59.2%) and ADC (38.0%). The main tumor locations were in the upper, middle, and lower esophagus in 14.1%, 23.9%, and 26.8%, respectively, and in the EGJ zone in 35.2% of the patients. The clinical tumor depths were T1, T2, T3, and T4 in 31.0%, 7.0%, 50.7%, and 11.3% of patients, respectively. No patients received chemoradiation or radiotherapy before surgery. Two- and three-field lymphadenectomies were performed in 64.8% and 35.2% of them, respectively. The median total operative time was 540 min (range, 508-587 min). No patients underwent conversion to open thoracotomy. Earlier, in the introduction phase of RAMIE, we experienced a high volume of postoperative effusion and the cumulative volume of drainage fluid from the right chest tube, compared with that of conventional MIE (case nos. 1-7, [Figure 7](#)). In some cases, pharmacological treatments were needed to reduce the pleural effusion while no major fatal effects were observed due to the increased pleural effusion. Therefore, we standardized the use of a vessel sealer rather than Maryland bipolar forceps around the thoracic duct, which



**Figure 7.** Cumulative volume of right pleural effusion on POD 7. Earlier, in the introduction phase of robot-assisted minimally invasive esophagectomy, postoperative pleural effusion increased compared to that in conventional minimally-invasive esophagectomy (case nos. 1-7). Active use of a vessel sealer instead of Maryland bipolar forceps around the thoracic duct significantly reduced postoperative effusion (case nos. 8-14). POD: Postoperative day.

significantly reduced postoperative effusion (case nos. 8-14, [Figure 7](#)).

Postoperative RLN paralysis was assessed by Clavien-Dindo (CD) grade, in which grade  $\geq$  I was observed in 6 (6.6%), pneumonia CD grade  $\geq$  I in 9 (9.9%), atelectasis CD grade  $\geq$  I in 6 (6.7%), and anastomotic leak grade CD grade  $\geq$  I in 13 (14.3%) cases. Both operative mortality and 30-day mortality rates were 0%.

## DISCUSSION

In the present study, we demonstrated our standardized surgical procedures and the short-term outcomes of RAMIE for esophageal and EGJ cancers.

To implement RAMIE, we established a dedicated RAMIE team composed of a console surgeon (H.T), assistant surgeons (H.K, R.H, T.M, and Y.H), surgical nurses, medical engineers, and anesthesiologists. In preparation for the first case, our RAMIE team visited another leading hospital with extensive experience in RAMIE, conducted simulations of the patient placement and roll-in of the patient cart, and verified troubleshooting for an emergency in the operating room at our hospital.

Throughout our experience with RAMIE, we modified the RAMIE procedures, including the active use of a vessel sealer instead of Maryland bipolar forceps around the thoracic duct to reduce postoperative effusion, a change in the patient placement to the hybrid position that provided increased space for assistant surgeons outside of the patient, and improved retraction of the esophagus using Teflon tape below the tracheal bifurcation. The assistant surgeons made further modifications to their assisting procedures. We initially used Kodama Disuction (Sumitomo Bakelite, Tokyo, Japan), a relatively short suction device with a spherical silicon head, to compress organs around the esophagus, but later transitioned to a longer and



articular suction device with a metallic head. Although its longer shaft enabled active traction of the distant organ from the assistant port, the metallic suction head decreased friction and caused difficulty retracting the organs. Therefore, we eventually settled on using a long and articulating suction device covered with Lapaclear D, a cotton pouch shaped like a slipper, which maximized counter traction even in fields distant from the assistant port. In upper mediastinal lymphadenectomy, the console surgeon initially used a small clip applier (Intuitive Surgical, Inc.) on the third arm. After handling several cases, we changed the application method of small clips to target small vessels around the RLNs using a Challenger (B Braun, Tokyo, Japan), which was used by the first assistant to reduce the application time for small clips. Notably, a tremor-less application of clips is necessary to avoid RLN injury; however, assistant surgeons with good experience in using a Challenger device in conventional MIE can safely place small clips around the RLN in RAMIE. These assistant techniques are unique and first described in the literature.

The concepts of upper mediastinal lymphadenectomy in RAMIE are consistent with those of conventional MIE in the following manner: fine dissection in the proper layer while preserving the lymphatic chain, preservation of the RLNs in the original position, early sectioning of the esophageal branch of the RLNs, and proper use of surgical devices with a gentle approach to the RLNs for curative lymphadenectomy and prevention of RLN paralysis. Compared with the conventional MIE, RAMIE has advantages regarding the stability of surgical devices, cameras, and improved retraction of the esophagus or surrounding organs. These merits of robotic systems may significantly help surgeons perform safe and precise lymphadenectomy in RAMIE and potentially reduce postoperative complications, such as RLN paralysis<sup>[8-11]</sup>. In a randomized control trial (RCT) conducted at a single center in the Netherlands, RAMIE resulted in a lower percentage of overall surgery-related and cardiopulmonary complications than open esophagectomy<sup>[10]</sup>. In a multicenter RCT conducted in China, significantly shorter operation time was taken in RAMIE than MIE, and RAMIE can achieve better lymph node dissection in patients who received neoadjuvant therapy<sup>[11]</sup>. To fully validate the benefits of RAMIE *vs.* MIE, further investigations are ongoing, including a multicenter, open-label RCT in Taiwan and mainland China [Robotic-assisted Esophagectomy *vs.* Video-Assisted Thoracoscopic Esophagectomy (REVATE)], in which the primary outcome measure is the rate of unsuccessful lymph node dissection along the left RLN<sup>[12]</sup>.

In locally advanced esophageal cancer, the circumferential resection margin (CRM) is an important prognostic factor after esophagectomy. Robotic systems can create and maintain proper traction between the esophagus and surrounding organs<sup>[13-15]</sup>. Additionally, clear, bright, and magnified images in the surgeon's console aid in recognizing the resectable layers around advanced tumors<sup>[8,16]</sup>. RAMIE could be advantageous in recognizing the proper layer for resection of locally advanced cancers and achieving curative CRM.

Future research and comparative studies are warranted to address several clinical questions regarding the safety and superiority of RAMIE in terms of short-term and long-term oncological outcomes, as RAMIE has the potential to become a safe and less invasive surgical procedure for esophagectomy with mediastinal lymphadenectomy.

## CONCLUSION

RAMIE enables precise dissection techniques and holds the potential to improve short-term outcomes of esophagectomy for thoracic esophageal and EGJ cancers.

## DECLARATIONS

### Authors' contributions

Performed RAMIEs as a console surgeon: Takeuchi H

Performed RAMIEs as assistant surgeons and collected clinicopathological data: Kikuchi H, Booka E, Haneda R, Murakami T, Matsumoto T, Hiramatsu Y

Wrote the manuscript: Kikuchi H

### Availability of data and materials

Not applicable.

### Financial support and sponsorship

None.

### Conflicts of interest

All authors declared that there are no conflicts of interest.

### Ethical approval and consent to participate

This study was approved by the ethics committee of Hamamatsu University School of Medicine (IRB Nos. 17-149 and 17-165). The board waived the requirement for written patient consent for the use of clinicopathological data, and all the patients provided written informed consent or agreed to participate via an opt-out approach. This study conformed to the guidelines set forth in the Helsinki Declaration of 1975 and its later versions.

### Consent for publication

Not applicable.

### Copyright

© The Author(s) 2024

## REFERENCES

1. Sung H, Ferlay J, Siegel RL, et al. Global cancer statistics 2020: GLOBOCAN estimates of incidence and mortality worldwide for 36 cancers in 185 countries. *CA Cancer J Clin* 2021;71:209-49. DOI PubMed
2. Manabe N, Matsueda K, Haruma K. Epidemiological review of gastroesophageal junction adenocarcinoma in Asian countries. *Digestion* 2022;103:29-36. DOI PubMed
3. Ozawa S, Uchi Y, Ando T, Hayashi K, Aoki T. Essential updates 2020/2021: recent topics in surgery and perioperative therapy for esophageal cancer. *Ann Gastroenterol Surg* 2023;7:346-57. DOI PubMed PMC
4. Booka E, Takeuchi H, Kikuchi H, et al. Recent advances in thoracoscopic esophagectomy for esophageal cancer. *Asian J Endosc Surg* 2019;12:19-29. DOI PubMed
5. Takeuchi H, Miyata H, Ozawa S, et al. Comparison of short-term outcomes between open and minimally invasive esophagectomy for esophageal cancer using a nationwide database in Japan. *Ann Surg Oncol* 2017;24:1821-7. DOI PubMed
6. Booka E, Kikuchi H, Haneda R, et al. Short-term outcomes of robot-assisted minimally invasive esophagectomy compared with thoracoscopic or transthoracic esophagectomy. *Anticancer Res* 2021;41:4455-62. DOI PubMed
7. Kikuchi H, Hiramatsu Y, Matsumoto T, et al. The hybrid position is superior to the prone position for thoracoscopic esophagectomy with upper mediastinal lymphadenectomy. *Ann Laparosc Endosc Surg* 2020;5:13. DOI
8. Hosoda K, Niihara M, Harada H, Yamashita K, Hiki N. Robot-assisted minimally invasive esophagectomy for esophageal cancer: meticulous surgery minimizing postoperative complications. *Ann Gastroenterol Surg* 2020;4:608-17. DOI PubMed PMC
9. van der Horst S, Weijs TJ, Braunius WW, et al. Safety and feasibility of robot-assisted minimally invasive esophagectomy (RAMIE) with three-field lymphadenectomy and neoadjuvant chemoradiotherapy in patients with resectable esophageal cancer and cervical lymph node metastasis. *Ann Surg Oncol* 2023;30:2743-52. DOI PubMed
10. van der Sluis PC, van der Horst S, May AM, et al. Robot-assisted minimally invasive thoracoscopic esophagectomy versus open transthoracic esophagectomy for resectable esophageal cancer: a randomized controlled trial. *Ann Surg* 2019;269:621-30. DOI PubMed

11. Yang Y, Li B, Yi J, et al. Robot-assisted versus conventional minimally invasive esophagectomy for resectable esophageal squamous cell carcinoma: early results of a multicenter randomized controlled trial: the RAMIE trial. *Ann Surg* 2022;275:646-53. DOI PubMed
12. Chao YK, Li ZG, Wen YW, et al. Robotic-assisted esophagectomy vs video-assisted thoracoscopic esophagectomy (REVATE): study protocol for a randomized controlled trial. *Trials* 2019;20:346. DOI PubMed PMC
13. Haneda R, Kikuchi H, Nagakura Y, et al. Development and validation of the optimal circumferential resection margin in pathological T3 esophageal cancer: a multicenter, retrospective study. *Ann Surg Oncol* 2022;29:4452-61. DOI PubMed
14. Okada N, Fujii S, Fujita T, et al. The prognostic significance of the positive circumferential resection margin in pathologic T3 squamous cell carcinoma of the esophagus with or without neoadjuvant chemotherapy. *Surgery* 2016;159:441-50. DOI PubMed
15. Evans R, Bundred JR, Kaur P, Hodson J, Griffiths EA. Meta-analysis of the influence of a positive circumferential resection margin in oesophageal cancer. *BJS Open* 2019;3:595-605. DOI PubMed PMC
16. Kikuchi H, Takeuchi H. Future perspectives of surgery for esophageal cancer. *Ann Thorac Cardiovasc Surg* 2018;24:219-22. DOI PubMed PMC