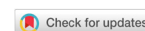

Original Article

Open Access



The “central six” of ptosis repair: eliminating contour as a variable in external levator surgery

Benjamin C. Campbell^{1,2,3}, Susuana T. Adjei^{1,3}, William R. Nunery^{1,2,3}, H. B. Harold Lee^{1,2,3}

¹Oculofacial Plastic and Orbital Surgery, Indianapolis, IN 46280, USA.

²Ascension St. Vincent Hospital, Indianapolis, IN 46260, USA.

³Department of Ophthalmology, Indiana University School of Medicine, Indianapolis, IN 46290, USA.

Correspondence to: Dr. H. B. Harold Lee, Department of Ophthalmology, Indiana University School of Medicine, Indianapolis, IN 46290, USA. E-mail: huiabae@gmail.com

How to cite this article: Campbell BC, Adjei ST, Nunery WR, Lee HBH. The “central six” of ptosis repair: eliminating contour as a variable in external levator surgery. *Plast Aesthet Res* 2020;7:12. <http://dx.doi.org/10.20517/2347-9264.2019.59>

Received: 26 Nov 2019 **First Decision:** 4 Feb 2020 **Revised:** 8 Feb 2020 **Accepted:** 26 Feb 2020 **Published:** 13 Mar 2020

Science Editor: Chau Pham **Copy Editor:** Jing-Wen Zhang **Production Editor:** Jing Yu

Abstract

Aim: Eyelid contour is a key component to satisfactory lid position and appearance following ptosis repair, the components of which have been highly debated and remain difficult to objectively measure. We sought to minimize the number of intraoperative adjustments required and reduce reoperation rates by addressing only the central 6 mm of tarsus when reapproximating levator to the anterior surface of tarsus, thereby eliminating contour as an adjustable variable.

Methods: All patients who underwent external levator resection with blepharoplasty for correction of involutional ptosis between 2012 and 2019 by a single surgeon at one center were retrospectively reviewed. Patients who underwent concomitant brow lifting surgery were excluded. The same technique was used for each eyelid with uniform suture placement. One 6-0 silk horizontal mattress suture was placed partial thickness through the superior third of tarsus 3 mm lateral to the center of tarsus; another was passed 3 mm medial to the center of tarsus. No sutures were placed outside of this central 6-mm zone. Patient fixation was used to determine lid height and symmetry. Once satisfactory, the sutures were tied down in a permanent fashion and the eyelid position again verified. In total, 153 eyelids in 85 patients were evaluated. Data obtained included preoperative and postoperative margin-to-reflex distance (MRD₁), intraoperative and postoperative complications, reoperation rates, and patient satisfaction with appearance of lid contour and symmetry.

Results: The mean follow up time was 3.41 months. The mean preoperative MRD₁ was 1.05 mm. The mean postoperative was 3.18 mm. All patients had recovery of an anatomically normal temporal peak height. Two of 153



© The Author(s) 2020. **Open Access** This article is licensed under a Creative Commons Attribution 4.0 International License (<https://creativecommons.org/licenses/by/4.0/>), which permits unrestricted use, sharing, adaptation, distribution and reproduction in any medium or format, for any purpose, even commercially, as long as you give appropriate credit to the original author(s) and the source, provide a link to the Creative Commons license, and indicate if changes were made.



eyelids (1.31%) required reoperation due to residual ptosis or overcorrection. No patients had postoperative lagophthalmos. Ninety-one percent of patients who underwent bilateral surgery had satisfactory symmetry defined as less than or equal to 1-mm difference between right and left MRD₁. Eighty-two of the 85 patients were satisfied with their postoperative appearance.

Conclusion: This simple and standardized technique for suture placement gives reliable and effective results for external levator advancement for ptosis repair by eliminating contour as an adjustable variable. Addressing the central 6 mm of tarsus is not only paramount but also in and of itself satisfactory in achieving optimal contour during external levator resection, without regard to more medial or lateral lid anatomy.

Keywords: Ptosis, levator advancement, central 6

INTRODUCTION

Acquired eyelid ptosis is most commonly due to involutional changes of the levator aponeurosis^[1,2]. There are various surgical techniques to correct ptosis, and the majority of them focus on tightening or advancing the levator aponeurosis onto tarsus^[3,4]. External levator advancement was first described in the 1880s^[5], and since then it has been repeatedly modified and improved. The traditional surgical technique is to place one or more sutures to reattach the levator aponeurosis to the anterior surface of tarsus once it has been carefully dissected and partially resected. The first suture is placed centrally to achieve appropriate eyelid height, and more sutures are then placed medially and laterally to achieve proper contour. This approach can be cumbersome and require multiple adjustments intraoperatively to achieve proper contour. There have been several studies suggesting modifications of the procedure in order to standardize and simplify the process^[6-9]. It remains a challenging surgery in order to achieve adequate lift of the eyelid while retaining proper eyelid contour.

A recent study^[10] describing a single stitch müller muscle conjunctival resection for ptosis repair has suggested that only the central portion of the eyelid needs to be addressed surgically. Excellent results were demonstrated with this technique, and it is similar to the concept we propose for the external levator advancement surgery. We propose a technique for external levator resection that standardizes suture placement on only the central 6 mm of tarsus, thereby eliminating contour as an adjustable variable and simplifying the surgery.

METHODS

A retrospective chart review was performed at the practice of the main author. The institutional review board from Ascension St Vincent Hospital in Indianapolis granted exception status for the study. The research was Health Insurance Portability and Accountability Act compliant and adhered to the principles of the Declaration of Helsinki. All patients who underwent ptosis surgery by the main author from 2012 to 2019 using the central six technique were identified. The medical records were analyzed to record pertinent clinical examination measurements and outcomes, including measurements of margin-to-reflex distance (MRD₁) and reoperation rates.

Patients with aponeurotic ptosis with levator function greater than 12 mm were included. Exclusion criteria included those who underwent concomitant brow lifting procedures, those with prior ptosis surgery, and those with inadequate follow up.

Surgical technique

Cases were performed under monitored anesthesia care with approximately 4-5 mL of local anesthetic injected in each upper eyelid. Corneal protectors were placed to ensure no damage to the globe. A lid

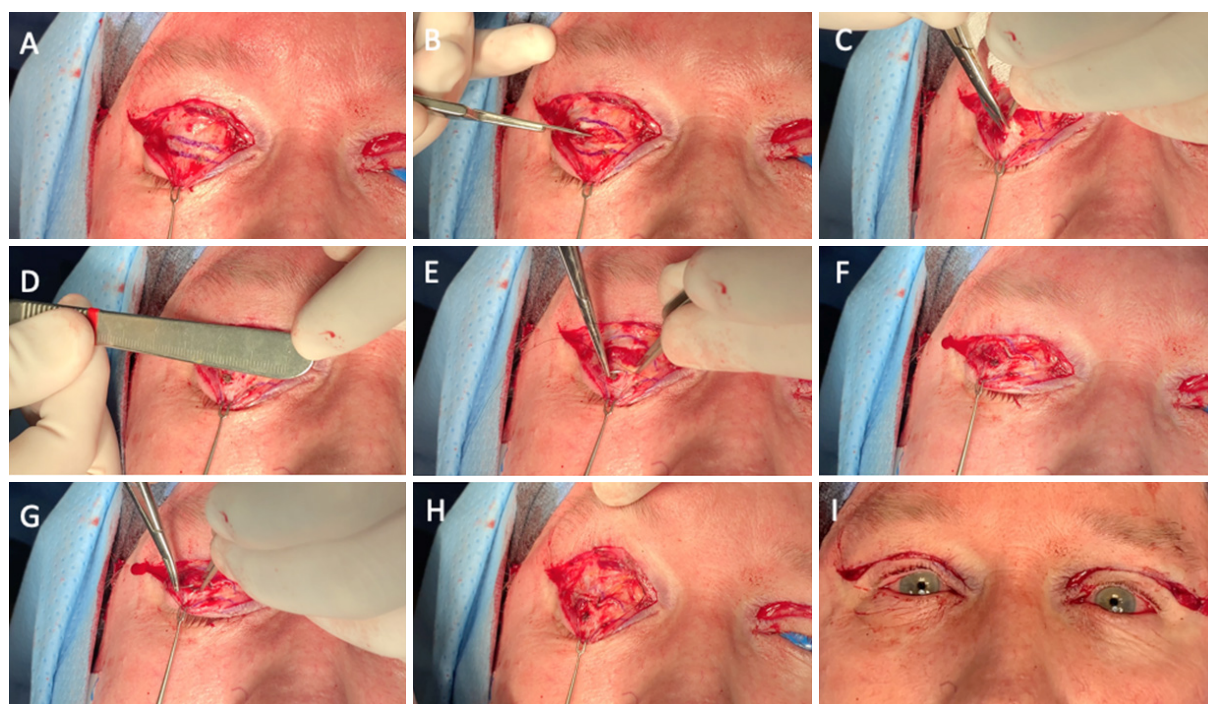


Figure 1. Surgical steps. A: after a blepharoplasty has been performed, the amount of levator resection is marked; B: a 15 Bard-Parker blade is used to cut through superior marking down to Mueller's muscle; C, D: the upper border of tarsus is exposed and the central 6 mm of tarsus is marked; E, F: a 6-0 silk suture is placed at the medial mark in a horizontal mattress fashion; G: a second 6-0 silk suture is placed at the lateral mark; H: the levator is advanced with two paracentral sutures. No sutures are placed outside of the central 6 mm; I: adequate lid height and symmetry is checked

crease incision was made, and standard blepharoplasty performed, in which skin and orbicularis muscle were removed. The lid was stretched with gentle retraction, and the upper border of tarsus was marked. A parallel line was placed 3-4 mm above the upper border of tarsus to mark the amount of levator aponeurosis to be resected. A 15 Bard-Parker blade was used to cut through septum and levator aponeurosis, exposing Mueller's muscle underneath. The peripheral marginal arcade was preserved. Sharp dissection was used to expose the central upper border of tarsus. The center of the tarsal plate was determined as the widest portion of tarsus. This point may not coincide with the midpoint of the eyelid, as many patients have a temporal shift of the tarsus with age. Appropriate hemostasis was achieved. Two paracentral marks were placed 6 mm apart to indicate the placement of sutures. Each mark was placed approximately 3 mm on either side of the center of tarsus, thus marking the "central six". One 6-0 silk horizontal mattress suture was placed partial thickness through the superior third of tarsus 3 mm medial to the center of tarsus and another passed 3 mm lateral to the center of tarsus. No sutures were placed outside of this central 6 mm zone. Patient fixation was then used to ensure adequate lid height and symmetry with the patient supine. Any adjustments were made and sutures tied down permanently. The skin was closed in a standard fashion. [Figure 1](#) demonstrates the key steps of central six technique for suture placement.

RESULTS

There were 85 patients identified who underwent surgery with the central six technique. The results are summarized in [Table 1](#). In total, 153 eyelids were included, with 68 patients undergoing bilateral surgery and 17 undergoing unilateral surgery. The average patient age was 68 years (range 38 to 73). The mean levator function was 14.45 mm (range 12 to 18 mm) and average follow-up was 3.4 months (range 1 to 17 months). The average preoperative MRD₁ was 1.05 mm (range -5 to 2 mm) and the average postoperative MRD₁ was 3.18 mm (range 1 to 5.5 mm), yielding a mean improvement in MRD₁ of 2.13 mm (standard deviation

Table 1. Results

Number of patients	85
Total eyelids	153
Bilateral surgery	68
Average age	72
Average preoperative MRD ₁	1.05 mm
Average postoperative MRD ₁	3.18 mm
Average improvement in MRD ₁	2.13 mm
Reoperation required	2
Post op symmetry (MRD ₁ difference < 1 mm)	91.2%
Patients satisfaction	96.5%

MRD₁: margin-to-reflex distance

1.32 mm). Only two patients (1.31%) required reoperation: one for overcorrection and the second for residual ptosis. Both of these patients had undergone unilateral surgery. The patient with residual ptosis who underwent reoperation had to be converted to general anesthesia intraoperatively due to patient pain and discomfort, thus not allowing for intraoperative adjustment of eyelid height. Of those who underwent bilateral surgery, 62 patients (91.2%) had satisfactory postoperative symmetry of eyelid height defined as an MRD₁ difference less than 1 mm between the two eyes. Postoperatively, 82 of 85 patients (96.5%) were satisfied with the outcomes of surgery. The three patients who were not satisfied included the two who required reoperation, while the third patient elected not to have a reoperation performed for residual ptosis. The two who underwent a secondary surgery using the same technique had good results. No patients developed postoperative lagophthalmos. There were no immediate postoperative complications. [Figure 2](#) shows typical patients who underwent surgery with the central six technique.

DISCUSSION

The two main goals of ptosis surgery are to restore eyelid height and contour, which can often be a challenging process requiring multiple intraoperative adjustments. The traditional approach is to place a central stitch to achieve the correct height, but this then leaves a peak centrally. Additional sutures are placed medially and laterally to restore a natural eyelid shape. Multiple techniques to simplify the procedure have been proposed since modern ptosis surgery was described in the 1970s by Jones *et al.*^[4]. In the 1990s, there were several modifications. Liu *et al.*^[6] proposed the concept of a single-suture ptosis repair, while Lucarelli and Lemke^[7] later introduced small incision ptosis repair without concurrent blepharoplasty. Meltzer *et al.*^[8] presented their experience using an adjustable suture. Later, Ahuero *et al.*^[9] proposed a refinement to small-incision surgery with a standardized suture placement at the medial pupillary border and lateral limbus.

In a similar fashion, our proposed technique standardizes suture placement and thus eliminates contour as an adjustable variable. In our practice, those patients who have external ptosis surgery performed generally require concomitant blepharoplasty for dermatochalasis and are not good candidates for small-incision ptosis surgery. We have had excellent results with high patient satisfaction by only focusing on the central 6 mm of tarsus for suture placement. Operative time is reduced, thus leading to improved patient comfort and safety. Intraoperative adjustments for height can be made by tightening or loosening sutures, or on occasion a suture must be replaced to achieve more lift. Eyelid contour is typically excellent, without need to adjust suture placement horizontally.

Eyelid contour is a key component to satisfactory lid position and appearance following ptosis repair, the components of which have been highly debated and remain difficult to objectively measure^[11-13]. External photos can be analyzed with geometrical models to quantify contour^[11]. Another technique involves

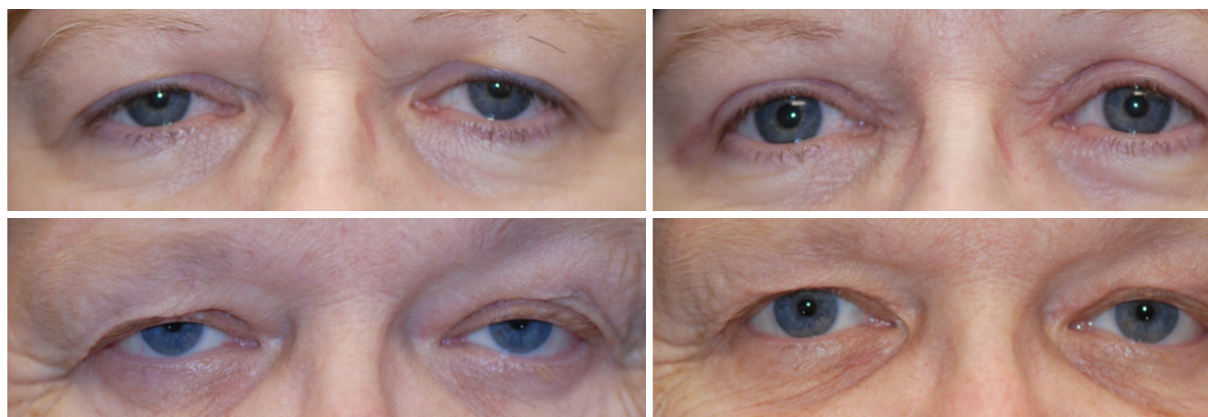


Figure 2. Preoperative and postoperative photos of patients who underwent bilateral surgery with the “central six” technique

measuring distances from mid-pupil to different points on the upper eyelid^[12]. Alternatively, blind graders can judge whether contour is adequate based on external photos. Ultimately, contour is important as it is a key component to postoperative patient satisfaction. A peaked eyelid or focal drooping results in abnormal appearance and displeased patients. In our study, we focused on patient satisfaction as an indirect measure of both good contour and adequate eyelid height. Eighty-two of the 85 patients (96.5%) in our study were satisfied with the outcomes of their surgery.

There are limitations to our study, including its retrospective nature and limited sample size. In addition, there was no control group to demonstrate statistically significant improvement over standard techniques. Our symmetry rate (91.2%) and satisfaction rate (96.5%) were among the high end of those published in the literature. We did not measure contour directly, but instead used patient satisfaction as an indirect measure of contour. The rates of intraoperative adjustment for eyelid height was not documented.

In conclusion, this simple and standardized technique for suture placement gives reliable and effective results for external levator resection for ptosis repair by eliminating contour as an adjustable variable. Addressing the central 6 mm of tarsus is not only paramount but also in and of itself satisfactory in achieving optimal contour during external levator resection, without regard to more medial or lateral lid anatomy.

DECLARATIONS

Authors' contributions

Made substantial contributions to conception and design of the study and performed data analysis and interpretation: Campbell BC, Nunery WR, Lee HBH

Performed data acquisition: Adjei ST

Availability of data and materials

Not applicable.

Financial support and sponsorship

None.

Conflicts of interest

All authors declared that there are no conflicts of interest.

Ethical approval and consent to participate

The institutional review board from Ascension St Vincent Hospital in Indianapolis granted exception status for the study. The research was Health Insurance Portability and Accountability Act compliant and adhered to the principles of the Declaration of Helsinki.

Consent for publication

Written consent was obtained for publication for patient images.

Copyright

© The Author(s) 2020.

REFERENCES

1. Anderson RL, Beard C. The levator aponeurosis. Attachments and their clinical significance. *Arch Ophthalmol* 1977;95:1437-41.
2. Pearl RM. Acquired ptosis: a reexamination of etiology and treatment. *Plast Reconstr Surg* 1985;76:56-64.
3. Anderson RL, Dixon RS. Aponeurotic ptosis surgery. *Arch Ophthalmol* 1979;97:1123-8.
4. Jones LT, Quickert MH, Wobig JL. The cure of ptosis by aponeurotic repair. *Arch Ophthalmol* 1975;93:629-34.
5. Eversbusch O. Zur operation der congenitalen blepharoptosis. *Klin Monatsbl Augenheilkd* 1883;21:100.
6. Liu D. Ptosis repair by single suture aponeurotic tuck: surgical technique and long-term results. *Ophthalmology* 1993;100:251-9.
7. Lucarelli MJ, Lemke BN. Small-incision external levator repair: technique and early results. *Am J Ophthalmol* 1999;127:637-44.
8. Meltzer MA, Elahi E, Taupeka P, Flores E. A simplified technique of ptosis repair using a single adjustable suture. *Ophthalmology* 2001;108:1889-92.
9. Ahuero AE, Winn BJ, Sires BS. Standardized suture placement for mini-invasive ptosis surgery. *Arch Facial Plast Surg* 2012;14:408-12.
10. Ediriwickrema LS, Geng J, Nair AA, Prendes M, Gerber AL, et al. Single suture müeller muscle conjunctival resection (ssMMCR): a modified technique for ptosis repair. *Ophthalmic Plast Reconstr Surg* 2019;35:403-6.
11. Malbouisson JM, Baccega A, Cruz AA. The geometrical basis of the eyelid contour. *Ophthalmic Plast Reconstr Surg* 2000;16:427-31.
12. Golbert M, Pereira FJ, Garcia DM, Cruz AAV. Contour symmetry of the upper eyelid following bilateral conjunctival-Müller's muscle resection. *Aesthet Surg J* 2017;37:269-75.
13. Ahn S, Lee H, Lee J, Park J, Park M, et al. Analysis of surgical outcome after levator advancement by assessing changes in eyelid contour. *J Craniofac Surg* 2016;27:1147-50.