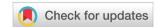

Technical Note

Open Access



Optimizing aesthetic outcomes in immediate prepectoral breast reconstruction using sharp-needle intradermal fat grafting: a clinical experience

Mirco Pozzi¹ , Luigi Losco¹ , Pietro Susini¹, Gianluca Marcaccini¹ , Vanessa Marron Mendes², Ishith Seth³ , Warren M. Rozen³, Roberto Cuomo¹ , Michela Schettino²

¹Unit of Plastic and Reconstructive Surgery, Department of Medicine, Surgery and Neuroscience, University of Siena, Siena 53100, Italy.

²Service de Chirurgie Plastique, Hôpital CHIREC, Braine-L'Alleud 1420, Belgium.

³Department of Plastic and Reconstructive Surgery, Peninsula Health, Melbourne 3199, Australia.

Correspondence to: Dr. Ishith Seth, Department of Plastic and Reconstructive Surgery, Peninsula Health, 2 Hastings Road, Melbourne 3199, Australia. E-mail: ishithseth1@gmail.com

How to cite this article: Pozzi M, Losco L, Susini P, Marcaccini G, Mendes VM, Seth I, Rozen WM, Cuomo R, Schettino M. Optimizing aesthetic outcomes in immediate prepectoral breast reconstruction using sharp-needle intradermal fat grafting: a clinical experience. *Plast Aesthet Res.* 2025;12:23. <https://dx.doi.org/10.20517/2347-9264.2024.146>

Received: 10 Nov 2024 **First Decision:** 7 Mar 2025 **Revised:** 8 Jun 2025 **Accepted:** 26 Jun 2025 **Published:** 4 Jul 2025

Academic Editor: Pietro Gentile **Copy Editor:** Ting-Ting Hu **Production Editor:** Ting-Ting Hu

Abstract

Breast reconstruction after mastectomy is a critical aspect of breast cancer treatment. This retrospective study analyzes the efficacy and safety of the sharp needle intradermal fat (SNIF) technique in immediate two-stage prepectoral breast reconstruction (PPBR) after mastectomy. A retrospective cohort analysis was conducted on patients who underwent SNIF fat grafting after mastectomy and PPBR. Demographics, surgical indications, procedures, and complications were analyzed. The SNIF procedure involves the precise injection of small fat particles into the dermal layer, aiming to improve skin texture and correct minor surface irregularities. Sixty-seven patients underwent the SNIF procedure after PPBR. The mean age was 53.2 years, with a range of 33 to 71 years. No serious complications, such as infection or fat embolism, were observed. Minor complications included ecchymosis in 30 patients and redness with mild swelling in 13 patients, all of which resolved within a few days after surgery. Patients and surgeons reported satisfactory cosmetic results. The SNIF technique, using small-diameter fat particles injected intradermally, shows promise for improving aesthetic results and minimizing complications in two-stage PPBR.

Keywords: Breast, breast reconstruction, snif, fat grafting



© The Author(s) 2025. **Open Access** This article is licensed under a Creative Commons Attribution 4.0 International License (<https://creativecommons.org/licenses/by/4.0/>), which permits unrestricted use, sharing, adaptation, distribution and reproduction in any medium or format, for any purpose, even commercially, as long as you give appropriate credit to the original author(s) and the source, provide a link to the Creative Commons license, and indicate if changes were made.



INTRODUCTION

Approximately 1 in 8 women in the United States is expected to face a diagnosis of invasive breast cancer during her lifetime. More broadly, the disease accounts for over 266,000 new cases annually, highlighting the significant health challenge posed by this neoplasm in the country^[1]. Implant-based reconstruction stands out as the primary method for restoring breast volume and contour following mastectomy^[2,3]. Over many years, the recommended approach has involved subpectoral implant placement to address the heightened complication rates associated with subcutaneous implant positioning. This preference stems from the well-vascularized nature of the muscular interface beneath the skin, which was believed to reduce the risk of capsular contracture and to afford superior protection for the prosthesis in case of wound breakdowns^[4-6]. Despite the perceived benefits, the pectoral elevation technique has drawbacks, including breast animation deformity, discomfort resulting from muscle spasms, and the potential for restricted shoulder motion^[7]. Recently, there has been increasing acknowledgment of the prepectoral breast reconstruction (PPBR) approach^[8-12]. First introduced in the 1960s^[13], PPBR has fallen into disuse due to significant complications, including infections, implant explantation, and capsular contracture^[14,15]. Moreover, the suboptimal soft tissue coverage over the prosthesis resulted in serious issues such as implant malposition, rippling, and palpability. Recent advances in mastectomy and breast reconstruction techniques incorporated innovative strategies, including the use of acellular dermal matrix, autologous fat grafting, and highly cohesive gel implants. These have been related to promising results, leading to a reevaluation of the PPBR approach, including one-stage and two-stage expander and prosthesis PPBR. In such a scenario, autologous fat grafting, also known as lipofilling, seems to play a crucial role. The technique involves the patient's own adipose tissue extraction, adequate purification, and subsequent injection into the breast area. In the context of two-stage PPBRs, it is a valuable adjunct to improve breast volume, contour, and overall aesthetic results. Moreover, it provides a natural-looking soft tissue coverage and reduces the risk of implant palpability and rippling. Finally, it improves breast symmetry and long-term patient satisfaction.

At our breast oncology center, there has been a significant shift in our approach to implant-based breast reconstructions. We have transitioned from predominantly performing retropectoral reconstructions to embracing the PPBR technique. This change represents a strategic evolution of our surgical practices, driven by advances in breast reconstruction methodologies and a desire to optimize patient outcomes. According to our experience, the PPBR approach offers several advantages, including reduced postoperative pain, minimized muscle-related complications, and improved aesthetic results. Lipofilling is key to improving volume, contour, and overall aesthetic results.

Introducing autologous fat grafts helps solve common challenges associated with implant-based reconstructions, such as achieving natural-looking soft tissue coverage and minimizing the risk of palpability and rippling. Additionally, it helps improve the symmetry and long-term satisfaction of breast reconstruction patients. Scientifically, studies have demonstrated the regenerative potential of adipose-derived stem cells within the graft, providing additional benefits such as improved vascularization and tissue quality^[16-18]. This underscores the multifaceted significance of lipofilling in PPBR, highlighting its role in achieving aesthetic excellence and contributing to the biological viability of the reconstructed breast^[16-20].

Recently, the sharp needle intradermal fat (SNIF) procedure, first described in facial rejuvenation, has been related to significant advantages. The technique involves extracting small-diameter fat particles using dedicated harvesting cannulas, followed by accurate fat processing. The filtered fat is then injected into the skin using a sharp needle, ensuring precise fat placement, optimizing the capillary contact and improving fat survival. The key to the SNIF technique's success lies in using micrografts, which will enhance graft survival and minimize complications. The SNIF technique is a safe, effective, and cost-effective option, offering

patients natural and long-lasting results in facial rejuvenation^[21,22]. This article aims to elucidate our experience with the SNIF technique in immediate two-stage breast reconstruction after mastectomy.

METHODS

We retrospectively reviewed patients who underwent the SNIF fat grafting procedure following mastectomy and PPBR at our clinic in Braine L'Alleud, Belgium, between January 2021 and September 2023. All patients underwent two-staged PPBR with a prepectoral tissue expander and prosthesis. The SNIF procedure was performed at the time of breast expander replacement with a definitive implant in the second stage of the PPBR.

The aesthetic and morphological analysis by the senior author indicated the use of SNIF fat grafting. The SNIF procedure addressed patients presenting with very thin or irradiated mastectomy flaps or patients showing post-mastectomy skin irregularities. Compared to traditional lipofilling, the SNIF aims to enhance skin quality and texture, whereas the conventional procedure focuses on modifying breast volumes and contours. It, therefore, represents an adjunct to traditional lipofilling rather than an alternative technique. It is technically applicable to all patients who undergo traditional lipofilling. However, it is particularly indicated for those who require an improvement in tissue quality rather than contour, aiming to extend the results documented by Zeltzer *et al.* concerning facial rejuvenation with intradermal lipofilling^[21]. Patients presenting with absent or hypertrophic fat deposits were considered ineligible. All patients were 18 or older, and the minimum follow-up was one year.

Patients who underwent a different type of breast reconstruction other than two-stage PPBR were excluded. Patients were also excluded if they received traditional lipofilling without the SNIF procedure. Missing/incomplete data on demographics (age, sex, smoking habits, drug assumption, indication for surgery, and surgical procedure) and missing/incomplete follow-up were also considered exclusion criteria. Detailed information regarding breast reconstruction, fat grafting, SNIF procedure, and possible complications was shared with all patients at the time of consultation. Informed written consent was obtained from all enrolled patients to analyze and publish personal data. The article adhered to the principles outlined in the Declaration of Helsinki.

Reviewing patient records, we analyzed demographics, indications for surgery, surgical procedures, and complication rates. The volume of injected fat was quantified for each procedure. SNIF-specific complications were also assessed, including infection, contour irregularities, cyst formation, and fat embolism. Photographic documentation was collected both before the surgeries and during the SNIF procedures, as well as at the one-year follow-up.

The Breast-Q questionnaire was administered to our patients in August 2024 to assess their satisfaction and perception of the results. Specifically, the questionnaire explored the patient's satisfaction with Physical, Psychosocial, and sexual well-being, Surgical results, the Surgeon and Surgical Team, Information, and Hospital Care. Each scale was administered and scored independently, following the BREAST-Q Version 2.0 User's Guide (qportfolio-lio.org/breast-q). Each scale was scored independently into a 0-100 Q-score.

Finally, all patients were preoperatively and postoperatively (12 months after the surgery) evaluated using high-resolution ultrasound imaging (Vevo MD, Fujifilm Visu-alSonic). The SNIF procedure was considered successful for an increase in mastectomy skin flap thickness of more than 0.3 cm, measured at the apex of the breast mound, corresponding to the nipple-areola complex. Particular attention was given to the dermal layer to assess improvements in the cutaneous flap.

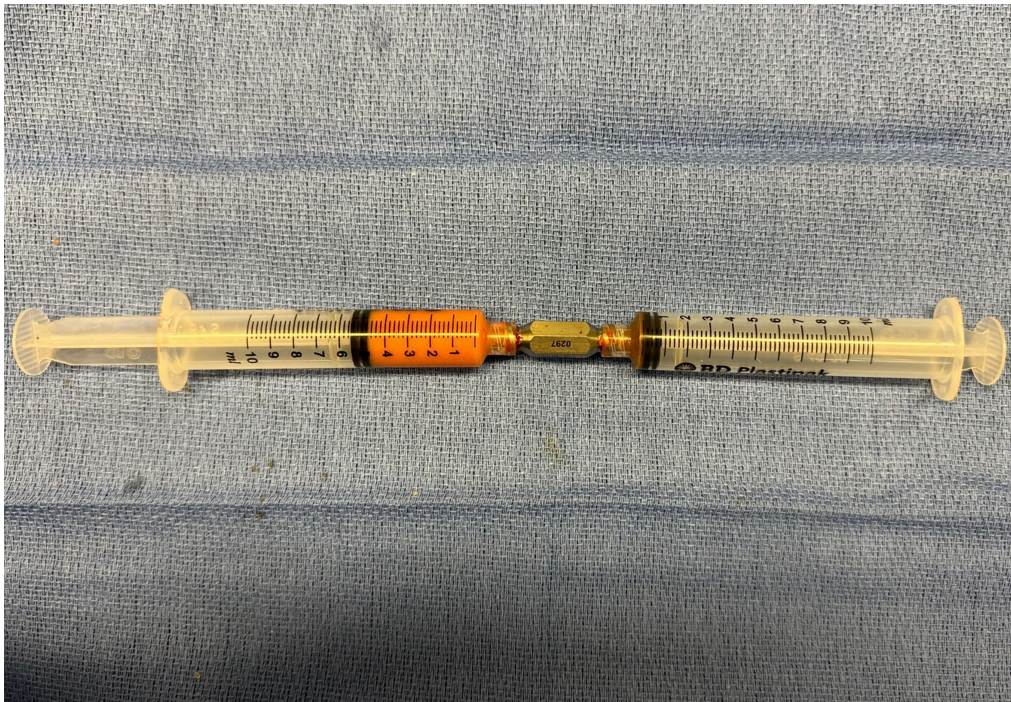

Figure 1. The emulsified fat graft; note the foamy consistency.

Operative technique

Two sequential surgeries are performed during the same surgical session. First, the tissue expander is replaced with the definitive breast implant. Secondly, we proceed with breast lipofilling and SNIF procedures. A careful preoperative analysis, including markings, is performed to determine the volume and placement area for the fat graft, with the patient in the standing position, before induction of anesthesia. Natural fat deposits are evaluated throughout the body, and their contours are marked on the skin. Our first choice is the saddlebags, inner thighs, and knees, preserving the abdominal perforators in the event of a future deep inferior epigastric perforator (DIEP) flap.

All of our patients undergo a combination of traditional lipofilling and concomitant SNIF. Based on the patients' needs, we variably combine the procedures. Specifically, patients requiring a breast contour change receive mostly traditional lipofilling. If the contour is acceptable, but the patient requires improvement in the quality of the tissues, we prefer to mainly use SNIF. The decision is based on the clinical evaluation of tissue quality, texture, and breast shape. The effects of the two procedures could be separated. However, in our experience, we have used these techniques in combination to achieve synergistic effects - traditional lipofilling for volume enhancement and SNIF for improving the quality of the superficial tissues.

Adipose tissue is harvested using an adrenaline-containing local anesthetic. First, a modified Klein solution comprising 800 mg lidocaine and adrenaline (1/1,000,000) is in-filtered, following the standard protocol for liposuction procedures. The infiltration technique used a "wet" approach, with a 2:1 ratio of infiltrate to aspirate. Subsequently, an assisted suction lipectomy is performed with a suction device and sterile container. The harvesting cannula's diameter ranges from 2 to 3 mm and is characterized by multiple 1 mm holes along its upper segment. The limited diameter of the cannula holes is crucial for obtaining small fat particles suitable for injection.

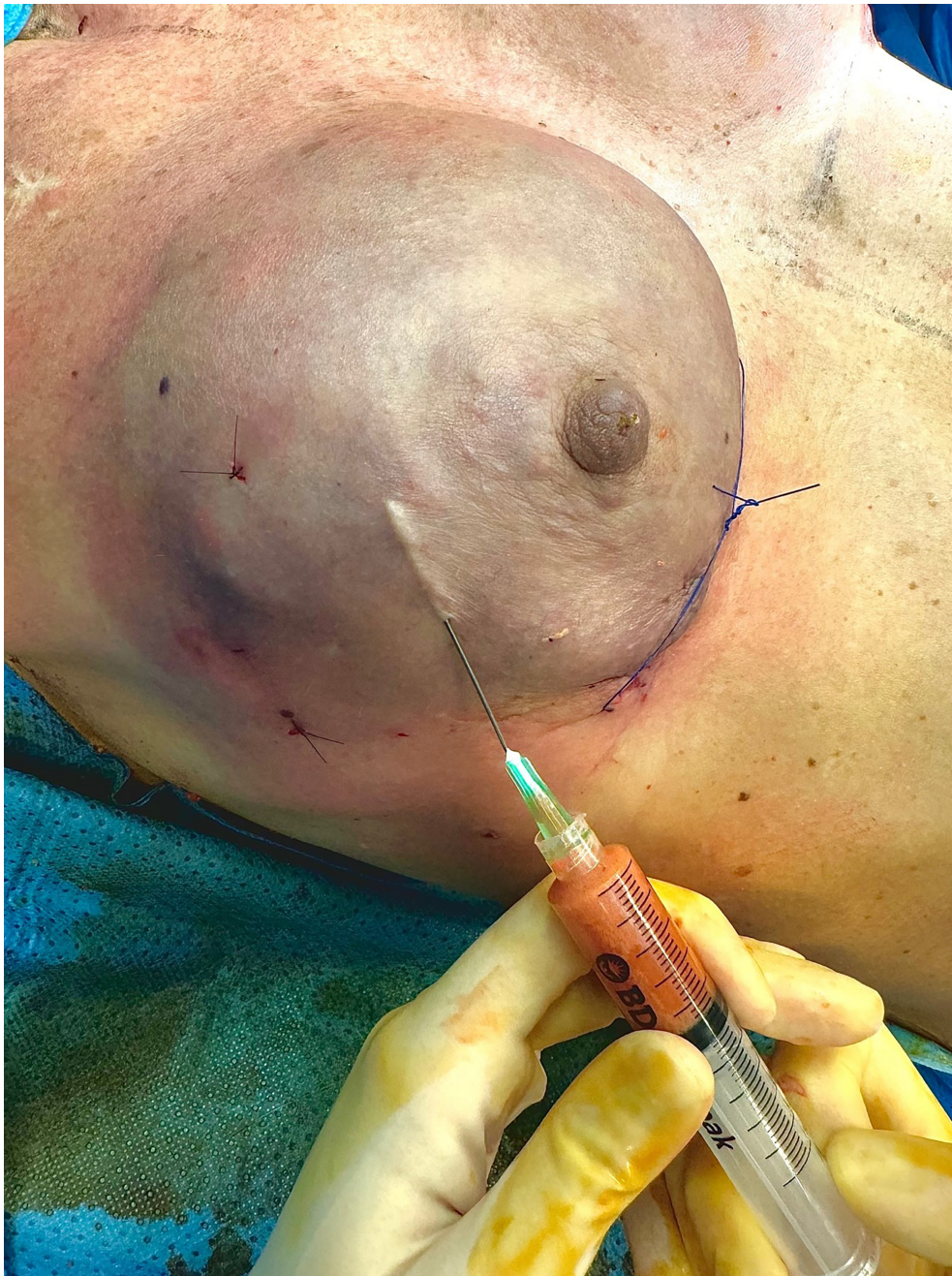


Figure 2. The injection technique in the intradermal plane, with a sharp small needle.

After the suction, centrifugation at 3,000 rpm per three min of the syringes is performed in batches of 6. This process separates the fat into three layers. Only the purified fat's middle layer is retained and passed through several syringes to obtain an emulsified graft with a foamy consistency [Figure 1].

A 23-gauge sharp needle or a small cannula 0.81 mm × 70 mm is used for injection, linearly addressing the superficial dermal plane. The SNIF particles are released as the needle is withdrawn [Figures 2 and 3]. The average dermal fat volume injection is 4.6 cc (3-8 cc) with a 1 to 3 ratio for dermal/subcutaneous space fat volume injection, considering an average of 35.6 cc (24-45 cc) of total lipotransfer. Lipofilling and SNIF are

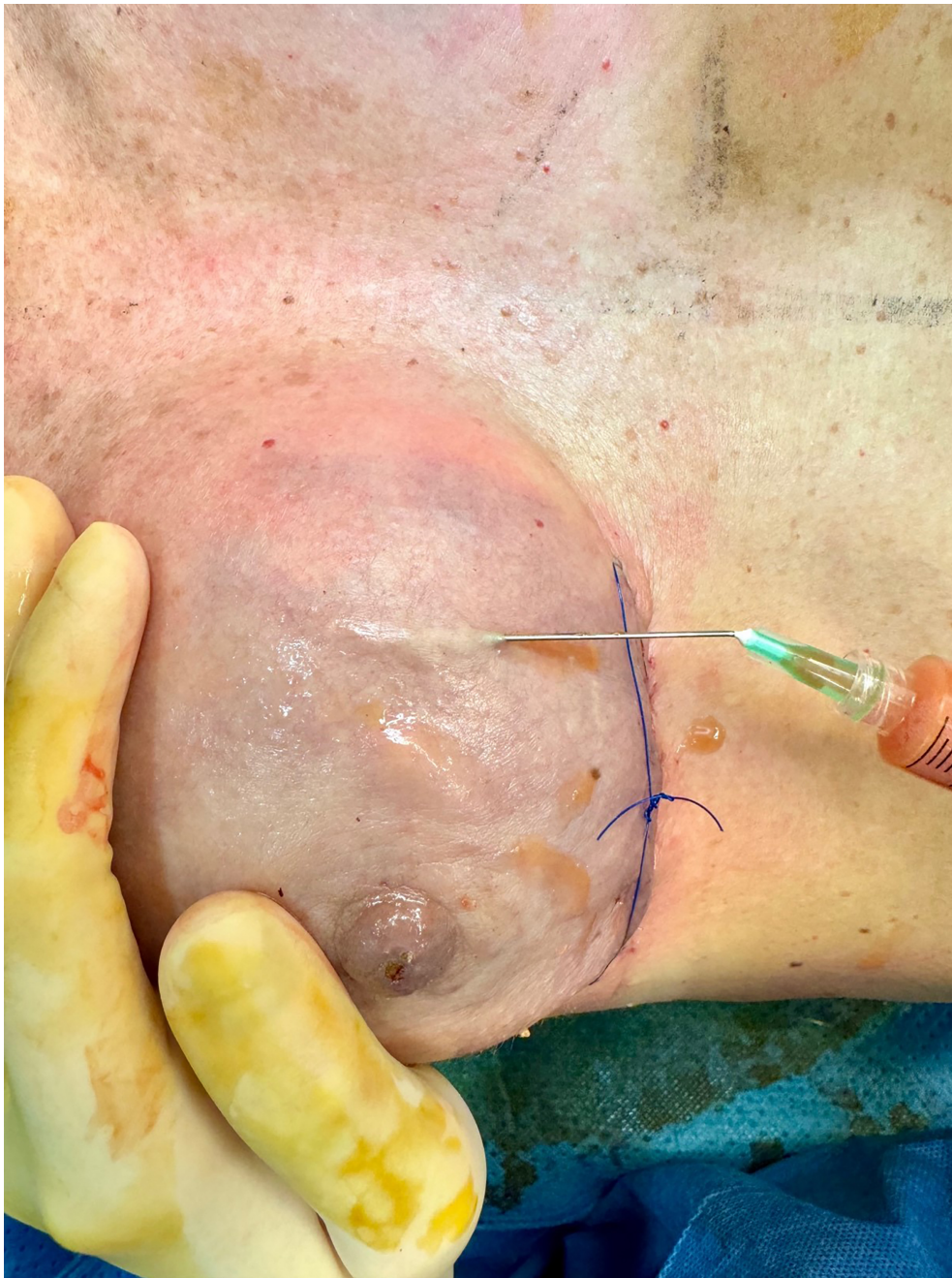

Figure 3. To facilitate fat injection, it is possible to manually adjust the orientation of the needle.

always performed after the positioning of the definitive prosthesis to determine the shape and characteristics of the breast being treated, as in common clinical practice. In our experience, the procedure is safe, and there is no risk of piercing the prosthesis if the treatment is performed correctly and is limited to the target area, specifically the dermis. Notably, to safely perform the SNIF, treatment must be directed to the very superficial skin layer, the dermis, and injections should be performed tangentially, keeping the needle parallel to the skin surface.

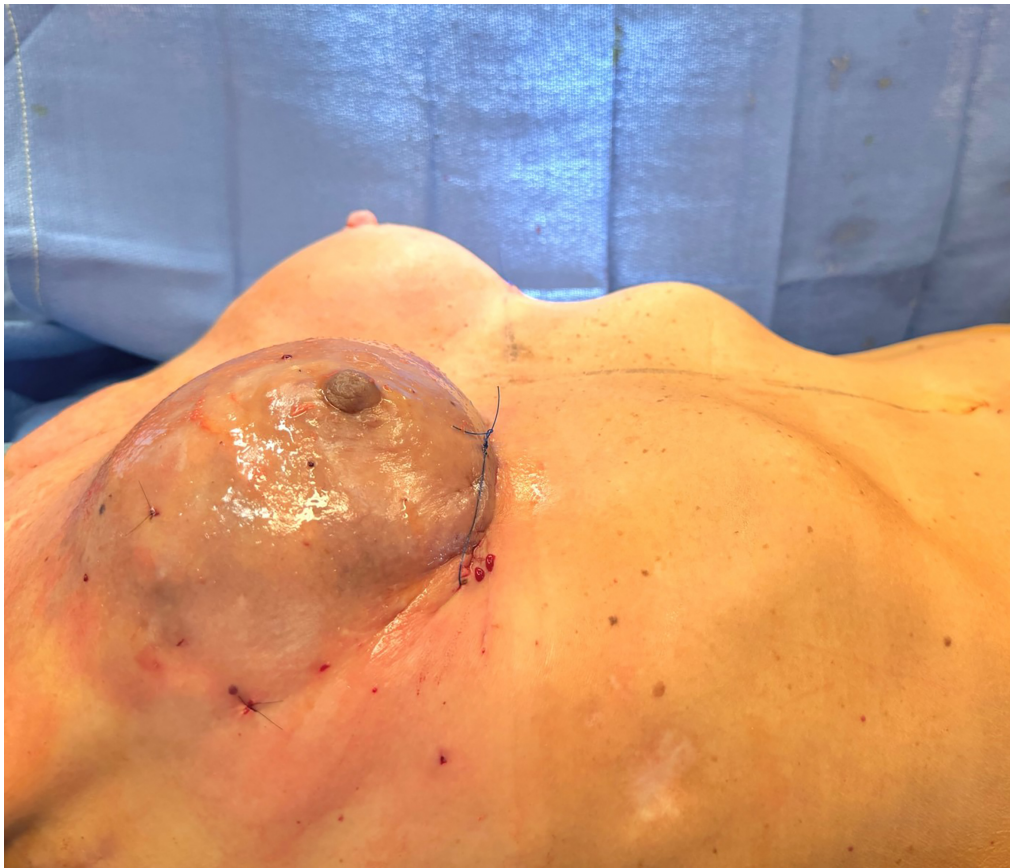

Figure 4. It is possible to apply the eventually remaining fat directly onto the skin as a biological dressing.

After the injection, the skin appears blanching above the treated area. It is recommended to slightly overcorrect the defect. Indeed, this blanching will typically resolve within a few hours as the interstitial fluid is absorbed.

The SNIF procedure can be performed as a supplementary and final procedure after classic lipofilling. Fat grafting and SNIF are always performed at the end of the procedure, following tissue expander exchange with the definitive prosthesis, after adequate surgical access suture. Finally, the remaining fat can be applied directly onto the breast skin as a biological dressing [Figure 4]. Postoperative bandages typically consist of sterile gauze and an elastic compression bra.

All patients receive intraoperative antibiotic prophylaxis with amoxicillin and clavulanate. Surgical follow-up is regularly performed for at least one year after the procedure and then continued if necessary.

RESULTS

From January 2021 to September 2023, 67 patients underwent SNIF procedure following PPBR at our clinic in Braine L'Alleud. The senior author performed all surgeries. Patients' demographics and complications are reported [Table 1]. The median age was 53 years old (range 33-71), 9 (13%) were smokers, and 3 were diabetics (4%). Twenty-one patients (31%) underwent radiotherapy following mastectomy and breast expander reconstruction. In these groups, SNIF was performed a mean of 4 months after radiotherapy (range: 3-8 months) and 6 months after mastectomy (range: 5-9 months). Additionally, 23 (34%) received

Table 1. Patient's demographics and complications

Demographics	
N. patients	67
Median age	53 (33-71)
Smoke	9/67 (13%)
Diabetes	3/67 (4%)
Radiotherapy	21/67 (31%)
Neoadjuvant chemotherapy	23 (34%)
Adjuvant chemotherapy	9 (13%)
SNIF fat volume	4.6 cc (3-8 cc)
Mastectomy flap thickness increase > 0.3 cm	82.1% (55/67 patients)
Complications	
Bruising	30/67 (35%)
Redness and mild swelling	13/67 (15%)

SNIF: Sharp needle intradermal fat.

neoadjuvant chemotherapy, and 9 (13%) received adjuvant chemotherapy. SNIF was performed within the breast dermis, with an average injected fat volume of 4.6 cc (range: 3-8 cc).

All patients were followed up for at least 18 months (average follow-up 20, range 18-24 months). No indurations, cysts, or infections were observed, and no severe complications, such as necrosis or fat emboli, resulted from intravascular injection. Bruising was noted in 30 patients (35%), while redness accompanied by mild swelling occurred in 13 patients (15%), all of which resolved within several days post-procedure. No surface irregularities, such as lumpiness or unevenness, were observed among our patients.

Satisfactory aesthetic results were reported by all patients and surgeons, according to clinical examination and patient photographs. The ultrasound study documented an increase in the thickness of the mastectomy flaps both before and after the expander exchange with a definitive implant and SNIF. Particularly, mastectomy flap thickness increase of > 0.3 cm was documented in 82.1% (55/67 patients) at the 12-month follow-up, demonstrating the efficacy of the procedure. Notably, an increase in dermal layer thickness was also reported, suggesting a positive adipose tissue engraftment integration in the dermis layer. A non-significant difference was documented in radio-treated patients with a flap thickness increase of > 0.3 cm in 81.0% (17/21 patients). The Breast Q questionnaire was administered in August 2024. Of the 67 patients, 46 (68.7%) answered the questionnaire. Overall, positive results were reported, particularly for Surgical Results (88, range 75-100), the Surgical team, and Information [Table 2].

The relationship between complication rates and patients' demographics was tested according to the chi-squared test and found to be not significant ($P > 0.05$).

DISCUSSION

At our breast oncology center, there has been a significant shift in our implant-based breast reconstruction approach. We have transitioned from predominantly performing subpectoral reconstructions to embracing the PPBR technique, specifically, a two-stage PPBR with an expander and prosthesis, lipofilling, and SNIF. This change represents a strategic evolution of our surgical practices, driven by the growing evidence available in the literature on breast reconstruction methodologies and a personal desire to optimize patient outcomes. Per our experience, the PPBR offers several advantages, including reduced postoperative pain, minimized muscle-related complications, and improved aesthetic results. The choice of two-stage PPBR

Table 2. Outcomes of the breast-Q questionnaire

Breast-Q scale	Outcome
n. questionnaire	46/67 (68.7%)
Psychosocial well-being	78 (50-100)
Sexual well-being	60 (40-90)
Physical well-being	80 (65-100)
Satisfaction with surgical results	88 (75-100)
Satisfaction with the surgeon	85 (70-100)
Satisfaction with the information	80 (70-100)
Satisfaction with the surgical team	85 (70-100)
Satisfaction with the hospital	60 (40-90)

represents a new frontier in the field of breast reconstruction, coupling the benefit of prepectoral reconstructions in terms of reduced pain, reduced morbidity, animation deformity, and surgical risks. Breast expander placement in the prepectoral space could seem unnecessary. However, the use of an expander minimizes trauma to the mastectomy flap, reducing the risk of dehiscence and implant loss, while allowing to perform radiotherapy and chemotherapy on an expander and not on a definitive prosthesis. At the time of breast expander with definitive implant exchange, additional procedures can be considered.

Breast lipomodeling, also referred to as breast fat transfer, has been related over the past two decades to significant benefits in the field of breast reconstructive surgery and, particularly, in implant-based reconstructions^[23-26]. Specifically, it represents a landmark development, serving as an optimal complement to breast reconstruction^[27-30]. Several studies have demonstrated the regenerative potential of adipose-derived stem cells within the graft, providing additional benefits regarding tissue vascularization and quality^[16-20]. Such a phenomenon underscores the multifaceted significance of lipofilling in PPBRs, contributing to both aesthetic excellence and biological viability of the reconstructed breasts^[16-20]. Moreover, lipofilling has been shown to positively impact cosmesis and patient satisfaction. Indeed, Bonomi *et al.* reported satisfaction rates of “moderately good”, “good”, and “very good” in 10%, 40%, and 50% of patients, respectively, in a study of patients undergoing breast reconstruction and lipomodeling^[26].

Recently, the SNIF procedure has been described as a promising alternative to traditional lipofilling. It was first described by Zeltzer *et al.* in 2012 as an intradermal fat injection technique to address wrinkles in facial rejuvenation. It was applied in cosmetic surgery to enhance facial aesthetics, fill wrinkles, and restore age-related facial volume loss^[21]. The SNIF is based on fat transforming into small particles using specialized processing cannulas with multiple sharp holes. These enable precise injections into the dermal layer. Unlike traditional synthetic dermal fillers, the SNIF procedure is based on autologous fat, thus avoiding complications such as unwanted foreign body reactions and hypersensitivity. Compared to conventional lipofilling, the small fat particles remain in better contact with the recipient area’s capillaries, potentially resulting in improved graft survival rates. As a result, the SNIF procedure could offer longer-lasting and more natural results. When properly performed, the procedure is also minimally invasive and presents a low risk of complications. Overall, it represents a safe, effective, and cost-effective option, offering natural and long-lasting results in facial rejuvenation^[21,22].

Based on our experience, the combination of SNIF and lipofilling in PPBR can significantly advance reconstructive and regenerative surgery. The SNIF offers a significant advantage after mastectomy by enhancing skin quality and filling minor skin surface imperfections. These are rarely improved by traditional lipofilling. Before introducing SNIF into our routine clinical practice, we performed traditional

lipofilling alone. Despite the positive experience, we wanted to extend the treatment to the dermal layer, aiming to maximize our outcomes.

The SNIF procedure enables fat preparation into smaller particles, optimizing their contact with blood vessels in the reconstructed breast. This promotes better survival of the transplanted tissue and harmonious integration with the surrounding tissue. Moreover, the intradermal injection of autologous fat enhances the quality of the overlying skin, promoting tissue regeneration and possibly stimulating collagen production. Empirically, it improves skin texture, thickness, and overall appearance, leading to natural and long-lasting breast reconstructions that yield satisfactory aesthetic outcomes and reduce the need for secondary procedures over time.

In our experience, following the introduction of SNIF in our surgical practice, we observed softer mastectomy skin flaps and improved tissue quality, as confirmed by the imaging results. Specifically, the introduction of the SNIF technique in PPBR has represented a significant advancement, as evidenced by high-resolution ultrasound findings. These studies have demonstrated a substantial increase in the thickness of the mastectomy flaps and a positive integration of the transplanted adipose tissue within the deep dermal layers. High-resolution ultrasound has enabled us to precisely monitor postoperative changes, revealing not only the engraftment of adipose tissue but also an improvement in dermal quality and skin tropism. These results indicate that SNIF could promote tissue regeneration and vascularization due to the presence of adipose-derived stem cells. This approach, therefore, offers a dual advantage: enhancing the aesthetic outcomes of breast reconstruction while providing potential biological benefits for the skin, underscoring the importance of SNIF in the contemporary landscape of reconstructive surgery.

We do not have histological evidence of the effects of SNIF on the dermis, so this could be the next step. However, our findings agree with the reported benefits of intra-dermal grafting for facial rejuvenation, as reported by Zeltzer *et al.*^[21].

Overall, the combination of SNIF with lipofilling for patients undergoing breast reconstruction is a safe, effective, and long-lasting solution to restore breast shape and symmetry post-mastectomy. The procedure addresses minor superficial skin imperfections and improves skin tropism. It should be considered and combined with traditional lipofilling in patients with a thin mastectomy skin flap, with small and hardly correctable irregularities. At the end of our procedures, we may add any remaining fat on top of the breast's skin as a biological medication [Figure 4]. Although strong evidence is lacking, it has been demonstrated that adipose tissue contains stem cells, nutrients, and biological factors beneficial to the skin. It is routinely used to treat ulcers and burns. Likewise, it could promote healing and tropism of the breast skin. This particular dressing does not require additional procedures and does not cause unwanted effects, representing a possible helpful addition^[31-34].

The SNIF procedure is safe. We did not observe complications in terms of fat necrosis or uneven fat absorption. A key element to limit complications could be linked to the volume of adipose tissue transplanted. In fact, we do not recommend exceeding the volume, especially in the dermis, which is poorly extensible. Excessive lipofilling would lead to an increase in interstitial pressure with consequent compressive ischemia of the adipocytes, compromising the result of the procedure. If contour anomalies persist, the procedure can be safely repeated after 3 months.

Recent advances in PPBR have highlighted the integration of innovative materials and techniques to optimize outcomes. The use of titanium-coated polypropylene mesh in PPBR, as described by Gentile *et al.*

(2021), has demonstrated significant promise in enhancing soft tissue integration and providing structural support while minimizing capsular contracture risks (DOI: 10.1016/j.bioactmat.2021.05.002)^[35]. This bioactive material fosters improved tissue outcomes in conservative mastectomies and prepectoral reconstructions, supporting its role in complex reconstructive scenarios.

Fat grafting has emerged as a pivotal adjunct in reconstructive breast surgery, offering potential benefits in achieving superior contouring and aesthetic outcomes. Gentile and Valerio's systematic review (2022) confirms the oncological safety of autologous fat grafting, addressing long-standing concerns about its impact on breast cancer recurrence^[35]. Recent studies on fat grafting techniques, including manipulation and precision delivery, underscore advancements in achieving consistent volumetric enhancement and aesthetic contouring^[36]. Moreover, Seth *et al.* (2024) highlight the need for clinical caution in fat grafting, emphasizing meticulous patient selection and adherence to best practices to mitigate complications such as fat necrosis and graft resorption^[37]. Sharp-needle intradermal fat grafting offers a refined approach, facilitating precise placement of adipose tissue to address superficial irregularities and optimize skin texture, further complementing immediate prepectoral reconstructions.

These insights collectively underscore the growing role of advanced materials and precise fat grafting techniques in PPBR, paving the way for improved patient satisfaction and aesthetic outcomes.

Clinical examination, photographs, high-resolution ultrasound imaging, and the Breast-Q questionnaire were used to assess patient satisfaction and aesthetic outcomes. The present paper highlights the clinical utility of the SNIF procedure in PPBR. Moreover, it shares a promising alternative field of application for techniques other than facial rejuvenation. It is hoped that future studies will validate the present findings, possibly extending the SNIF application to alternative breast reconstruction techniques or lipofilling strategies. Moreover, future evidence comparing traditional lipofilling versus SNIF alone versus lipofilling with SNIF is expected, including studies on histopathological examination.

Limitation analysis

The main limitation of performing breast reconstruction with PPBR and subsequent replacement of the expander with prosthesis and concomitant SNIF is that it requires two surgical steps, compared to direct reconstructions with prosthesis. However, prepectoral expander placement allows for a muscle-sparing breast reconstruction even in those cases in which PPBR would be contraindicated or unlikely to succeed due to the risk of complications, such as wound dehiscence or implant loss. It could be advantageous for selected patients.

Lipofilling can be done at the same time as the replacement of the expander with the prosthesis; it is not painful, has few complications, and is universally recognized in aesthetic surgery for its biorevitalizing properties, as demonstrated in facial rejuvenation. The treatment of the dermal layer is an additional step that optimizes lipofilling in a safe and effective way without any additional costs. It is also an easily reproducible procedure, technically simple. Overall, the SNIF could represent a new strategy in the plastic surgeon's toolbox that offers additional advantages with minimal cost to the patient. Concerning the specific limitation of the article, it has a limited sample and lacks a true comparative analysis of SNIF vs traditional lipofilling. The latter could represent an interesting future step.

In conclusion, the potential application of the SNIF technique in breast reconstruction holds promise for enhancing surgical outcomes. The SNIF procedure, by using small-diameter filtered fat particles harvested through specialized cannulas, offers a precise and minimally invasive approach to complement breast

volume and contour. This method seems particularly advantageous in immediate two-stage PPBR after mastectomy since preserving aesthetic integrity and achieving natural-looking results are paramount. The micrografts obtained through the SNIF procedure facilitate graft survival and minimize complications, offering a safe and effective option. Further research and clinical studies are warranted to explore the full potential of the SNIF technique in breast reconstruction.

DECLARATIONS

Authors' contributions

Conceptualization: Pozzi M, Schettino M

Methodology: Susini P, Marcaccini G

Software: Mendes VM

Validation: Losco L, Cuomo R

Formal analysis: Susini P

Investigation: Pozzi M

Resources: Mendes VM, Marcaccini G

Data curation: Seth I, Rozen WM, Schettino M

Writing - original draft preparation: Pozzi M

Writing - review and editing: Susini P

Visualization: Rozen WM, Seth I, Cuomo R

Supervision: Schettino M

Project administration: Losco L

All authors have read and agreed to the published version of the manuscript.

Availability of data and materials

The data presented in this study are available from the corresponding author upon reasonable request. They are not publicly available due to the privacy of research participants.

Financial support and sponsorship

None.

Conflicts of interest

Rozen WM is an Editorial Board member of the journal *Plastic and Aesthetic Research*. Seth I is a Junior Editorial Board member of the journal *Plastic and Aesthetic Research*. Rozen WM and Seth I were not involved in any steps of editorial processing, notably including reviewer selection, manuscript handling, or decision making. The other authors declared that there are no conflicts of interest.

Ethical approval and consent to participate

The study was conducted following the Declaration of Helsinki, and approved by the Ethics Committee of Chirec Braine L'Alleud H ôpital LNR:2024/11. Informed consent was obtained from all subjects involved in the study.

Consent for publication

Informed consent was obtained from all subjects involved in the study.

Copyright

© The Author(s) 2025.

REFERENCES

1. Breastcancer-Org. Breast cancer facts and statistics. Available from: <https://www.breastcancer.org/facts-statistics>. [Last accessed on 27 Jun 2025].
2. Ilonzo N, Tsang A, Tsantes S, Estabrook A, Thu Ma AM. Breast reconstruction after mastectomy: a ten-year analysis of trends and immediate postoperative outcomes. *Breast*. 2017;32:7-12. DOI PubMed
3. Leff DR, Bottle A, Mayer E, et al. Trends in immediate postmastectomy breast reconstruction in the United Kingdom. *Plast Reconstr Surg Glob Open*. 2015;3:e507. DOI PubMed PMC
4. Gruber RP, Kahn RA, Lash H, Maser MR, Apfelberg DB, Laub DR. Breast reconstruction following mastectomy: a comparison of submuscular and subcutaneous techniques. *Plast Reconstr Surg*. 1981;67:312-7. DOI PubMed
5. Susini P, Nisi G, Pierazzi DM, et al. Advances on capsular contracture-prevention and management strategies: a narrative review of the literature. *Plast Reconstr Surg Glob Open*. 2023;11:e5034. DOI PubMed PMC
6. Nahai F, Bostwick J 3rd. Aesthetic aspects of breast reconstruction. *Aesthetic Plast Surg*. 1982;6:61-7. DOI PubMed
7. Becker H, Fregosi N. The impact of animation deformity on quality of life in post-mastectomy reconstruction patients. *Aesthet Surg J*. 2017;37:531-6. DOI PubMed
8. Reitsamer R, Peintinger F. Prepectoral implant placement and complete coverage with porcine acellular dermal matrix: a new technique for direct-to-implant breast reconstruction after nipple-sparing mastectomy. *J Plast Reconstr Aesthet Surg*. 2015;68:162-7. DOI PubMed
9. Sigalove S, Maxwell GP, Sigalove NM, et al. Prepectoral implant-based breast reconstruction: rationale, indications, and preliminary results. *Plast Reconstr Surg*. 2017;139:287-94. DOI PubMed
10. Sbitany H, Piper M, Lentz R. Prepectoral breast reconstruction: a safe alternative to submuscular prosthetic reconstruction following nipple-sparing mastectomy. *Plast Reconstr Surg*. 2017;140:432-43. DOI PubMed
11. Jones G, Yoo A, King V, et al. Prepectoral immediate direct-to-implant breast reconstruction with anterior alloderm coverage. *Plast Reconstr Surg*. 2017;140:31S-8. DOI PubMed
12. Nahabedian MY, Cocilovo C. Two-stage prosthetic breast reconstruction: a comparison between prepectoral and partial subpectoral techniques. *Plast Reconstr Surg*. 2017;140:22S-30. DOI PubMed
13. Freeman BS. Subcutaneous mastectomy for benign breast lesions with immediate or delayed prosthetic replacement. *Plast Reconstr Surg Transplant Bull*. 1962;30:676-82. DOI PubMed
14. Redi U, Marcasciano M, Lo Torto F, Patanè L, Ribuffo D. Invited response on: dual-plane retro-pectoral versus pre-pectoral DTI breast reconstruction: an Italian multicenter experience. *Aesthetic Plast Surg*. 2021;45:1348-9. DOI PubMed
15. Schlenker JD, Bueno RA, Ricketson G, Lynch JB. Loss of silicone implants after subcutaneous mastectomy and reconstruction. *Plast Reconstr Surg*. 1978;62:853-61. DOI PubMed
16. Razzouk K, Fitoussi A, Al Khori N, Pasquier J, Chouchane L, Tabrizi AR. Breast reconstruction combining lipofilling and prepectoral prosthesis after radiotherapy. *Plast Reconstr Surg Glob Open*. 2020;8:e2659. DOI PubMed PMC
17. Silva-Vergara C, Fontdevila J, Descarrega J, Burdio F, Yoon TS, Grande L. Oncological outcomes of lipofilling breast reconstruction: 195 consecutive cases and literature review. *J Plast Reconstr Aesthet Surg*. 2016;69:475-81. DOI PubMed
18. Stillaert FB, Lannau B, Van Landuyt K, Blondeel PN. The prepectoral, hybrid breast reconstruction: the synergy of lipofilling and breast implants. *Plast Reconstr Surg Glob Open*. 2020;8:e2966. DOI PubMed PMC
19. Turner A, Abu-Ghname A, Davis MJ, Winocour SJ, Hanson SE, Chu CK. Fat grafting in breast reconstruction. *Semin Plast Surg*. 2020;34:17-23. DOI PubMed PMC
20. Cogliandro A, Barone M, Tenna S, Morelli Coppola M, Persichetti P. The role of lipofilling after breast reconstruction: evaluation of outcomes and patient satisfaction with BREAST-Q. *Aesthetic Plast Surg*. 2017;41:1325-31. DOI PubMed
21. Zeltzer AA, Tonnard PL, Verpaele AM. Sharp-needle intradermal fat grafting (SNIF). *Aesthet Surg J*. 2012;32:554-61. DOI PubMed
22. Carraway JH. Commentary on: sharp-needle intradermal fat grafting (SNIF). *Aesthet Surg J*. 2012;32:562-3. DOI PubMed
23. Delay E, Streit L, Toussoun G, La Marca S, Ho Quoc C. Lipomodelling: an important advance in breast surgery. *Acta Chir Plast*. 2013;55:34-43. PubMed
24. Pozzi M, Marcaccini G, Giardino FR, et al. Flowchart in post-bariatric surgery: a research for the appropriate type and timing of plasties reshaping the body. *Aesthetic Plast Surg*. 2024;48:1790-6. DOI PubMed
25. Susini P, Marcaccini G, Giardino FR, et al. Selective capsulotomies and partial capsulectomy in implant-based breast reconstruction revision surgery. *Breast J*. 2024;2024:9097040. DOI PubMed PMC
26. Bonomi R, Betal D, Rapisarda IF, Kalra L, Sajid MS, Johri A. Role of lipomodelling in improving aesthetic outcomes in patients undergoing immediate and delayed reconstructive breast surgery. *Eur J Surg Oncol*. 2013;39:1039-45. DOI PubMed
27. Giardino FR, Cuomo R, Pozzi M, et al. Erdheim-Chester disease of the breast: first review and first case of isolated severe gynecomastia. *Diagnostics*. 2023;13:1239. DOI PubMed PMC
28. Domenici L, Caputo GG, Losco L, et al. Muscle-sparing skin-reducing breast reconstruction with pre-pectoral implants in breast cancer patients: long-term assessment of patients' satisfaction and quality of life. *J Invest Surg*. 2022;35:841-7. DOI PubMed
29. Delay E, Garson S, Toussoun G, Sinna R. Fat injection to the breast: technique, results, and indications based on 880 procedures over 10 years. *Aesthet Surg J*. 2009;29:360-76. DOI PubMed
30. Losco L, Cigna E. Aesthetic refinements in C-V flap: raising a perfect cylinder. *Aesthet Surg J*. 2018;38:NP26-8. DOI PubMed

31. Qari S, Bader M, Farran E, Borrah R, Khamis S, Alharbi Z. Combined synergetic effect of lipoconcentrate fat grafting, nanofat transfer, platelet-rich plasma, microneedling, and CO2 fractional laser for plastic regenerative and esthetic surgery and cosmetic care. *Cureus*. 2023;15:e44035. DOI PubMed PMC
32. Garza RM, Paik KJ, Chung MT, et al. Studies in fat grafting: Part III. Fat grafting irradiated tissue--improved skin quality and decreased fat graft retention. *Plast Reconstr Surg*. 2014;134:249-57. DOI PubMed PMC
33. Cao Z, Li H, Wang ZH, Liang XQ. High-density fat grafting assisted stromal vascular fraction gel in facial deformities. *J Craniofac Surg*. 2022;33:108-11. DOI PubMed PMC
34. Pozzi M, Patanè L, Redi U, et al. Managing the animation deformity in breast reconstruction transposing the implant to a partial prepectoral pocket: early experience and preliminary results with a new technique. *J Plast Reconstr Aesthet Surg*. 2023;86:139-45. DOI PubMed
35. Gentile P, Bernini M, Orzalesi L, et al. Titanium-coated polypropylene mesh as innovative bioactive material in conservatives mastectomies and pre-pectoral breast reconstruction. *Bioact Mater*. 2021;6:4640-53. DOI PubMed PMC
36. Gentile P, Cervelli V. Systematic review: oncological safety of reconstruction with fat grafting in breast cancer outcomes. *J Plast Reconstr Aesthet Surg*. 2022;75:4160-8. DOI PubMed
37. Seth I, Bulloch G, Gibson D, et al. Autologous fat grafting in breast augmentation: a systematic review highlighting the need for clinical caution. *Plast Reconstr Surg*. 2024;153:527e-38. DOI PubMed