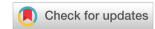

Review

Open Access



# Median and ulnar neuropathy after distal radius fractures: a narrative review and illustrative case presentation

Hugo F. den Boogert<sup>1</sup>, Teun P. Saltzherr<sup>2</sup>, Jaap L.P. van Vliet<sup>2</sup>, Michel Wesstein<sup>3</sup>, Godard C.W. de Ruiter<sup>1</sup>

<sup>1</sup>Department of Neurosurgery, Haaglanden Medical Center, The Hague 2512 VA, The Netherlands.

<sup>2</sup>Department of Traumasurgery, Haaglanden Medical Center, The Hague 2512 VA, The Netherlands.

<sup>3</sup>Department of Clinical Neurophysiology, Haaglanden Medical Center, The Hague 2512 VA, The Netherlands.

**Correspondence to:** Dr. Hugo F. den Boogert, Department of Neurosurgery, Haaglanden Medical Center, Lijnbaan 32, The Hague 2512 VA, The Netherlands. E-mail: h.den.boogert@haaglandenmc.nl

**How to cite this article:** den Boogert HF, Saltzherr TP, van Vliet JLP, Wesstein M, de Ruiter GCW. Median and ulnar neuropathy after distal radius fractures: a narrative review and illustrative case presentation. *Plast Aesthet Res.* 2025;12:3. <https://dx.doi.org/10.20517/2347-9264.2024.84>

**Received:** 15 Jun 2024 **First Decision:** 3 Jan 2025 **Revised:** 10 Feb 2025 **Accepted:** 24 Feb 2025 **Published:** 28 Feb 2025

**Academic Editor:** Warren Matthew Rozen **Copy Editor:** Ting-Ting Hu **Production Editor:** Ting-Ting Hu

## Abstract

Distal radius fractures (DRFs) are very common fractures and can result in additional nerve injuries. Median nerve lesions occur more frequently than ulnar nerve injuries, with reported incidences ranging from 0.2% to 32%. Studies on ulnar nerve injuries are limited to case reports or very small case series. Dorsal angulated fractures, open fractures, and high-impact injuries are particularly associated with a high risk of nerve injuries. The optimal management and timing of treatment for patients with nerve pathology following DRF remain unclear. Clinically distinguishing between the various types and causes of nerve injuries in the acute phase can be very challenging, making close monitoring of these patients crucial. To provide a current overview of this important issue, we reviewed the literature regarding median and ulnar nerve injuries secondary to DRFs, with a special focus on treatment strategies and timing. In addition, an illustrative case of ulnar nerve injury after a DRF is presented. In this case, the ulnar nerve was translocated between the fractured parts of the distal radius. Surgical exploration and relocation of the nerve, along with fracture stabilization 8 days after the trauma, resulted in improved sensorimotor function at a 16-month follow-up.

**Keywords:** Distal radius fracture, nerve injury, median nerve, ulnar nerve, neuropathy, treatment strategy



© The Author(s) 2025. **Open Access** This article is licensed under a Creative Commons Attribution 4.0 International License (<https://creativecommons.org/licenses/by/4.0/>), which permits unrestricted use, sharing, adaptation, distribution and reproduction in any medium or format, for any purpose, even commercially, as long as you give appropriate credit to the original author(s) and the source, provide a link to the Creative Commons license, and indicate if changes were made.



## INTRODUCTION

Fractures of the distal radius are one of the most common fractures encountered in the Emergency Department, accounting for one-sixth of all fractures<sup>[1,2]</sup>. Although the majority of patients are still treated conservatively, recent large population studies show an increase in the surgical management of these fractures, with surgical rates varying between 15% and 20%<sup>[1,3-5]</sup>. Distal radius fractures (DRFs), whether treated conservatively or operatively, can lead to complications such as tendon ruptures, tendosynovitis, malunion, compartment syndrome, complex regional pain syndrome, wound infection, and nerve injury<sup>[6,7]</sup>. Notably, median nerve palsy is frequently observed following DRF, with reported incidences of 0.2%-32%<sup>[8-11]</sup>. In contrast, ulnar nerve injuries are rare, typically described only in case reports<sup>[12-23]</sup>. Even less frequent is damage to the superficial radial nerve, which only occurs after surgical treatment of the fracture<sup>[24]</sup>. Median or ulnar neuropathy after DRF can result from direct trauma, displacement of fractured bone fragments, subsequent compartment syndrome, cast immobilization, or iatrogenic causes following surgical stabilization. If a complete nerve transection (neurotmesis) is suspected immediately after injury, urgent surgical intervention is required to repair the nerve. More often, the nerve is contused or stretched, resulting in transient neuropathy (neurapraxia) or more severe injury (axonotmesis).

Differentiating between these types of nerve injury in the acute phase can be challenging, as neurological examination and diagnostic tests (e.g., ultrasound) are often limited by pain, swelling, or cast immobilization. This complicates the decision-making process regarding whether and when surgical exploration is necessary, potentially delaying proper treatment and reducing the chances of neurological recovery. Furthermore, international guidelines on the (surgical) management of these pathologies are lacking<sup>[25,26]</sup>, leading to differences in treatment strategies among surgeons<sup>[27]</sup>.

To provide an overview of current standards in the management of median and ulnar nerve injuries secondary to DRF, we reviewed the literature with an emphasis on surgical treatment strategies and the optimal timing for intervention when neurapraxia or axonotmesis is suspected. Additionally, we present a novel illustrative case highlighting the importance of early surgical treatment.

## METHODS

A PubMed search was conducted using the terms “ulnar nerve injury”, “median nerve injury”, “distal radius fractures”, and their synonyms. Clinical studies reporting on outcomes after surgical or conservative treatment of ulnar or median nerve injuries following DRFs were included in this narrative review. Only studies describing neurapraxia or axonotmesis were included; articles reporting complete nerve transection, which always requires urgent surgical treatment, were excluded. Additionally, studies in languages other than English or Dutch, or those lacking full-text availability, were excluded. Given the relatively uncommon nature of this complication, no publication year limit was applied, provided the aforementioned inclusion criteria were met.

## EPIDEMIOLOGICAL AND ANATOMICAL CONSIDERATIONS

The first mention of nerve injury after a dorsally displaced and angulated distal radius fracture (Colles' fracture) dates back to 1836, when an autopsy revealed that the median nerve had been severed between the fracture fragments<sup>[28]</sup>. Over the following decades, the incidence of median nerve injury after DRF has varied between 0.2% and 21.3%<sup>[10]</sup>. More recently, a retrospective study involving 220 patients even reported an incidence of median neuropathy after DRF as high as 32%<sup>[11]</sup>. In a comprehensive review of all possible nerve injuries associated with DRF, Cooney *et al.* retrospectively analyzed 565 patients with DRF and found compression neuropathy in 7.9% of cases; early median neuropathy was observed in 31 patients (5.5%), ulnar neuropathy in 6 patients (1.1%), and radial neuropathy in 5 patients (0.9%). According to the authors,

the latter two cases were attributed to improper cast immobilization or irritation from external pin fixation<sup>[9]</sup>. In 2006, Bienek *et al.* reported symptoms of median nerve compression in 12 of 60 patients with DRF (20%), which were confirmed by electrodiagnostic investigations indicative of ulnar or radial nerve injury<sup>[8]</sup>. This aligns with the broader literature, where ulnar nerve injury has been described only in case reports to date<sup>[12-23]</sup>.

Several anatomical factors may account for the differences in the occurrence of these injuries. Vance and Gelberman reported that the median and ulnar nerves were located at the same distance (3 mm) from the distal radius in five specimens, even after osteotomizing the radius to stimulate a displaced DRF, (in this case, the distance between the nerves and the fracture site decreased to < 2 mm)<sup>[22]</sup>. However, the median nerve is more firmly bound along a longer distance by the carpal tunnel than the ulnar nerve is within Guyon's canal, which is shorter and more distant from the distal radius, suggesting that the ulnar nerve may experience greater excursion at the injury site. This theory, however, is somewhat contested by cadaver studies of non-fractured specimens, which show that the median nerve exhibits a total excursion of 19.6 mm when the wrist moves from 60 degrees of extension to 65 degrees of flexion, compared to 13.6 mm for the ulnar nerve<sup>[29,30]</sup>. The ulnar nerve appears to be more mobile in the forearm than the median nerve, allowing the ulnar nerve to potentially 'bend' more at the fracture site, particularly in cases of severely displaced DRF<sup>[14]</sup>.

After reviewing the literature, distinct differences and some similarities were found between median and ulnar nerve injuries following DRFs in terms of pathophysiology, classification, and treatment strategies.

## MEDIAN NERVE INJURY

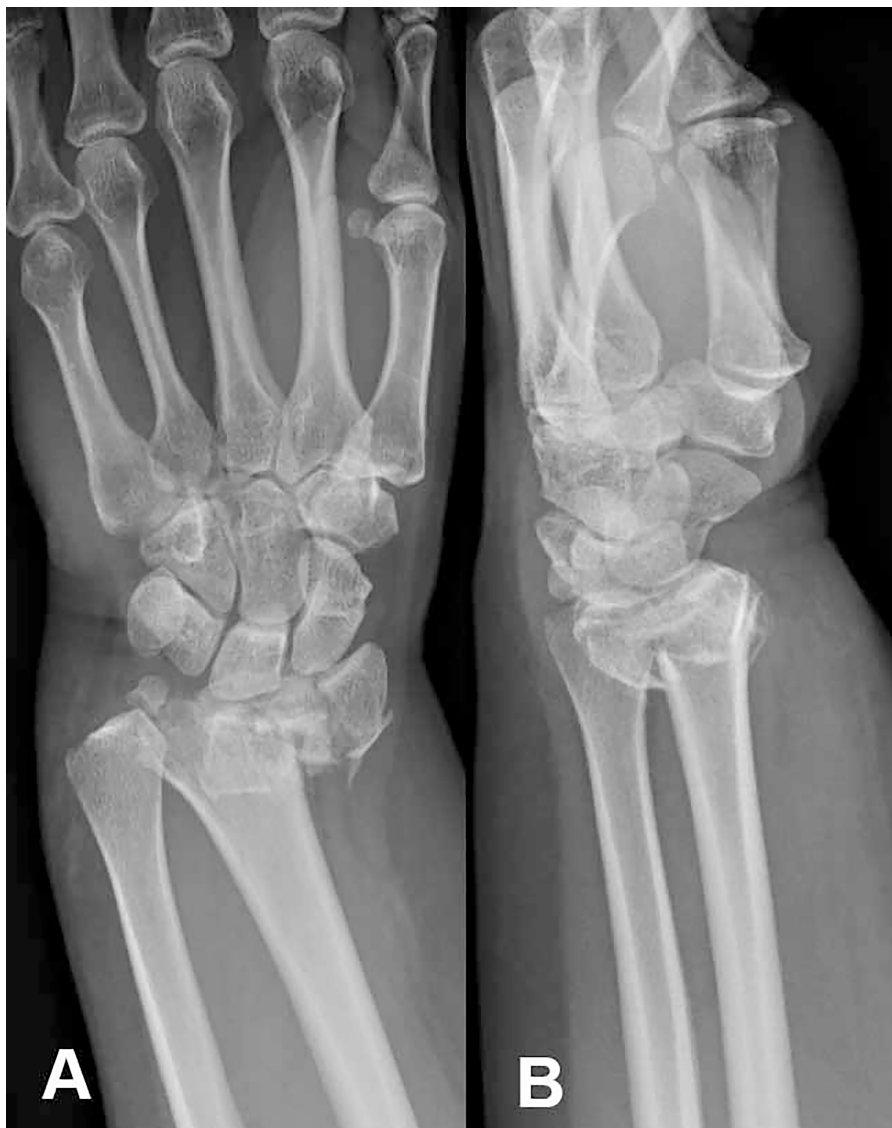Median nerve injury after wrist trauma can be classified based on the underlying cause, type of injury, or onset of symptoms. In the acute phase, median nerve neurapraxia or axonotmesis may result from stretching or contusion of the nerve proximal to the carpal tunnel due to fracture dislocation or hematoma formation<sup>[31,32]</sup>. In rare cases, complete neurotmesis can also occur<sup>[33,34]</sup>. Dislocation of the fracture, edema, or post-traumatic hemorrhage can lead to a rapid increase in pressure within the carpal tunnel, resulting in acute carpal tunnel syndrome (ACTS)<sup>[32,35]</sup>. Additionally, local anesthetic injections for repositioning or cast immobilization in extensive flexion have been reported to cause ACTS<sup>[36-38]</sup>. The carpal tunnel is a relatively enclosed space, bounded by the carpal bones and the transverse ligament, and contains, in addition to the median nerve, nine tendons. Its volume is generally constant at around 5 mL, with a normal resting compartment pressure of 2.5 mmHg. When the pressure rises to 30 mmHg, epineural blood flow is reduced, and prolonged high pressure can result in neural damage and severe sensorimotor deficits<sup>[37,39]</sup>. Fracture translation is an important predictor for the development of ACTS<sup>[40]</sup>, whereas intra-articular fractures and high-energy impact are significantly more common in the ACTS group than in the subacute or chronic carpal tunnel syndrome (CTS) group<sup>[41]</sup>.

Both ACTS and median nerve neurapraxia are a result of acute injury to the median nerve, leading to immediate symptoms. However, the key difference lies in the progressive nature of ACTS, which is often associated with painful paresthesia in the median nerve distribution of the hand due to increasing pressure in the carpal tunnel, necessitating urgent surgical release. On the contrary, median neurapraxia symptoms are non-progressive and can resolve gradually over time with conservative treatment<sup>[32]</sup>. This condition is sometimes referred to as subacute or transient CTS, sharing clinical similarities with delayed CTS in terms of patient population<sup>[38,41]</sup>. Reported incidences of ACTS after DRF vary between 5.4% and 8.6%, compared to 4% for transient CTS. Delayed, chronic CTS occurs in 0.5% to 22% of cases following DRF and can present months or even years after the trauma due to malunion, callus formation, or tenosynovitis<sup>[9,42,43]</sup>. Lastly, it is important to note that the trauma can exacerbate pre-existing (idiopathic) CTS.

## ULNAR NERVE INJURY

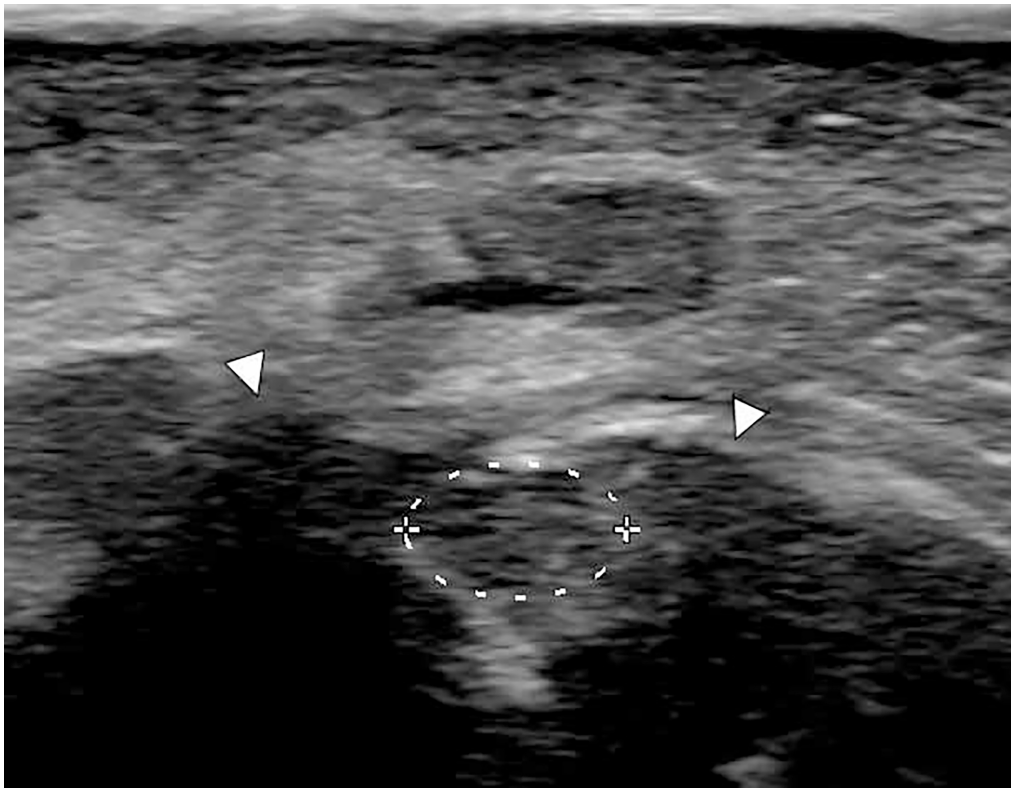
### Illustrative case of ulnar nerve injury

A 47-year-old right-handed female, with no relevant history, presented to the emergency department of another hospital after a fall from bicycle, during which she extended her left hand to break the fall. She complained of severe wrist pain and apparent deformity, in addition to experiencing a tingling sensation in her little and ring fingers. Radiographs revealed a comminuted distal radius fracture with dorsal angulation [Figure 1]. After closed reduction, her neurological symptoms worsened, and she developed complete numbness in the ulnar nerve distribution distal to the wrist. Because her wrist was immobilized with a plaster cast, her strength could not be accurately assessed. Six days after the accident, the patient was referred to our hospital, where she was seen in the outpatient clinic. She reported persisting numbness in the fourth and fifth digits and weakness in the intrinsic hand muscles [medical research council scale

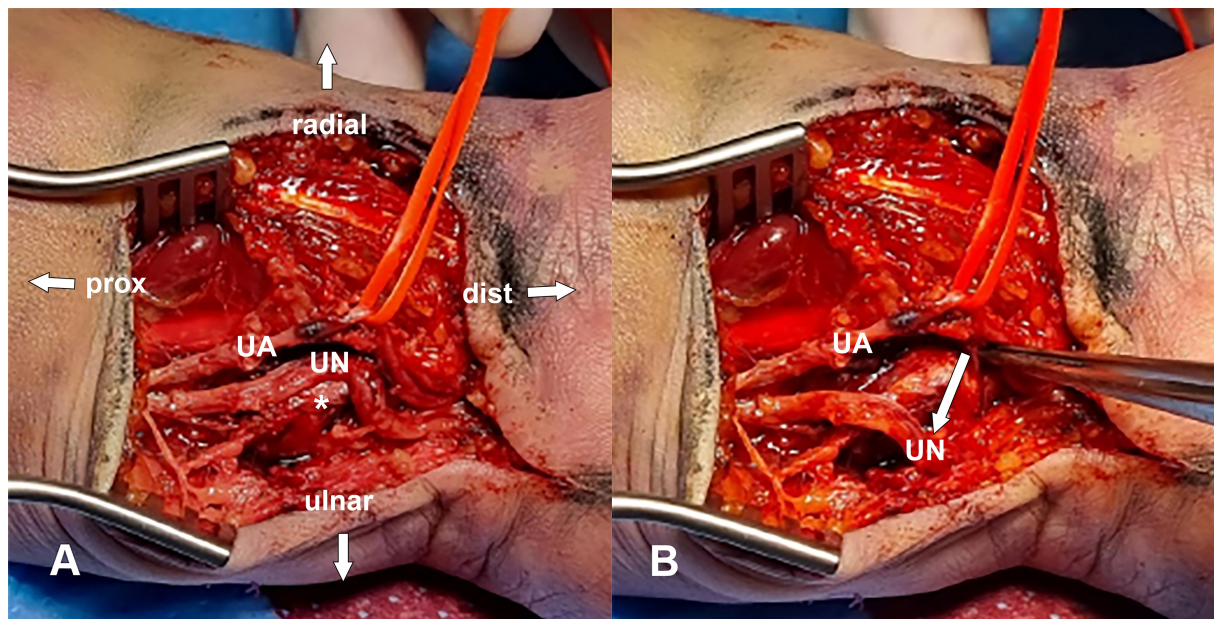


**Figure 1.** Posterolateral (A) and lateral radiograph (B) of a closed distal radius fracture with volar dislocation.





**Figure 2.** Transverse ultrasound image of the wrist, showing the ulnar nerve prior to surgery. The nerve is swollen (dashed line) with signs of intraneural edema, lying between the two fractured parts of the distal radius (arrowheads).



**Figure 3.** The distal radius. Intraoperative images showing the ulnar nerve entrapped between the volarly displaced fractured parts of the distal radius. (A) shows the pre-reduction state, where the UN is abnormally displaced by a fractured part of the distal radius. A red loop is placed around the UA for identification; (B) shows the UN repositioned to its anatomical position on the ulnar side (indicated by the white arrow). The nerve exhibited signs of interfascicular hematoma. After repositioning, the fracture was stabilized with a volar plate (not shown). UN: Ulnar nerve; UA: ulnar artery.

(MRC) grade 3]. The plaster cast was removed a day after to conduct an ultrasound, revealing that the nerve was in continuity, but exhibited a caliber change. It was positioned between the fractured parts with signs of intraneural edema [Figure 2]. Given these ultrasound findings and the absence of any neurological improvement, a joint surgery was planned with the trauma surgeon to explore and reposition the nerve, and fixate the fracture. The surgery, performed 8 days after the accident, involved an S-curved volar approach to expose both the distal radius radially and the ulnar nerve medially. Intraoperatively, it was found that the ulnar nerve had been severely displaced by the dorsoradial dislocation of the comminuted radius fracture, lying behind the volar rim of the intermediate column of the distal radius [Figure 3]. Approximately 1 cm of the nerve was crushed, with interfascicular hematoma present. Due to the incomplete nature of the sensorimotor deficits and the relatively small size of the nerve lesion, resection and grafting were not deemed necessary and a neurolysis was performed. The nerve was carefully relocated back from the fractured parts to its normal anatomical position [Figure 3B], and Guyon's canal was opened distally. The fracture was then stabilized using a volar plate. Postoperatively, the patient's ulnar nerve function improved gradually. She was referred to a specialized hand and wrist rehabilitation center for targeted training and ongoing recovery monitoring. Over the weeks following the surgery, the patient reported improved motor and sensory function in her left hand, with no further paresthesia or pain in the ulnar distribution. Sensory testing in the ulnar region of the hand using the Semmes-Weinstein monofilament test showed slight abnormality (threshold: 0.7 grams; normal: 0.2 grams). At the last outpatient follow-up, 16 months postoperatively, she had achieved full functional recovery. Strength measurements using a Jamar hand dynamometer showed improvements in her left hand: grip strength increased from 22.8 kg (24 weeks post-op) to 30.4 kg (16 months post-op), and lateral pinch strength increased from 5.9 to 6.8 kg. However, her strength remained lower than on the right side, as might be expected for a right-handed individual (right hand: grip 40 kg, lateral pinch 8.4 kg).

### Literature review

Compared to median nerve palsy after DRF, literature on ulnar nerve injury is scarce and mostly limited to case reports or very small case series [Table 1]. A total of 23 cases from 13 case reports (including the current article) demonstrate substantial variation in symptom progression, treatment strategies, and surgical timing. The majority of patients were adults, with only one pediatric case reported. Most fractures were comminuted DRFs, with ulnar involvement observed in 12 patients (52%), typically affecting the ulnar styloid process. In 10 studies (14 patients, 63%), ulnar nerve injury symptoms were present immediately after trauma<sup>[12,13,15-19,21-23]</sup>. In three cases from the same study, symptoms appeared later: one patient developed symptoms after 1 week, another after 3 weeks, and a third after 8 weeks<sup>[14]</sup>. Soong *et al.* described five cases with complete sensorimotor deficits before surgery, but the exact onset was not further specified. In three patients, additional CTS symptoms occurred within 72 h of injury<sup>[20]</sup>. Hypesthesia or paresthesia in the ulnar distribution of the hand was the most common presenting symptom, reported in 22 patients (96%). Among them, 11 patients (48%) also exhibited weakness in ulnar-innervated hand muscles at presentation. In most cases, symptoms progressed gradually, starting with sensory disturbances in the fourth and fifth digits, followed by mild motor deficits, and, in some cases, evolving into complete ulnar palsy with claw hand deformity. Only one case first presented with motor deficits without sensory disturbances<sup>[14]</sup>. Surgical intervention was performed in 21 cases (91%), typically involving extensive neurolysis to release fibrous scar tissue, and in some cases, repositioning of a displaced ulnar nerve. In most of the cases, this was done secondary to additional surgical fracture management, when after an initial period of casting and/or stabilization with K-wires or external fixators, internal fixation and volar plating were indicated. DRFs were managed conservatively in three cases<sup>[12,17,22]</sup>, with 1 patient undergoing surgery for ulnar nerve palsy more than 3 months post-injury<sup>[12]</sup>. In the other two cases, both the fracture and ulnar neuropathy were treated conservatively<sup>[17,22]</sup>. The timing of surgical treatment varied, ranging from immediately after trauma to 9 months post-injury. In some cases<sup>[18,21]</sup>, ulnar nerve symptoms worsened after initial fracture reduction. One

**Table 1. Ulnar nerve injuries after DRF**

Author, year, No. of patients	Type(s) of fracture(s)	Onset of neurological symptoms	Treatment strategy	Timing of surgery for ulnar nerve palsy	Follow-up after surgery	Outcome
Poppi <i>et al.</i> , 1978 <sup>[12]</sup> 1 adult patient	DRF and slight dislocation of the distal radio-ulnar joint (Galeazzi's fracture)	Immediately after trauma: hypesthesia/paresthesia in the fourth and fifth digits and "clawing" Gradually progressive symptoms	Fracture: conservative treatment with reduction and casting Nerve: exploration at the wrist and neurolysis, contused nerve	> 3 months, not further specified	2 months	Partial: normal sensation and no clawing. Only mild atrophy in intrinsic muscles
Vance <i>et al.</i> , 1978 <sup>[22]</sup> 3 adult patients	C1: comminuted DRF and ulnar styloid proc C2: DRF and ulna fracture with dislocation C3: DRF with moderate dislocation	Immediately after trauma: both sensory and motor deficits (all cases)	C1: Conservative treatment C2: Open reduction, exploration of ulnar nerve (tethered around ulna), decompression of Guyon's canal C3: Decompression and internal neurolysis, resection distal ulna. Second neurolysis 14 months after injury	C1: NA C2: Immediately after closed reduction C3: 5 months; 14 months second surgery	C2: 4 months C3: 3 years	C1: Complete recovery C2: Partial: normal sensation, strength 75% of normal C3: No recovery, also after second surgery: persisting pain and poor hand function
Clarke <i>et al.</i> , 1991 <sup>[14]</sup> 3 adult patients	C1: open DRF and ulnar styloid proc C2: displaced Colles' fracture C3: displaced DRF	C1: 8 weeks: motor deficits first C2: 3 weeks: paresthesia, later clawing C3: 1 week: numbness All cases reported slowly progressive symptoms	C1: Neurolysis from scar tissue, internal fixation of nonunion radial styloid proc C2: Neurolysis from dense fibrous tissue C3: Replacement of displaced ulnar nerve at DRU joint, joint stabilization	C1: 3 months after injury C2: 3 months after injury C3: 8 weeks after injury	3 months	C1: Complete recovery C2: Partial: full motor recovery, slight loss of sensation C3: Complete recovery
Lu <i>et al.</i> , 2007 <sup>[17]</sup> 1 pediatric patient (14 yrs)	DRF (Salter-Harris type 2) with dorsal displacement and fractured ulnar styloid proc with volar protrusion of the distal ulna	Immediately after trauma: decreased sensation and weakness ab- and adduction of the fourth and fifth digits Slowly progressive symptoms	Conservative treatment with close observation and rehabilitation treatment	NA	16 weeks	Complete recovery
Soong <i>et al.</i> , 2007 <sup>[20]</sup> 5 adult patients	All fractures were dorsally displaced DRF, two were open fractures. Three also had ulnar fractures	Not clearly stated; Complete ulnar motor and sensory deficit before operative treatment of the fracture, and in 3 cases, additional CTS developed < 72 h after injury	Fracture: All patients had operative treatment for the fractures 3 patients had additional ulnar nerve exploration, release and CTR. In 1 patient, the ulnar nerve was trapped in DRF 2 patients treated conservatively for ulnar nerve injury	Not specified	Surgical: 6, 12 and 31 months Conservative: 14 and 22 months	Surgical group: all complete recovery Conservative group: 1 patient partial recovery: persisting intrinsic motor weakness (22 months of FU) 1 patient complete recovery (14 months of FU)
Sohal <i>et al.</i> , 2009 <sup>[19]</sup> 1 adult patient	Closed, extraarticular, displaced, DRF	Immediately after trauma: Numbness and loss of strength in first dorsal interossei Persisting symptoms	Fracture: first conservative treatment with reduction and casting, later K-wires Nerve: first observation, later exploration, replacement of dorsal deviated ulnar nerve and neurolysis from scar tissue	2 months and 8 days after injury	1 year	Partial recovery: mild tingling in tip fifth digit, improved strength
Cho <i>et al.</i> , 2010 <sup>[13]</sup> 2 adult patients	C1: I intra-articular comminuted DRF with posterolateral displacement and fractured ulnar styloid proc C2: intra-articular comminuted	Immediately after trauma: hypesthesia in the fourth and fifth digits, later motor deficits with claw hand deformity (both cases) Progressive symptoms	C1: Fracture: closed reduction, K-wires and external fixator Nerve: first observation, later exploration, and decompression of fibrous tissue in Guyon's canal	C1: 12 weeks and 2 days after injury C2: 8 weeks and 1 day	C1: 3 months C2: 1 year	C1: Complete recovery C2: Partial: minor numbness in the fourth and fifth digits, claw hand deformity resolved

	DRF with fractured ulnar styloid proc		C2: Fracture: open reduction, external fixator Nerve: observation, later exploration, decompression adhesions			
de Ruiter <i>et al.</i> , 2016 <sup>[16]</sup> 1 adult patient	Closed, extraarticular, displaced DRF and fractured ulnar styloid proc	Immediately after trauma: tingling sensation in the fourth and fifth digits. Testing of motor function was not reliable due to severe pain	Fracture: closed reduction, external fixator, later K-wire due to recurrent dislocation. Definitive internal fixation with a plate Nerve: exploration, ulnar nerve rotated around the ulnar head. Opening distal-radial ulnar joint and relocation ulnar nerve	9 months	9 months	Partial: full recovery of motor function, sensation slightly decreased and synkinesis of all fingers
Pogetti <i>et al.</i> , 2020 <sup>[18]</sup> 1 adult patient	Extraarticular DRF with dorsal and radial displacement	Immediately after trauma: paresthesia in the fourth and fifth digits, intrinsic hand muscles (MRC 3) Progressive symptoms after reduction	Fracture: K-wires and external fixator, later volar plating Nerve: exploration: encased in scar tissue and kinked/stuck between fracture fragments. Subtotal neurotmesis, primary coaptation by epineural sutures	10 days after injury	6 months	Partial: normal sensation, intrinsic hand muscle strength (MRC 4)
Yang <i>et al.</i> , 2021 <sup>[23]</sup> 2 adult patients	Closed DRF with dorsolateral displacement and fractured ulnar styloid proc (both cases)	Immediately after trauma: mild hypesthesia in the fourth and fifth digits Slowly progressive symptoms	Fractures: open reduction and volar plating Nerves: exploration, decompression, and neurolysis	C1: 6 days after injury C2: 10 weeks and 2 days after injury	C1: 4 weeks C2: 6 weeks	C1: Complete recovery C2: Partial: normal sensation, residual claw hand deformity
Tsujino <i>et al.</i> , 2022 <sup>[21]</sup> 1 adult patient	Closed DRF and ulna fracture with dorsoradial displacement	Immediately after trauma: slight numbness in the fourth and fifth digits Progressive after reduction with motor deficits	Fracture: open reduction and plating Nerve: exploration, ulnar nerve and artery were displaced by fractured radius, release of ulnar nerve/artery	3 days after injury	1 year	Partial: complete recovery of sensation, slight weakness remained
Feng <i>et al.</i> , 2023 <sup>[15]</sup> 1 adult patient	Closed, displaced DRF	Immediately after trauma: dysesthesia in all digits, weakness in the second and third interossei, FDS and EDC Post reduction improvement of median nerve symptoms. Persisting ulnar nerve symptoms	Fracture: first observation, later open reduction and plating of fracture Nerve: CTR, repositioning dorsoulnar translocated ulnar nerve	10 days after injury	1 year	Complete recovery
This article, 2024 1 adult patient	Closed, comminuted, displaced DRF	Immediate after trauma: paresthesia in the fourth and fifth digits, later weakness in intrinsic hand muscles (MRC 3) Progressive after closed reduction	Fracture: open reduction and volar plating Nerve: exploration, repositioning nerve from dislocation between the fracture parts, opening Guyon's canal	8 days after injury	16 months	Partial: functional full recovery Slight loss of sensation, improved strength measured by hand dynamometer

proc: Process; CTS: carpal tunnel syndrome; CTR: carpal tunnel release; MRC: medical research council scale; FDS: flexor digitorum superficialis; EDC: extensor digitorum communis; FU: follow-up; DRF: distal radius fractures; DRU: distal radioulnar; C1: case 1; C2: case 2; C3: case 3; NA: not applicable.

case report described symptom improvement after repositioning the wrist to its initial state, followed by surgery 3 days later after nerve conduction studies and ultrasound ruled out nerve laceration<sup>[21]</sup>. Two other patients experienced worsening symptoms after closed reduction or temporary stabilization with K-wires and external fixation and subsequently underwent surgery at 8 days (this study) and 10 days<sup>[18]</sup> after trauma, respectively. At follow-up, all these patients exhibited mild residual deficits.



Among the 23 reported cases, 11 patients achieved full recovery of sensory and motor function, with follow-up durations ranging from 4 weeks to 31 months post-surgery. Partial recovery, characterized by persistent mild sensory or intrinsic hand muscle weakness, was reported in another 11 patients. One patient, however, experienced persistent pain and poor hand function despite undergoing a second neurolysis 14 months post-injury<sup>[22]</sup>.

## TREATMENT STRATEGY AND TIMING

The optimal treatment and timing for median or ulnar nerve injuries following DRF remain unclear. The 2010 Guidelines on DRF management did not provide a definitive recommendation for or against nerve decompression in cases of nerve injury. More recent guidelines, including those from the American Academy of Orthopaedic Surgeons (AOSS) in 2020<sup>[26,44]</sup> and the Dutch guidelines in 2021<sup>[45]</sup>, do not mention nerve dysfunction after DRF at all. Furthermore, robust comparative trials on the (surgical) management of median and ulnar nerve injuries after DRF are lacking. Several factors may contribute to this gap in research:

- (1) The acute nature of DRF, which is typically associated with significant pain, can mask underlying neurological symptoms or (wrongfully) make them seem less relevant in the acute and subacute phases;
- (2) The difficulty in distinguishing between acute CTS and median nerve neurapraxia in the acute phase;
- (3) The rarity of ulnar nerve pathology following DRF, and thereby potential unawareness among clinicians.

A 2019 survey of 101 U.S. surgeons and 26 Dutch surgeons highlighted how this lack of evidence contributes to variations in clinical practice. More U.S. surgeons reported experience treating patients with displaced DRF and preoperative acute CTS compared to their Dutch counterparts (98% *vs.* 85%,  $P = 0.016$ ). However, significantly fewer U.S. surgeons considered persistent paresthesia after closed reduction to be a surgical emergency compared to their Dutch colleagues (22% *vs.* 50%,  $P = 0.007$ ). Additionally, only 8% of U.S. surgeons - and none of the Dutch surgeons - reported having guidelines to identify patients at risk for developing CTS after DRF<sup>[27]</sup>. Despite the diagnostic challenges in the acute phase, differentiating between acute CTS and median nerve neurapraxia is crucial<sup>[32,39]</sup>. Acute CTS is characterized by increasing pain and rapidly progressive sensory deficits after trauma, and requires urgent decompression to avoid irreversible nerve damage due to increasing pressure in the carpal tunnel. In contrast, non-progressive sensory deficits that appear immediately after trauma suggest neurapraxia, which typically resolves without surgical intervention. Additionally, although rare, forearm compartment syndrome is associated with DRF and can present with the same symptoms but necessitate a completely different surgical approach<sup>[46]</sup>.

Beyond the question of whether surgical treatment for nerve injury after DRF is necessary, the timing of intervention also remains unclear. Samuel *et al.* evaluated 35 patients who underwent carpal tunnel release and wrist fracture stabilization (not only DRF) within 48 h, and reported high levels of satisfaction along with improved pain relief and hand function after a mean follow-up of 24 months. Although the study lacked a control group and did not establish a statistical relationship between surgical timing and functional outcomes, the authors advise surgical treatment within 36 h (instead of 48 h) after symptom onset<sup>[47]</sup>. Other studies also advocate for nerve decompression 'as soon as possible' in the case of ACTS<sup>[10,32,39,43,48,49]</sup>. There seems to be a broader consensus on the obsolete role of prophylactic median nerve decompression during fracture surgery<sup>[27,38]</sup>. In a study of 69 patients without preoperative CTS, 24 underwent prophylactic median nerve decompression during fracture treatment, but they showed no benefit compared to those who did not receive decompression. Notably, although the difference was not statistically significant, the risk of developing new CTS symptoms was twice as high in patients who underwent neurolysis compared to those who did not receive decompression<sup>[50]</sup>. In contrast to median nerve pathology, there are no established

guidelines or case series on the surgical management and optimal timing of surgery for ulnar nerve injuries after DRF. This makes decision making in such cases much more difficult. This is even more the case when median and ulnar nerve injuries occur simultaneously.<sup>[20,51]</sup>

### **Treatment strategy proposal**

The lack of large-scale studies on the timing of surgical intervention, the heterogeneity of clinical data, and the lack of standardized outcome measures make it challenging to provide definite treatment recommendations. Based on our experience and findings from the literature, surgical exploration is indicated when neurological deficits are not likely to improve over time, regardless of whether additional fracture stabilization is required. For patients with signs of neuropathy and requiring early open surgical stabilization of the fracture, we would recommend that trauma or orthopedic surgeons consult a peripheral nerve surgeon. This allows the nerve surgeon to attend the procedure and assess the nerve intraoperatively. Although ultrasound has certain limitations in the acute phase following DRF, we believe it can be a valuable adjunct to detect potential nerve continuity disruption intraneural edema, hematoma, or nerve dislocation. Temporally removing the plaster cast may improve ultrasound imaging quality and aid in the decision-making process. However, it is important to realize that nerve continuity is often preserved, which, as our case shows, should not be a reason to forgo surgical exploration.

### **CONCLUSION**

Ulnar nerve lesions after DRFs are less common compared to median nerve injuries. However, clinicians should be aware that such injuries can occur. The literature reports several causes, classifications, and predictors of nerve injury after DRFs; however, optimal treatment strategies and timing for intervention remain unclear. ACTS, characterized by rapidly progressive median nerve symptoms after trauma, requires urgent decompression. It is therefore important to distinguish it from median nerve neurapraxia, which can often be treated conservatively. Our overview suggests that surgical treatment for ulnar nerve injury after DRF can result in good functional recovery, even when performed at a later stage. Nonetheless, we advocate early ultrasound assessment by temporarily removing the cast and prompt exploratory surgery in cases where nerve continuity disruption or compression/dislocation by fracture fragments is suspected. Close collaboration between trauma or orthopedic surgeons and peripheral nerve specialists is important when nerve injury is suspected following a distal radius fracture, in order to ensure appropriate assessment and timely decisions regarding conservative or surgical management.

### **DECLARATIONS**

#### **Authors' contributions**

Made substantial contributions to the conception and design of the study and performed data analysis and interpretation: den Boogert HF, de Ruiter GCW

Reviewed the manuscript, commented, and provided administrative and material support: Saltzherr TP, van Vliet JLP, Wesstein M

#### **Availability of data and materials**

Not applicable.

#### **Financial support and sponsorship**

None.

#### **Conflicts of interest**

de Ruiter G is an Editorial Board member of the journal *Plastic and Aesthetic Research*. de Ruiter G is also a Guest Editor for the Special Issue *Neuropathic Pain after Trauma: Risk Factors and Treatment*. de Ruiter G

was not involved in any steps of editorial processing, notably including reviewer selection, manuscript handling, and decision making. The other authors declared that there are no conflicts of interest.

### Ethical approval and consent to participate

The patient of the illustrative case provided informed consent for the use of her clinical information and operative images in this article. No further ethical approval was required.

### Consent for publication

Not applicable.

### Copyright

© The Author(s) 2025.

## REFERENCES

1. Nellans KW, Kowalski E, Chung KC. The epidemiology of distal radius fractures. *Hand Clin*. 2012;28:113-25. DOI PubMed PMC
2. Chung KC, Spilson SV. The frequency and epidemiology of hand and forearm fractures in the United States. *J Hand Surg Am*. 2001;26:908-915. DOI PubMed
3. Kakar S, Noureldin M, Van Houten HK, Mwangi R, Sangaralingham LR. Trends in the incidence and treatment of distal radius fractures in the United States in privately insured and medicare advantage enrollees. *Hand*. 2022;17:331-8. DOI PubMed PMC
4. Raudasoja L, Aspinen S, Vastamaki H, Ryhanen J, Hulkkonen S. Epidemiology and treatment of distal radius fractures in Finland-A nationwide register study. *J Clin Med*. 2022;11:2851. DOI PubMed PMC
5. Rundgren J, Bojan A, Mellstrand Navarro C, Enocson A. Epidemiology, classification, treatment and mortality of distal radius fractures in adults: an observational study of 23,394 fractures from the national Swedish fracture register. *BMC Musculoskelet Disord*. 2020;21:88. DOI PubMed PMC
6. Ochen Y, Peek J, van der Velde D, et al. Operative vs nonoperative treatment of distal radius fractures in adults: a systematic review and meta-analysis. *JAMA Netw Open*. 2020;3:e203497. DOI PubMed PMC
7. Townsley SH, Pulos N, Shin AY. Complications of operatively treated distal radial fractures. *J Hand Surg Eur Vol*. 2024;49:215-25. DOI PubMed
8. Bienek T, Kusz D, Cielinski L. Peripheral nerve compression neuropathy after fractures of the distal radius. *J Hand Surg Br*. 2006;31:256-60. DOI PubMed
9. 3rd WP, Dobyns JH, Linscheid RL. Complications of Colles' fractures. *J Bone Joint Surg Am*. 1980;62:613-9. PubMed
10. Mack GR, McPherson SA, Lutz RB. Acute median neuropathy after wrist trauma. The role of emergent carpal tunnel release. *Clin Orthop Relat Res*. 1994;300:141-6. PubMed
11. U J, Ethiraj P, M U, H S A. Incidence of carpal tunnel syndrome in distal radius fractures treated by various modalities in a tertiary care center: a single center study. *Cureus*. 2023;15:e35346. DOI PubMed PMC
12. Poppi M, Padovani R, Martinelli P, Pozzati E. Fracture of the distal radius with ulnar nerve palsy. *J Trauma*. 1978;18:278-9. DOI PubMed
13. Cho CH, Kang CH, Jung JH. Ulnar nerve palsy following closed fracture of the distal radius: a report of 2 cases. *Clin Orthop Surg*. 2010;2:55-8. DOI PubMed PMC
14. Clarke AC, Spencer RF. Ulnar nerve palsy following fractures of the distal radius: clinical and anatomical studies. *J Hand Surg Br*. 1991;16:438-40. DOI PubMed
15. Feng JE, Espiritu MGS, Tooley TR, Altman PR. Ulnar nerve translocation following a routine distal radius fracture. *Iowa Orthop J*. 2023;43:185-9. DOI PubMed PMC
16. de Ruiter G.C.W, den Hollander P.H.C.. Ulnar nerve palsy with dislocation of the nerve around the ulna following a fracture of the distal radius. *J Spine Neurosurg*. 2016;5:6. DOI
17. Lu CC, Chuo CY, Chen SK, Huang YH, Chou PH. Ulnar nerve palsy following fracture of the distal radius in an adolescent: a case report. *Kaohsiung J Med Sci*. 2007;23:151-5. DOI PubMed
18. Poggetti A, Nucci AM, Baluganti A, Pfanner S. Jammed ulnar nerve after distal radius fracture: a case report. *JPRAS Open*. 2020;24:20-4. DOI PubMed PMC
19. Sohal JK, Chia B, Catalano LW 3rd. Dorsal displacement of the ulnar nerve after a displaced distal radius fracture: case report. *J Hand Surg Am*. 2009;34:432-5. DOI PubMed
20. Soong M, Ring D. Ulnar nerve palsy associated with fracture of the distal radius. *J Orthop Trauma*. 2007;21:113-6. DOI PubMed
21. Tsujino S, Seki Y, Shirasawa S. Entrapment of the ulnar nerve and artery associated with closed distal radius and ulna fracture: a case report. *JBJS Case Connect*. 2022;12:2. DOI PubMed
22. Vance RM, Gelberman RH. Acute ulnar neuropathy with fractures at the wrist. *J Bone Joint Surg Am*. 1978;60:962-5. DOI PubMed
23. Yang JJ, Qu W, Wu YX, Jiang HJ. Ulnar nerve injury associated with displaced distal radius fracture: two case reports. *World J Clin*

- Cases. 2021;9:6956-63. DOI PubMed PMC
24. Teimouri M, Ghaderi M, Hatami S. Comparing the outcomes of surgical and non-surgical approaches in management of older patients with distal radius fracture; a retrospective cohort study. *Arch Acad Emerg Med.* 2022;10:e62. DOI PubMed PMC
  25. Lichtman DM, Bindra RR, Boyer MI, et al. Treatment of distal radius fractures. *J Am Acad Orthop Surg.* 2010;18:180-9. DOI PubMed
  26. Shapiro LM, Kamal RN; Management of Distal Radius Fractures Work Group; Nonvoting Clinical Contributor; Nonvoting Oversight Chairs; Staff of the American Academy of Orthopaedic Surgeons and the American Society for Surgery of the Hand. Distal radius fracture clinical practice guidelines-updates and clinical implications. *J Hand Surg Am.* 2021;46:807-11. DOI PubMed
  27. Özkan S, Mudgal CS, Evans BT, Watkins CJ, Heng MM, Bloemers FW. Surgical decision-making in median neuropathy associated with distal radius fractures. *J Wrist Surg.* 2019;8:366-73. DOI PubMed PMC
  28. Abbott LC, CM SJD. Injuries of the median nerve in fractures of the lower end of the radius. *Surg Gynecol Obstet* 1933;57:e516. Available from: [https://scholar.google.com/scholar?hl=zh-CN&as\\_sdt=0%2C48&q=Abbott+LC%2C+CM+SJD.+Injuries+of+the+median+nerve+in+fractures+of+the+lower+end+of+the+radius.+Surg+Gynecol+Obstet+1933%3B57%3A517.&btnG=](https://scholar.google.com/scholar?hl=zh-CN&as_sdt=0%2C48&q=Abbott+LC%2C+CM+SJD.+Injuries+of+the+median+nerve+in+fractures+of+the+lower+end+of+the+radius.+Surg+Gynecol+Obstet+1933%3B57%3A517.&btnG=). [Last accessed on 27 Feb 2025].
  29. Wright TW, Glowczewskie F, Jr., Cowin D, Wheeler DL. Ulnar nerve excursion and strain at the elbow and wrist associated with upper extremity motion. *J Hand Surg Am.* 2001;26:655-62. DOI PubMed
  30. Wright TW, Glowczewskie F, Wheeler D, Miller G, Cowin D. Excursion and strain of the median nerve. *J Bone Joint Surg Am.* 1996;78:1897-903. DOI PubMed
  31. Waters PM, Kolettis GJ, Schwend R. Acute median neuropathy following physeal fractures of the distal radius. *J Pediatr Orthop.* 1994;14:173-7. DOI PubMed
  32. Holbrook HS, Hillesheim RA, Weller WJ. Acute carpal tunnel syndrome and median nerve neurapraxia: a review. *Orthop Clin North Am.* 2022;53:197-203. DOI PubMed
  33. Swan CC, Buchanan PJ, Chim H. Complete transection of the median nerve with distal radius fracture: a case report. *JBJS Case Connect.* 2020;10:e0328. DOI PubMed
  34. Mead KC, Sgromolo NM, Krueger CA, Rhee PC. Comminuted distal radius fracture with concomitant median nerve transection: a case report and literature review. *JBJS Case Connect.* 2021;11:3. DOI PubMed
  35. McCarroll HR, Jr. Nerve injuries associated with wrist trauma. *Orthop Clin North Am.* 1984;15:279-87. PubMed
  36. Kongsholm J, Olerud C. Carpal tunnel pressure in the acute phase after Colles' fracture. *Arch Orthop Trauma Surg.* 1986;105:183-6. DOI PubMed
  37. Bauman TD, Gelberman RH, Mubarak SJ, Garfin SR. The acute carpal tunnel syndrome. *Clin Orthop Relat Res.* 1981;156:151-6. PubMed
  38. Pope D, Tang P. Carpal tunnel syndrome and distal radius fractures. *Hand Clin.* 2018;34:27-32. DOI PubMed
  39. Gillig JD, White SD, Rachel JN. Acute carpal tunnel syndrome: a review of current literature. *Orthop Clin North Am.* 2016;47:599-607. DOI PubMed
  40. Dyer G, Lozano-Calderon S, Gannon C, Baratz M, Ring D. Predictors of acute carpal tunnel syndrome associated with fracture of the distal radius. *J Hand Surg Am.* 2008;33:1309-13. DOI PubMed
  41. Itsubo T, Hayashi M, Uchiyama S, Hirachi K, Minami A, Kato H. Differential onset patterns and causes of carpal tunnel syndrome after distal radius fracture: a retrospective study of 105 wrists. *J Orthop Sci.* 2010;15:518-23. DOI PubMed
  42. Aro H, Koivunen T, Katevuo K, Nieminen S, Aho AJ. Late compression neuropathies after Colles' fractures. *Clin Orthop Relat Res.* 1988;233:217-25. PubMed
  43. Niver GE, Ilyas AM. Carpal tunnel syndrome after distal radius fracture. *Orthop Clin North Am.* 2012;43:521-7. DOI PubMed
  44. American Academy of Orthopaedic Surgeons. Management of distal radius fractures evidence-based clinical practice guideline. Available from: <https://www.aaos.org/globalassets/quality-and-practice-resources/distal-radius/drfcpg.pdf>. [Last accessed on 27 Feb 2025].
  45. Federatie Medisch Specialisten. Distale radiusfracturen. Available from: [https://richtlijndatabase.nl/richtlijn/distale\\_radiusfracturen/startpagina\\_-\\_distale\\_radiusfracturen.html](https://richtlijndatabase.nl/richtlijn/distale_radiusfracturen/startpagina_-_distale_radiusfracturen.html). [Last accessed on 27 Feb 2025].
  46. Kalyani BS, Fisher BE, Roberts CS, Giannoudis PV. Compartment syndrome of the forearm: a systematic review. *J Hand Surg Am.* 2011;36:535-43. DOI PubMed
  47. Samuel TD, Jeffrey H, Hayter E, et al. Acute carpal tunnel syndrome: early nerve decompression and surgical stabilization for bony wrist trauma. *Plast Reconstr Surg Glob Open.* 2023;11:e4929. DOI PubMed PMC
  48. Floyd WE 4th, Earp BE, Blazar PE. Acute median nerve problems in the setting of a distal radius fracture. *J Hand Surg Am.* 2015;40:1669-71. DOI PubMed
  49. Barbee GA, Haley CL, Berry-Cabán CS. A case of acute carpal tunnel syndrome. *JAAPA.* 2016;29:31-2. DOI PubMed
  50. Odumala O, Ayekoloye C, Packer G. Prophylactic carpal tunnel decompression during buttress plating of the distal radius-is it justified? *Injury.* 2001;32:577-9. DOI PubMed
  51. Dauzere F, Delclaux S, Pham TT, Rongièrès M, Mansat P. Combined median and ulnar nerve palsy complicating distal radius fractures. *Orthop Traumatol Surg Res.* 2018;104:871-5. DOI PubMed