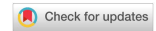

Mini-Review

Open Access



The role of artificial intelligence and 3D printing in minimally invasive liver surgery

Paraskevi Chatzikomnitsa, Areti Danai Gkaitatzi, Menelaos Papakonstantinou^{ID}, Eleni Louri, Dimitrios Giakoustidis, Vasileios N. Papadopoulos, Alexandros Giakoustidis^{ID}

Department of Surgery, General Hospital Papageorgiou, School of Medicine, Faculty of Medical Sciences, Aristotle University of Thessaloniki, Thessaloniki 56429, Greece.

Correspondence to: Dr. Menelaos Papakonstantinou, Department of Surgery, General Hospital Papageorgiou, School of Medicine, Faculty of Medical Sciences, Aristotle University of Thessaloniki, Agiou Pavlou 76, Thessaloniki 56429, Greece. E-mail: menelaospap.md@gmail.com

How to cite this article: Chatzikomnitsa P, Gkaitatzi AD, Papakonstantinou M, Louri E, Giakoustidis D, Papadopoulos VN, Giakoustidis A. The role of artificial intelligence and 3D printing in minimally invasive liver surgery. *Mini-invasive Surg.* 2025;9:8. <https://dx.doi.org/10.20517/2574-1225.2024.78>

Received: 29 Sep 2024 **First Decision:** 10 Dec 2024 **Revised:** 11 Feb 2025 **Accepted:** 6 Mar 2025 **Published:** 14 Mar 2025

Academic Editor: Giulio Belli **Copy Editor:** Ting-Ting Hu **Production Editor:** Ting-Ting Hu

Abstract

During the past decade, technological advancements have transformed liver surgery. New tools are available to assist the surgeon during complex operations, such as a hepatectomy for liver cancer. Augmented reality (AR) is an innovative technology that utilizes computed tomography (CT) or magnetic resonance imaging (MRI) scans to create three-dimensional (3D) images of the area or the organ of interest. This is especially useful for minimally invasive liver resection (MILR), where the field of view and maneuverability during the operation is limited. A 3D image of vascular structures, hilar segments, and the tumor location is projected into the operating field, thus contributing to a more precise resection. Combining AR with the groundbreaking capabilities of artificial intelligence (AI) could further improve the surgical outcomes of MILR. Specialized AI programs are designed to analyze the surgical field, provide information and facilitate the operation plan, simplify intraoperative decision making and reduce human error. 3D printing of hepatocellular cancer liver models is another useful technology that allows for procedure simulation, proper preoperative planning, and effective intraoperative navigation. Even though the benefits could be outstanding, the large cost of those technologies is a major limiting factor. Future research should focus on making AI and 3D imaging tools more widely affordable to the healthcare industry as data show that they could improve diagnostic efficiency, increase surgical precision, minimize human error and optimize patient care.

Keywords: Minimally invasive liver surgery, artificial intelligence, 3D printing, augmented reality



© The Author(s) 2025. **Open Access** This article is licensed under a Creative Commons Attribution 4.0 International License (<https://creativecommons.org/licenses/by/4.0/>), which permits unrestricted use, sharing, adaptation, distribution and reproduction in any medium or format, for any purpose, even commercially, as long as you give appropriate credit to the original author(s) and the source, provide a link to the Creative Commons license, and indicate if changes were made.



INTRODUCTION

Hepatobiliary surgery has evolved exponentially over the past decade. The utilization of modern technological equipment during surgery has made the procedure safer than ever before. The new techniques of minimally invasive surgery (MIS) in combination with the current enhanced recovery after surgery (ERAS) protocols have contributed to decreasing mortality from 20% to less than 5%^[1-4]. Laparoscopic hepatectomy has been proven to have significantly better postoperative outcomes compared to open hepatectomy, along with smaller incisions, less intraoperative blood loss, reduced postoperative pain, faster recovery, and a lower risk of complications during surgery^[5,6]. Therefore, it is increasingly popular and preferred by surgeons over older open methods for liver resection.

Admittedly, hepatic resection is a major procedure with a steep learning curve, which is even more challenging when performed laparoscopically. The loss of tactile sensation, along with the distorted depth perception through the laparoscopic camera, makes the intraoperative maneuvers and the ability to identify tumor margins and vital vasculature highly demanding, even for experienced surgeons^[7]. To overcome this burden, intraoperative ultrasound (IOUS), indocyanine green fluorescence, and tactile sensation were used to detect the tumor and the surrounding vessels^[8]. Recently, a revolutionary technology emerged in that area. Three-dimensional (3D) printing of liver models is assisting surgeons in understanding the patient's liver anatomy, tumor location and tumor margins and their anatomical relations with important nearby structures^[9,10].

The creation and utilization of 3D models have effectively facilitated liver surgery. They show progressively positive outcomes in terms of both preoperative planning and intraoperative navigation, increasing the accuracy and precision of highly demanding minimally invasive operations^[11,12]. Moreover, 3D liver allows the estimation of liver volume and functional liver remnant, and has been shown to improve postoperative outcomes in liver transplants, especially living donor transplants^[13,14]. Briefly, 3D printing of liver models is an exceptional tool that assists in planning a challenging hepatectomy.

Artificial intelligence (AI) is a revolutionary technology of our age and has begun to make significant inroads into surgery with great potential applications. It has been tested as a tool for the recognition of specific anatomical landmarks in complex laparoscopic operations with promising results for safe implementation in clinical practice^[15-17]. By combining preoperative computed tomography (CT) and magnetic resonance imaging (MRI) scans, an augmented reality (AR) image can be created and projected intraoperatively. This way, the visualization and identification of the tumor and its relationship with the portal veins, hepatic arteries, bile ducts and hepatic segments can be significantly enhanced^[8,18,19]. AI has been used to identify those structures by interpreting the AR projections of the surgical field. Improved intraoperative navigation, accuracy, precision and consequent surgical outcomes such as less intraoperative blood loss or shorter length of hospital stay are some of the expected end results^[15,20].

In this review, we examine recent technological advancements, such as AI and 3D printing, their increasing implementation in surgery, especially minimally invasive liver surgery, as well as their potential role in the refinement of surgical outcomes and the advancement of future patient care.

THE ROLE OF AR AND AI IN LIVER SURGERY

AI, a primary field of technology that uses algorithms to make close-to-human-level decisions, has gained more and more ground in surgery over the last few years. With technological advancements in imaging, navigation, and robotic interventions, as well as the utility in preoperative planning and intraoperative guidance, AI is practically changing the practice of today's surgery. The major role of AI integration into

surgery is improving efficiency and reducing human error. It also facilitates the preoperative planning of a surgical procedure and simplifies the intraoperative decision-making process.

Currently, AR is advancing in minimally invasive liver resection (MILR) because of the assistance that it provides intraoperatively, including better navigation for the excision, reduction of blood loss and complication, and the advantages of improving surgical outcomes and shortening hospital stay^[15]. Through AR and AI, CT and MRI scan images can be used to create a specific 3D patient-like model that can provide the surgeon with a real-life tangible liver module, aiding in the precise understanding of the anatomy, accurate tumor localization, and careful surgical planning, so that liver resection can be performed with well-defined safe margins, ensuring the preservation of important surrounding anatomical and vascular structures, such as the hepatic artery, portal vein, and hepatic vein^[12,18,21,22].

AR navigation systems have been applied to various surgical procedures; however, challenges remain in constructing a comprehensive visualization system to accurately determine tumor locations and ensure sufficient resection margins on the hepatic surface during laparoscopic liver resection. These challenges arise from the complexity of the liver's anatomical structures and the variability of each patient's internal anatomy^[22,23].

Some of the methods that are performed using AR assistance are video-based, projection-based, and see-through AR visualization. The video-assisted AR navigation system uses imaging information from CT and MRI scans and provides the surgeon with live laparoscopic video, enabling him to detect critical vascular structures to achieve safer and more effective resection, along with reduced adverse intraoperative and postoperative outcomes^[23].

The early and accurate diagnosis of hepatic disease is of great importance, and until recently, the necessary information, such as liver size and condition, tumor location, and surrounding vascular structures, were obtained from abdominal CT and MRI images. The evolution of technology and the establishment of AI and 3D imaging in MILR has offered surgeons an important tool in the operating room and a valuable technique to overcome any difficulties^[12,23].

In a 2019 study, Shen *et al.* proposed a deep learning (DL) network architecture and developed patient-specific models to demonstrate the feasibility of reconstructing 3D CT images of the abdomen, lung, head and neck regions from X-ray projections. Their research showed that this deep-learning network that utilizes a single-view image incorporating information obtained from all the imaging techniques (e.g., X-ray, CT scan, and MRI) represents a possible solution for any interventional procedures and may contribute to optimal procedure planning^[24]. Ying *et al.* in 2019 also demonstrated the feasibility of lung CT reconstructions from two orthogonal X-ray projections. Specifically, they explored the possibility of reconstructing a 3-dimensional CT scan from 2-dimensional X-ray images. The results of their study showed the superiority of the 3-dimensional reconstructed image over the simple 2-dimensional X-ray scan^[25]. In the same year, Prevost *et al.* investigated the efficiency of an AR system regarding the clinical benefit of 3D laparoscopic liver surgery. Their research showed that in all the patients who received laparoscopic liver resection by using the 3D imaging preoperative planning system, the surgical time was reduced, the intraoperative errors were lessened, and the excision of hepatic lesions was more efficient^[12]. Shao *et al.* in 2021 developed a method to localize liver tumors, using a combination of 2D and 3D registrations and biomechanical modeling approaches. Their method used 2D and 3D deformable registrations, by obtaining information from CT images and X-ray projections, to build a biomechanical model that converts the organ of interest, in this case the liver, into small connected tetrahedral mesh

elements with specific biomechanical assets^[26]. Considering the diversity of liver anatomy and structure patterns among different patients, Shao *et al.* proposed a patient-specific model to demonstrate the anatomical details of each patient under treatment and, thus, an important way of predicting liver boundary motion and precise tumor location and margins, using the deep-learning module and analysis of the biomechanical liver modeling, a method that could potentially be applied in monitoring of liver tumors and real-time adaptation planning for the liver and the surrounding anatomical structures^[26,27].

To improve diagnostic efficiency and acquire more accurate information about individual tumor position, AI and 3D computer imaging must be implemented in everyday practice^[28]. However, the cost of this technique is extremely high and demands adequate time for the exact preparation of a reliable 3D liver model^[11].

THE ROLE OF 3D MODELS IN LIVER SURGERY

Liver surgery has entered a new era where CT and MRI are no longer sufficient for preoperative planning. Therefore, 3D reconstruction has become a crucial tool for mapping the relationships between vascular structures and the biliary tree and for measuring liver volume^[29].

CT and MRI provide two-dimensional images of the actual 3D anatomy [Figure 1]. It is very important to have a thorough understanding of the 3D anatomy before conducting a surgical procedure for optimal results. Oh *et al.* conducted a study involving 120 patients to assess the performance of 3D models. Their study compared the 3D models to the removed liver and found that a better understanding of the anatomy preoperatively resulted in improved surgical outcomes with very minimal discrepancies^[30].

Lopez-Lopez *et al.* conducted a multicenter study involving seven centers using 3D reconstruction technology^[31]. The study included 41 patients with perihilar cholangiocarcinoma, for whom a 3D model was created. Four patients, based on this model, were considered to have uncontrolled tumors. A questionnaire completed by the surgeons indicated that the 3D model helped in better understanding and interpreting the anatomical structures of the area^[8].

Currently, radical hepatectomy is still the preferred treatment for primary or metastatic liver tumors. However, the main difficulty in liver surgery is striking a balance between acceptable resection margins and functional residual liver volume. By utilizing 3D printing and IOUS technology, surgeons can identify the tumor boundaries, achieving the performance of the hepatectomy with great precision in the boundaries that were planned preoperatively^[32,33].

The technology of 3D printing allows for accurate reconstruction of vascular structures with minimal error, as the CT sections are thin enough to create a true copy without introducing human error. According to Cui *et al.*, 3D models have been shown to reduce intraoperative blood loss, shorten operative time, and not increase the incidence of complications. In their study, a blood loss of 772.52 ± 112.13 mL was observed in the group that did not use 3D models, compared to 553.62 ± 98.56 mL in the group that did use them (P value < 0.001). Additionally, the surgical time was 645.29 ± 121.14 min in the group that did not use 3D models, compared to 523.19 ± 103.15 min in the group that did use them (P value < 0.001). The study also indicated that the R0 resection rate and number of lymph nodes in the 3D printing group were higher, suggesting that 3D reconstruction provided benefits for patients undergoing surgery for cholangiocarcinoma. The overall complication rate in the group that used the 3D models is 21.05%, compared to 25.71% in the group that did not use them^[34].

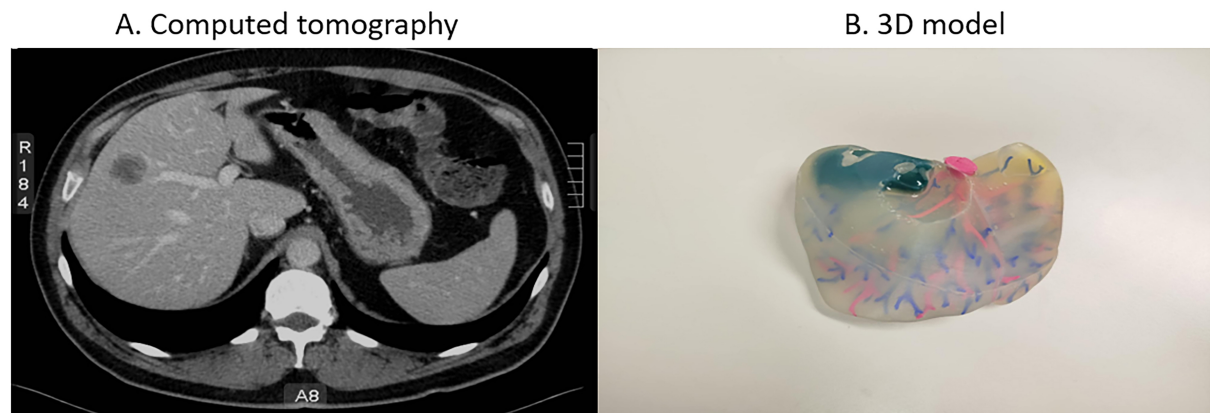


Figure 1. (A) Computed tomography scan of a patient with right liver lobe hepatocellular carcinoma; (B) The 3D-printed liver model of the same patient. The right liver lobe carcinoma is marked with blue ink.

Yang *et al.* conducted a study on surgeons specializing in liver surgery. The study aimed to compare the efficiency of preoperative planning based on either CT data or 3D model data[35]. The results demonstrated that surgeons using the 3D model required less time for preoperative planning. Additionally, patients undergoing hepatectomy planned using the 3D model experienced higher surgical accuracy compared to those planned using CT scans.

One of the key applications of 3D models is to measure liver volume accurately. Through 3D reconstruction technology, we have achieved greater accuracy in measuring residual liver volume compared to older empirical methods. This allows for preoperative assessment to determine if a patient is at risk of developing postoperative liver failure. Consequently, the patient could undergo preoperative liver resection or embolization of the portal vein branch to increase the volume of the remaining liver^[36].

An important use of 3D liver models is in combination with the indocyanine green dye (ICG)^[36]. This method has been shown to achieve the best surgical results in the accuracy of liver tumor resection. Indocyanine green is a dye that can stain the tumor through systemic circulation or portal vein circulation, helping the surgeon identify specific resection margins^[37]. The use of ICG fluorescence imaging makes the fusion of multi-modal images possible, which helps to define tumor demarcation, detect small lesions, and improve surgical precision^[38].

3D liver models are not only used by surgeons to improve surgical outcomes, but also serve as an important tool for interventional radiologists, helping them better identify the anatomy of the hepatic artery when preparing patients for chemoembolization (TACE), tumor ablation, or argon-helium knife treatment^[39].

3D printing technology serves as a superior enhancement method for preoperative planning and intraoperative navigation, demonstrating progressively positive outcomes^[11].

THE FUTURE OF MINIMALLY INVASIVE LIVER SURGERY

The utilization of 3D printing, AR, and AI is a promising step for improving the management of patients with liver tumors and enhancing the precision of the surgical team. Moreover, the ever-increasing integration of robotics in surgery over the past decade is poised to revolutionize MILS. The robotic approach merges the mobility of open surgery with the merits of laparoscopic surgery, such as fewer perioperative complications and shorter length of stay.

The application of AI in liver surgery has many areas with potential for development, which, however, require more study^[40]. Moreover, robotic liver resection (RLR) lacks tactile feedback; therefore, accurate intraoperative imaging is essential. Even though ICG can be utilized in RLR, the use of more advanced imaging methods is not yet supported in robotic platforms. In some pilot studies, virtual 3D liver models created based on CT scans have offered preoperative guidance for RLR with promising results. However, intraoperative AR projections are still unavailable due to limitations in robotic platform capabilities. Research on the application of AI in robotic surgery is also in the early stages, as robotic platforms currently have only a limited level of autonomy^[41,42]. More advanced robotic platforms are needed for AR imaging modalities to be available intraoperatively. Preliminary results are promising, but the equipment is still premature. On the other hand, IOUS-guided robotic resection for liver tumors has been proven to be safe and feasible without compromising the oncological outcomes^[41,43].

Robotic technology is continuously evolving and being integrated into MILS. Spiegelberg *et al.* have observed reduced length of stay in patients undergoing robotic hepatectomy versus both open and laparoscopic approaches. However, the cost remains high as, besides the cost of the console itself, hidden costs like disposables, maintenance, and other additional costs outweigh any advantage of the shorter hospitalization^[44]. The literature is not conclusive, as in a study, the total cost of liver resection was higher for the open versus robotic approach^[45]. Hopefully in the future new competitors will enter the market and the operative cost of a robotic platform will be affordable for wider application.

Another downside of the limited application is the lack of organized training. An expert panel in 2019 agreed on the standardization and optimization of training in robotic procedures for HPB surgeons. The suggested curriculum would provide both theoretical knowledge on the function of a robotic platform and surgical training including basic skills and gradual advancement to more complex procedures^[46]. This is a noteworthy first step, but more effort is needed in the future to improve and incorporate the robotic platform in everyday surgical practice^[47].

Today, case studies and single-center analyses are mostly available in the literature, concluding that RLR is technically feasible and clinically safe^[48,49]. A propensity-score matched analysis from the National Cancer Database concluded that over seven years, the use of robotic platforms for liver resection in the USA has increased by fivefold and was associated with shorter length of stay without any difference in survival compared to the open approach^[50]. Nevertheless, the robotic platform represents the current evolution of MIS. Through the robotic platform, fluorescence technology can be used to enhance the accuracy and safety of the surgical procedure. Additionally, robotic surgery utilizes 3D imaging. Thus, through AR and 3D models, the safe boundaries of the procedure being performed are displayed on the surgeon's screen^[42].

Special mention should be made of the application of AI in the imaging and detection of liver tumors. Convolutional neural networks (CNNs), a type of DL algorithm, effectively encode the translation invariance, a key feature of image data. The use of DL with CNNs has become widespread in image recognition, and the role of AI in medical diagnosis and prognosis is steadily increasing^[51].

This technology enables clinicians to determine which patients should undergo surgery and which ones would benefit more from alternative treatments. It helps reduce the need for repeat examinations, as all essential elements can be identified at the outset. Moreover, it streamlines the decision-making process for developing the patient's treatment plan.

However, for DL algorithms to yield reliable results, a large volume of data is required. More large prospective studies and multicentered randomized controlled trials (RCTs) are needed in order to consolidate those findings and successfully compare the robotic approach to the current standard of care.

CONCLUSION

Minimally invasive liver surgery is entering a new era, as modern technology, such as AI and AR imaging, is being incorporated into clinical practice. The combination of advanced intraoperative imaging methods with the use of 3D liver models during preoperative planning increases the precision and accuracy of the surgery. Furthermore, emerging robotic platforms are another promising way to take advantage of state-of-the-art intraoperative imaging and refine patient care. However, this technology is still immature and more research is needed to decrease the cost and implement robotic liver resection more widely in clinical practice. Future studies should focus on large multicentered RCTs directly comparing MILS using 3D-printed liver models or AI guidance with the standard laparoscopic approach to further advance liver surgery.

DECLARATIONS

Authors' contributions

Made substantial contributions to the conception and design of the study: Chatzikomnitsa P, Papakonstantinou M, Giakoustidis A

Contributing to writing the manuscript: Chatzikomnitsa P, Gkaitatzi AD, Papakonstantinou M, Louri E

Performed revisions and provided administrative support: Giakoustidis D, Papadopoulos VN

Served as supervising author: Giakoustidis A

Availability of data and materials

Not applicable.

Financial support and sponsorship

None.

Conflicts of interest

All authors declared that there are no conflicts of interest.

Ethical approval and consent to participate

Not applicable.

Consent for publication

Not applicable.

Copyright

© The Author(s) 2025.

REFERENCES

1. Noba L, Rodgers S, Chandler C, Balfour A, Hariharan D, Yip VS. Enhanced recovery after surgery (ERAS) reduces hospital costs and improve clinical outcomes in liver surgery: a systematic review and meta-analysis. *J Gastrointest Surg.* 2020;24:918-32. DOI PubMed PMC
2. Marvin MR, Buell JF. Laparoscopic liver surgery. *Adv Surg.* 2009;43:159-73. DOI PubMed
3. Filmann N, Walter D, Schadde E, et al. Mortality after liver surgery in Germany. *Br J Surg.* 2019;106:1523-9. DOI PubMed
4. Melloul E, Hübner M, Scott M, et al. Guidelines for perioperative care for liver surgery: enhanced recovery after surgery (ERAS) society recommendations. *World J Surg.* 2016;40:2425-40. DOI PubMed

5. Lim JSH, Shelat VG. 3D laparoscopy and fluorescence imaging can improve surgical precision for hepatectomy. *Hepatobiliary Surg Nutr.* 2024;13:544-7. DOI PubMed PMC
6. Finotti M, D'Amico F, Testa G. The current and future role of robotic surgery in liver surgery and transplantation. *Minerva Surg.* 2022;77:380-90. DOI PubMed
7. Buchs NC, Volonte F, Pugin F, et al. Augmented environments for the targeting of hepatic lesions during image-guided robotic liver surgery. *J Surg Res.* 2013;184:825-31. DOI PubMed
8. Tripke V, Sommer N. An update on liver surgery - a new terminology and modern techniques. *Innov Surg Sci.* 2023;8:197-201. DOI PubMed PMC
9. Kang X, Azizian M, Wilson E, et al. Stereoscopic augmented reality for laparoscopic surgery. *Surg Endosc.* 2014;28:2227-35. DOI PubMed
10. Banchini F, Romboli A, Rizzi N, Luzietti E, Conti L, Capelli P. Laparoscopic dorsal subsegmentectomy 8: exploit the 3d technology to plan liver resection, and predict intraparenchymal pedicles. A case report. (With video explanation). *Int J Surg Case Rep.* 2021;88:106516. DOI PubMed PMC
11. Cheng J, Wang Z, Liu J, Dou C, Yao W, Zhang C. Value of 3D printing technology combined with indocyanine green fluorescent navigation in complex laparoscopic hepatectomy. *PLoS One.* 2022;17:e0272815. DOI PubMed PMC
12. Prevost GA, Eigl B, Paolucci I, et al. Efficiency, accuracy and clinical applicability of a new image-guided surgery system in 3D laparoscopic liver surgery. *J Gastrointest Surg.* 2020;24:2251-8. DOI PubMed
13. Gavriilidis P, Edwin B, Pelanis E, et al. Navigated liver surgery: state of the art and future perspectives. *Hepatobiliary Pancreat Dis Int.* 2022;21:226-33. DOI PubMed
14. Berardi G, Colasanti M, Meniconi RL, et al. The applications of 3D imaging and indocyanine green dye fluorescence in laparoscopic liver surgery. *Diagnostics.* 2021;11:2169. DOI PubMed PMC
15. Kasai M, Uchiyama H, Aihara T, Ikuta S, Yamanaka N. Laparoscopic projection mapping of the liver portal segment, based on augmented reality combined with artificial intelligence, for laparoscopic anatomical liver resection. *Cureus.* 2023;15:e48450. DOI PubMed PMC
16. Koo B, Robu MR, Allam M, et al. Automatic, global registration in laparoscopic liver surgery. *Int J Comput Assist Radiol Surg.* 2022;17:167-76. DOI PubMed PMC
17. Labrunie M, Ribeiro M, Mourthadhoi F, et al. Automatic preoperative 3d model registration in laparoscopic liver resection. *Int J Comput Assist Radiol Surg.* 2022;17:1429-36. DOI PubMed
18. Volonté F, Pugin F, Bucher P, Sugimoto M, Ratib O, Morel P. Augmented reality and image overlay navigation with OsiriX in laparoscopic and robotic surgery: not only a matter of fashion. *J Hepatobiliary Pancreat Sci.* 2011;18:506-9. DOI PubMed
19. Oshiro Y, Ohkohchi N. Three-dimensional liver surgery simulation: computer-assisted surgical planning with three-dimensional simulation software and three-dimensional printing. *Tissue Eng Part A.* 2017;23:474-80. DOI PubMed
20. Saito Y, Shimada M, Morine Y, Yamada S, Sugimoto M. Essential updates 2020/2021: current topics of simulation and navigation in hepatectomy. *Ann Gastroenterol Surg.* 2022;6:190-6. DOI PubMed PMC
21. Pelanis E, Teatini A, Eigl B, et al. Evaluation of a novel navigation platform for laparoscopic liver surgery with organ deformation compensation using injected fiducials. *Med Image Anal.* 2021;69:101946. DOI PubMed
22. Zhang P, Luo H, Zhu W, et al. Real-time navigation for laparoscopic hepatectomy using image fusion of preoperative 3D surgical plan and intraoperative indocyanine green fluorescence imaging. *Surg Endosc.* 2020;34:3449-59. DOI PubMed
23. Luo H, Yin D, Zhang S, et al. Augmented reality navigation for liver resection with a stereoscopic laparoscope. *Comput Methods Programs Biomed.* 2020;187:105099. DOI
24. Shen L, Zhao W, Xing L. Patient-specific reconstruction of volumetric computed tomography images from a single projection view via deep learning. *Nat Biomed Eng.* 2019;3:880-8. DOI PubMed PMC
25. Ying X, Guo H, Ma K, Wu J, Weng Z, Zheng Y. X2CT-GAN: reconstructing CT from biplanar X-Rays with generative adversarial networks. In: 2019 IEEE/CVF Conference on Computer Vision and Pattern Recognition (CVPR); 2019 Jun 15-20; Long Beach, USA. IEEE; 2019. pp. 10611-20. DOI
26. Shao HC, Wang J, Bai T, et al. Real-time liver tumor localization via a single x-ray projection using deep graph neural network-assisted biomechanical modeling. *Phys Med Biol.* 2022;67:115009. DOI PubMed PMC
27. Shao HC, Huang X, Folkert MR, Wang J, Zhang Y. Automatic liver tumor localization using deep learning-based liver boundary motion estimation and biomechanical modeling (DL-Bio). *Med Phys.* 2021;48:7790-805. DOI PubMed PMC
28. Wang B, Yang J, Ai J, et al. Accurate tumor segmentation via octave convolution neural network. *Front Med.* 2021;8:653913. DOI PubMed PMC
29. Lu Y, Chen X, Han F, et al. 3D printing of self-healing personalized liver models for surgical training and preoperative planning. *Nat Commun.* 2023;14:8447. DOI PubMed PMC
30. Oh N, Kim JH, Rhu J, et al. Automated 3D liver segmentation from hepatobiliary phase MRI for enhanced preoperative planning. *Sci Rep.* 2023;13:17605. DOI PubMed PMC
31. Lopez-Lopez V, Gomez-Perez B, de Vicente E, et al. Next-generation three-dimensional modelling software for personalized surgery decision-making in perihilar cholangiocarcinoma: multicentre study. *Br J Surg.* 2021;108:e394-5. DOI PubMed
32. Lv A, Li Y, Qian HG, Qiu H, Hao CY. Precise navigation of the surgical plane with intraoperative real-time virtual sonography and 3D simulation in liver resection. *J Gastrointest Surg.* 2018;22:1814-8. DOI PubMed

33. Wu T, Huang W, He B, et al. Diagnostic accuracy of 3D imaging combined with intra-operative ultrasound in the prediction of post-hepatectomy liver failure. *J Gastrointest Oncol.* 2022;13:1224-36. DOI PubMed PMC
34. Cui DP, Fan S, Guo YX, Zhao QW, Qiao YX, Fei JD. Accurate resection of hilar cholangiocarcinoma using eOrganmap 3D reconstruction and full quantization technique. *World J Gastrointest Surg.* 2023;15:1693-702. DOI PubMed PMC
35. Yang HY, Rho SY, Han DH, Choi JS, Choi GH. Robotic major liver resections: surgical outcomes compared with open major liver resections. *Ann Hepatobiliary Pancreat Surg.* 2021;25:8-17. DOI PubMed PMC
36. Society Of Digital Medicine Chinese; Cancer Committee Of Chinese Medical Doctor Association Liver; Precision Medicine Committee Of Chinese Medical Doctor Association Clinical; Intelligent Surgery Committee Of Chinese Research Hospital Association Digital. [Clinical practice guidelines for precision diagnosis and treatment of complex liver tumor guided by three-dimensional visualization technology (version 2019)]. *Nan Fang Yi Ke Da Xue Xue Bao.* 2020;40:297-307. (in Chinese). DOI PubMed PMC
37. Fang CH, Liang HB, Chi CW, et al. [Application of indocyanine green-fluorescent imaging technique in planning resection line and real-time surgical navigation in small hepatocellular carcinoma]. *Zhonghua Wai Ke Za Zhi.* 2016;54:444-50. (in Chinese). DOI PubMed
38. Fang CH, Zhang P, Lau YY, Zhong SZ. [Construction and application of the core technology system of digital intelligent diagnostic and treatment for hepato-biliary-pancreatic diseases]. *Zhonghua Wai Ke Za Zhi.* 2019;57:253-7. (in Chinese). PubMed
39. Arizumi T, Ueshima K, Minami T, et al. Effectiveness of sorafenib in patients with transcatheter arterial chemoembolization (TACE) refractory and intermediate-stage hepatocellular carcinoma. *Liver Cancer.* 2015;4:253-62. DOI PubMed PMC
40. Giannone F, Felli E, Cherkaoui Z, Mascagni P, Pessaux P. Augmented reality and image-guided robotic liver surgery. *Cancers.* 2021;13:6268. DOI PubMed PMC
41. Vasey B, Lippert KAN, Khan DZ, et al. Intraoperative applications of artificial intelligence in robotic surgery: a scoping review of current development stages and levels of autonomy. *Ann Surg.* 2023;278:896-903. DOI PubMed PMC
42. Knudsen JE, Ghaffar U, Ma R, Hung AJ. Clinical applications of artificial intelligence in robotic surgery. *J Robot Surg.* 2024;18:102. DOI PubMed PMC
43. Pesi B, Moraldi L, Guerra F, et al. Surgical and oncological outcomes after ultrasound-guided robotic liver resections for malignant tumor. Analysis of a prospective database. *Int J Med Robot.* 2019;15:e2002. DOI PubMed
44. Spiegelberg J, Iken T, Diener MK, Fichtner-Feigl S. Robotic-assisted surgery for primary hepatobiliary tumors-possibilities and limitations. *Cancers.* 2022;14:265. DOI PubMed PMC
45. Daskalaki D, Gonzalez-Heredia R, Brown M, et al. Financial impact of the robotic approach in liver surgery: a comparative study of clinical outcomes and costs between the robotic and open technique in a single institution. *J Laparoendosc Adv Surg Tech A.* 2017;27:375-82. DOI PubMed PMC
46. Fong Y, Buell JF, Collins J, et al. Applying the Delphi process for development of a hepatopancreaticobiliary robotic surgery training curriculum. *Surg Endosc.* 2020;34:4233-44. DOI PubMed
47. Boal MWE, Anastasiou D, Tesfai F, et al. Evaluation of objective tools and artificial intelligence in robotic surgery technical skills assessment: a systematic review. *Br J Surg.* 2024;111:znad331. DOI PubMed PMC
48. Lim C, Goumard C, Salloum C, et al. Outcomes after 3D laparoscopic and robotic liver resection for hepatocellular carcinoma: a multicenter comparative study. *Surg Endosc.* 2021;35:3258-66. DOI PubMed
49. Hawksworth J, Llore N, Holzner ML, et al. Robotic hepatectomy is a safe and cost-effective alternative to conventional open hepatectomy: a single-center preliminary experience. *J Gastrointest Surg.* 2021;25:825-8. DOI PubMed
50. Kamel MK, Tuma F, Keane CA, Blebea J. National trends and perioperative outcomes of robotic-assisted hepatectomy in the USA: a propensity-score matched analysis from the national cancer database. *World J Surg.* 2022;46:189-96. DOI PubMed
51. Njei B, Kanmounye US, Seto N, et al. Artificial intelligence in medical imaging for cholangiocarcinoma diagnosis: a systematic review with scientometric analysis. *J Gastroenterol Hepatol.* 2023;38:874-82. DOI PubMed