

Original Article

Open Access



Exploring the emerging role of Meek micrografting in healing smaller burns: a case series and evidence review

Elizabeth Wilson , Michael Grant, Malik Fleet, Megan Lee, Isabel Jones

Department of Burns and Plastic Surgery, Chelsea and Westminster Hospital, London SW10 9NH, UK.

Correspondence to: Dr. Elizabeth Wilson, Dr. Isabel Jones, Department of Burns and Plastic Surgery, Chelsea and Westminster Hospital, 369 Fulham Road, London SW10 9NH, UK. E-mail: Elizabeth.Wilson58@nhs.net; Isabel.Jones2@nhs.net

How to cite this article: Wilson E, Grant M, Fleet M, Lee M, Jones I. Exploring the emerging role of Meek micrografting in healing smaller burns: a case series and evidence review. *Plast Aesthet Res.* 2025;12:8. <https://dx.doi.org/10.20517/2347-9264.2024.135>

Received: 17 Oct 2024 **First Decision:** 23 Jan 2025 **Revised:** 23 Feb 2025 **Accepted:** 6 Mar 2025 **Published:** 24 Mar 2025

Academic Editors: Xianwen Wang, Marc Jeschke **Copy Editor:** Ting-Ting Hu **Production Editor:** Ting-Ting Hu

Abstract

Aim: Deep dermal and full-thickness burns typically require reconstruction with split-thickness skin grafting, usually following a traditional Tanner mesh technique. An alternate is the modified Meek technique, which has the benefit of reducing the required donor site size. The study presents our experience with the modified Meek technique over thirteen years, involving 64 patients with varying total body surface area (TBSA) sizes, aiming to evaluate outcomes including length of stay, time to heal, and patient and observer scar assessment scale (POSAS) scores. Additionally, we conducted a review of the current literature.

Methods: Patients who underwent skin grafting using the modified Meek technique at the Adult Burns Centre at Chelsea and Westminster Hospital between 2011 and 2024 were identified retrospectively using theatre logs. A dual-investigator literature review was carried out using Ovid and PubMed.

Results: The mean length of stay was 64 days, with a mortality rate of 4.6%. The mean time to achieve 95% healing was 76 days. The median POSAS score was 5. The literature search identified 27 relevant papers for analysis.

Conclusion: The modified Meek technique results in smaller donor sites, and safely and effectively heals a wound in a more timely way using the same expansion ratio as conventional meshed grafts. Areas for ongoing future research from our review include the use of Meek for smaller TBSA injuries and its potential combination with



© The Author(s) 2025. **Open Access** This article is licensed under a Creative Commons Attribution 4.0 International License (<https://creativecommons.org/licenses/by/4.0/>), which permits unrestricted use, sharing, adaptation, distribution and reproduction in any medium or format, for any purpose, even commercially, as long as you give appropriate credit to the original author(s) and the source, provide a link to the Creative Commons license, and indicate if changes were made.



dermal templates.

Keywords: Meek micrografting, modified Meek technique, burns, dermal templates

INTRODUCTION

Various techniques are available for skin reconstruction following burn injuries; however, the application of split-thickness skin grafts remains the most common. Harvesting a skin graft requires the surgeon to create an additional skin defect, termed the donor site. This presents a significant challenge, particularly in patients with large burns, where limited donor site availability may necessitate re-cropping the same donor site multiple times^[1,2]. Such procedures can delay wound healing, as the surgeon must wait for the donor site to heal before it can be re-harvested. In cases requiring a large donor site, this also increases morbidity, resulting in greater acute pain and a larger long-term scar. For massive burns, a high expansion ratio for skin grafts is desirable, which can be achieved through Meek micrografting.

Meek micrografting, a technique developed by Cicero Parker Meek in 1958, aims to produce reproducible micromeshing of skin grafts, thereby reducing the donor site area required, using a device to facilitate the process^[3]. However, the technique did not gain popularity at the time, possibly because it coincided with the introduction of the Tanner meshed skin graft method in the 1960s, which was less technically demanding^[4]. The Meek technique was reintroduced in 1993 as the modified Meek technique, following technical advances that streamlined the process by Humeca. Since then, it has gradually gained popularity and is now an established alternative to conventional meshed grafts for massive burns that require larger skin expansion ratios^[2,5-19]. The modified Meek technique enables exact expansion ratios of 1:2, 1:3, 1:4, 1:6, and 1:9, with minimal donor skin wastage. The Meek system produces 3mm square split-thickness micrografts that can be easily transferred to a wound using silk backing fabric, at a predetermined expansion ratio^[1]. A donor as small as 10% total body surface area (TBSA) can cover 90% of a TBSA burn with a 1:9 expansion ratio, and a 60% TBSA burn can be covered relatively easily with an expansion ratio as low as 1:3, without the need for re-cropping donor sites.

We recognize the role of the Meek technique in facilitating the healing of large burn wounds when there is limited donor site availability^[6,7,10,12,17-20]. Additionally, we are beginning to explore the potential of Meek grafting for patients who are at risk of poor wound healing, including the elderly or those with comorbidities such as diabetes and peripheral vascular disease, where donor site healing is an additional challenge and smaller donor sites are desirable^[2]. We are starting to observe positive outcomes following Meek micrografting in combination with two-stage skin substitutes, reporting favorable graft take and long-term scarring outcomes^[13,21,22].

To date, the only published evidence focused solely on the use of Meek in smaller TBSA burns is our own previously published work, which mentions a small early series where this technique was used in patients with burns < 20% TBSA^[1]. There are, however, several papers where patients with burns < 20% TBSA are included as part of a larger series of patients with a range of injury sizes, providing additional support for the use of this technique in smaller injuries^[21,23-26].

In our practice, we are increasingly electing to use Meek for smaller TBSA burns. Our goal is to minimize the size of donor sites in patients with thinner dermis, particularly among the elderly. We also consider the wishes of patients who request the smallest donor sites possible while ensuring timely healing and comparable scar outcomes. We recognize that a substantial body of literature exists on the use of Meek for

larger TBSA burns, which has been covered in a recent review^[27]. In this paper, we aim to present our experience with Meek since its introduction to our unit in 2011, focusing on its application for smaller (< 20%) TBSA burns and considering the use and outcomes in combination with dermal substitutes.

METHODS

Patients who underwent skin grafting using the modified Meek technique at the Adult Burns Centre of Chelsea and Westminster Hospital between 2011 and 2024 were retrospectively identified using theatre logs. Burn cases of any TBSA were included if the Meek technique was used for either partial or complete coverage of the burn. Data on patient demographics, operative details, and surgical outcomes were manually retrieved from patient medical records and operation notes, with all information anonymized. Statistics were performed using Microsoft Excel and GraphPad Prism (Version 10). The quality of the healed grafts was assessed using the patient and observer scar assessment scale (POSAS), which assigns a score from 1 to 10, whereby the closer the score to “1”, the more similar to normal skin the scar is felt to be^[28].

A systematic review of the literature on the modified Meek technique was conducted by two investigators using Ovid, searching MEDLINE, Embase, and PubMed. The search strategy was as follows:

1. “Meek” OR “Meek micrograft” OR “Micrograft” AND;
2. “Burns” OR “Major Burns” OR “Burn Injuries” AND;
3. “Outcomes”.

Further references were identified using the snowballing technique. Papers evaluating non-human subjects or written in languages other than English were excluded. A flow diagram of the process is demonstrated in [Figure 1](#).

Following a two-stage review process, a total of 27 papers were included in our literature review. Data were extracted from these papers using a formal, standardized data extraction form in Microsoft Excel.

RESULTS

Demographics

A total of 76 patients were treated for burn injuries using the modified Meek technique at our hospital between 2011 and 2024. Of these, 12 were excluded from our analysis due to incomplete records, resulting in a final study population of 64 (series A). The overall median age was 53 years (IQR 39-73).

The mechanisms of injury were as follows: flame burn in 71%, scald in 16%, chemical in 2%, contact in 5%, electrical in 3%, and oil in 3%. Burn depth varied: 19% full thickness, 3% deep dermal, 6% mid-dermal, 2% superficial partial thickness, and 70% mixed depth. Among the mixed-depth burns, 42% had a full-thickness component.

There were 29 patients requiring ICU-level care. The mortality rate among ICU patients was 7% ($n = 2$). Seven patients were transferred to another unit and were therefore excluded from further analysis. One additional patient was excluded due to unclear ICU admission details. Among the remaining 19 ICU patients, the median length of stay was 36 days (IQR 19,44), and the median TBSA was 40% (IQR 10, 40).

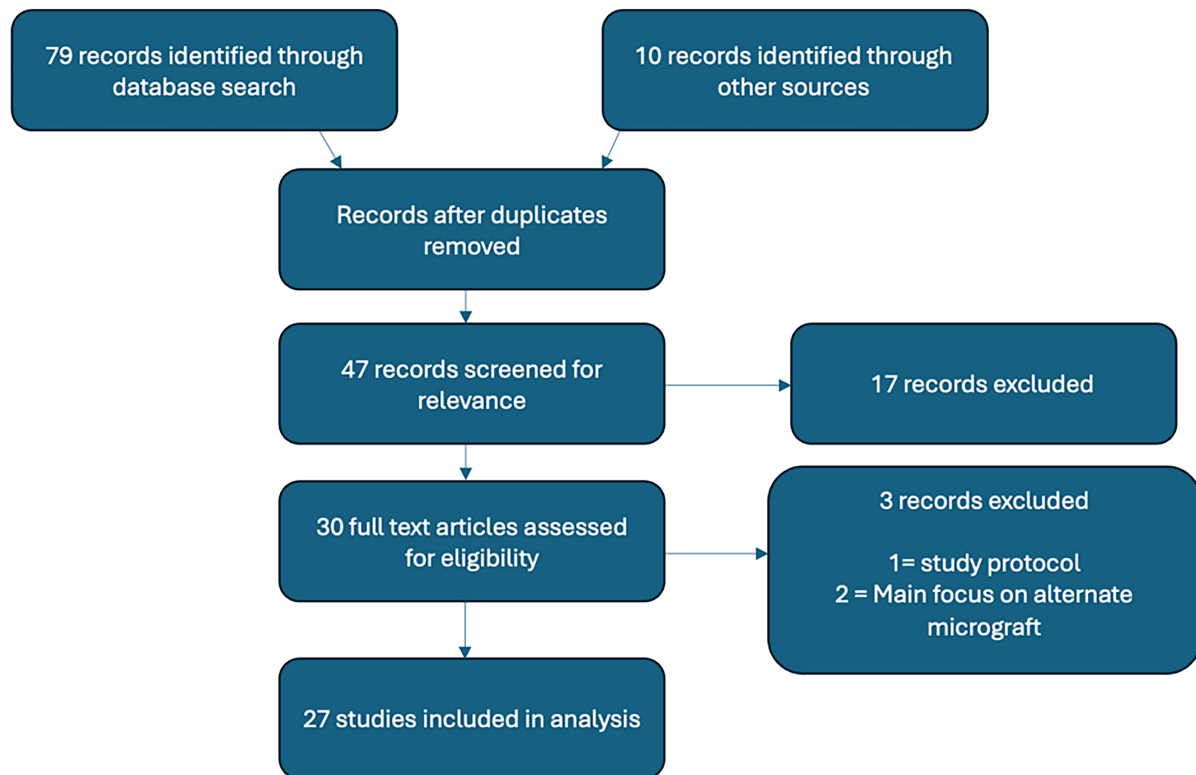


Figure 1. Literature search diagram.

Operative data

The median number of procedures per patient was 2 (IQR 2,7). The median number of Meek procedures was 1 (IQR 1,2). The median time to the first Meek graft was 10 days (IQR 7,24). Prior to first Meek autograft, patients were medically optimised and usually underwent tangential excision with temporization of the burn with allograft, to prepare the wound bed for optimal graft take. During the first Meek procedure, the median grafted area was 11% (IQR 7.5,18.0), and 22% of patients received a combination of Meek and meshed grafts during their first autografting. In 27% of cases, the donor site was over-grafted. Overall, 78% of the cohort received both micrografts and mesh grafts during their admission.

Postoperative outcomes

The median time to achieve 95% wound healing was 76 days (IQR 41-133). The mean length of hospital stay was 64 days. The overall mortality rate was 4.6%.

Functional and aesthetic outcomes

At one year post-procedure, the median POSAS score was 5 (IQR 4-6), based on data from 13 patients. As POSAS data were collected only in the second half of this study, only these 13 patients were included in this analysis, all of whom had a TBSA < 20%.

Meek technique in smaller burns (< 20% TBSA)

As earlier stated, the total study population was labeled Series A. This group was further divided into two cohorts: (1) Burns < 20% (Series B) and (2) Burns ≥ 20% (Series C). A total of 28 patients with a median age of 71 years (IQR 53,77) were treated with Meek micrografting for burns covering < 20% TBSA (Series B). Series C included 36 patients. Among series B patients, 14 were aged 70 years or above, 13 were adults under

70, and one was a child. Information regarding patient comorbidities is summarized in [Table 1](#), with a median of 3 comorbidities per patient.

The median number of procedures was 2 (IQR 2,3). The median time to first Meek graft was 8 days (IQR 7,15), with a median TBSA grafted of 12% (IQR 8.5,15.4). Two patients received a combination of Meek and meshed grafts at the time of the first autograft. The median time to 95% healing was 62.5 days (IQR 26,130), and the median length of hospital stay was 29 days (IQR 16,53). There was a high mortality rate in those aged 70 years or older, with 4 out of 14 (29%) dying within 3 months of surgery.

Compared with Series C ($n = 36$), there was a statistically significant difference in median age between Series B and C (71 vs. 43 years old, $P < 0.0001$), as shown in [Figure 2](#). Patients with burns less than 20% TBSA (Series B) underwent significantly fewer procedures than those with larger burns in Series C (median: 2 vs. 6.5 procedures, $P < 0.0001$). Although patients in Series B had a smaller TBSA requiring healing, their median wound healing rate was slower than that of Series C (0.18 vs. 0.61 % TBSA healed per day, $P < 0.0014$).

Literature review

Of the 27 papers we reviewed, we found one randomized study, six retrospective cohort studies, sixteen case series, and four case reports. The sample sizes of these studies ranged from 1 to 175 patients. The majority ($n = 14$) focused exclusively on adults, while six examined only pediatric patients, and seven included both age cohorts. As noted in Introduction, a comprehensive review of the outcomes associated with the modified Meek technique for burn injuries has been recently published. The authors of that review noted the absence of evidence on the use of Meek for small burns^[27]. In our literature search, we identified five papers discussing the application of Meek in smaller TBSA injuries, one of which specifically explored its use in combination with Novosorb® Biodegradable Temporising Matrix (BTM)^[21,23-26]. Additionally, two studies evaluated the modified Meek technique in conjunction with an alternate dermal substitute, Integra® (Integra Life Sciences Corp., US), while another investigated its use with cultured epithelial allografts (CEA)^[5,13,22].

Our review focuses on key areas for future innovation with Meek: its application in small burns, its integration with dermal substitutes, and its impact on scar-related outcomes. A summary of the reviewed papers is presented in [Table 2](#). The studies included in the review varied in design and reported outcomes, leading to heterogeneity in the results. Consequently, not all columns in the table are applicable to every paper. WA “/” in the table denotes cases where a particular category does not apply to a given study.

DISCUSSION

When selecting skin graft techniques for patients with burn injuries, surgeons must consider multiple factors, from donor site availability and patient preference, to time to healing, and both aesthetic and functional outcomes. Innovative techniques such as Meek micrografting, and epidermal and dermal substitutes play important roles in determining the most suitable approach for each patient. Historically, there has been a general perception that the traditional Tanner meshed split-thickness skin graft produces superior aesthetic results compared to the Meek split-thickness skin graft. However, based on our experience, while the final appearance of Meek micrografts and meshed split-thickness grafts differs, neither technique is definitively superior. Further analysis of our patient series is currently ongoing to evaluate this observation in greater detail. One challenge associated with meshed grafts is that the actual expansion achieved does not correspond directly to the intended expansion ratio. In practice, the expansion is often significantly lower due to various factors, such as the loss of fragile graft pieces during meshing and the

Table 1. Summary of comorbidities of < 20% TBSA (Series B) patient cohort

Patient	Total comorbidities	Diabetes	Malignancy	Significant cardiac, respiratory, kidney disease (CKD 3b/4/5)	Other
1	1	N	N	N	Spinal injury
2	3	N	N	N	Chronic kidney disease, hypertension, cataracts
3	0	N	N	N	n
4	1	N	N	N	HTN
5	5	Y	N	N	Diabetic neuropathy, cataracts, HTN, hyperlipidemia
6	3	N	Y	N	Hypertension, stroke
7	1	N	N	N	arthritis
8	0	N	N	N	n
9	8	Y	N	MI, HFREF	Cataracts, hypertension, chronic kidney disease, peripheral neuropathy
10	1	N	N	N	stroke
11	3	Y	N	N	Hypercholesterolemia, hypertension
12	-	-	-	-	-
13	-	-	-	-	-
14	4	Y	N	MI	Chronic kidney disease, benign prostatic hyperplasia, hypercholesterolemia, hypertension
15	7	Y	N	N	Chronic kidney disease, benign prostatic hyperplasia, hypercholesterolemia, hypertension
16	4	Y	N	MI, HFREF	Hypercholesterolemia
17	3	Y	N	MI	Barrett's esophagus, pancreatitis, benign prostatic hyperplasia
18	6	Y	N	MI, HFREF	Tension headaches, visual impairment, hypertension
19	3	N	N	N	Bipolar, hypertension, hypothyroidism
20	1	N	N	N	depression
21	-	-	-	-	-
23	1	N	N	N	HTN
24	0	N	N	N	n
25	5	N	N	MI	Cyclical vomiting, anxiety, depression, hypertension
26	1	N	N	N	Mental health disorder
27	4	N	N	N	Atrial fibrillation, dementia, hypertension, osteoporosis

TBSA: Total body surface area; CKD: chronic kidney disease; HTN: hypertension; MI: myocardial infarction; HFREF: heart failure with reduced ejection fraction.

greater contractility of thicker split skin grafts^[29,30]. A key advantage of Meek is its ability to provide a precise calculation of the TBSA that can be covered by a donor site of a given size. For instance, a 20 cm × 20 cm donor site expanded at a 1:4 ratio can cover a 40 cm × 40 cm wound bed.

One potential drawback of Meek is the surgical time required. This paper does not specifically assess operative duration, while data from a previous series at our center demonstrated that the Meek technique, on average, required 17 min less than conventional meshed grafting in comparable patients with similar wound sizes.^[1] Additionally, published literature supports the observation that Meek grafting can reduce operative time.^[7,31] We acknowledge that there is a learning curve associated with this technique and that, in addition to this, its success depends on appropriate planning and staffing. We believe the reduced surgical time in our series is largely due to an optimized workflow: by harvesting the donor site at the beginning of the procedure, the primary surgeon can debride the burn wound while a trained colleague performs the

Table 2. Summary of literature review (Ordered by year of publication)

Author	Publication year	Study design	Journal	Number of patients	Age cohort (Adult/Pediatric/Both)	%TBSA	Comparator	Primary outcomes (Taken as first-listed outcome if no primary outcome stated)
Tapking et al. ^[21]	2024	Retrospective cohort study	<i>Journal of Clinical Medicine</i>	175	Adult	> 10%	BTM + Meek vs. BTM + meshed graft	BTM take rate in burns > 10%; STSG take rate
Craft-coffman et al. ^[5]	2024	Case series	<i>Burns Open</i>	15	Both	> 50%	/	Combined CEA + Meek take rate
Subramaniam et al. ^[14]	2023	Case report	<i>Polish Annals of Medicine</i>	1	Pediatric	52%	/	% take rate
Mishra et al. ^[11]	2022	Case series	<i>Burns Open</i>	11	Adult	< 20%	Tanner meshed graft	Operative time
Noureldin et al. ^[25]	2022	Randomized study	<i>Burns</i>	40	Pediatric	5%-40%	Meshed SSG	Observer scar assessment at three months
Hu et al. ^[9]	2021	Case series	<i>Journal of Burn Care & Research</i>	121	Adult	35%-76%	Poor skin quality group vs. good skin quality	Evaluate the impact of pre-op PNI on Meek prognosis
Gao et al. ^[8]	2021	Case report	<i>Journal of Burn Care & Research</i>	1	Adult	91%	/	Time to burn wound healing
Zhang et al. ^[2]	2021	Case series	<i>Journal of Burn Care & Research</i>	83	Adult	45.9%-82%	Poor skin quality group vs. good skin quality	Factors impacting Meek survival rate
Wu et al. ^[15]	2021	Retrospective cohort study	<i>Annals of Plastic Surgery</i>	24	Both	> 40%	CEA, Re-Cell, tanner mesh	Duration of hospitalization
Dahmardehei et al. ^[16]	2020	Retrospective cohort study	<i>World Journal of Plastic Surgery</i>	20	Adult	> 20%	/	Rate of graft rejection
Zajicek et al. ^[22]	2020	Case report	<i>Journal of Wound Care</i>	1	Pediatric	90%	Multi modalities. majority of TBSA covered with Integra - subsequent comparison between Integra + Meek vs. Integra + meshed STSG	Time to burn wound healing s
Houschyar et al. ^[32]	2019	Case series	<i>Plastic Surgery</i>	12	Adult	31%-77%	/	Mean length of stay
Lee and Halim ^[23]	2019	Retrospective cohort study	<i>Burns</i>	43	Both	10%-40%	SSG	Mean % graft take
Lee et al. ^[24]	2018	Case series	<i>Burn Surgery and Research</i>	12	Pediatric	15%-75%	/	Mean % graft take
Gao et al. ^[7]	2017	Retrospective cohort study	<i>Retrospective Cohort Study</i>	105	Adult	60%-98% with FT > 20%	Stamp graft; microskin grafting	% skin graft survival rate
Rode et al. ^[26]	2017	Case series	<i>Burns</i>	35	Pediatric	15%-86% (49% mean)	/	Mean length of stay
Almodumeeagh et al. ^[20]	2016	Case series	<i>International Wound Journal</i>	67	Adult	65% (50%-87%)	/	Graft viability post-op day 7-10
Medina et al. ^[31]	2016	Case series	<i>Burn Care & Research</i>	10	Adult	68%	/	Mean % TBSA requiring regrafting post Meek application

Munasinghe et al. ^[12]	2016	Case series	<i>Burns & Trauma</i>	11	Adult	20%-85%	/	Mean % graft take
Menon et al. ^[33]	2013	Case series	<i>Burns</i>	7	Pediatric	30%-70%	/	Mean number of surgical procedures
Danks and Lairet ^[18]	2010	Case report	<i>Journal of Burn Care and Research</i>	1	Adult	54%	/	Length of stay
Lumenta et al. ^[19]	2009	Case series	<i>Journal of Burn Care and Research</i>	10	Adult	> 60%	/	Time to heal
Hsieh et al. ^[17]	2008	Case series	<i>Burns</i>	37	Adult	40%-97%	/	% viability at POD 10
Papp and Härmä ^[13]	2003	Case series	<i>Burns</i>	3	Both	76%-92%	/	% re-epithelialization at 4 weeks post op
Lari and Gang ^[11]	2001	Case series	<i>Burns</i>	7	Both	50%-85%	/	% Graft take at POD7
Zermani et al. ^[16]	1997	Retrospective cohort study	<i>Burns</i>	5	Both	Average 35.6%	/	% graft <i>in situ</i> POD6
Kreis et al. ^[10]	1993	Case series	<i>Burns</i>	10	Both	43%-83%	/	Mean % take at one week

BTM: Biodegradable temporising matrix; CEA: cultured epithelial allografts; TBSA: total body surface area; SSG/STSG: split thickness skin graft; POD: post operative day; PNI: prognostic nutrition index.

micrografting, allowing both tasks to be completed concurrently and improving overall efficiency.

Meek for larger burns

The modified Meek technique for treating larger burns is well established^[6-8,12,14,15,27]. For large TBSA burns with limited donor site availability, the ability to cover as much area as possible, as quickly as possible, allows for larger burns to be treated with fewer procedures and a reduced need to re-crop donor sites. Reports show that the overall Meek take rates range from 60%-100%, with the time to healing varying from 7 to 90 days. In our cohort, the mean length of stay was 64 days, which is comparable to the literature range of 27 to 160 days, with a mean of 72.5 days^[2,7,9-11,13,16,19,22,24,25]. These studies included patients with varying ages, frailty, and comorbidities, so the wide range in length of stay is not necessarily reflective of the Meek itself.

Several papers have evaluated postoperative infection rates in Meek patients in comparison to those receiving meshed grafts. Although infection has been cited as a cause of graft failure,^[1,32,33] no statistically significant difference was found between the infection rates of the two cohorts^[2,6]. The same was true for the rate of colonization^[24]. In our experience, we have not observed a significantly elevated infection rate in patients receiving Meek grafts. However, data on this were not specifically collected as part of this series, and this represents an area for future focus. This opinion is shared by other researchers, including those conducting the ongoing inpatient Meek RCT, who have listed postoperative infection rates in their outcomes for evaluation^[8,34].

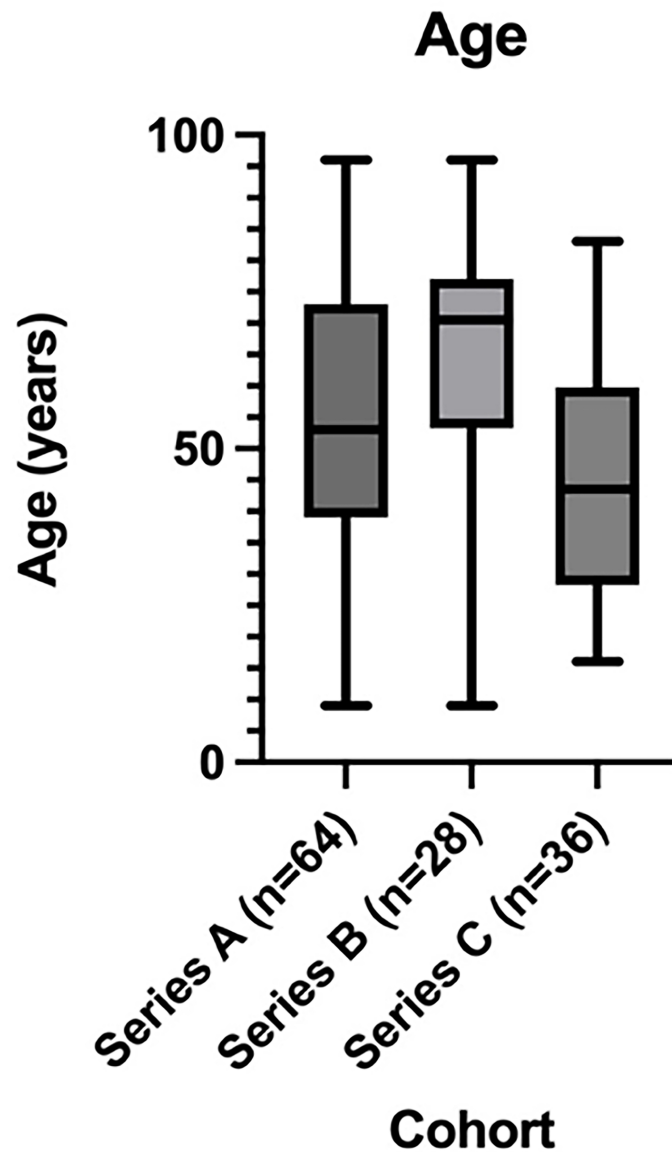


Figure 2. Box and whisker plot demonstrating medianage and interquartile range for each TBSA series. TBSA: Total body surface area.

Initially, the Meek technique was reserved for burns $\geq 70\%$ TBSA. However, our experience with Meek now leads us to regularly consider it as a first choice for any burns $\geq 40\%$ TBSA, which is increasingly supported in the literature^[6,32]. In our patients, a combination of 1:3 and 1:4 expansion rates allows us to cover the burn using a single cropped donor site in most of our larger cases. The donor site can be as small as 10% TBSA. This approach has the advantage of avoiding the need to wait for donor sites to be ready for re-cropping,

and it also requires less analgesia, as the burn is completely grafted sooner and the donor site is smaller. Furthermore, in the earlier stages, the Meek micrografts are covered with silk as a secondary dressing, making dressing changes more tolerable and reducing the need for general anesthesia. This results in fewer trips to the operating room for dressing changes, earlier mobilization, and earlier discharge. We are increasingly combining Meek with two-stage dermal substitutes, allowing some areas to be temporized and grafted at a later second stage when the neodermis has vascularized. This combination of Meek and a dermal matrix/scaffold or other cell-based technologies such as CEA is gaining increasing interest^[5,8,15]. The early outcomes of long-term scarring are encouraging.

In our practice, we are seeing that the combination of Meek and a dermal regeneration template allows for a robust reconstruction. These scars are less prone to contracture, with more elastic and pliable results compared to Meek on a full-thickness wound bed. Our scar outcomes are comparable to those of conventional meshed grafts with the same dermal templates; however, our present series is too small to have statistical significance. A large series published by Tapping *et al.* in 2024 included 175 patients treated at a German burns center. All patients with burns greater than 10% TBSA received Novosorb[®] BTM, followed by skin grafting using various techniques, including standard meshing and Meek. Of the 24 Meek patients, the mean TBSA was 47.9% +/- 19%, with a mean take of 80.7 (+/-21.1%) at 10 days, which was not significantly different to the BTM + traditional meshed graft patients^[21].

Two other studies have evaluated the use of Integra for these injuries in a total of four patients, with injury size ranging from 76% to 92%^[13,22]. Of the four patients, three had initial application of Integra[®] followed by Meek at a subsequent date, and one received a combination of Integra[®] and a traditional meshed graft in some anatomical areas, and Integra[®] with Meek in others. For the latter patient, the Integra[®] and traditional mesh combination led to an 85% healing rate at 2-3 weeks, while the Integra[®] and Meek combination resulted in 45% healing at 2-4 weeks, ultimately requiring subsequent regrafting with meshed STSG in areas with ongoing issues^[22]. The other three patients also reported varying degrees of healing, with one showing 75% re-epithelialization seen at four weeks, while another required a subsequent meshed graft due to infection-related loss of Meek^[13].

The concept of overgrafting split-thickness skin graft donor sites has been documented in the literature, with the earliest mention by Thompson in 1960^[35]. The aim of this practice is to reduce donor site healing time, thereby decreasing the risk of morbidity, including donor site infection and hypertrophic scarring^[36]. We have used Meek to overgraft donor sites when Meek is also used to graft the burn, primarily in patients who may struggle with donor site healing, such as the very elderly or those with very large burns. There is currently limited literature on the possible benefits of overgrafting donor sites with Meek, and we are still evaluating our results - the practice was only mentioned in one Meek-related paper, which did not specifically address the outcome^[33].

Meek for smaller burns

We believe that the Meek technique is a valuable option for patients with smaller TBSA burns, particularly in the elderly or comorbid patients at risk of poorer wound healing. In these patients, reducing donor size and subsequently overgrafting the donor sites can help reduce healing time and pain - both factors known to limit mobility and prolong the rehabilitation period. Additionally, in patients who are not fit for general

anesthetic, the reduced donor site required allows procedures to be performed under local anesthesia, which would otherwise be intolerable without general anesthetic.

At present, there is no strong published evidence supporting the use of Meek for burns < 20% TBSA. However, an ongoing inpatient randomized controlled trial in the Netherlands is evaluating the outcomes of Meek micrografting *vs.* mesh grafting for deep dermal/full-thickness burn injuries < 20% TBSA. This study aims to reduce interpatient and wound variability by using both techniques on the same patient with two wounds of similar depth, size, and location^[34]. We eagerly await the results of this trial.

It is also worth noting that although the majority of papers focus on the modified Meek technique in adults, it has also been successfully used in pediatric patients. A total of eleven studies present outcomes for pediatric patients with TBSA ranging from 5% to 92%, with time to satisfactory healing varying from 7 to 28 days^[5,10,11,13-16,22,25,26]. One study that randomized 40 pediatric patients to either Meek or traditional meshed grafts found that Meek grafts had a higher graft take rate than meshed skin grafts [84.25% (60-100) *vs.* 71.5% (20-95)], with a shorter mean time to epithelialization [Meek 27.11 (14-70) days *vs.* Mesh: 33.5 (16-100) days]. Additionally, the Meek patient group showed more favorable POSAS scores, both for the patient (Meek mean 3.17, mesh mean 4.2) and observer (Meek mean 2.89, mesh mean 4.1). All these outcomes were statistically significant^[25]. Minimizing donor sites in children is important, particularly as younger children have a tendency to develop pathological scarring, which can lead to prolonged morbidity in the future^[37].

In our series of 64 patients, we evaluated the role of the modified Meek technique for burn patients with a range of TBSAs. We emphasize the importance of considering this technique, which is already accepted for larger burn injuries, for patients with < 20% TBSA burns. The Meek technique allows for smaller donor sites and promotes safe, effective, and timely wound healing, using the same expansion ratio as conventional meshed grafts. Furthermore, the secondary silk dressing reduces the risk of wound desiccation, a common issue with conventional skin grafts at higher expansion rates.

We have summarized the current published evidence on the use of the modified Meek technique and discussed innovations and developments based on our series, including the combination of Meek with a dermal substitute to achieve robust reconstructions with improved aesthetic and functional outcomes.

Our study has limitations. We focus on novel applications of Meek, such as for smaller burns and in combination with dermal templates. Due to the relatively recent introduction of Meek in these areas, our sample sizes for these cohorts are correspondingly smaller. Additionally, as our center began collecting POSAS data only from the second half of the study, the sample size for the data ($n = 13$) was limited. We continue to build upon these cohorts, which will help further strengthen the validity of future research.

Meek is emerging as a safe and easily effected technique not only for massive burns injuries, but also for smaller TBSA burns, in both adults and children, with and without dermal regeneration templates and spray cell technologies. We anticipate seeing Meek gain popularity for treating smaller TBSA burns, in combination with dermal templates and keratinocyte cells, and look forward to more evidence supporting overgrafting of donor sites with Meek.

DECLARATIONS

Authors' contributions

Made substantial contributions to the design of the study and performed data analysis, review of literature and interpretation: Wilson E

Performed data acquisition, analysis and design of supporting figures and tables: Grant M

Performed data acquisition and review of literature, as well as providing administrative, technical, and material support: Fleet M

Performed data acquisition: Lee M

Made substantial contributions to the conception and design of the study, review of all data, results of evidence review and manuscript: Jones I

Availability of data and materials

The data supporting this work are provided in the text. Additional raw data will be made available by the corresponding authors upon reasonable request.

Financial support and sponsorship

Wilson E, Grant M, Fleet M, and Jones I have presented the data at the Humeca ISBI Meek Summit 2024, with transport funding from Humeca. They have received no financial support or sponsorship specific to the collection of data for this project and the formation of this publication.

Conflicts of interest

All authors declared that there are no conflicts of interest.

Ethical approval and consent to participate

This work, conducted within the National Health Service (NHS), is classified as quality improvement rather than research and, therefore, does not require ethical committee review.

Consent for publication

Not applicable.

Copyright

© The Author(s) 2025.

REFERENCES

1. Mishra A, Rabiee S, Opel S, Jones I. Applying the modified Meek technique to heal smaller burns: a retrospective review. *Burns Open*. 2022;6:120-4. [DOI](#)
2. Zhang P, Wang W, Hu G, et al. A retrospective study of factors influencing the survival of modified Meek micrografting in severe burn patients. *J Burn Care Res*. 2021;42:331-7. [DOI](#) [PubMed](#)
3. MEEK CP. Successful microdermagrafting using the Meek-Wall microdermatome. *Am J Surg*. 1958;96:557-8. [DOI](#) [PubMed](#)
4. Ottomann C, Hartmann B, Branski L, Krohn C. A tribute to Cicero Parker Meek. *Burns*. 2015;41:1660-3. [DOI](#) [PubMed](#)
5. Craft-coffinan B, Homsombath B, Cramer C, et al. CEA graft take after combining with a modified MEEK procedure. *Burns Open*. 2024;8:23-8. [DOI](#)
6. Dahmardehei M, Vaghardoost R, Saboury M, et al. Comparison of modified Meek technique with standard mesh method in patients with third degree burns. *World J Plast Surg*. 2020;9:267-73. [DOI](#) [PubMed](#) [PMC](#)
7. Gao G, Li W, Chen X, et al. Comparing the curative efficacy of different skin grafting methods for third-degree burn wounds. *Med Sci Monit*. 2017;23:2668-73. [DOI](#) [PubMed](#) [PMC](#)
8. Gao X, Zhang M, Lin Y, Li D, Zhang L. Combined complex skin repair in patient with extensive burns: a case report. *J Burn Care Res*. 2021;42:1053-6. [DOI](#) [PubMed](#)
9. Hu G, Yuan L, Peng Y, Luo G, Song H. Predictive value of the prognostic nutrition index for the prognosis of patients with severe burns treated with the Meek graft. *J Burn Care Res*. 2021;42:448-53. [DOI](#) [PubMed](#)
10. Kreis RW, Mackie DP, Vloemans AW, Hermans RP, Hoekstra MJ. Widely expanded postage stamp skin grafts using a modified Meek technique in combination with an allograft overlay. *Burns*. 1993;19:142-5. [DOI](#) [PubMed](#)
11. Lari AR, Gang RK. Expansion technique for skin grafts (Meek technique) in the treatment of severely burned patients. *Burns*. 2001;27:61-6. [DOI](#) [PubMed](#)
12. Munasinghe N, Wasiak J, Ives A, Cleland H, Lo CH. Retrospective review of a tertiary adult burn centre's experience with modified Meek grafting. *Burns Trauma*. 2016;4:6. [DOI](#) [PubMed](#) [PMC](#)

13. Papp A, Härmä M. A collagen based dermal substitute and the modified Meek technique in extensive burns. Report of three cases. *Burns*. 2003;29:167-71. [DOI](#) [PubMed](#)
14. Subramaniam S, Rodzaian WS, Yusof SJ, Ibrahim S, Hayati F. Multimodal management of more than 50% mixed deep dermal and full thickness burns in a child. *Pol Ann Med*. 2023;30:144-8. [DOI](#)
15. Wu CJ, Li JJ, Liao WC, et al. Using various skin graft techniques in major burn reconstruction: a lesson learned from a taiwanese cornstarch explosion. *Ann Plast Surg*. 2021;86:S30-4. [DOI](#) [PubMed](#)
16. Zermani RG, Zarabini A, Trivisonno A. Micrografting in the treatment of severely burned patients. *Burns*. 1997;23:604-7. [DOI](#) [PubMed](#)
17. Hsieh CS, Schuong JY, Huang WS, Huang TT. Five years' experience of the modified Meek technique in the management of extensive burns. *Burns*. 2008;34:350-4. [DOI](#) [PubMed](#)
18. Danks RR, Laird K. Innovations in caring for a large burn in the Iraq war zone. *J Burn Care Res*. 2010;31:665-9. [DOI](#) [PubMed](#)
19. Lumenta DB, Kamolz LP, Frey M. Adult burn patients with more than 60% TBSA involved-Meek and other techniques to overcome restricted skin harvest availability--the Viennese concept. *J Burn Care Res*. 2009;30:231-42. [DOI](#) [PubMed](#)
20. Almodumeeagh A, Heidekrueger PI, Ninkovic M, Rubenbauer J, Hadjipanayi E, Broer PN. The MEEK technique: 10-year experience at a tertiary burn centre. *Int Wound J*. 2017;14:601-5. [DOI](#) [PubMed](#) [PMC](#)
21. Tapking C, Panayi AC, Hundeshagen G, et al. The application of a synthetic biodegradable temporizing matrix in extensive burn injury: a unicenter experience of 175 cases. *J Clin Med*. 2024;13:2661. [DOI](#) [PubMed](#) [PMC](#)
22. Zajicek R, Kubok R, Petrova N, Tokarik M, Matouskova E, Gal P. Complex approach to skin repair in an extensively burned child: a case study. *J Wound Care*. 2020;29:458-63. [DOI](#) [PubMed](#)
23. Lee SZ, Halim AS. Superior long term functional and scar outcome of Meek micrografting compared to conventional split thickness skin grafting in the management of burns. *Burns*. 2019;45:1386-400. [DOI](#) [PubMed](#)
24. Lee SZ, Halim AS, Wan Sulaiman WA, Mat Saad AZ. Outcome of the modified Meek technique in the management of major pediatric burns. *Ann Plast Surg*. 2018;81:295-301. [DOI](#) [PubMed](#)
25. Noureldin MA, Said TA, Makeen K, Kadry HM. Comparative study between skin micrografting (Meek technique) and meshed skin grafts in paediatric burns. *Burns*. 2022;48:1632-44. [DOI](#) [PubMed](#)
26. Rode H, Martinez R, Potgieter D, Adams S, Rogers AD. Experience and outcomes of micrografting for major paediatric burns. *Burns*. 2017;43:1103-10. [DOI](#) [PubMed](#)
27. Rijpma D, Claes K, Hoeksema H, et al. The Meek micrograft technique for burns; review on its outcomes: searching for the superior skin grafting technique. *Burns*. 2022;48:1287-300. [DOI](#) [PubMed](#)
28. van de Kar AL, Corion LU, Smeulders MJ, Draaijers LJ, van der Horst CM, van Zuijlen PP. Reliable and feasible evaluation of linear scars by the patient and observer scar assessment scale. *Plast Reconstr Surg*. 2005;116:514-22. [DOI](#) [PubMed](#)
29. Kamolz L, Schintler M, Parvizi D, Selig H, Lumenta DB. The real expansion rate of meshers and micrografts: things we should keep in mind. *Ann Burns Fire Disasters*. 2013;26:26-9. [PubMed](#) [PMC](#)
30. Pripotnev S, Papp A. Split thickness skin graft meshing ratio indications and common practices. *Burns*. 2017;43:1775-81. [DOI](#) [PubMed](#)
31. Medina A, Riegel T, Nystad D, Tredget EE. Modified Meek micrografting technique for wound coverage in extensive burn injuries. *J Burn Care Res*. 2016;37:305-13. [DOI](#) [PubMed](#)
32. Houschyar KS, Tapking C, Nietzsche I, et al. Five years experience with Meek grafting in the management of extensive burns in an adult burn center. *Plast Surg*. 2019;27:44-8. [DOI](#) [PubMed](#) [PMC](#)
33. Menon S, Li Z, Harvey JG, Holland AJ. The use of the Meek technique in conjunction with cultured epithelial autograft in the management of major paediatric burns. *Burns*. 2013;39:674-9. [DOI](#) [PubMed](#)
34. Rijpma D, Pijpe A, Claes K, et al. Outcomes of Meek micrografting versus mesh grafting on deep dermal and full thickness (burn) wounds: study protocol for an intra-patient randomized controlled trial. *PLoS One*. 2023;18:e0281347. [DOI](#) [PubMed](#) [PMC](#)
35. THOMPSON N. A clinical and histological investigation into the fate of epithelial elements buried following the grafting of "shaved" skin surfaces based on a study of the healing of split-skin graft donor sites in man. *Br J Plast Surg*. 1960;13:219-42. [DOI](#) [PubMed](#)
36. Gorman J, Kraft CT, Fagan S, Levi B. Back Grafting the split-thickness skin graft donor site. *J Burn Care Res*. 2017;38:e443-9. [DOI](#) [PubMed](#) [PMC](#)
37. Wallace HJ, Fear MW, Crowe MM, Martin LJ, Wood FM. Identification of factors predicting scar outcome after burn injury in children: a prospective case-control study. *Burns Trauma*. 2017;5:19. [DOI](#) [PubMed](#) [PMC](#)