

Review

Open Access



# Correction and prevention of tip asymmetries, bossae, and alar retraction

Nicholas R. Randall, Lazaro R. Peraza, Grant S. Hamilton III

Department of Otolaryngology, Head & Neck Surgery, Mayo Clinic, Rochester, MN 55905, USA.

**Correspondence to:** Dr. Grant S. Hamilton III, Department of Otolaryngology - Head and Neck Surgery, Mayo Clinic, 200 1st St SW, Rochester, MN 55905, USA. E-mail: hamilton.grant@mayo.edu

**How to cite this article:** Randall NR, Peraza LR, III GSH. Correction and prevention of tip asymmetries, bossae, and alar retraction. *Plast Aesthet Res* 2024;11:18. <https://dx.doi.org/10.20517/2347-9264.2023.115>

**Received:** 13 Nov 2023 **First Decision:** 24 Apr 2024 **Revised:** 9 May 2024 **Accepted:** 21 May 2024 **Published:** 29 May 2024

**Academic Editors:** Stefano Gentileschi, Paolo Boffano **Copy Editor:** Yanbing Bai **Production Editor:** Yanbing Bai

## Abstract

Secondary rhinoplasty to address complications from initial surgical intervention is a technically challenging operation. Common aesthetic complications that plague patients after primary rhinoplasty include nasal tip asymmetries, bossae, and alar retraction. These adverse outcomes are usually a result of over-manipulation and/or over-excision of native cartilage and are especially prevalent in patients with thick lower lateral cartilages and thin nasal skin. Techniques to minimize tissue handling, maintain natural nasal anatomic support and structure, and soften sharp edges from cartilage grafts or incisions are all essential in the prevention of nasal tip irregularities. In addition to prevention, there are many operative and procedural interventions to correct tip asymmetries, bossae, and alar retraction. These interventional corrections include varying cartilage and/or fascial grafts, camouflaging of previously performed grafts, and repositioning of the alar cartilage.

**Keywords:** Secondary rhinoplasty, complications, bossae, nasal tip asymmetry, alar retraction

## INTRODUCTION

Rhinoplasty is a complex operation referred to as the “queen of facial plastic surgery”<sup>[1]</sup>. Patients often seek rhinoplasty for a myriad of reasons, often driven by aesthetic aspirations, traumatic deformities, dissatisfaction with previous surgical outcomes, or the development of a new deformity after the initial surgery<sup>[2]</sup>.



© The Author(s) 2024. **Open Access** This article is licensed under a Creative Commons Attribution 4.0 International License (<https://creativecommons.org/licenses/by/4.0/>), which permits unrestricted use, sharing, adaptation, distribution and reproduction in any medium or format, for any purpose, even commercially, as long as you give appropriate credit to the original author(s) and the source, provide a link to the Creative Commons license, and indicate if changes were made.



Differences in the nasal tip, a major subunit of the nose, can result in significant nasal obstruction and noteworthy undesirable nasal shape and appearance. As such, the intricacies of nasal tip surgery lie in its dual requirement of fulfilling aesthetic desires while preserving or enhancing nasal function. The delicate balance between these objectives necessitates a thorough understanding of the underlying anatomical structures and their interplay. Historically, ablative techniques incorporating reduction or division of the osseocartilaginous framework were used<sup>[2]</sup>. However, in recent years, there has been a shift toward preserving natural nasal anatomy. This has been achieved through cartilage-sparing techniques and by augmenting areas that lack volume in order to correct irregularities in shape and provide additional support<sup>[3]</sup>. The functional importance and aesthetic prominence of the nasal tip, therefore, warrants significant consideration before, during, and following any rhinoplasty. Whether through tip enhancement, reduction, or simply ensuring that tip support is maintained, every surgical approach to the nose must address the nasal tip.

Support for the nasal tip consists of the structure, shape, and attachments of the cartilage and soft tissue structures that are housed therein - namely the bilateral lower and upper lateral cartilages and the nasal septum. The complexity of the nasal tip support structures is reflected in the challenging, though rewarding, undertaking of tip reduction, enhancement, or repair. As the approach to the nasal tip is varied and intricate, nasal tip surgery is fraught with challenges. The pursuit of ideal nasal tip aesthetics can give rise to postoperative deformities such as nasal tip asymmetries, bossae, and alar retraction. These are all well-documented complications that can occur as a result of over-resection of the tip cartilages or failure to support weakened lower lateral cartilages during rhinoplasty. This lack of support can have negative consequences, both in the appearance of the nose, and the patency of the external and internal nasal valves. Over the years, many techniques have been refined to address these complex nasal tip complications, each with its distinctive set of advantages, limitations, and learning curves. This review outlines the most common causes, prevention strategies, and treatment approaches to these prevalent rhinoplasty nasal tip complications. By delving into a thorough assessment of academic literature, this review aims to provide a comprehensive understanding that may steer surgeons toward making informed decisions during surgical planning and execution, ultimately elevating patient outcomes and satisfaction in nasal tip surgery.

## METHODS

A comprehensive literature review was conducted to identify relevant data previously published on the causes, prevention, and treatment of nasal tip asymmetry, nasal bossae, and alar retraction. PubMed/MEDLINE database was searched using the following terms in multiple combinations: Rhinoplasty, asymmetry, rhinoplasty complications, nasal tip, nasal bossae, alar retraction, revision rhinoplasty, secondary rhinoplasty, and postoperative complications. Results from the past 30 years were included. This search yielded 194 results. Non-English articles were excluded. Two of the authors separately reviewed the results of the search for articles that focused on the pertinent nasal tip complications for inclusion in this review.

## RESULTS

A total of 66 articles were identified that offered high-quality data pertaining to the causes, prevention, and/or treatment of nasal tip asymmetry, nasal bossae, and alar retraction. The potential causes, techniques for prevention, and strategies for the management of these potential rhinoplasty complications will be reviewed individually.

### Nasal tip asymmetry

Nasal tip asymmetry can be defined as any noticeable difference between sides in the shape, size, or orientation of the nasal tip. While the nasal tip can certainly demonstrate natural asymmetry, prominent tip asymmetries are typically due to previous rhinoplasty. When performing revision rhinoplasty for tip asymmetry, it is common to find that the causes of such asymmetries were irregularly shaped or placed grafts, asymmetric and unequal cartilage excisions, and unbalanced suture correction of the lower lateral cartilages. Scar contracture and thin skin can also reveal asymmetries that were not readily apparent at the time of surgery. Sutures can also create unequal tension that will result in asymmetry, not necessarily intraoperatively, but months to years after surgery.

It is estimated that as many as 29% of patients seeking revision rhinoplasty note tip asymmetry as a major motivator for seeking secondary surgery<sup>[4]</sup>. Patients who have undergone revision rhinoplasty are more likely to be perceived as having an asymmetric nose compared to those who have only undergone primary rhinoplasty<sup>[5]</sup>. This finding illustrates the necessity of careful planning and the level of complexity faced when approaching nasal asymmetry correction with revision rhinoplasty.

### Prevention

Given that various seemingly minor variations in technique can cause noticeable tip asymmetries, it is essential to carefully plan and meticulously perform all maneuvers that will affect nasal tip shape.

Any graft used in correction or support of the nasal tip can potentially contribute to nasal asymmetry if not properly placed or shaped. Correct placement and careful consideration of smoothing cartilage edges, especially in patients with thin skin, can help prevent nasal tip asymmetries. Shield grafts are sometimes used to help project and contour the nasal tip, but irregularly shaped shield grafts can cause a noticeable asymmetry in the nasal tip. Lateral crural grafts can help to smooth the edges of a shield graft, making them less noticeable. Using a curved piece of cartilage for the shield graft can help to preserve the infratip lobule<sup>[6]</sup>.

Various materials and grafts can be used to help mask the firm, irregular edges of cartilage grafting that may contribute to nasal tip asymmetry. Perichondrium from either the ear or rib can be used to cover cartilage grafts to help smooth sharp edges and fill up empty spaces from previous rhinoplasty. In a case series of 62 patients, Bocchieri *et al.* demonstrated the successful use of perichondrial graft harvested together with conchal cartilage to be used during revision rhinoplasty for the correction of nasal tip asymmetries<sup>[7]</sup>. Other autologous grafting material can also be used depending on surgeon or patient preference to cover and camouflage nasal tip reconstructions such as postauricular soft tissue, temporalis fascia, or fascia lata<sup>[8,9]</sup>. AlloDerm (AbbVie - North Chicago, Illinois, USA) has been used in the past for smoothing out the edges of cartilage grafts to prevent asymmetries, but the resorption rate has been found to be significant, and this has fallen out of favor<sup>[10]</sup>.

### Correction

Tip asymmetries can be due to an unwanted tip shape such as a boxy or overly rounded tip. In patients undergoing revision rhinoplasty, these tip abnormalities are more frequently caused by malpositioned, rather than orthotopic, lower lateral crura. Consequently, these tip asymmetries can be addressed via lateral crural repositioning or reconstruction with or without lateral crural strut grafts<sup>[11]</sup>.

One strategy to reduce the delayed appearance of cartilage graft edges and asymmetries after postoperative edema has resolved, is to create a soft, moldable cartilage graft. This has been achieved through a diversity of described techniques, which include dicing, or finely mincing cartilage and then wrapping it in fascia or

another tissue to create a moldable graft<sup>[12]</sup>. Erol has termed his specific technique as “Turkish Delight”, in which he wraps his thinly diced cartilage in Surgicel, so that the mold can better adapt to adjacent and enveloping tissues<sup>[13]</sup>. More recently, Tasman described using diced cartilage in tissue glue<sup>[14]</sup>. It is important to recognize that some common cartilage softening techniques are destructive to chondrocytes and can diminish the long-term viability of the grafts<sup>[15]</sup>. Crushing and shaving are most likely to damage the cellular structure of the cartilage<sup>[15]</sup>.

Bracaglia *et al.* were able to correct nasal tip asymmetry in 18/20 revision rhinoplasty patients via the use of a rainbow graft<sup>[16]</sup>. This graft is explained in more detail as a method of correction of alar retraction.

Often, the nasal tip can appear asymmetric due to weak or unsupported lower lateral cartilages. A columellar strut graft, while frequently used for tip projection, can also be used as an anchoring point for weakened lower lateral cartilages. This can help to strengthen and support the structure of the nasal tip and correct the asymmetry of the lower lateral cartilages<sup>[3,17,18]</sup>. The septal extension graft is another graft typically used for tip support that can also help strengthen weak lower lateral cartilages and correct asymmetry by creating a more solid foundation<sup>[19,20]</sup>. Both the columellar strut graft and the septal extension graft, if not placed or shaped appropriately or covered with further grafting or other material, can cause nasal tip asymmetry.

### Nasal bossae

Bossa is a Latin synonym of massa for “lump” or “bump”, with bossae being the plural form. True to their nomenclature, nasal bossae are sharp “knob-like” bumps of the lower lateral cartilage that can alter the external appearance of the nose. Bossae can occur as natural asymmetries of the lower lateral cartilages, though they are most frequently seen in the setting of previously performed surgery. Previous reviews have demonstrated that bossae may be present in as many as 3%-5% of patients who have undergone primary rhinoplasty<sup>[5,21,22]</sup>. As a surgical complication, bossae are thought to form from sharp, irregular cartilage edges that undergo scar contracture and form a pointed bump<sup>[23]</sup>.

The timing of bossae determines size, structure, and difficulty in treating. Earlier bossae are usually simple irregularities in the cartilage that are appreciable through thin skin. Late bossae can form because of fibrosis or scar contracture of sharp cartilage and adjacent tissues. There have been some suggestions in the past of delaying bossae treatment until the irregularity is “fully declared”. However, bossae are unlikely to improve with time, and leaving them to develop typically leads to more scar formation, resulting in a more difficult correction, so it is suggested that these be addressed without any unnecessary delay<sup>[24]</sup>.

### Prevention

Bossae can be more noticeable in patients with thin skin over the nasal tip and thick lower lateral cartilages. Surgical technique that minimizes trauma and unnecessary manipulation, while always worth practicing, is especially important to use in these patients given their propensity to develop noticeable bossae.

Intralobular bifidity, defined as a widened interdomal distance, has been suggested as a significant risk factor for bossae formation because of the possibility of the domes becoming “knuckled”, which can lead to bossa formation<sup>[25]</sup>. Some authors suggest that vertical dome division techniques may present the risk of bossae formation<sup>[26]</sup>, though this is controversial<sup>[21]</sup>. Many surgeons advocate for the reapproximation of the lower lateral cartilages with sutures to help prevent the widening of the domes to prevent bossa formation<sup>[6,24]</sup>.

Cuts that create sharp cartilage edges, especially edges that face the external nasal skin, should be avoided. These sharp edges on grafts or native cartilage can be smoothed out intraoperatively to help prevent bossae formation, with care to not over-resect cartilage and sacrifice structural integrity in favor of smoothing out cartilage edges. Any maneuver that can cause the lower lateral cartilages to weaken and buckle, such as over-resection, can lead to bossae formation<sup>[6,24]</sup>.

Surgical approaches that are more invasive, such as delivery via marginal and intercartilaginous incisions, are typically associated with more disruption of planes and handling of tissue that can increase the risk of bossae formation. Nondelivery approaches are less disruptive, but also have the disadvantage of not being able to easily address some deformities such as an increased interdomal width. The external approach allows for better visualization and may make it easier to ensure symmetry and smooth or covered cartilage edges to help prevent bossae formation<sup>[24]</sup>. During a primary rhinoplasty, the soft cartilage from a conservative cephalic trim can be used to camouflage potentially visible cartilage edges. Other camouflage materials such as soft tissue, perichondrium or diced cartilage can also be used.

### *Correction*

Properly addressing bossae surgically necessitates the complete separation of a bossa from the attached soft tissue via undermining. This releases the scar and fibrous attachment that have helped to form the deformity and allows the cartilage irregularity to be addressed. Bossae can be carefully trimmed with careful suture reconstruction of the lower lateral cartilages<sup>[21]</sup>. Shaving down or complete excision of the bossa has been suggested in the past<sup>[27,28]</sup>, but this has fallen out of favor due to the risk of weakening the underlying cartilage, which may lead to further complications or even recurrent bossa formation<sup>[24]</sup>. However, excision and reinforcement is a viable alternative. Covering materials used to camouflage the bossae, similar to those previously discussed regarding tip asymmetries, can be used to help address bossae as well. These materials can include fascia, perichondrium, or other soft tissue.

Injection of fillers into the nose over the top of bossae can help reduce the noticeability of sharp, asymmetric edges or irregularities in the nose. However, injection of fillers can lead to further asymmetry of the shape of the nose and carry the inherent risk of filler injection such as embolization and over-injection<sup>[29]</sup>. Additionally, it does not treat the underlying deformity and with any resorption of filler injection, the deformity will again become noticeable, providing only a temporary fix. In addition, fillers placed in the nose tip have resulted in infection, discoloration, skin necrosis<sup>[30]</sup>, blindness<sup>[31]</sup> and granuloma formation<sup>[32]</sup>. The risk of adverse events with nasal filler injections may also increase in post-rhinoplasty patients<sup>[33]</sup>.

### **Alar retraction**

Excessive resection of the lower lateral cartilages can lead to alar retraction, an abnormal elevation of the mid-portion of the lower lateral cartilage that can give the appearance of perpetually flared nostrils. When viewing the profile of the nose, alar retraction also results in excessive columellar show. As many as 28% of patients undergoing resection of the lateral crus will suffer from unfavorable alar retraction<sup>[34]</sup>. Alar retraction has been documented as the most common complication of rhinoplasty in the Asian nose, so special consideration for the management of the lower lateral cartilages should be given to patients of Asian ethnicity<sup>[35]</sup>.

Alar retraction can also violate the appropriate function of the external nasal valve, causing dynamic nasal obstruction. The prevention and treatment of lower lateral cartilage malpositioning can improve aesthetics as well as nasal breathing<sup>[36]</sup>. It is possible to improve the patency of the nose without detrimentally affecting

the appearance<sup>[35]</sup>.

### Prevention

Surgical etiologies of alar retraction include excessive resection of the lower lateral cartilage, improperly placed sutures to manipulate the shape of the lower lateral cartilage, and contracture due to scarring. When performing trimming of the lower lateral cartilage, it has historically been suggested that leaving at least 6-10 mm in width to an intact strip of lateral crus would help to prevent alar retraction and preserve shape. In current practice, surgeons are preserving more of the lateral crus and are using structural techniques<sup>[37]</sup> or lateral crural tensioning<sup>[38]</sup> to reshape convex lateral crura instead of resecting a large cephalic trim [Figure 1]. The degree of cephalic resection and subsequent rotation has been shown to relate to the severity of alar retraction following surgery<sup>[39]</sup>.

When considering the necessity of cephalic resection, simple repositioning of the lower lateral cartilages may be an effective alternative and has been shown to result in a significant lowering of the alar rim even without additional grafting<sup>[40]</sup>. To ensure that the function of the external nasal valve remains intact with repositioning of the lower lateral cartilage, it can be helpful to draw a line that represents the long axis of the lateral crus. For optimized external nasal valve function, this long axis should point at the lateral canthus when secured in the corrected position<sup>[41]</sup>.

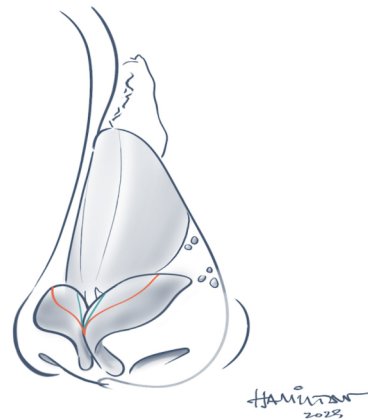
Appropriate handling and manipulation of the soft tissue and vestibular skin overlying the lower lateral cartilages is also essential in preventing alar retraction. Because the soft tissue envelope is comprised of skin, subcutaneous fat, and the superficial musculoaponeurotic system (SMAS), its thickness can vary between patients<sup>[42]</sup>. While a healthy soft tissue envelope may be freely mobile in many cases, patient age, gender, ethnicity, and prior trauma or surgery may impact its general laxity<sup>[42,43]</sup>. These variables may impact the soft tissue envelope in which the alar cartilage is contained and may not always be amenable to stretching. This restriction can even result in minimal scar contracture from surgical intervention, leading to appreciable alar retraction. The pyriform ligament, attaching the pyriform rim to the lower lateral cartilage, must also be considered, and usually released, when approaching malpositioned crura in need of repositioning or grafting<sup>[44]</sup>.

Alar contour grafts are often thought of as a first line in correcting alar deformities but can also be an effective method of preventing this complication in patients who are at high risk for alar retraction. In a controlled retrospective study comparing patients who received alar contour grafts and those who did not in primary rhinoplasty, Unger *et al.* not only found significantly reduced rates of alar retraction in the alar contour graft group, but also found improved alar aesthetics in general<sup>[45]</sup>. Additionally, there was no complication in this series associated with graft placement, suggesting that alar contour grafting may be a low-risk option during primary rhinoplasty to not only prevent alar retraction, but also to improve the aesthetic appearance of the nasal ala.

### Correction

Every rhinoplasty surgeon should have a repertoire of lower lateral cartilage grafts that can be employed to address alar retraction. The shape of the lower lateral cartilages, the severity of the retraction, and the availability of donor cartilage may all influence which type of grafting is used to correct alar retraction. When placing lower lateral cartilage grafts, it is helpful to create a dissection pocket to hold the graft that is closer to the vestibular skin than the external skin, which may help to prevent the graft from becoming visible externally or displacement of soft tissue into the vestibule<sup>[37]</sup>. Regardless of the type of graft used, both the form and function of the nose need to be considered with any manipulation or adjustment of the size,





**Figure 1.** Historical guidance was to leave a minimum of 6 mm of width (orange lines) to the lateral crus after performing a cephalic trim. This type of trim can leave a structural void between the upper and lower lateral cartilages, leading to alar retraction. It can also sufficiently weaken the cartilage longitudinally, predisposing to buckling of the cartilage and bossa formation. The senior author prefers a more medially placed cephalic trim, which preserves most of the structural integrity of the lateral crura (blue lines). This type of trim will permit reorienting the short axis of the lateral crus, flattening its shape and decreasing the volume in the supratip, moving the supratip break closer to the tip defining point.

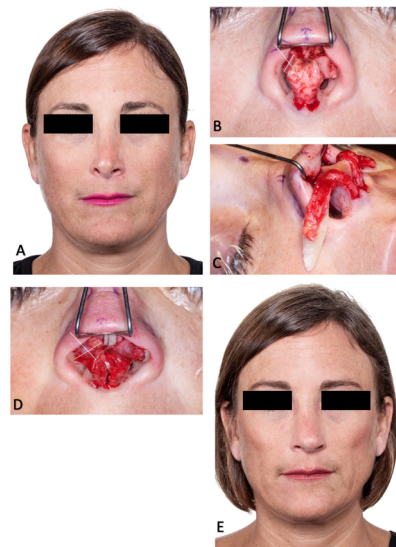
shape, or position of the lower lateral cartilages.

Already mentioned in the setting of prevention, a common “workhorse” for correction of mild alar retraction is the alar contour graft. Alar contour grafts consist of a thin, 2-3 mm strip of cartilage that is used to reinforce and reshape the caudal edge of the lower lateral cartilage where the retraction has occurred. However, this graft may not be as effective in treating more severe notching or in a case with significant scarring, leading Boahene *et al.* and Rohrich *et al.* to suggest against its use in these scenarios<sup>[46,47]</sup>.

For mild retraction in the setting of weak lower lateral cartilages, an alar batten graft can be used to help strengthen shape. This can be used in both treatment of mild retraction and prevention of postoperative retraction during primary rhinoplasty in patients who have notably weak alar cartilage<sup>[48]</sup>.

Lateral crural strut grafts are used most frequently in approaching revision of the lower lateral crura. These grafts are secured to the underside of the remaining lower lateral crura and can help to reestablish stability of the lateral nasal wall while correcting asymmetry. Some authors, when faced with severe alar retraction and sagittally malpositioned lower lateral crura, employ lateral crural strut grafting and caudal repositioning for correction<sup>[49]</sup> [Figure 2]. This method can be helpful in reorienting the nasal base but should not be considered for mild or focal alar retraction that can be approached with a more focused correction. Cartilage grafts measuring approximately 25 mm × 5 mm × 1.5 mm are attached to the underside of the lower lateral cartilage remnants with 5-0 polydioxanone (PDS) sutures. Costal or septal cartilage is preferred over conchal cartilage for lateral crural strut grafts because the strength of cartilage from these donor sites allows for thinner grafts without sacrificing integrity. This graft is then placed in a pocket dissected in a caudal position compared to the original position of the lower lateral crura between the soft tissue envelope and vestibular mucosa<sup>[50]</sup>.

In instances of severe alar retraction, it can become necessary to replace all or some of the lower lateral crura with septal or costal cartilage. In this scenario, it is essential to retain as much of the dome as possible, as reshaping this curved structure can be difficult and result in nasal tip asymmetry<sup>[36,51]</sup>. The articulated alar



**Figure 2.** (A) This patient had two prior rhinoplasties and was troubled by her tip bossae, asymmetry, irregularity, and alar retraction. She has bifidity of her tip with prominent domes. Note the pinching lateral to the domes that creates shadows between the tip and the alae. These areas should be supported by the caudal margins of the lateral crura. Operative notes indicated that a vertical dome division was performed at her initial surgery. No tip work was performed at her second surgery; (B) Note the structural void between the lower and upper lateral cartilages as a result of the cephalic trim. Approximately 8 mm of lateral crural width remained. There is buckling of the cartilage on each side lateral to the domes. Additionally, note the sagittal malpositioning of the short axes of the lateral crura. This not only narrows the external nasal valve but creates shadows lateral to the tip, making it look more bulbous. The right lateral crus was also cephalically malpositioned, contributing to her greater alar retraction on that side. The short and long axes are superimposed on the right lateral crus; (C) To correct these problems, the lateral crura were dissected from the vestibular skin and costal cartilage lateral crural strut grafts were placed. The long axes of the lateral crura were then repositioned more caudally to address the cephalic malpositioning; (D) Sutures were used to reorient the short axes of the lateral crura in order to correct the sagittal malpositioning-improving the airway and reducing the bulbosity of the tip. Note how the caudal edges of the lateral crura are farther from the septum than they were. This is a consequence of correcting the sagittal malpositioning of the short axes of the lateral crura. Compare the short and long axes to their prior positions; (E) After surgery, her tip is more symmetric, smoother, without alar retraction, and the tip blends into the alar lobules. Her external nasal valve is more patent, and her breathing is better.

rim graft described by Ballin *et al.* has shown promising results in preventing and treating severe alar retraction<sup>[52]</sup>. In combination with septal extension grafting and lateral crural tensioning, the authors found total correction in 65% of patients undergoing revision rhinoplasty for moderate-severe alar retraction, and the other 35% demonstrated significant, sub-total correction<sup>[52]</sup>. This graft is secured to the underside of the nasal tip complex, as opposed to a traditional rim graft that is not structurally dependent or sutured to the tip complex<sup>[52]</sup>.

In some patients, the alae are retracted due to cephalic malpositioning of the lateral crura. Repositioning them more caudally can provide the support needed to the alar rim<sup>[37]</sup>.

The alar spreader graft has historically been used to correct pinched tip deformity but is another option when attempting to correct medialization of the lateral crus, a potential cause of alar retraction. Kim *et al.* suggest using alar spreader when simultaneously correcting alar retraction and an upturned tip<sup>[35,53]</sup>. In this scenario, both deformities can be addressed with the release of the nasal hinge and the scroll area, which helps to correct the upturned tip abnormality and simultaneously is a necessary step prior to alar spreader graft placement. Care needs to be taken to not spread or lateralize the alar cartilages too much, as this can result in a bulbous tip deformity.



The rainbow graft used by Bracaglia *et al.* in the correction of nasal tip asymmetry was also found to correct alar retraction in 16 of 18 revision rhinoplasty patients in their case series<sup>[16]</sup>. In patients with multiple tip deformities, a rainbow graft could be considered a viable option for reconstruction<sup>[17]</sup>. Comprehensive grafts have been attempted with varying success, including the nasal tip tripod graft, which has been shown as a useful technique in cases of severe tip deformity to reconstruct the entire nasal tip in one single structured graft<sup>[54]</sup>.

In the most severe cases of alar retraction, there may be a deficiency of nasal lining. In these cases, composite grafting is a powerful technique that can replace the deficient soft tissue and cartilage with one graft<sup>[55]</sup>. Composite grafts for alar retraction are typically harvested from the cymba concha and placed into the defect created by incising the vestibular skin to release it.

Adjuvant therapy for revision rhinoplasty to help treat scar contraction may also be helpful in the setting of alar retraction. Ahn *et al.* demonstrated a cohort of 30 patients with nasal skin retraction who underwent revision rhinoplasty and were treated with several sessions of pre- and postoperative polydeoxyribonucleotide and invasive bipolar radiofrequency treatments. These treatments helped to release the tightness of the scar tissue from previous surgery and made revision surgery more accessible, with no patients suffering from persistent alar retraction or scar contracture following revision surgery<sup>[56]</sup>.

## DISCUSSION

In the words of Samuel Fomon MD, PhD, “He who masters the nasal tip, masters rhinoplasty.” The nasal tip remains one of the most important subunits of the nose to address in rhinoplasty. Each of the common nasal tip abnormalities and/or complications, tip asymmetries, bossae, and alar retraction, require deliberate consideration to prevent, and careful planning when approaching correction with revision surgery. Care should be taken during primary rhinoplasty to practice meticulous and deliberate surgical techniques to prevent these complications by preserving or augmenting the native structural integrity of the lower lateral cartilages. Repair is more difficult than prevention. While secondary rhinoplasty can present a surgical challenge, appropriately addressing patient concerns with revision rhinoplasty has been shown to improve health-related quality of life, which is rewarding for both the patient and the surgeon<sup>[57]</sup>. To better visualize the tip structure in vivo, revision rhinoplasty is often undertaken with an external approach<sup>[3,31,58]</sup>.

As trends in modern rhinoplasty shift toward emphasizing minimal intervention for maximal function and aesthetic benefits, rhinoplasty surgeons must be familiar with minimally invasive approaches to nasal tip refinement. The endonasal approach can offer many advantages that abide by these modern rhinoplasty principles, as it offers preservation of nasal tip anatomy by minimizing external incisions and limiting direct dissection of nasal tip structures<sup>[59-61]</sup>. The minimally invasive nature of this approach not only limits the visibility of scars but also significantly reduces postoperative swelling and bruising, enhancing patient recovery times<sup>[62,63]</sup>.

Additionally, preservation of the scroll area and Pitanguy’s ligament during endonasal rhinoplasty allows the surgeon to maintain the nasal tip’s natural contour and function, enabling retention of its natural dynamics and support<sup>[43]</sup>. Furthermore, rhinoplasty literature has demonstrated that many of the non-destructive techniques originally designed for open rhinoplasty have been successfully adapted for use in the endonasal approach, including cephalic trims, lateral crural steals, and various grafting techniques<sup>[60]</sup>.

In addition to the endonasal approaches, other modern techniques are gaining popularity in addressing nasal tip contouring in a minimally invasive manner. Hyaluronic acid filler injections to sculpt the nose have been suggested as a “Non-surgical rhinoplasty” technique for patients hoping to improve aesthetic aspects of their nose without the risks and/or costs associated with surgical intervention<sup>[64,65]</sup>. Surgical fat grafting has also been suggested as a less-invasive rhinofiller technique to approach boxy and asymmetric nasal tips and has shown favorable results. One case series demonstrated that compared to hyaluronic injection, fat graft injection as a rhinofiller for nasal sculpting resulted in longer-lasting favorable cosmetic results for patients<sup>[66,67]</sup>. However, given the need to harvest autologous fat for injection, fat grafting for a rhinofiller is a more involved surgical procedure and can be less comfortable and more invasive for patients than hyaluronic acid injection<sup>[67]</sup>. While the more recent data are encouraging, it is unclear whether the positive results of hyaluronic acid or fat graft rhinofiller injections can be expected in post-rhinoplasty patients who are suffering from nasal tip complications secondary to their surgery. Additionally, the long-term reliability of these injections is still under debate, with some suggesting that the duration of treatment is between 8-12 months, though duration is highly dependent on filler material<sup>[66-68]</sup>. The prospect of a less-invasive, lower-risk procedure that can help manage nasal tip complications following rhinoplasty is certainly intriguing and further trials should be conducted to assess the safety, efficacy, and reliability of these approaches.

This nasal tip complication analysis suffers from limitations inherent to many reviews focused on rhinoplasty data. Namely, most of the studies published for aesthetic procedures such as rhinoplasty consist of retrospective data, case series, or author techniques. Additionally, of note for this paper is an abundance of technique and review papers focused on alar retraction and nasal tip asymmetry and a relative paucity of data published on bossae, given the reduced incidence of this complication with more modern methods.

## CONCLUSION

Despite these limitations, there exists a wealth of published experience and data among current and past rhinoplasty surgeons that should prove essential to any aspiring surgeon aiming to prevent and correct nasal tip deformities. When faced with myriad complication possibilities in rhinoplasty, it is essential for any rhinoplasty surgeon to have access to a plethora of surgical techniques to address the varied and distinct nasal tip abnormalities.

## DECLARATIONS

### Authors' contributions

Performed the literature review and drafted the manuscript: Randall NR, Peraza LR

Performed the revision and the editing of the manuscript and the design and illustration of figures: Hamilton III GS

### Availability of data and materials

Not applicable.

### Financial support and sponsorship

None.

### Conflicts of interest

All authors declared that there are no conflicts of interest.

## Ethical approval and consent to participate

Informed consent has been obtained from patients.

## Consent for publication

Written informed consent has been obtained from patients whose photos were used in this article.

## Copyright

© The Author(s) 2024.

## REFERENCES

1. Adamson PA, Gantous A. Once upon a rhinoplasty: the history of the "queen" of facial plastic surgery. *Facial Plast Surg* 2019;35:322-39. DOI PubMed
2. Constantian MB. What motivates secondary rhinoplasty? *Plast Reconstr Surg* 2012;130:667-78. DOI PubMed
3. Rohrich RJ, Ahmad J. Rhinoplasty. *Plast Reconstr Surg* 2011;128:49e-73e. DOI PubMed
4. Nassab R, Matti B. Presenting concerns and surgical management of secondary rhinoplasty. *Aesthet Surg J* 2015;35:137-44. DOI PubMed
5. Abbas OL, Kurkcuglu A, Aytop CD, Uysal C, Pelin C. Perception of symmetry in aesthetic rhinoplasty patients: anthropometric, demographic, and psychological analysis. *Perception* 2017;46:1151-70. DOI PubMed
6. Bermudez P, Queresly FA. Nasal tip deformities after primary rhinoplasty. *Oral Maxillofac Surg Clin North Am* 2021;33:111-7. DOI PubMed
7. Bocchieri A, Marianetti TM. Perichondrium graft: harvesting and indications in nasal surgery. *J Craniofac Surg* 2010;21:40-4. DOI PubMed
8. Hodgkinson DJ, Valente PM. The versatile posterior auricular fascia in secondary rhinoplasty procedures. *Aesthetic Plast Surg* 2017;41:893-7. DOI PubMed
9. Karaaltin MV, Batioglu-Karaaltin A, Orhan KS, Demirel T, Guldiken Y. Autologous fascia lata graft for contour restoration and camouflage in tertiary rhinoplasty. *J Craniofac Surg* 2012;23:719-23. DOI PubMed
10. Gryskiewicz JM. Waste not, want not: the use of AlloDerm in secondary rhinoplasty. *Plast Reconstr Surg* 2005;116:1999-2004. DOI PubMed
11. Constantian MB. The boxy nasal tip, the ball tip, and alar cartilage malposition: variations on a theme--a study in 200 consecutive primary and secondary rhinoplasty patients. *Plast Reconstr Surg* 2005;116:268-81. DOI PubMed
12. Kreutzer C, Hoehne J, Gubisch W, Rezaeian F, Haack S. Free diced cartilage: a new application of diced cartilage grafts in primary and secondary rhinoplasty. *Plast Reconstr Surg* 2017;140:461-70. DOI PubMed
13. Erol OO. Long-term results and refinement of the turkish delight technique for primary and secondary rhinoplasty: 25 years of experience. *Plast Reconstr Surg* 2016;137:423-37. DOI PubMed
14. Tasman AJ. Dorsal augmentation-diced cartilage techniques: the diced cartilage glue graft. *Facial Plast Surg* 2017;33:179-88. DOI PubMed
15. Thomas WW, Brody RM, Alotaibi AD, et al. Characterization of injury induced by routine surgical manipulations of nasal septal cartilage. *JAMA Facial Plast Surg* 2019;21:393-401. DOI PubMed PMC
16. Bracaglia R, Servillo M, Fortunato R, Pino V, Albanese R, Gentileschi S. Rainbow graft for tip reconstruction in revision rhinoplasty. *J Plast Reconstr Aesthet Surg* 2020;73:556-62. DOI PubMed
17. Pastorek NJ, Bustillo A, Murphy MR, Becker DG. The extended columellar strut-tip graft. *Arch Facial Plast Surg* 2005;7:176-84. DOI PubMed
18. Rohrich RJ, Hoxworth RE, Kurkjian TJ. The role of the columellar strut in rhinoplasty: indications and rationale. *Plast Reconstr Surg* 2012;129:118e-25e. DOI PubMed
19. Kim MH, Choi JH, Kim MS, Kim SK, Lee KC. An introduction to the septal extension graft. *Arch Plast Surg* 2014;41:29-34. DOI PubMed PMC
20. Nadimi S, Kim DW. Revision functional surgery: salvaging function. *Facial Plast Surg Clin North Am* 2017;25:251-62. DOI PubMed
21. Gillman GS, Simons RL, Lee DJ. Nasal tip bossae in rhinoplasty. Etiology, predisposing factors, and management techniques. *Arch Facial Plast Surg* 1999;1:83-9. DOI PubMed
22. Parkes MH, Kanodia R, Kern EB. The universal tip: a systematic approach to aesthetic problems of the lower lateral cartilages. *Plast Reconstr Surg* 1988;81:878-90. PubMed
23. Goodwin WJ Jr, Schmidt JF. Iatrogenic nasal tip bossae. Etiology, prevention, and treatment. *Arch Otolaryngol Head Neck Surg* 1987;113:737-9. DOI PubMed
24. Kridel RW, Yoon PJ, Koch RJ. Prevention and correction of nasal tip bossae in rhinoplasty. *Arch Facial Plast Surg* 2003;5:416-22. DOI PubMed
25. Paun SH, Nolst Trenité GJ. Revision rhinoplasty: an overview of deformities and techniques. *Facial Plast Surg* 2008;24:271-87. DOI

[PubMed](#)

26. Kamer FM, McQuown SA. Revision rhinoplasty. Analysis and treatment. *Arch Otolaryngol Head Neck Surg* 1988;114:257-66. [DOI](#) [PubMed](#)
27. Parkes ML, Bassilios MI. Removal of nasal bossa through unipedicle flap. *Laryngoscope* 1978;88:184-6. [PubMed](#)
28. Tardy ME, Jr., Cheng EY, Jernstrom V. Misadventures in nasal tip surgery. Analysis and repair. *Otolaryngol Clin North Am* 1987;20:797-823. [PubMed](#)
29. Liapakis IE, Englander M, Vrentzos NP, Derdas SP, Paschalis EI. Secondary rhinoplasty fixations with hyaluronic acid. *J Cosmet Dermatol* 2013;12:235-9. [DOI](#) [PubMed](#)
30. Saad N, Stallworth CL. Liquid rhinoplasty. *Facial Plast Surg Clin North Am* 2022;30:357-64. [DOI](#) [PubMed](#)
31. Lee W, Koh IS, Oh W, Yang EJ. Ocular complications of soft tissue filler injections: a review of literature. *J Cosmet Dermatol* 2020;19:772-81. [DOI](#) [PubMed](#)
32. Hall SS, Kontis TC. Nonsurgical rhinoplasty. *World J Otorhinolaryngol Head Neck Surg* 2023;9:212-9. [DOI](#) [PubMed](#) [PMC](#)
33. Rivkin A. Nonsurgical rhinoplasty using injectable fillers: a safety review of 2488 procedures. *Facial Plast Surg Aesthet Med* 2021;23:6-11. [DOI](#) [PubMed](#)
34. Gubisch W, Eichhorn-Sens J. Overresection of the lower lateral cartilages: a common conceptual mistake with functional and aesthetic consequences. *Aesthetic Plast Surg* 2009;33:6-13. [DOI](#) [PubMed](#)
35. Kim JH, Song JW, Park SW, Bartlett E, Nguyen AH. Correction of alar retraction based on frontal classification. *Semin Plast Surg* 2015;29:278-85. [DOI](#) [PubMed](#) [PMC](#)
36. Abdelhamid AS, Kimura KS, El Abany A, Kandathil CK, Most SP. Patient outcomes in lateral crural repositioning and reconstruction in revision rhinoplasty. *Facial Plast Surg Aesthet Med* 2024;26:9-14. [DOI](#) [PubMed](#)
37. Hamilton GS 3rd. Form and function of the nasal tip: reorienting and reshaping the lateral crus. *Facial Plast Surg* 2016;32:49-58. [DOI](#) [PubMed](#)
38. Davis RE. Lateral crural tensioning for refinement of the wide and underprojected nasal tip: rethinking the lateral crural steal. *Facial Plast Surg Clin North Am* 2015;23:23-53. [DOI](#) [PubMed](#)
39. Leary RP, Manuel CT, Shamouelian D, Protsenko DE, Wong BJ. Finite element model analysis of cephalic trim on nasal tip stability. *JAMA Facial Plast Surg* 2015;17:413-20. [DOI](#) [PubMed](#) [PMC](#)
40. Paquet CA, Choroomi S, Frankel AS. An analysis of lateral crural repositioning and its effect on alar rim position. *JAMA Facial Plast Surg* 2016;18:89-94. [DOI](#) [PubMed](#)
41. Hamilton GS 3rd. The external nasal valve. *Facial Plast Surg Clin North Am* 2017;25:179-94. [DOI](#) [PubMed](#)
42. Dunn BS, Madorsky S. Functional nasal surgery in a compromised soft tissue envelope. *Facial Plast Surg* 2023;39:648-53. [DOI](#)
43. Cakir B, Oreroğlu AR, Doğan T, Akan M. A complete subperichondrial dissection technique for rhinoplasty with management of the nasal ligaments. *Aesthet Surg J* 2012;32:564-74. [DOI](#)
44. Rohrich RJ, Hoxworth RE, Thornton JF, Pessa JE. The pyriform ligament. *Plast Reconstr Surg* 2008;121:277-81. [DOI](#) [PubMed](#)
45. Unger JG, Roostaeian J, Small KH, et al. Alar contour grafts in rhinoplasty: a safe and reproducible way to refine alar contour aesthetics. *Plast Reconstr Surg* 2016;137:52-61. [DOI](#)
46. Boahene KD, Hilger PA. Alar rim grafting in rhinoplasty: indications, technique, and outcomes. *Arch Facial Plast Surg* 2009;11:285-9. [DOI](#) [PubMed](#)
47. Rohrich RJ, Raniere J Jr, Ha RY. The alar contour graft: correction and prevention of alar rim deformities in rhinoplasty. *Plast Reconstr Surg* 2002;109:2495-505; discussion 2506. [DOI](#) [PubMed](#)
48. Alexander AJ, Shah AR, Constantinides MS. Alar retraction: etiology, treatment, and prevention. *JAMA Facial Plast Surg* 2013;15:268-74. [DOI](#) [PubMed](#)
49. Gunter JP, Friedman RM. Lateral crural strut graft: technique and clinical applications in rhinoplasty. *Plast Reconstr Surg* 1997;99:943-52; discussion 953. [DOI](#) [PubMed](#)
50. Losquadro WD, Bared A, Toriumi DM. Correction of the retracted alar base. *Facial Plast Surg* 2012;28:218-24. [DOI](#) [PubMed](#)
51. Eichhorn-Sens J, Gubisch W. [Overresection of the lower lateral cartilage. a frequent cause for revision rhinoplasty]. *HNO* 2009;57:1113-20. [DOI](#) [PubMed](#)
52. Ballin AC, Kim H, Chance E, Davis RE. The articulated alar rim graft: reengineering the conventional alar rim graft for improved contour and support. *Facial Plast Surg* 2016;32:384-97. [DOI](#) [PubMed](#)
53. Kim JH, Park SW, Oh WS, Lee JH. New classification for correction of alar retraction using the alar spreader graft. *Aesthetic Plast Surg* 2012;36:832-41. [DOI](#) [PubMed](#)
54. Pedroza F, Pedroza LF, Achiques MT, Felipe E, Becerra F. The tripod graft: nasal tip cartilage reconstruction during revision rhinoplasty. *JAMA Facial Plast Surg* 2014;16:93-101. [DOI](#)
55. Locketz GD, Franco A, Miller PJ. Correction of the nasal ala. *Facial Plast Surg* 2022;38:70-3. [DOI](#) [PubMed](#)
56. Ahn TH, Cho SB. Adjuvant therapy for revision rhinoplasty of contracted nose using polydeoxyribonucleotide and invasive bipolar radiofrequency. *Plast Reconstr Surg Glob Open* 2018;6:e1645. [DOI](#) [PubMed](#) [PMC](#)
57. Riedel F, Wähmann M, Veit JA, Bulut OC. Quality of life outcome in revision rhinoplasty in regards to number of revision surgeries and cartilage donor site. *Auris Nasus Larynx* 2022;49:286-90. [DOI](#) [PubMed](#)
58. Rohrich RJ, Lee MR. External approach for secondary rhinoplasty: advances over the past 25 years. *Plast Reconstr Surg* 2013;131:404-16. [DOI](#) [PubMed](#)

59. Tardy ME Jr, Patt BS, Walter MA. Transdomal suture refinement of the nasal tip: long-term outcomes. *Facial Plast Surg* 1993;9:275-84. DOI PubMed
60. Sulyman O, Dayan S. Narrowing the wide tip via endonasal approach. *Facial Plast Surg* 2022;38:21-31. DOI PubMed
61. Dayan SH, Arkins JP. The endonasal lateral crural underlay and sandwich grafts. *Aesthet Surg J* 2011;31:30-9. DOI PubMed
62. Kamer FM, Pieper PG. Nasal tip surgery: a 30-year experience. *Facial Plast Surg Clin North Am* 2004;12:81-92. DOI PubMed
63. Simons RL. A personal report: emphasizing the endonasal approach. *Facial Plast Surg Clin North Am* 2004;12:15-34. DOI PubMed
64. Rauso R, Tartaro G, Chirico F, Zerbinati N, Albani G, Rugge L. Rhinofilling with hyaluronic acid thought as a cartilage graft. *J Craniomaxillofac Surg* 2020;48:223-8. DOI
65. Giammarioli G, Liberti A. Non-surgical rhinoplasty technique: an innovative approach for nasal reshaping with hyaluronic acid fillers. *J Cosmet Dermatol* 2023;22:2054-62. DOI
66. Beneduce N, Botter C, Coiante E, Hersant B, Meningaud JP. The longevity of the nonsurgical rhinoplasty: a literature review. *J Stomatol Oral Maxillofac Surg* 2023;124:101319. DOI PubMed
67. Gentile P. Rhinofiller: fat grafting (surgical) versus hyaluronic acid (non-surgical). *Aesthetic Plast Surg* 2023;47:702-13. DOI PubMed
68. Rho NK, Youn CS, Youn SJ, Lee S, Kim HS. A comparison of the safety, efficacy, and longevity of two different hyaluronic acid fillers in filler rhinoplasty: a multicenter study. *Dermatol Ther* 2021;34:e14707. DOI