

Review

Open Access



# Marginal ulceration after Roux-en-Y gastric bypass - literature review and management algorithm

Dustin Baldwin, Ahmed M. Ali, Maria S. Altieri, Eric J. DeMaria

Department of Surgery, Division of General and Bariatric Surgery, East Carolina University, Greenville, NC, 27834 USA.

**Correspondence to:** Dr. Ahmed M. Ali, MD, Department of Surgery, Division of General and Bariatric Surgery, East Carolina University, 600 Moye Boulevard, Greenville, NC, 27834 USA. E-mail: ahmed\_said93@hotmail.com

**How to cite this article:** Baldwin D, Ali AM, Altieri MS, DeMaria EJ. Marginal ulceration after Roux-en-Y gastric bypass - literature review and management algorithm. *Metab Target Organ Damage* 2024;4:6. <https://dx.doi.org/10.20517/mtod.2023.33>

**Received:** 22 Aug 2023 **First Decision:** 6 Nov 2023 **Revised:** 4 Jan 2024 **Accepted:** 26 Jan 2024 **Published:** 31 Jan 2024

**Academic Editor:** Wah Yang **Copy Editor:** Yanbing Bai **Production Editor:** Yanbing Bai

## Abstract

Roux-en-Y gastric bypass (RYGB)-associated marginal ulceration (MU) poses significant challenges for both patients and clinicians. Persistent symptoms such as epigastric pain, nausea, and reduced oral intake complicate the clinical landscape. MU can lead to severe complications, including anastomotic strictures, bleeding, and perforations. The etiology of MU is intricate, likely stemming from a combination of technical and patient-related factors. Technical considerations involve ischemia, tension on the anastomosis causing tissue ischemia, anastomotic technique, gastric pouch size, foreign bodies, and gastrogastroic fistulas. Patient factors encompass smoking, nonsteroidal anti-inflammatory drugs (NSAIDs), *Helicobacter pylori* (*H. pylori*), and uncontrolled medical comorbidities. Diagnosis primarily relies on upper endoscopy. Initial treatment typically involves proton pump inhibitors (PPI) and sucralfate. Should these measures prove insufficient, the addition of misoprostol and the implementation of endoscopic techniques, such as oversewing or stenting across the ulcer, may be considered to facilitate healing. Ultimately, if medical and endoscopic interventions fail, surgical options become imperative. These include transthoracic truncal vagotomy and revisional procedures such as resection of the ulcer with redo gastrojejunostomy, resection of the ulcer and pouch with esophagojejunostomy, or resection and reversal to normal anatomy. Surgical interventions demand expertise and should be conducted at qualified, high-volume centers. To support clinicians in comprehending the nuances of MU, we conducted a literature review, presenting a summary of our findings. Additionally, we propose an algorithm delineating the escalation of treatments for MU, ranging from medical to endoscopic to surgical therapies. This concise review aims to assist clinicians in both the prevention and treatment of marginal ulceration.



© The Author(s) 2024. **Open Access** This article is licensed under a Creative Commons Attribution 4.0 International License (<https://creativecommons.org/licenses/by/4.0/>), which permits unrestricted use, sharing, adaptation, distribution and reproduction in any medium or format, for any purpose, even commercially, as long as you give appropriate credit to the original author(s) and the source, provide a link to the Creative Commons license, and indicate if changes were made.



**Keywords:** Marginal ulceration, marginal ulcer, Roux-en-Y gastric bypass, gastric bypass, bariatric surgery, bariatrics

## INTRODUCTION

As the global obesity epidemic persists, an increasing number of individuals opt for bariatric surgery<sup>[1]</sup>. Specifically, in the United States, the annual volume of bariatric operations surged from 158,000 to 256,000 from 2011 to 2019<sup>[1]</sup>. Although sleeve gastrectomy constitutes approximately 60% of bariatric procedures, 18% undergo Roux-en-Y Gastric Bypass (RYGB), and an additional 17% opt for revisional operations<sup>[1]</sup>. Among the various complications arising post-RYGB, marginal ulcerations present as both common and challenging.

Marginal ulceration (MU) is characterized by mucosal erosion at the gastrojejunal anastomosis, typically on the jejunal side, and occasionally termed stomal ulcers when occurring on the gastric side. The prevalence of MU following anastomotic bariatric operations ranges from 0.6% to 16%<sup>[2]</sup>. A review of 35,000 RYGB patients between 2005 and 2010 in New York reported a MU rate of 6.28%<sup>[3]</sup>.

The timeframe for MU development post-operation is categorized as early (< 12 months) or late (> 12 months)<sup>[4]</sup>. However, the average time to presentation and diagnosis spans from 2 months<sup>[5]</sup> to 3.9 years<sup>[6]</sup>, with a range between 10 days<sup>[7]</sup> to 84 months<sup>[8]</sup>. Clapp *et al.*, using the national MBSAQIP database, reported a 30-day post-op MU rate of 0.35% (155 of 44,379 patients)<sup>[9]</sup>. Wilson *et al.* found a median diagnosis time of 2 months, with 95% of cases presenting within 12 months<sup>[10]</sup>. Although early MU is more prevalent, the etiologies between early and late cases seem distinct, necessitating further research.

MU manifests with symptoms ranging from epigastric pain and oral intake intolerance to severe bleeding and perforations. Surprisingly, many MU cases are asymptomatic. Csendes *et al.* performed post-RYGB upper endoscopies on 441 patients, identifying MU in 5.6%, with 28% being asymptomatic<sup>[4]</sup>. Of these, 71% underwent a repeat endoscopy within 1-2 years post-RYGB, revealing a late MU rate of 0.6%<sup>[4]</sup>. While endoscopy is the gold standard for diagnosis, upper GI contrast studies and CT scans may also provide suggestive evidence<sup>[11]</sup>.

An extensive review of marginal ulceration holds significance due to elevated healthcare costs associated with medications, hospital admissions, and endoscopies for post-RYGB MU patients<sup>[12]</sup>. Moreover, MU can lead to reoperations and heightened morbidity and mortality. This paper aims to delve into the causes, complications, and treatments of marginal ulcerations.

## METHODS

Conducting an extensive online literature review, we utilized PubMed and Scopus to explore articles under the headings: gastric bypass AND marginal ulceration. The evaluation was independently carried out by one author (DB), focusing on articles published between 2000 and 2021 and written in English. Initial screening involved assessing article abstracts for relevance to marginal ulceration following Roux-en-Y Gastric Bypass (RYGB). Exclusion criteria encompassed video-based entries, articles on single anastomosis, omega loop, or duodenal switch-based gastric bypass, as well as single case reports, book chapters, or letters to editors. From an initial pool of 257 articles from PubMed and 83 from Scopus, 68 and 29 articles, respectively, met the inclusion criteria. After eliminating duplicates, the secondary review scrutinized 70 articles in detail. Eventually, 43 articles were included in the final manuscript [Table 1], as they adhered to the screening criteria and significantly contributed to the review.

**Table 1. PMID of 43 of 70 included articles with their corresponding reference number. Of the 70 articles included in the secondary review, 43 met the criteria for inclusion and are listed below**

PMID	Reference number
25085224	14
34570307	
34433513	92
34152456	21
33939060	22
33761070	43
33159295	25
32939660	
32424625	
32299714	68
32107170	80
31956065	44
31262648	83
30842023	89
30543040	
30251139	9
30132208	90
29556889	17
29159552	62
28983751	35
28842805	45
28694899	
28442315	
28360973	
28229552	63
28215394	18
28062217	
27889483	37
27773764	6
27000883	
26948448	79
26476491	
26381875	
26324028	
26194258	30
26106845	65
25979205	
25868835	84
25868834	24
25820625	
25552229	20
27398113	11
25381115	2
25159641	5
24851857	
24462313	76
24234733	19
23743389	71

22951079	64
22743116	66
22643261	91
22543994	
21997722	31
21865096	
21725715	8
20721455	
20678964	
19136312	85
19067070	28
18581192	
18023815	26
17705072	
17514403	
16925381	
16925380	
16925306	29
16925272	36
16333541	
22939553	
18656579	

Additionally, we identified 25 articles that, while not meeting the screening criteria, provided meaningful contributions to the review. These articles were incorporated into the review but were not added to [Table 1](#). This comprehensive review served as the foundation for developing an algorithm delineating the causes, complications, and treatments of marginal ulceration [[Figure 1](#)].

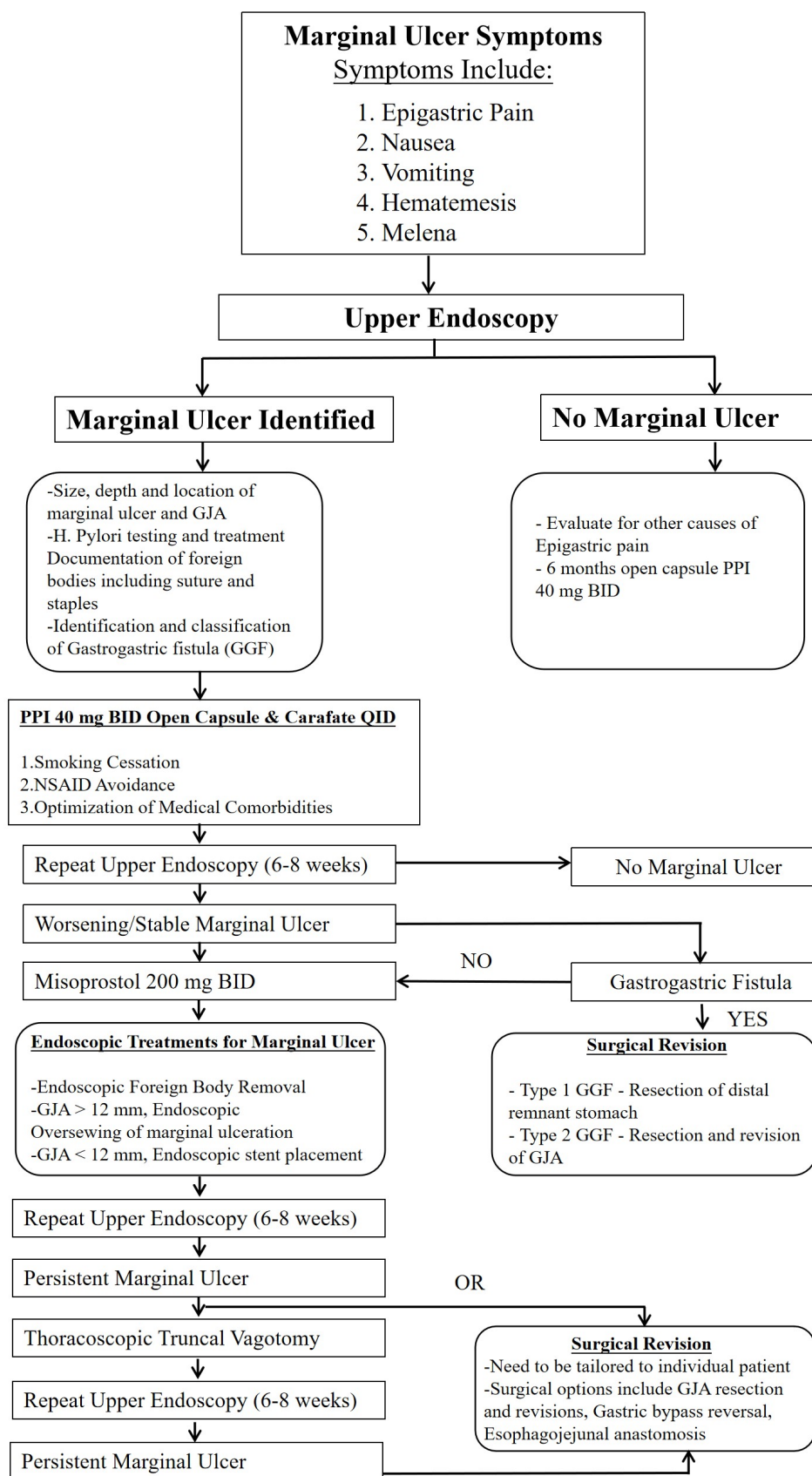
## CAUSES OF MARGINAL ULCERATION

The etiology of MU is likely complex, involving both technical and patient-related factors. Technical elements encompass ischemia, the technique used for anastomotic gastrojejunal connection, the presence of foreign bodies, gastric pouch size, and the occurrence of gastrogastic fistulas (GGF). Patient-related factors comprise smoking, usage of nonsteroidal anti-inflammatory drugs (NSAIDs), the presence of *Helicobacter pylori* (*H. pylori*), and the impact of underlying medical conditions necessitating chronic steroid and/or other immunosuppressive medications.

### Technical factors

#### *Ischemia/Tension*

It is widely acknowledged that the construction of any gastrointestinal anastomosis should adhere to solid principles to prevent ischemia and undue tension. When the gastrojejunal anastomosis is subjected to tension or the local blood vessels are compromised, the incidence of anastomotic leakage, stricture formation, and MU<sup>[13]</sup> tends to rise. Alleviating tension on the anastomosis can be achieved by routing the Roux limb through a retrocolic route as opposed to the antecolic path. Supporting this concept, an anatomic routing study comparing the retrocolic and antecolic paths for the Roux limb found a notable impact on the incidence of marginal ulceration<sup>[14]</sup>. In a comprehensive retrospective study of 1,142 patients undergoing RYGB with a circular stapler for gastrojejunostomy creation, the antecolic and retrocolic paths were used in 572 and 570 patients, respectively. During follow-up, 46 patients developed a marginal ulcer (4%), with 32 in the antecolic group (5.6%) compared to only 14 in the retrocolic group (2.5%) ( $P = 0.007$ )<sup>[14]</sup>. Their



**Figure 1.** Comprehensive marginal ulcer management algorithm based on this extensive review.

conclusion suggested the potential prudence of opting for the retrocolic path instead of the antecolic, retrogastric Roux limb in the presence of significant antecolic Roux limb tension. However, it is important to note that this approach is associated with a higher risk of internal hernia compared to the antecolic approach<sup>[15]</sup>.

The introduction of fluorescence-based imaging, such as indocyanine green (ICG), has empowered surgeons to assess ischemia intraoperatively<sup>[16]</sup>. Although widely accepted in colorectal surgery, this technique is increasingly finding its place in bariatric surgery. The use of ICG may alert surgeons to decreased perfusion of an anastomosis, potentially mitigating higher rates of MU<sup>[16]</sup>. While there are no randomized trials demonstrating a reduction in MU or leaks with ICG, its availability prompts us to recommend its use in evaluating for ischemia.

#### *Anastomotic technique*

Various techniques for gastrojejunal anastomosis (GJA) exist, with common methods including the use of a linear stapler (LS), circular stapler (CS), and hand-sewn (HS) techniques. Existing data indicates a higher incidence of marginal ulceration (MU) with the CS technique<sup>[7,17-20]</sup>. In a comparison of anastomotic techniques (LS vs. HS) following Roux-en-Y Gastric Bypass (RYGB), Schäfer *et al.* found that MU occurred in 46 patients (19.1%), with significantly higher rates in the CS group (26.2%) compared to the LS group (11.3%) ( $P = 0.0034$ )<sup>[21]</sup>. Sundaresan *et al.* reported a MU incidence of 7.3% among 1,112 patients, with technique-specific rates of 9.3% for CS, 4.8% for LS, and 5.8% for HS<sup>[22]</sup>. Similarly, Leyba *et al.*, in a study involving 80 patients randomized to a 21 mm CS GJA vs. a 45 mm linear stapler, found higher rates of MU and strictures with the circular stapler<sup>[23]</sup>. A comparison by Lois *et al.* between CS and HS techniques revealed a higher frequency of MU with the CS method (5.5% CS vs. 0.7% HS;  $P$  value = 0.04)<sup>[24]</sup>. In a systematic literature review, Fakas *et al.* found statistically significant increases in postoperative bleeding, MU, and strictures with circular staplers (21- and 25-mm) compared to LS or HS for gastrojejunal anastomosis<sup>[25]</sup>. Consequently, there seems to be a statistically significant higher rate of MU associated with circular stapler techniques, although MU can still occur with linear staplers and hand-sewn anastomoses.

#### *Foreign bodies within the anastomotic area*

The penetration of full-thickness staples and non-absorbable suture material through the mucosal layer of an anastomosis has the potential to induce local mucosal inflammation at the anastomotic site, leading to the formation of marginal ulceration and resulting in chronic pain<sup>[26,27]</sup>. Contrastingly, employing absorbable suture material for anastomosis creation has demonstrated lower rates of marginal ulceration compared to the use of permanent suture<sup>[28]</sup>. In a study by Sacks *et al.*<sup>[29]</sup>, the reported incidence of marginal ulceration after Roux-en-Y Gastric Bypass (RYGB) was 2.6% (28 out of 1,095) when non-absorbable suture was used. Interestingly, this risk significantly decreased to 1.3% (29 out of 2,190) following a programmatic shift to the use of absorbable suture for the inner layer of the gastrojejunal anastomosis ( $P < 0.001$ )<sup>[29]</sup>.

#### *Gastric pouch size*

A larger gastric pouch size has been associated with elevated rates of marginal ulceration<sup>[30-32]</sup>. Histologic examination of circular stapler rings after Roux-en-Y Gastric Bypass (RYGB) has consistently revealed acid-producing parietal cells in the proximal pouch, irrespective of pouch size<sup>[32]</sup>. Edholm *et al.* noted that smaller gastric pouches correlate with lower marginal ulceration rates. For every additional centimeter above a 14.5 cm total staple line firing length (horizontal plus vertical firings), the relative risk of marginal ulcers

increases by 14%<sup>[30]</sup>.

Patients with known marginal ulcers post-RYGB exhibit increased acid production in the proximal pouch compared to asymptomatic RYGB patients, as demonstrated by endoscopy and pH probe comparisons<sup>[33]</sup>. Maclean *et al.* found that patients with gastrojejunal ulcers had significantly larger amounts of acid, a lower pH, and a greater duration with a pH less than two measured in the gastric pouch<sup>[34]</sup>.

#### *Gastro-gastric fistula*

The occurrence of Gastro-gastric fistula (GGF) after RYGB, although rare in the modern era<sup>[35-37]</sup>, poses a risk factor for marginal ulceration due to increased anastomotic acid exposure. In the past, GGFs were more common before the widespread technique of dividing the gastric pouch from the remnant stomach. With non-divided gastric bypass techniques, GGF rates in some series reached as high as 12%<sup>[38]</sup>. In a recent study of 1,273 patients after RYGB, 15 patients presented with symptomatic GGF (1.18%)<sup>[35]</sup>, with symptoms including epigastric pain (78%), weight regain (44%), vomiting (11%), gastrointestinal bleeding (11%), and reports of MU and reflux<sup>[39]</sup>. Diagnosis traditionally involved upper GI with contrast examination, but CT with oral contrast has become more useful in recent years, particularly for detecting small fistulas or those occurring higher on the gastric pouch<sup>[40]</sup>. Endoscopy is also a valuable diagnostic tool, but caution is needed for proximal stomach pouch GGF examinations near the gastroesophageal as they may be missed unless the scope can be retroflexed to examine this<sup>[37]</sup>. Additionally, the presence of bile in the gastric pouch could suggest GGF or a short Roux limb, and some fistulas may fistulize into the jejunum instead of the stomach<sup>[41]</sup>.

#### **Patient factors**

##### *Smoking*

Tobacco smoking has consistently been associated with elevated rates of marginal ulceration following Roux-en-Y Gastric Bypass (RYGB)<sup>[31,42-46]</sup>. In a comprehensive study by Dittrich *et al.*<sup>[44]</sup> involving 249 RYGB patients over 5 years, 10.8% developed marginal ulcers, with smoking identified as a significant predictor, presenting a 4.6-fold greater risk<sup>[44]</sup>. Interestingly, daily smokers, including light, moderate, and heavy categories, exhibited similar rates of marginal ulcers (17.4%, 17.1%, and 17.9%, respectively). Even light smokers (< 10 cigarettes per day) demonstrated an increased risk compared to nonsmokers (17.4% vs. 4.2%, respectively). Former and current smokers showed comparable risks for marginal ulcers (13.3% vs. 17.5%, respectively)<sup>[44]</sup>. Another study by Di Palma *et al.* found that patients with a history of smoking were five times more likely to develop marginal ulcers requiring surgical intervention than never-smokers<sup>[42]</sup>.

In a New York state database review, Spaniolas *et al.* identified 35,075 RYGB patients between 2005 and 2010, revealing a significant association between a history of tobacco use and the development of marginal ulcers [odds ratio (OR) 1.56,  $P < 0.001$ ]<sup>[46]</sup>. Over 8 years of follow-up, the cumulative incidence of marginal ulcers increased to 3.2%, 4.7%, 7.9%, and 11.4% at 1, 2, 5, and 8 years, respectively<sup>[46]</sup>.

King *et al.* monitored 1770 RYGB patients for 7 years postoperatively to assess changes in smoking behavior<sup>[47]</sup>. The prevalence of smoking fluctuated significantly across this period ( $P < 0.001$ ), with 13.7% of patients smoking within 1 year before surgery, reducing to 2.2% at surgery, then increasing to 9.6% at 1 year postop, and reaching 14.0% smoking at 7 years. Among former smokers at the 7-year follow-up, 61.7% smoked within 1 year pre-surgery, 12.3% quit over 1 year pre-surgery, and 3.8% reported no smoking history<sup>[47]</sup>.



A recent systemic review highlighted the association between smoking 1 year before bariatric surgery and increased 30-day major postoperative complications and mortality, encompassing wound complications, pulmonary complications, and long-term complications such as marginal ulceration and fractures<sup>[48]</sup>.

Collectively, these studies suggest caution regarding anastomotic gastric bypass operations in individuals with a history of smoking. Many programs advocate active smoking cessation programs and medications for all bariatric patients, considering the reported high smoking recidivism rate of up to 61% in patients who quit within the year prior to RYGB<sup>[47]</sup>. Testing patients for nicotine and cotinine levels to confirm smoking cessation is recommended before surgery.

Cannabis (marijuana), being the most commonly used federal illicit drug in the US, presents a unique challenge to bariatric surgery programs<sup>[49]</sup>. Marijuana smoke, like tobacco smoke, contains over 400 identified chemicals, including irritants and carcinogens similar to tobacco smoke<sup>[50]</sup>. Current evidence does not suggest higher rates of marginal ulcers or other morbidities in cannabis users, although studies are limited and retrospective<sup>[51]</sup>. Nevertheless, several programs recommend marijuana cessation or transitioning to edibles before any bariatric operation.

#### *NSAIDs and aspirin*

The use of NSAIDs exerts an impact on the gastrointestinal mucosa, manifesting both locally and systemically. The primary mechanism involves the inhibition of prostaglandin (PG) production through the blocking of two cyclooxygenase enzymes, namely COX-1 and COX-2. Notably, Aspirin stands out among NSAIDs due to its irreversible binding to COX enzymes. This inhibition results in a reduction of PGI<sub>2</sub> and PGE<sub>2</sub> levels. Specifically, PGI<sub>2</sub> and PGE<sub>2</sub> play roles in inhibiting gastric acid secretion, inducing vasodilation in the vessels of the gastric mucosa, and enhancing mucus, bicarbonate production, and mucosal proliferation<sup>[52]</sup>. The effects of NSAIDs, whether administered orally or intravenously, are consistent both locally and systemically. For instance, ketorolac, an intravenous NSAID, carries a black box warning concerning its potential to induce gastric ulcers. Chronic NSAID use significantly raises the risk of developing marginal ulcers, with an odds ratio of 15.62 ( $P < 0.0001$ )<sup>[53]</sup>.

However, not all authors advocate complete NSAID avoidance. Hariri *et al.* observed that post-bariatric surgery, the use of ketorolac led to reduced opioid consumption and shorter hospital stays without an increase in bleeding rates compared to patients using opioids exclusively<sup>[54]</sup>. Nonetheless, they did not provide data on the marginal ulceration rates between the groups.

The frequent recommendation of low-dose aspirin (81 mg) for cardiac disease is noteworthy. Kang *et al.* reported on a cohort of 1,016 patients, among whom 145 (14.3%) were on low-dose aspirin post-RYGB, while 871 (85.7%) were not<sup>[39]</sup>. Importantly, there was no significant difference in the incidence of marginal ulceration between the two groups (12/145, 8.3% vs. 90/871, 10.3%;  $P = 0.45$ )<sup>[39]</sup>. Aspirin comes in various forms such as goody powder or other combination pills, and caution should be exercised to avoid high doses.

Numerous studies have delved into the comparison of selective COX-2 inhibitors (celecoxib) with nonselective NSAIDs in mitigating gastrointestinal ulceration in the general population<sup>[55-58]</sup>. Simon *et al.* examined 688 patients taking celecoxib, naproxen, or placebo over 12 weeks, finding a similar incidence of endoscopically determined gastroduodenal ulcers between the celecoxib and placebo groups (4%), in stark contrast to the higher incidence observed with naproxen (26%)<sup>[55]</sup>. Similarly, Emery *et al.* investigated patients taking celecoxib or diclofenac for endoscopically discovered gastrointestinal ulcerations, revealing a



lower occurrence in the celecoxib group (4%) compared to diclofenac (15%) ( $P < 0.001$ )<sup>[56]</sup>.

Despite this evidence, controversy persists regarding the long-term use of selective COX-2 inhibitors. Silverstein *et al.* compared 8,059 patients on ibuprofen, diclofenac, or celecoxib, noting that celecoxib was associated with fewer symptomatic ulcers than ibuprofen or diclofenac in the first six months of therapy<sup>[57]</sup>. However, over the subsequent six months, the incidence of ulcer complications was higher with celecoxib than with ibuprofen or diclofenac<sup>[58]</sup>. After one year, no significant differences in ulcer complications were observed among the three groups<sup>[58]</sup>. While many programs advocate lifelong NSAID avoidance after RYGB, if NSAIDs are deemed necessary post-bariatric surgery, a preference is often given to sleeve gastrectomy.

### *H. pylori*

*Helicobacter pylori* (*H. pylori*), a gram-negative bacterium prevalent in the stomachs of individuals worldwide, is responsible for chronic gastritis and plays a role in conditions such as peptic ulcer disease, gastric carcinoma, and lymphoma. In developing nations, 70%-90% of the populace carries *H. pylori*<sup>[59]</sup>. Diagnostic methods encompass both invasive (endoscopic-based) and noninvasive approaches. Invasive tests involve endoscopic imaging, histology, rapid urease testing, culture, and molecular techniques. Non-invasive tests comprise the urea breath test, stool antigen test, serological assays, and molecular examinations<sup>[60]</sup>. Histology biopsies from the gastric antrum and body are recommended for their ability to detect histologic gastric changes and identify HP<sup>[60]</sup>. While rapid urease tests, boasting specificity above 95%-100% and sensitivity exceeding 85%-95%, offer diagnostic utility, histology biopsies are favored in RYGB due to reduced gastric surface area potentially rendering urease tests inefficient<sup>[60]</sup>.

Treatment strategies for *H. pylori* are tailored based on local resistance patterns. Clarithromycin-based triple therapy is recommended for patients without macrolide resistance risk factors, whereas bismuth quadruple therapy is suggested for those with high macrolide resistance rates<sup>[61]</sup>. Confirmation of eradication is essential, with tests such as the urea breath test, fecal antigen test, or upper endoscopy performed four weeks post-antibiotic therapy completion. PPI therapy cessation for one to two weeks before testing is advised<sup>[61]</sup>.

A thorough review of the literature yielded seven studies encompassing 255,435 patients undergoing bariatric surgery with *H. pylori*<sup>[62]</sup>. Meta-analysis indicated comparable rates of bleeding, leaks, hospital length of stay, and weight loss between HP-positive and negative patients. However, HP-positive individuals exhibited a tenfold increase in marginal ulceration, emerging as the primary independent predictor in RYGB patients<sup>[62]</sup>. Another study involving 253,765 RYGB patients reported a marginal ulcer prevalence of 3.90%, with 31.20% of those cases testing positive for *H. pylori*. Multivariate regression analysis underscored *H. pylori* as the most robust independent predictor of marginal ulceration, boasting an odds ratio of 10.88<sup>[63]</sup>.

While certain studies suggest a lower incidence or no significant difference in anastomotic ulcer complications post-RYGB in the presence of *H. pylori* infection<sup>[20,64]</sup>, due to the severity of marginal ulcers, we advocate testing and eradicating *H. pylori* before RYGB and, if detected post-diagnosis of marginal ulcers.

### *Medical comorbidities*

Bariatric patients frequently present with multiple medical comorbidities, such as hypertension, diabetes, and immunosuppression, which can contribute to the onset of marginal ulcers (MUs). In a comprehensive cohort study involving 20,294 individuals undergoing Roux-en-Y gastric bypass (RYGB), diabetes and a

history of peptic ulcers demonstrated a statistically significant association with an elevated risk of MU<sup>[65]</sup>. Type 2 diabetes mellitus emerged as an independent risk factor for MU development in multivariate analysis<sup>[43]</sup>. Hypertension was identified as a potential contributor to marginal ulceration, with hypertensive patients exhibiting an odds ratio of 7.84 for MU formation ( $P = 0.007$ )<sup>[66]</sup>. Furthermore, Di Palma *et al.*<sup>[42]</sup> reported immunosuppression as a statistically significant factor in MU development, presenting an odds ratio of 6.69 (1.22-36.68) ( $P = 0.028$ )<sup>[42]</sup>.

The impact of corticosteroids on wound healing is well-documented, leading to increased overall mortality and morbidity following bariatric surgery<sup>[67]</sup>. Notably, corticosteroids also contribute to higher rates of MU, as highlighted by Coblijn *et al.*<sup>[2]</sup>, with an odds ratio of 4.46. We advocate for the continuous management of diabetes, hypertension, and peptic ulcer disease throughout the postoperative period. Considering the heightened risk of marginal ulceration, it is prudent to exercise caution and potentially avoid anastomotic bariatric procedures in individuals undergoing chronic immunosuppression or receiving steroid therapy.

## COMPLICATIONS OF MARGINAL ULCERATIONS

Complications arising from marginal ulceration (MU) encompass epigastric pain, gastrojejunal stenosis, perforation, and bleeding.

### Epigastric pain

The primary symptom and complication linked to MU is epigastric pain. Typically, marginal ulcers manifest with pain exacerbated by eating, accompanied by symptoms such as nausea, vomiting, and occasionally hematemesis or melena. Interestingly, around 25% of patients may exhibit no symptoms despite the presence of a marginal ulcer<sup>[43]</sup>. A systematic review reported diverse symptoms including epigastric burn (56%), nausea and vomiting (50%), dysphagia (36%), and bleeding in 5% of cases<sup>[19]</sup>. Differential diagnosis in RYGB patients with epigastric pain is broad, necessitating the exclusion of conditions such as marginal ulceration, gastrojejunal anastomotic stenosis, and internal herniation. A recent study evaluating 250 post-RYGB patients with epigastric pain revealed that 39% had an endoscopic cause for their symptoms, with marginal ulceration and stomal stenosis being the most common diagnoses<sup>[68]</sup>.

### Gastrojejunal anastomotic stenosis

Inflammation and healing of marginal ulceration at the gastrojejunal anastomosis (GJA) lead to granulation and scar tissue formation, culminating in late-onset anastomotic stenosis<sup>[23-25,69]</sup>. Sundaresan *et al.*<sup>[69]</sup> observed higher stenosis rates with a 25 mm circular stapler compared to linear and robotic hand-sewn methods. Stricture rates were 4.9%, 0.5%, and 1.2% for circular stapler, linear, and hand-sewn anastomoses, respectively, with circular stapler showing significant differences compared to linear stapler ( $P < 0.05$ ). They concluded that circular staplers had the highest stenosis rates, aligning with their observation of more frequent marginal ulcers in GJA performed with circular staplers<sup>[22]</sup>.

Management typically involves through-the-scope (TTS) endoscopic balloon dilations, with resistant strictures possibly requiring endoscopic stent placement. However, certain strictures resistant to balloon dilation may need endoscopic stent placement. Skidmore<sup>[70]</sup> evaluated 14 patients who required lumen-apposing metal stents for resistant strictures, with 12 patients achieving complete resolution of stricture<sup>[70]</sup>. Prevention of marginal ulceration is crucial to reducing the frequency of GJA stenosis and strictures.

### Marginal ulcer bleeding

Bleeding from MU can lead to chronic or acute blood loss anemia. Evaluation involves standard methods for bleeding peptic ulceration, including upper endoscopy. Once diagnosed, endoscopic interventions for

bleeding MU encompass heater probe coagulation, bipolar probe coagulation, chemical sclerosant, epinephrine injection, laser therapy, and hemostatic clip placement. Endoscopic suturing is also a consideration for bleeding MU<sup>[7]</sup>. Angiographic interventions may be employed, especially when endoscopic therapies fail<sup>[71]</sup>. Surgical management is necessary if bleeding remains uncontrolled. Although endoscopic or angiographic modalities usually identify bleeding, both endoscopy and laparoscopy may occasionally be required to localize and treat intestinal bleeding.

### Marginal ulcer perforation

Perforation of a marginal ulcer is a surgical emergency, presenting with pain, fever, sepsis, and pneumoperitoneum. The reported incidence of perforated marginal ulceration after RYGB is less than 1%<sup>[45]</sup>. A New York state database review revealed 292 cases (0.83%) of perforated marginal ulcers occurring 937 (443-1,546) days post-RYGB<sup>[45]</sup>. Treatment typically involves emergent laparoscopic or open surgery, including oversewing the ulcer, omental patching, and wide drains. However, nonoperative and even endoscopic therapies have also been described in stable patients<sup>[72]</sup>. Occasionally, extensive revision, such as redoing the gastrojejunal anastomosis, is required. However, a review indicated a common recurrence of marginal ulcer after both omental patch repair and anastomotic revision (26.09% and 29.69%, respectively,  $P = 0.726$ ).

In contrast, a retrospective analysis suggested a lower recurrence rate in cases where initial revision of the gastrojejunostomy was performed (11.4% vs. 41.7%,  $P < 0.001$ ). Complications of re-ulceration after initial perforation were also lower in the RG group, 8 cases: 1 treated medically and 7 treated surgically, compared to the SGP group, 30 cases: 8 treated medically and 22 treated surgically<sup>[73]</sup>. Reversal was needed in 2.8% of the RG cohort compared to 11.1% in the SGP cohort ( $P < 0.05$ )<sup>[73]</sup>. Although operative time was longer in the revision group, RG group (93.8 min) vs. the SGP group (57.5 min) ( $P < 0.001$ ), no significant differences were noted in time to perforation, length of stay, leaks, readmissions, or reoperations. The study suggested that both suturing of the ulcer with or without omental patch and revision of the gastrojejunostomy are safe and effective treatments for acutely perforated marginal ulcers. Nonetheless, the lower rate of recurrence in the revision group emphasizes the potential clinical benefits of initial gastrojejunostomy revision. In cases of urgent intervention for patients with a history of refractory marginal ulcers, complementary steps such as truncal vagotomy and/or gastrectomy may be considered.

## TREATMENTS OF MARGINAL ULCERATIONS

### Medical treatments

The initial approach to managing marginal ulcers (MUs) should involve gastric acid suppression through the use of proton pump inhibitors (PPIs) and sucralfate. PPIs function by blocking the gastric H,K-ATPase, thereby inhibiting gastric acid secretion. These prodrugs require gastric acid for conversion to their active forms, sulfenamide or sulfenic acid, both of which effectively block gastric acid secretion<sup>[74]</sup>. Traditionally, PPIs are administered before meals to facilitate meal-stimulated gastrin release, activating parietal cells irreversibly. However, studies indicate that after Roux-en-Y gastric bypass (RYGB), gastrin-mediated acid production from parietal cells is lower than in control subjects<sup>[75]</sup>. Notably, PPIs have demonstrated high rates of MU healing, ranging from nearly 100%<sup>[4,6]</sup> to 83%<sup>[76]</sup>.

In conjunction with PPIs, sucralfate is a frequently prescribed component of MU treatment. Comprising sucrose and aluminum hydroxide, sucralfate forms a viscous paste in acidic media, which binds to proteins in the ulcer, creating a direct protective barrier for up to six hours. Additionally, sucralfate stimulates prostaglandin synthesis, mucus secretion, and bicarbonate production, indirectly exerting a mucoprotective effect. Although the potential stimulation of growth factors for mucosal repair exists, this mechanism

remains unconfirmed<sup>[77]</sup>.

Evidence supports the post-RYGB use of PPIs to reduce MU formation risk, with studies indicating benefits from durations of 30 to 90 days<sup>[5,78,79]</sup>. Kang *et al.* observed a significant decrease in marginal ulceration incidence after RYGB in patients receiving daily PPI for 90 days (6.5%) compared to 30 days (12.4%)<sup>[79]</sup>. Similarly, Coblijn *et al.* reported a lower MU occurrence (1.2%) in a PPI prophylaxis group compared to a control group (7.3%)<sup>[78]</sup>.

Despite these findings, there remains debate regarding routine PPI use after RYGB, as evidenced by a Swedish national registry study suggesting no reduction in MU and stricture risk with PPI prophylaxis<sup>[80]</sup>. The debate extends to factors such as capsule administration, where open capsule PPIs may be more effective due to the limited gastric pouch size and rapid small-bowel transit in RYGB patients. Studies indicate shorter ulcer healing times, fewer endoscopic procedures, and reduced healthcare resource utilization with open capsule PPIs compared to intact capsules<sup>[6]</sup>. Consequently, prescribing open capsule or readily soluble PPI forms for RYGB patients, along with a recommended six months of PPI prophylaxis, is advisable.

In addressing recalcitrant MU, misoprostol, a synthetic analog of prostaglandin E1, is suggested alongside PPIs and sucralfate. Misoprostol serves as a potent inhibitor of gastric acid secretion and provides mucosal protection<sup>[81]</sup>. Although not exclusively studied in patients after RYGB, patients may receive some benefit in cases where common MU causes are avoided<sup>[82]</sup>.

Therefore, for recalcitrant MU cases, we recommend a course of misoprostol 200 mg BID along with PPIs and sucralfate.

### Endoscopic treatments

Following unsuccessful maximal medical therapy, the subsequent course of action involves endoscopic treatment. In a recent investigation by Barola *et al.*<sup>[17]</sup>, 11 patients grappling with refractory marginal ulcers, despite receiving maximal medical therapy for 6-8 weeks, underwent endoscopic intervention. Despite the study's limited sample size, a noteworthy 90% healing of ulcers was reported post-endoscopic suturing, fully covered self-expandable metal stent (FCSEMS) placement, or a combination of both<sup>[17]</sup>. The deciding factor for choosing between endoscopic suturing and FCSEMS hinged on the size of the gastrojejunal anastomosis (GJA); if GJA exceeded 12 mm, endoscopic suturing was performed to envelop the ulcer, while if less than 12 mm, an FCSEMS was utilized. The hypothesis posited that covering the ulcer bed with either suturing or stent deployment facilitated ulcer healing, ultimately resulting in a 90% success rate. These findings align with Skidmore's study<sup>[70]</sup> describing the success of lumen-apposing stents in addressing marginal ulcers and strictures. While the study's limited size raises questions about replicability on a larger scale, the outcomes show promise.

Endoscopy serves as a valuable tool for the removal of foreign bodies, including permanent sutures, staples, or clips<sup>[17,26,27]</sup>. If marginal ulcers and foreign bodies are observed during endoscopy, initial therapeutic measures involve medical management. However, in cases of refractory marginal ulcers unresponsive to medical therapy, coupled with visible foreign bodies within the ulceration, consideration should be given to endoscopic removal of the foreign body<sup>[26,27]</sup>. Employing a double-channel endoscope can be advantageous for introducing instruments such as grasping or rat tooth forceps, loop cutters, endoscopic scissors, or argon plasma coagulation probes. Ryou *et al.* reported a notable clinical improvement in over 70% of patients who underwent endoscopic accessory utilization for foreign body removal<sup>[27]</sup>.

## Surgical treatments

Addressing refractory marginal ulceration through surgery involves interventions such as vagotomy and revisional procedures, including gastrectomy and revision of the gastrojejunal anastomosis (GJA). These surgical approaches are associated with heightened risks of complications such as leaks, bleeding, sepsis, conversion from laparoscopic to open procedures, and postoperative chronic pain<sup>[83-85]</sup>. The elevated risk profile is particularly notable in individuals with a history of prior open operations who are now undergoing revisions.

### *Truncal vagotomy*

The vagus nerve assumes a pivotal role in regulating gastric acid secretion and gastrin release. Parietal cell stimulation via M3 cholinergic receptors, along with the release of histamine and gastrin from enterochromaffin-like cells and G-cells, respectively, contribute to this regulation<sup>[86]</sup>. The acidity resulting from this process has been implicated in the formation of marginal ulceration<sup>[33,34]</sup>.

For patients resistant to marginal ulcer treatment, even with appropriate measures, truncal vagotomy may present itself as a viable stand-alone strategy for healing before considering anastomotic revision. Truncal vagotomy, first described in 1947 for healing a GJA ulcer<sup>[87]</sup>, can be conducted either laparoscopically<sup>[88]</sup> or thoracoscopically<sup>[89-91]</sup>. In a study by Bonanno *et al.*<sup>[90]</sup>, where 20 patients with resistant marginal ulceration underwent either GJA revision or thoracoscopic truncal vagotomy (TTV), results indicated comparable ulcer recurrence rates between GJ revisions (15%) and TTV (14%). While complication rates were not significantly different (62% in the GJA revision group and 57% in the TTV group), the TTV group exhibited shorter operative times and fewer Clavien-Dindo III complications. Hunter *et al.* reported over 80% resolution of resistant marginal ulceration following TTV<sup>[91]</sup>. TTV, therefore, may present a healing opportunity for marginal ulcers before committing to a revisional operation and should be considered. Additionally, thoracoscopy offers the advantage of avoiding entry into a previously operated upper abdomen, which is particularly beneficial for individuals with a history of Roux-en-Y gastric bypass (RYGB).

### *Gastrojejunal revisional surgery*

Revisional surgery for refractory marginal ulceration is infrequent, and it is advisable to explore all other treatment avenues before considering such a procedure. A recent systematic review conducted by Fecso *et al.* delved into various revisional surgery techniques for refractory MU, encompassing 16 observational studies<sup>[92]</sup>. These studies covered a spectrum of revisional surgeries, including gastrojejunal anastomotic revision, subtotal gastrectomy with revisional gastrojejunal anastomosis, reversal to normal anatomy, and the conversion of RYGB to sleeve gastrectomy<sup>[92]</sup>. The studies reported a low quality of evidence, and as of now, there is no established algorithm for these procedures.

Chau *et al.* presented findings on 12 patients who underwent revisional surgery for refractory marginal ulceration<sup>[84]</sup>. Among them, ten patients underwent subtotal gastrectomy, with nine of them having a revision of the gastrojejunal anastomosis. One patient opted for total gastrectomy with esophagojejunal anastomosis due to ulcer recurrence after a failed previous revisional partial gastrectomy. Another patient underwent video-assisted thoracoscopic truncal vagotomy<sup>[84]</sup>. At a median follow-up of 35 months, none experienced a recurrence of MU, but 25% encountered significant postoperative complications<sup>[84]</sup>.

Di Palma *et al.* reported on 28 patients who underwent surgical treatment for refractory MU, involving resection and revision of their gastrojejunal anastomosis<sup>[42]</sup>. In 43% of cases ( $n = 12$ ), the surgery revealed and addressed gastric pouch and gastric remnant gastrogastroic fistula, with 10 patients (36%) reporting



symptom resolution one year post-revision. However, 16 patients (57%) exhibited endoscopic findings indicative of MU recurrence. Notably, three patients (11%) required a second revisional procedure involving the reversal of RYGB<sup>[42]</sup>. These findings suggest that patients with specific risk factors (such as smoking, immunosuppression, and NSAID use) may be more suitable candidates for bypass reversal rather than undergoing a revisional anastomotic operation.

In a comprehensive study involving 48 patients who had previously undergone RYGB and needed reversal to normal anatomy, over half (52%) underwent reversal due to refractory marginal ulceration<sup>[83]</sup>. Although all patients reported symptom resolution leading to RYGB reversal, 58% were lost to follow-up one year after surgery. The authors underscored the high morbidity associated with reversal to normal anatomy, including sepsis, leaks, bleeding, high re-operative rates, and readmissions. Therefore, such a procedure should only be considered when all other options have been exhausted and performed by experienced surgeons.

Regarding GJA revision techniques, a small case series from Taiwan suggests that revisional surgery with totally hand-sewn gastrojejunostomy and truncal vagotomy can be an effective solution for refractory MU<sup>[18]</sup>. Out of 11 patients undergoing this operation, nine showed endoscopic resolution of refractory MU at 1 year<sup>[18]</sup>. Other techniques, including stapled methods<sup>[92]</sup> and comparisons between laparoscopic and robotic approaches for revisional cases<sup>[93]</sup>, have also been explored in the literature. A recent meta-analysis comparing laparoscopic vs. robotic revisional bariatric procedures revealed no significant differences in postoperative complications, conversions to open surgery, length of stay, or operative time<sup>[93]</sup>.

For patients with gastrogastic fistula (GGF), revisional operations are necessary, as it likely contributes to refractory MU. Ribeiro-Parenti *et al.* proposed a GGF classification system, distinguishing between type 1 GGF located in the proximal part of the gastric pouch and type 2 GGF located near the gastrojejunostomy<sup>[37]</sup>. Their approach involved fistulous tract excision for type 1 GGF and gastrojejunostomy revision for type 2 GGF<sup>[37]</sup>. In their series, nine patients with GGF underwent surgery with a mean follow-up of 43 months, showing no loss of patients and all revisional patients being symptom-free<sup>[37]</sup>. Chahine *et al.*<sup>[35]</sup> further reported on a laparoscopic treatment series for GGF, with type 1 GGF patients undergoing sleeve resection of the pouch and remnant stomach, and type 2 GGF patients being treated with gastric resection and revision of the gastrojejunal anastomosis<sup>[35]</sup>. All patients were treated laparoscopically with no conversion to laparotomy.

The approach to refractory marginal ulceration should be customized based on the MU pathophysiology, undertaken by experienced surgeons in capable centers that can manage complications. Attempting GJA revision with hand-sewn or stapled techniques may be reasonable for patients without significant risk factors, but there is a risk of ulceration recurrence, necessitating reversal. In cases with substantial risk factors or a small gastric pouch, bypass reversal may be a more prudent choice. As a last resort, an esophagojejunal anastomosis may be considered for surgically refractory marginal ulcerations in patients requiring total or subtotal gastrectomy.

## CONCLUSION

Marginal ulceration poses a prevalent and intricate challenge stemming from a combination of technical and patient-related factors. The management and treatment of this condition demand a nuanced approach and a comprehensive diagnostic investigation. In the assessment of patients exhibiting typical symptoms, the diagnostic process commences with upper endoscopy. Upon confirming the diagnosis of marginal ulcer, the primary course of treatment involves medical therapy, with an emphasis on an open capsule proton



pump inhibitor (PPI) at a dosage of 40 mg twice daily and sucralfate administered four times daily. Concurrently, efforts should be made to address modifiable factors such as smoking cessation, avoidance of NSAIDs, and optimization of medical comorbidities.

To monitor progress, a follow-up endoscopy is recommended at 6-8 weeks to document healing, as the majority of marginal ulcers respond positively to this regimen. In instances where healing is not achieved, a thorough evaluation is necessary to identify and address contributing factors. These may include patient-related factors such as smoking, NSAID use, immunosuppression, or the presence of gastrogastic fistulas. Additionally, retained foreign bodies, such as non-absorbable sutures, visible staples, *etc.*, should be investigated and treated accordingly.

For patients who do not show improvement with medical interventions, endoscopic treatments become a viable consideration. These may involve oversewing and stenting of marginal ulcers. In cases where marginal ulcers prove recalcitrant to both medical and endoscopic approaches, surgical options come into play. These options encompass thoracoscopic truncal vagotomy, surgical revision with resection and redo gastrojejunal anastomosis, restoration to normal anatomy, and even total gastric pouch excision with esophagojejunal anastomosis. Each of these surgical interventions is indicated based on the severity and resistance of the marginal ulcer to earlier treatments.

## DECLARATIONS

### Authors' contributions

Made substantial contributions to the conception and design of the study and performed the literature review and interpretation: Baldwin D, Ali AM

Performed data acquisition, as well as providing administrative, technical, and material support: Altieri MS, DeMaria EJ

### Availability of data and materials

Not applicable.

### Financial support and sponsorship

None.

### Conflicts of interest

All authors declared that there are no conflicts of interest.

### Ethical approval and consent to participate

Not applicable.

### Consent for publication

Not applicable.

### Copyright

© The Author(s) 2024.

## REFERENCES

1. English WJ, DeMaria EJ, Hutter MM, et al. American Society for Metabolic and Bariatric Surgery 2018 estimate of and bariatric procedures performed in the United States. *Surg Obes Relat Dis* 2020;16:457-63. [DOI](#)
2. Coblijn UK, Lagarde SM, de Castro SM, Kuiken SD, van Wagensveld BA. Symptomatic marginal ulcer disease after Roux-en-Y

- gastric bypass: incidence, risk factors and management. *Obes Surg* 2015;25:805-11. [DOI](#) [PubMed](#)
3. Pyke O, Yang J, Cohn T, et al. Marginal ulcer continues to be a major source of morbidity over time following gastric bypass. *Surg Endosc* 2019;33:3451-6. [DOI](#)
  4. Csendes A, Burgos AM, Altuve J, Bonacic S. Incidence of marginal ulcer 1 month and 1 to 2 years after gastric bypass: a prospective consecutive endoscopic evaluation of 442 patients with morbid obesity. *Obes Surg* 2009;19:135-8. [DOI](#) [PubMed](#)
  5. Ying VW, Kim SH, Khan KJ, et al. Prophylactic PPI help reduce marginal ulcers after gastric bypass surgery: a systematic review and meta-analysis of cohort studies. *Surg Endosc* 2015;29:1018-23. [DOI](#)
  6. Schulman AR, Chan WW, Devery A, Ryan MB, Thompson CC. Opened proton pump inhibitor capsules reduce time to healing compared with intact capsules for marginal ulceration following Roux-en-Y gastric bypass. *Clin Gastroenterol Hepatol* 2017;15:494-500.e1. [DOI](#) [PubMed](#)
  7. Barola S, Magnuson T, Schweitzer M, et al. Endoscopic suturing for massively bleeding marginal ulcer 10 days post Roux-en-Y gastric bypass. *Obes Surg* 2017;27:1394-6. [DOI](#)
  8. Csendes A, Torres J, Burgos AM. Late marginal ulcers after gastric bypass for morbid obesity. Clinical and endoscopic findings and response to treatment. *Obes Surg* 2011;21:1319-22. [DOI](#) [PubMed](#)
  9. Clapp B, Hahn J, Dodoo C, Guerra A, de la Rosa E, Tyroch A. Evaluation of the rate of marginal ulcer formation after bariatric surgery using the MBSAQIP database. *Surg Endosc* 2019;33:1890-7. [DOI](#)
  10. Wilson JA, Romagnuolo J, Byrne TK, Morgan K, Wilson FA. Predictors of endoscopic findings after Roux-en-Y gastric bypass. *Am J Gastroenterol* 2006;101:2194-9. [DOI](#) [PubMed](#)
  11. Adduci AJ, Phillips CH, Harvin H. Prospective diagnosis of marginal ulceration following Roux-en-Y gastric bypass with computed tomography. *Radiol Case Rep* 2015;10:1063. [DOI](#) [PubMed](#) [PMC](#)
  12. Tarride JE, Doumouras AG, Hong D, et al. Association of Roux-en-Y gastric bypass with postoperative health care use and expenditures in Canada. *JAMA Surg* 2020;155:e201985. [DOI](#) [PubMed](#) [PMC](#)
  13. Enestvedt CK, Thompson SK, Chang EY, Jobe BA. Clinical review: healing in gastrointestinal anastomoses, part II. *Microsurgery* 2006;26:137-43. [DOI](#) [PubMed](#)
  14. Ribeiro-Parenti L, Arapis K, Chosidow D, Marmuse JP. Comparison of marginal ulcer rates between antecolic and retrocolic laparoscopic Roux-en-Y gastric bypass. *Obes Surg* 2015;25:215-21. [DOI](#) [PubMed](#)
  15. Al Harakeh AB, Kallies KJ, Borgert AJ, Kothari SN. Bowel obstruction rates in antecolic/antegastric versus retrocolic/retrogastric Roux limb gastric bypass: a meta-analysis. *Surg Obes Relat Dis* 2016;12:194-8. [DOI](#) [PubMed](#)
  16. Carrano FM, Di Lorenzo N. The use of indocyanine green in bariatric surgery: a systematic review. *J Gastric Surg* 2020;2:41-4. [DOI](#)
  17. Barola S, Fayad L, Hill C, et al. Endoscopic management of recalcitrant marginal ulcers by covering the ulcer bed. *Obes Surg* 2018;28:2252-60. [DOI](#)
  18. Chang PC, Huang CK, Tai CM, Huang IY, Hsin MC, Hung CM. Revision using totally hand-sewn gastrojejunostomy and truncal vagotomy for refractory marginal ulcer after laparoscopic Roux-en-y gastric bypass: a case series. *Surg Obes Relat Dis* 2017;13:588-93. [DOI](#) [PubMed](#)
  19. Coblijn UK, Goucham AB, Lagarde SM, Kuiken SD, van Wagenveld BA. Development of ulcer disease after Roux-en-Y gastric bypass, incidence, risk factors, and patient presentation: a systematic review. *Obes Surg* 2014;24:299-309. [DOI](#) [PubMed](#)
  20. Kelly JJ, Perugini RA, Wang QL, Czerniach DR, Flahive J, Cohen PA. The presence of *Helicobacter pylori* is not associated with long-term anastomotic complications in gastric bypass patients. *Surg Endosc* 2015;29:2885-90. [DOI](#)
  21. Schäfer A, Gehwolf P, Kienzl-Wagner K, Cakar-Beck F, Wykypiel H. Linear or circular: anastomotic ulcer after gastric bypass surgery. *Surg Endosc* 2022;36:3011-8. [DOI](#) [PubMed](#)
  22. Sundaesan N, Sullivan M, Hiticas BA, et al. Impacts of gastrojejunal anastomotic technique on rates of marginal ulcer formation and anastomotic bleeding following Roux-en-Y gastric bypass. *Obes Surg* 2021;31:2921-6. [DOI](#)
  23. Leyba JL, Llopis SN, Isaac J, Aulestia SN, Bravo C, Obregon F. Laparoscopic gastric bypass for morbid obesity-a randomized controlled trial comparing two gastrojejunal anastomosis techniques. *JSLs* 2008;12:385-8. [PubMed](#) [PMC](#)
  24. Lois AW, Frelich MJ, Goldblatt MI, Wallace JR, Gould JC. Gastrojejunostomy technique and anastomotic complications in laparoscopic gastric bypass. *Surg Obes Relat Dis* 2015;11:808-13. [DOI](#) [PubMed](#)
  25. Fakas S, Elias M, Lim D, Meytes V. Comparison of gastrojejunostomy techniques and anastomotic complications: a systematic literature review. *Surg Endosc* 2021;35:6489-96. [DOI](#) [PubMed](#)
  26. Frezza EE, Herbert H, Ford R, Wachtel MS. Endoscopic suture removal at gastrojejunal anastomosis after Roux-en-Y gastric bypass to prevent marginal ulceration. *Surg Obes Relat Dis* 2007;3:619-22. [DOI](#) [PubMed](#)
  27. Ryou M, Mogabgab O, Lautz DB, Thompson CC. Endoscopic foreign body removal for treatment of chronic abdominal pain in patients after Roux-en-Y gastric bypass. *Surg Obes Relat Dis* 2010;6:526-31. [DOI](#) [PubMed](#)
  28. Vasquez JC, Wayne Overby D, Farrell TM. Fewer gastrojejunostomy strictures and marginal ulcers with absorbable suture. *Surg Endosc* 2009;23:2011-5. [DOI](#) [PubMed](#)
  29. Sacks BC, Mattar SG, Qureshi FG, et al. Incidence of marginal ulcers and the use of absorbable anastomotic sutures in laparoscopic Roux-en-Y gastric bypass. *Surg Obes Relat Dis* 2006;2:11-6. [DOI](#)
  30. Edholm D, Ottosson J, Sundbom M. Importance of pouch size in laparoscopic Roux-en-Y gastric bypass: a cohort study of 14,168 patients. *Surg Endosc* 2016;30:2011-5. [DOI](#)
  31. Azagury DE, Abu Dayyeh BK, Greenwalt IT, Thompson CC. Marginal ulceration after Roux-en-Y gastric bypass surgery:

- characteristics, risk factors, treatment, and outcomes. *Endoscopy* 2011;43:950-4. DOI PubMed
32. Siilin H, Wanders A, Gustavsson S, Sundbom M. The proximal gastric pouch invariably contains acid-producing parietal cells in Roux-en-Y gastric bypass. *Obes Surg* 2005;15:771-7. DOI PubMed
33. Hedberg J, Hedenström H, Nilsson S, Sundbom M, Gustavsson S. Role of gastric acid in stomal ulcer after gastric bypass. *Obes Surg* 2005;15:1375-8. DOI PubMed
34. MacLean LD, Rhode BM, Nohr C, Katz S, McLean AP. Stomal ulcer after gastric bypass. *J Am Coll Surg* 1997;185:1-7. DOI PubMed
35. Chahine E, Kassir R, Dirani M, Joumaa S, Debs T, Chouillard E. Surgical management of gastrogastic fistula after Roux-en-Y gastric bypass: 10-year experience. *Obes Surg* 2018;28:939-44. DOI PubMed
36. Carrodeguas L, Szomstein S, Soto F, et al. Management of gastrogastic fistulas after divided Roux-en-Y gastric bypass surgery for morbid obesity: analysis of 1,292 consecutive patients and review of literature. *Surg Obes Relat Dis* 2005;1:467-74. DOI
37. Ribeiro-Parenti L, De Courville G, Daikha A, Arapis K, Chosidow D, Marmuse JP. Classification, surgical management and outcomes of patients with gastrogastic fistula after Roux-En-Y gastric bypass. *Surg Obes Relat Dis* 2017;13:243-8. DOI PubMed
38. Cucchi SG, Pories WJ, MacDonald KG, Morgan EJ. Gastrogastic fistulas. A complication of divided gastric bypass surgery. *Ann Surg* 1995;221:387-91. DOI PubMed PMC
39. Kang X, Hong D, Anvari M, Tiboni M, Amin N, Gmora S. Is daily low-dose aspirin safe to take following laparoscopic Roux-en-Y gastric bypass for obesity surgery? *Obes Surg* 2017;27:1261-5. DOI
40. Gao G, Nezami N, Mathur M, Balcacer P, Israel G, Spektor M. Diagnosis of gastrogastic fistula on computed tomography: a quantitative approach. *Abdom Radiol* 2018;43:1329-33. DOI PubMed
41. Lopez Luciano MJ, Then EO, Brana CJ, Ofosu A, Gaduputi A. Spontaneous gastrojejunal fistulization after roux-en-y bypass surgery: a case report and review of literature. *Cureus* 2019;11:e5035. DOI PubMed PMC
42. Di Palma A, Liu B, Maeda A, Anvari M, Jackson T, Okrainec A. Marginal ulceration following Roux-en-Y gastric bypass: risk factors for ulcer development, recurrence and need for revisional surgery. *Surg Endosc* 2021;35:2347-53. DOI PubMed
43. Süsstrunk J, Wartmann L, Mattiello D, Köstler T, Zingg U. Incidence and prognostic factors for the development of symptomatic and asymptomatic marginal ulcers after Roux-en-Y gastric bypass procedures. *Obes Surg* 2021;31:3005-14. DOI PubMed
44. Dittrich L, Schwenninger MV, Dittrich K, Pratschke J, Aigner F, Raakow J. Marginal ulcers after laparoscopic Roux-en-Y gastric bypass: analysis of the amount of daily and lifetime smoking on postoperative risk. *Surg Obes Relat Dis* 2020;16:389-96. DOI PubMed
45. Altieri MS, Pryor A, Yang J, et al. The natural history of perforated marginal ulcers after gastric bypass surgery. *Surg Endosc* 2018;32:1215-22. DOI
46. Spaniolas K, Yang J, Crowley S, et al. Association of long-term anastomotic ulceration after Roux-en-Y gastric bypass with tobacco smoking. *JAMA Surg* 2018;153:862-4. DOI PubMed PMC
47. King WC, White GE, Belle SH, et al. Changes in smoking behavior before and after gastric bypass: a 7-year study. *Ann Surg* 2022;275:131-9. DOI
48. Chow A, Neville A, Kolozsvari N. Smoking in bariatric surgery: a systematic review. *Surg Endosc* 2021;35:3047-66. DOI PubMed
49. Diggins A, Heinberg L. Marijuana and bariatric surgery. *Curr Psychiatry Rep* 2021;23:10. DOI PubMed
50. Tetrault JM, Crothers K, Moore BA, Mehra R, Concato J, Fiellin DA. Effects of marijuana smoking on pulmonary function and respiratory complications: a systematic review. *Arch Intern Med* 2007;167:221-8. DOI PubMed PMC
51. Jung F, Lee Y, Manzoor S, Hong D, Doumouras AG. Effects of perioperative cannabis use on bariatric surgical outcomes: a systematic review. *Obes Surg* 2021;31:299-306. DOI PubMed
52. Gunaydin C, Bilge SS. Effects of nonsteroidal anti-inflammatory drugs at the molecular level. *Eurasian J Med* 2018;50:116-21. DOI PubMed PMC
53. Rodrigo DC, Jill S, Daniel M, Kimberly C, Maher EC. Which factors correlate with marginal ulcer after surgery for obesity? *Obes Surg* 2020;30:4821-7. DOI
54. Hariri K, Hechenbleikner E, Dong M, Kini SU, Fernandez-Ranvier G, Herron DM. Ketorolac use shortens hospital length of stay after bariatric surgery: a single-center 5-year experience. *Obes Surg* 2019;29:2360-6. DOI PubMed
55. Simon LS, Weaver AL, Graham DY, et al. Anti-inflammatory and upper gastrointestinal effects of celecoxib in rheumatoid arthritis: a randomized controlled trial. *JAMA* 1999;282:1921-8. DOI
56. Emery P, Zeidler H, Kvien TK, et al. Celecoxib versus diclofenac in long-term management of rheumatoid arthritis: randomised double-blind comparison. *Lancet* 1999;354:2106-11. DOI
57. Silverstein FE, Faich G, Goldstein JL, et al. Gastrointestinal toxicity with celecoxib vs nonsteroidal anti-inflammatory drugs for osteoarthritis and rheumatoid arthritis: the CLASS study: a randomized controlled trial. celecoxib long-term arthritis safety study. *JAMA* 2000;284:1247-55. DOI
58. Jüni P, Rutjes AW, Dieppe PA. Are selective COX 2 inhibitors superior to traditional non steroidal anti-inflammatory drugs? *BMJ* 2002;324:1287-8. DOI PubMed PMC
59. Dunn BE, Cohen H, Blaser MJ. Helicobacter pylori. *Clin Microbiol Rev* 1997;10:720-41. DOI PubMed PMC
60. Wang YK, Kuo FC, Liu CJ, et al. Diagnosis of Helicobacter pylori infection: current options and developments. *World J Gastroenterol* 2015;21:11221-35. DOI PubMed PMC
61. McColl KE. Clinical practice. Helicobacter pylori infection. *N Engl J Med* 2010;362:1597-604. DOI PubMed

62. Mocanu V, Dang JT, Switzer N, et al. The effect of helicobacter pylori on postoperative outcomes in patients undergoing bariatric surgery: a systematic review and meta-analysis. *Obes Surg* 2018;28:567-73. [DOI](#)
63. Schulman AR, Abougergi MS, Thompson CC. H. Pylori as a predictor of marginal ulceration: A nationwide analysis. *Obesity* 2017;25:522-6. [DOI](#) [PubMed](#)
64. Rawlins L, Rawlins MP, Brown CC, Schumacher DL. Effect of helicobacter pylori on marginal ulcer and stomal stenosis after Roux-en-Y gastric bypass. *Surg Obes Relat Dis* 2013;9:760-4. [DOI](#) [PubMed](#)
65. Sverdén E, Mattsson F, Sonden A, et al. Risk factors for marginal ulcer after gastric bypass surgery for obesity: a population-based cohort study. *Ann Surg* 2016;263:733-7. [DOI](#)
66. Bhayani NH, Oyetunji TA, Chang DC, Cornwell EE 3rd, Ortega G, Fullum TM. Predictors of marginal ulcers after laparoscopic Roux-en-Y gastric bypass. *J Surg Res* 2012;177:224-7. [DOI](#) [PubMed](#)
67. Kaplan JA, Schecter SC, Rogers SJ, Lin MYC, Posselt AM, Carter JT. Expanded indications for bariatric surgery: should patients on chronic steroids be offered bariatric procedures? *Surg Obes Relat Dis* 2017;13:35-40. [DOI](#) [PubMed](#) [PMC](#)
68. Boerlage TCC, Wolvers PJD, Bruin SC, et al. Upper endoscopy after Roux-en-Y gastric bypass: diagnostic yield and factors associated with relevant findings. *Surg Obes Relat Dis* 2020;16:868-76. [DOI](#)
69. Sundaresan N, Hiticas BA, Sullivan M, et al. Gastrojejunal anastomotic stricture following Roux-en-Y gastric bypass: an analysis of anastomotic technique at a single institution. *Obes Surg* 2021;31:4947-52. [DOI](#)
70. Skidmore AP. Use of lumen-apposing metal stents (LAMS) in the management of gastro jejunostricture following Roux-en-Y gastric bypass for obesity: a prospective series. *BMC Surg* 2021;21:314. [DOI](#) [PubMed](#) [PMC](#)
71. Sidani S, Akkary E, Bell R. Catastrophic bleeding from a marginal ulcer after gastric bypass. *JSLs* 2013;17:148-51. [DOI](#) [PubMed](#) [PMC](#)
72. Vedantam S, Roberts J. Endoscopic stents in the management of bariatric complications: our algorithm and outcomes. *Obes Surg* 2020;30:1150-8. [DOI](#) [PubMed](#)
73. Crawford CB, Schuh LM, Inman MM. Revision gastrojejunostomy versus suturing with and without omental patch for perforated marginal ulcer treatment after Roux-en-Y gastric bypass. *J Gastrointest Surg* 2023;27:1-6. [DOI](#) [PubMed](#)
74. Shin JM, Sachs G. Pharmacology of proton pump inhibitors. *Curr Gastroenterol Rep* 2008;10:528-34. [DOI](#) [PubMed](#) [PMC](#)
75. Smith CD, Herkes SB, Behrns KE, Fairbanks VF, Kelly KA, Sarr MG. Gastric acid secretion and vitamin B12 absorption after vertical Roux-en-Y gastric bypass for morbid obesity. *Ann Surg* 1993;218:91-6. [DOI](#) [PubMed](#) [PMC](#)
76. Moon RC, Teixeira AF, Goldbach M, Jawad MA. Management and treatment outcomes of marginal ulcers after Roux-en-Y gastric bypass at a single high volume bariatric center. *Surg Obes Relat Dis* 2014;10:229-34. [DOI](#)
77. Bardal SK, Waechter JE, Martin DS. Gastroenterology. Applied Pharmacology. Elsevier; 2011. pp. 177-92.
78. Coblijn UK, Lagarde SM, de Castro SM, Kuiken SD, van Tets WF, van Wagenveld BA. The influence of prophylactic proton pump inhibitor treatment on the development of symptomatic marginal ulceration in Roux-en-Y gastric bypass patients: a historic cohort study. *Surg Obes Relat Dis* 2016;12:246-52. [DOI](#) [PubMed](#)
79. Kang X, Zurita-Macias L, Hong D, Cadeddu M, Anvari M, Gmora S. A comparison of 30-day versus 90-day proton pump inhibitor therapy in prevention of marginal ulcers after laparoscopic Roux-en-Y gastric bypass. *Surg Obes Relat Dis* 2016;12:1003-7. [DOI](#) [PubMed](#)
80. Wennerlund J, Gunnarsson U, Strigård K, Sundbom M. Acid-related complications after laparoscopic Roux-en-Y gastric bypass: risk factors and impact of proton pump inhibitors. *Surg Obes Relat Dis* 2020;16:620-5. [DOI](#) [PubMed](#)
81. Watkinson G, Hopkins A, Akbar FA. The therapeutic efficacy of misoprostol in peptic ulcer disease. *Postgrad Med J* 1988;64 Suppl 1:60-77. [PubMed](#)
82. Walt RP. Misoprostol for the treatment of peptic ulcer and antiinflammatory-drug-induced gastroduodenal ulceration. *N Engl J Med* 1992;327:1575-80. [DOI](#) [PubMed](#)
83. Ma P, Ghiassi S, Lloyd A, et al. Reversal of Roux en Y gastric bypass: largest single institution experience. *Surg Obes Relat Dis* 2019;15:1311-6. [DOI](#)
84. Chau E, Youn H, Ren-Fielding CJ, Fielding GA, Schwack BF, Kurian MS. Surgical management and outcomes of patients with marginal ulcer after Roux-en-Y gastric bypass. *Surg Obes Relat Dis* 2015;11:1071-5. [DOI](#) [PubMed](#)
85. Patel RA, Brolin RE, Gandhi A. Revisional operations for marginal ulcer after Roux-en-Y gastric bypass. *Surg Obes Relat Dis* 2009;5:317-22. [DOI](#) [PubMed](#)
86. Debas HT, Carvajal SH. Vagal regulation of acid secretion and gastrin release. *Yale J Biol Med* 1994;67:145-151. [PubMed](#) [PMC](#)
87. Weinstein VA, Colp R. Supradiaphragmatic vagotomy in gastrojejunal ulceration following subtotal gastrectomy for duodenal ulcer. *Surg Clin North Am* 1947;27:249-53. [DOI](#) [PubMed](#)
88. Birriel TJ, El Chaar M. Laparoscopic revision of chronic marginal ulcer and bilateral truncal vagotomy. *Surg Obes Relat Dis* 2016;12:443-4. [DOI](#) [PubMed](#)
89. Brungardt J, Tracy B, McBride K, Standiford D, Bailey BM. Right robotic-assisted transthoracic truncal vagotomy for marginal ulcer disease after gastric bypass surgery. *Am Surg* 2018;84:e340-2. [PubMed](#)
90. Bonanno A, Tieu B, Dewey E, Husain F. Thoracoscopic truncal vagotomy versus surgical revision of the gastrojejunal anastomosis for recalcitrant marginal ulcers. *Surg Endosc* 2019;33:607-11. [DOI](#) [PubMed](#)
91. Hunter J, Stahl RD, Kakade M, Breitman I, Grams J, Clements RH. Effectiveness of thoracoscopic truncal vagotomy in the treatment of marginal ulcers after laparoscopic Roux-en-Y gastric bypass. *Am Surg* 2012;78:663-8. [PubMed](#)

92. Fecso AB, Di Palma A, Maeda A, Englesakis M, Jackson T, Okrainec A. Operative management of recalcitrant marginal ulcers following laparoscopic Roux-en-Y gastric bypass for morbid obesity: a systematic review. *Surg Obes Relat Dis* 2021;17:2082-90. DOI PubMed
93. Bertoni MV, Marengo M, Garofalo F, et al. Robotic-assisted versus laparoscopic revisional bariatric surgery: a systematic review and meta-analysis on perioperative outcomes. *Obes Surg* 2021;31:5022-33. DOI