

Review

Open Access



# Innovations with the scapula and subscapular system for head and neck microvascular reconstruction

Farshad Chowdhury<sup>1</sup>, Eitan Prisman<sup>2</sup>, Carissa M. Thomas<sup>3</sup>

<sup>1</sup>Department of Otolaryngology-Head and Neck Surgery, University of Rochester, Rochester, NY 14618, USA.

<sup>2</sup>Department of Otolaryngology-Head and Neck Surgery, Vancouver General Hospital, University of British Columbia, Vancouver, BC V5Z 1M9, Canada.

<sup>3</sup>Department of Otolaryngology-Head and Neck Surgery, University of Alabama at Birmingham, Birmingham, AL 35294, USA.

**Correspondence to:** Dr. Carissa M. Thomas, Department of Otolaryngology-Head and Neck Surgery, University of Alabama at Birmingham, 1720 2nd Avenue South, Birmingham, AL 35294, USA. E-mail: carissathomas@uabmc.edu

**How to cite this article:** Chowdhury F, Prisman E, Thomas CM. Innovations with the scapula and subscapular system for head and neck microvascular reconstruction. *Plast Aesthet Res* 2023;10:68. <https://dx.doi.org/10.20517/2347-9264.2023.68>

**Received:** 8 Jul 2023 **First Decision:** 8 Oct 2023 **Revised:** 23 Nov 2023 **Accepted:** 4 Dec 2023 **Published:** 13 Dec 2023

**Academic Editor:** Marten Basta **Copy Editor:** Dan Zhang **Production Editor:** Dan Zhang

## Abstract

Microvascular free flap reconstruction based on the subscapular system is an established and versatile method of reconstructing complex head and neck defects. Since the first published description in the mid-1980s, advances have been made to the harvest technique, positioning, use of virtual surgical planning, and endosseous implants. Here, the most recent literature is reviewed for innovations related to the subscapular system. Microvascular head and neck surgeon preferences related to the subscapular system are surveyed and discussed. The concordance between virtual surgical plans using scapula cutting guides and pre-contoured plates with the postoperative result is assessed, and novel applications of the scapula free flap are presented. Subscapular system free flaps are an established and essential component of the reconstructive armamentarium for head and neck defects with minimal limitations and low donor site morbidity.

**Keywords:** Scapula, subscapular system, microvascular reconstruction, virtual surgical planning



© The Author(s) 2023. **Open Access** This article is licensed under a Creative Commons Attribution 4.0 International License (<https://creativecommons.org/licenses/by/4.0/>), which permits unrestricted use, sharing, adaptation, distribution and reproduction in any medium or format, for any purpose, even commercially, as long as you give appropriate credit to the original author(s) and the source, provide a link to the Creative Commons license, and indicate if changes were made.



## INTRODUCTION

Restoring form and function in head and neck surgical oncology poses special challenges to the reconstructive surgeon, given the local anatomic complexity underpinning the intersection of speech, swallowing, and breathing. The degree to which these functions are maintained and restored has a significant impact on post-treatment quality of life<sup>[1]</sup>. Reconstruction often necessitates microvascular free tissue transfer to achieve these goals. Free flaps from donor regions such as the radial forearm, fibula, iliac crest, anterolateral thigh, and scapula are available to the reconstructive surgeon, each providing a different balance of strengths and limitations when considering the optimal method for reconstructing dimensionally complex composite defects of the head and neck<sup>[2]</sup>. Flaps based on the subscapular system have evolved in terms of their design, application, and popularity since the initial description<sup>[3,4]</sup> and subsequent usage in head and neck reconstruction by Swartz in 1986<sup>[5,6]</sup>. Here, we review how the evolution of subscapular system flap design, developments in patient assessment and positioning, and the application of virtual surgical planning (VSP) have shifted perspectives on the use of free flaps based on the subscapular system in head and neck reconstruction. In addition to a review of the recent literature, a survey was performed to assess practice patterns among microvascular free flap surgeons, concordance was assessed between the VSP and postoperative outcome for scapula reconstruction of the mandible, and an innovative case report of utilizing the scapula tip for total rhinectomy reconstruction is presented to highlight recent innovation for subscapular system reconstruction.

## METHODS

### Literature review and case presentation

A review of the English language literature was performed for publications related to scapula and subscapular system in head and neck reconstruction using publicly available scholarly search engines PubMed and Google Scholar. Logical, synonymous search terms for the “subscapular system free flap” and “head and neck reconstruction” were utilized with an emphasis on literature published within the last 10 years. The focus was identifying new approaches to address previously reported challenges with the subscapular system and new innovations and uses in head and neck reconstruction. A novel application for subscapular system free flaps is presented as a case presentation.

### Microvascular head and neck surgeon practice patterns related to scapula free flaps

A 23-question survey of perioperative scapula free flap harvest preferences was created based on contemporary issues identified during the literature review. The survey was distributed in an anonymous fashion to head and neck microvascular surgeons who were professional contacts of the authors in the United States and Canada or had related publications. Qualtrics Research Suite (Provo, UT) was used for the survey. Survey questions are in [Supplementary Material](#). A total of 32 responses were collected (36.4% response rate) and analyzed using GraphPad Prism (v9.5.1).

### Concordance between virtual surgical planning and postoperative outcomes

VSP has been used for scapula reconstruction of the mandible and maxilla and includes cutting guides for both the mandible and the scapula bone graft as well as a custom, pre-contoured plate(s). The concordance between VSP and the postoperative outcome was investigated via a pilot study by overlaying the VSP model with a postoperative computed tomography (CT) of the neck with 1.0 mm or less slice thickness. Three cases were selected at random; two cases done according to the VSP and one case with a known intraoperative deviation from the plan. All three cases were done by the same surgeon with 5 years of experience performing scapula reconstruction. Outcome measures included the percent overlap between the plan and the postoperative outcome, the amount of bony contact between the native mandible and the bone graft, the amount of bony contact compared to the plan, and the maximum distance between the bone graft or native mandible and the pre-contoured plate.

## RESULTS

Microvascular surgeon practice pattern survey results are displayed in [Figure 1A](#) and [B](#). One (3.1%) surveyed head and neck microvascular surgeon obtains a preoperative computed tomography angiography (CTA) to assess the vessel anatomy of the subscapular system, while the vast majority ( $n = 31$ , 96.9%) do not. Twelve (37.5%) feel comfortable harvesting a scapula free flap from a previously operated shoulder. Positioning and harvest approaches in the operating room (OR) remain varied, though a majority favor newer approaches. Most microvascular surgeons use a 30-degree semi-decubitus ("lazy lateral") position in the OR ( $n = 25$ , 78.1%) compared to a full lateral decubitus position ( $n = 7$ , 21.9%), and approximately 60% do not use a spider limb positioner during harvest ( $n = 19$ , 59.4%). A majority utilize one prep and drape [ $n = 28$ , 87.5%; either sequential harvest ( $n = 21$ ) or simultaneous harvest ( $n = 7$ )]. The preferred side to harvest a scapula is either the same side as the bony defect ( $n = 17$ , 53.1%) or the nondominant arm regardless of bony defect location ( $n = 14$ , 43.8%). No one reported aborting a scapula harvest for any reason.

Approaches to the subscapular system include the parascapular and thoracodorsal, with 47% ( $n = 15$ ) of surveyed surgeons comfortable using both approaches depending on the indications of the case. Harvest of a thoracodorsal artery perforator (TDAP) flap for the soft tissue component is uncommon [68.8% ( $n = 22$ ) harvest a TDAP flap 0%-25% of cases] as is harvesting two separate skin paddles [87.5% ( $n = 28$ ) harvest two skin paddles 0%-25% of cases]. The preferred arterial supply for the bone favors using the angular artery ( $n = 19$ , 59%). Twelve surgeons (37.5%) will harvest up to 12 cm of scapula bone based only on the angular artery blood supply, while 17 surgeons (53.1%) will harvest up to 12 cm of bone based on the circumflex artery blood supply. None of the surveyed surgeons make three or more osteotomies in a scapula, with 53.1% ( $n = 17$ ) cutting a maximum of 1 osteotomy and 46.9% ( $n = 15$ ) cutting a maximum of 2 osteotomies. Eighteen surgeons (56.3%) prefer green stick osteotomies compared to 14 (43.8%) who prefer closing osteotomies. More than half of surveyed surgeons orient the scapula horizontally for a mandible reconstruction ( $n = 18$ , 56.3%) compared to a vertical orientation ( $n = 14$ , 43.7%). A minority ( $n = 12$ , 37.5%) use VSP for scapula reconstruction of the mandible or midface.

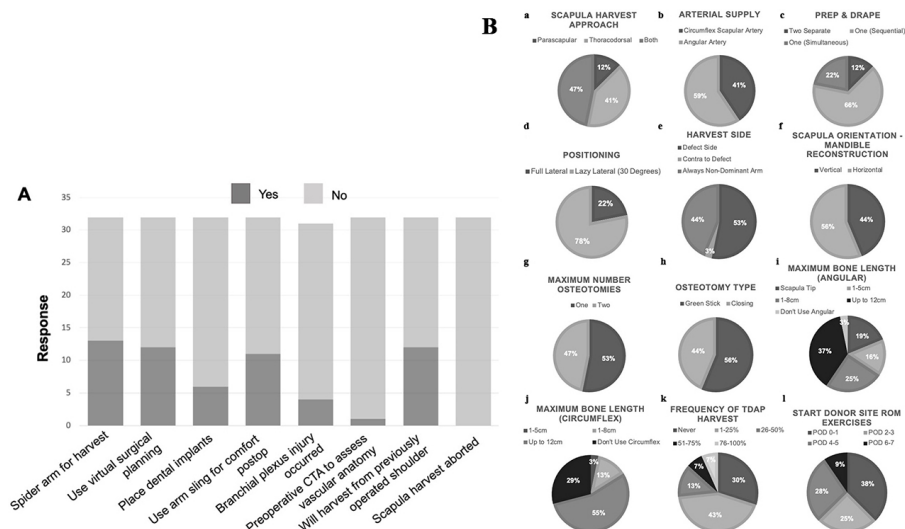
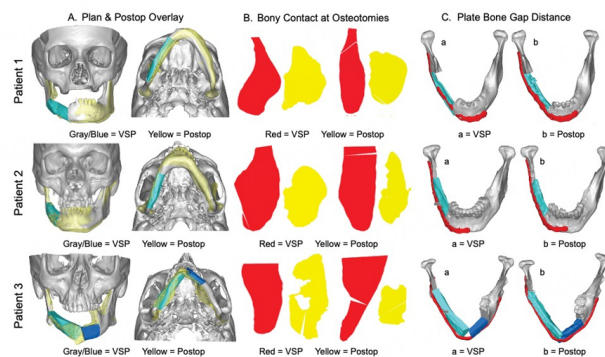
Placement of dental implants into a scapula graft remains rare, with only six surgeons (18.8%) reporting experience with this. Postoperative management of the donor site varies, with 11 surgeons (34.4%) recommending a sling for comfort and 12 (37.5%) starting range of motion exercises immediately [postoperative day (POD) 0-1]. Three surgeons (9.4%) prefer to wait until POD 6-7 for range of motion exercises, 9 (28.1%) POD 4-5, and 8 (25%) POD 2-3. Four surgeons (12.5%) reported a brachial plexus injury, and seventy-five percent of the brachial plexus injuries had a complete recovery.

Three random patients with the appropriate postoperative imaging were selected to assess the concordance between the VSP and postoperative outcome for mandible reconstruction with a scapula free flap [[Figure 2](#)]. The patients were selected because postoperative CT scans with slice thickness ( $< 1$  mm) were available. Two patients underwent reconstruction as planned and one patient had an intraoperative deviation of the plan secondary to a break in the scapula graft (patient 3). The concordance was greater at the anterior osteotomy site (parasymphyseal area) with an overlap of 70.6%-81.3% between VSP and postoperative outcome compared to the posterior osteotomy site (ramus/angle area) which overlapped 47.9%-74.8% [[Table 1](#)]. Bony contact at the anterior osteotomy was greater than 88 mm<sup>2</sup> in all three patients (range 88.7-149.3 mm<sup>2</sup>), and overlapped with the VSP by 70%-101.3%. At the posterior osteotomy site, the bony contact was 55.6-82.1 mm<sup>2</sup> with 42.1%-100.4% overlap. Two patients had small gaps between the bone graft and plate in the VSP (1.38-1.43 mm), while no gap was observed in any of the three postoperative CT scans.

**Table 1. Concordance between virtual surgical plan and postoperative result in mandible reconstruction with a scapula free flap**

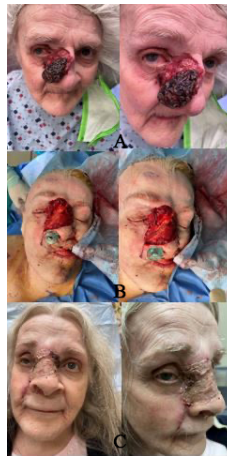	Patient 1	Patient 2	Patient 3
Overlap between VSP & postop-anterior osteotomy	76.5%	70.6%	81.3%
Overlap between VSP & postop-posterior osteotomy	74.8%	68.9%	47.9%
Bony contact-anterior osteotomy	88.7 mm <sup>2</sup>	124.8 mm <sup>2</sup>	149.3 mm <sup>2</sup>
Bony contact compared to VSP-anterior osteotomy	98.6%	70%	101.3%
Bony contact-posterior osteotomy	75.9 mm <sup>2</sup>	82.1 mm <sup>2</sup>	55.6 mm <sup>2</sup>
Bony contact compared to VSP-posterior osteotomy	100.4%	51%	42.1%
Greatest distance between plate & bone flap-VSP	0 mm	1.43 mm	1.38 mm
Greatest distance between plate & bone flap-postop	0 mm	0 mm	0 mm

VSP: virtual surgical plan.

**Figure 1.** Microvascular surgeon preferences for perioperative management and harvest of scapula free flaps. (A) The responses to yes/no survey questions are displayed in a bar graph with dark gray representing “yes” responses and light gray “no”; (B) Pie graphs representing percent responses to preoperative, intraoperative, and postoperative management of scapula free flaps.**Figure 2.** Concordance between virtual surgical plan and postoperative scapula reconstruction. The VSP and the postoperative result were compared for three patients who underwent scapula reconstruction of lateral to hemi-mandibular defects. (A) The VSP (gray/blue) and postoperative outcome (yellow) based on CT scan were overlaid. The percent overlap was calculated for the anterior and posterior osteotomies; (B) The amount of bony contact at the anterior and posterior osteotomies was determined for the VSP (red) and postoperative outcome (yellow); (C) The maximum gap between the bone graft or native mandible and pre-contoured plate was compared between VSP (a) and the postoperative outcome (b). VSP: virtual surgical plan.

## Case presentation

A 68-year-old woman presented with right-sided nasal dorsal squamous cell carcinoma (SCC) [Figure 3A].



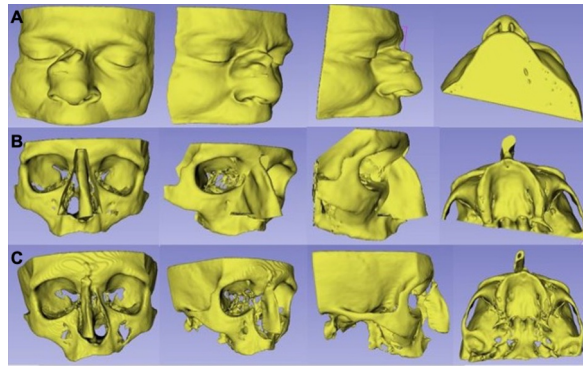
**Figure 3.** Scapula tip reconstruction of a rhinectomy defect. (A) Preoperative SCC of the right lateral nasal wall; (B) Operative scapula tip reconstruction with STSG. (C) One month postoperative result. SCC: squamous cell carcinoma; STSG: split-thickness skin graft.

Preoperative CT scan was obtained and virtual model generated [Figure 4A]. A rhinectomy including nasal dorsum, nasal bone, and internal lining was planned. Reconstruction with a right-sided osteocutaneous scapular tip positioned inferiorly was virtually planned to best recreate the nasal tip projection length [Figure 4B]. Cutting guides for the scapular harvest were printed and sterilized to facilitate harvest. A skin graft was placed overlying the reconstruction [Figure 3B and C], and a postoperative CT on day 5 was completed and a model generated [Figure 4C].

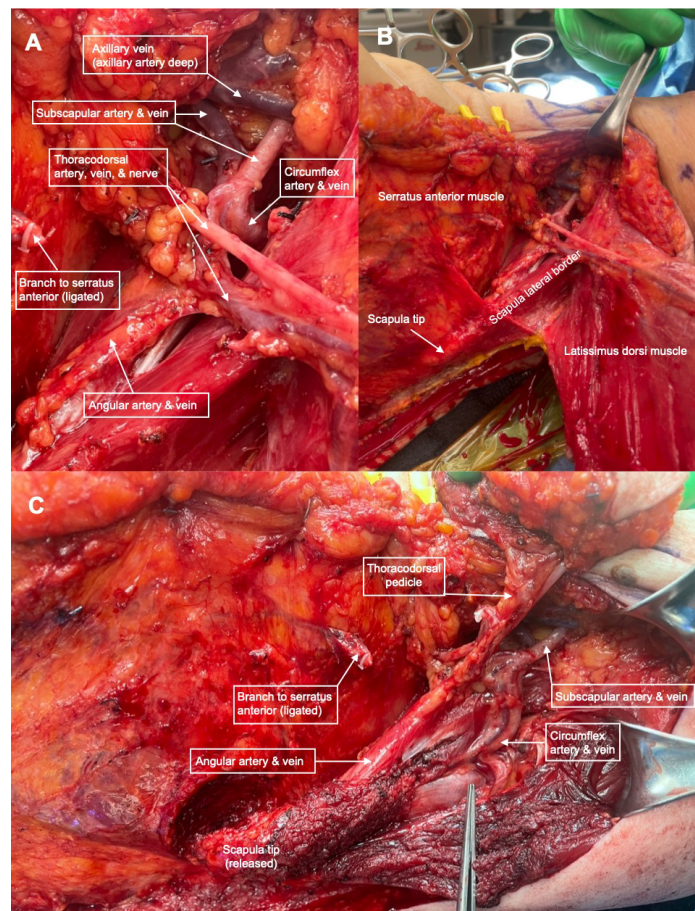
## DISCUSSION

The anatomy of the subscapular system is well described, though highly variable. The subscapular artery classically arises from the axillary artery and then divides into the circumflex scapular artery and thoracodorsal artery (TDA). The TDA gives rise to the angular branch to the tip of the scapula and branches to the serratus anterior and latissimus dorsi muscles and perforators to the overlying skin<sup>[7]</sup> [Figure 5]. Early experiences with this flap were based on independently rotating scapular and parascapular skin paddle designs along the lateral border of the scapula utilizing the circumflex scapular artery and perforators for its vascular supply with the additional option of latissimus dorsi muscle or myocutaneous paddle based off the TDA<sup>[5,8]</sup>. The angular artery was subsequently identified as an independent and reliable blood supply to the scapular tip<sup>[9,10]</sup>, allowing further modification of the flap design. Angular artery-based pedicles allow for the harvest of the scapular tip or the lateral border of the scapula with a longer vascular pedicle while preserving the options for independently rotating muscle or myocutaneous paddles, resulting in a versatile, chimeric system<sup>[11,12]</sup>. As reviewed by O'Connell *et al.*, the mean pedicle length of the angular artery to the subscapular artery is 14.8 cm<sup>[13]</sup>, and the mean combined length of bone and angular pedicle is 27 cm<sup>[11]</sup>. The average length of bone harvested on the angular branch has been reported as 6.2 cm<sup>[14]</sup> and 5.2 cm<sup>[11]</sup> depending on the series, with cadaveric studies suggesting that the angular artery could supply a segment of scapular bone up to 20 cm in total length<sup>[13,15]</sup>. Early reports of osteocutaneous scapular flaps harvested on the circumflex scapular artery describe the successful use of the lateral border with the scapular tip to reconstruct the angle of the mandible without the use of osteotomies<sup>[5]</sup>, as well as the harvest of 14.5 cm of bone with multiple osteotomies<sup>[8]</sup>. In the experience of our survey respondents [Figure 1], a significant cohort of surgeons report success in harvesting up to 12 cm of lateral scapula bone based on either the angular artery or circumflex scapular artery, highlighting the versatility of the subscapular system for flap reconstruction. A persistent contraindication to osseous flaps of the subscapular system is the desired number of osteotomies<sup>[16]</sup>. Length and osteotomy limitations can prevent the scapula from being used for large





**Figure 4.** Virtual surgical planning for total nasal reconstruction. (A) Preoperative staging CT scan; (B) Virtual surgical plan using the scapula tip supplied by angular artery to reconstruct the rhinectomy defect; (C) Postoperative day five CT scan. CT: computed tomography.

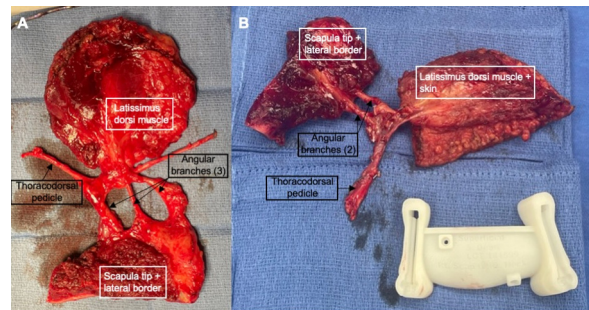


**Figure 5.** Subscapular system vascular anatomy. (A) Vascular anatomy of the subscapular system pedicle; (B) Muscle and bone anatomy in relationship to the pedicle; (C) Vascular anatomy of the subscapular system after the latissimus dorsi muscle with skin soft tissue paddle has been excised and rotated superiorly.

mandible defects such as angle-to-angle defects. None of the surgeons surveyed would cut more than two osteotomies in a scapula bone. In addition, the majority prefer green stick osteotomies. These preferences reflect the understanding that there are few perforators to the scapula bone; therefore, the number of bone cuts is limited to preserve the vascular supply. However, the literature on this is limited, and further research should be done on postoperative outcomes comparing osteotomy techniques.

The arterial pattern of the subscapular system-with the subscapular artery classically arising from the third section of the axillary artery and subsequently dividing into the circumflex and thoracodorsal arteries-is the primary factor enabling the harvest of free tissue with a chimeric or “megaflap” design. Microvascular surgeons commonly encounter variations in vascular anatomy among patients during flap harvest. Unexpected variability in arterial anatomy is especially pertinent in the context of chimeric flap design, as deviations in arterial anatomy may preclude the harvest of multiple, independently vascularized components arising from a single vascular pedicle. For example, the effective absence of a subscapular artery due to the TDA arising separately from the first or second part of the axillary artery has been reported<sup>[17-19]</sup>. Cadaveric series report the frequency of an absent common subscapular trunk between 3.3% and 19%<sup>[20-22]</sup>. Recent studies based on CTAs of the chest by Imaue *et al.* and Barrett *et al.* evaluating 39 and 200 subscapular arterial systems, respectively, report the absence of a common subscapular trunk in approximately 20% of the analyzed arterial systems in each of their respective cohorts<sup>[23,24]</sup>. Cadaveric studies focusing on the angular branch have reported up to six variants in branch patterns with respect to the location of the origin of the angular artery relative to other branches from the TDA. The most common variations are the angular branch arising from the serratus anterior branch or the TDA itself<sup>[22,25,26]</sup>. Additional variants include the angular branch arising from a trifurcation of branches and of multiple angular arteries [Figure 6]. In addition, there are anecdotal reports of an absent or diminished angular artery<sup>[13]</sup>. Vessel-depleted necks present additional challenges to the reconstructive surgeon where the geometry and number of available recipient vessels may demand both maximal pedicle length and the chimeric flap design to converge on a single pedicle/anastomosis. These constraints limit the surgeon’s ability to make effective real-time modifications to the anticipated flap design when unexpected aberrations in the vascular anatomy are encountered. The high rate of subscapular system vascular pedicle variations and the accuracy of assessing the subscapular system anatomy with a CTA highlights the potential benefit of preoperative vascular assessment in complex, salvage cases where maximal pedicle length and use of a single anastomosis are critical elements of the reconstructive plan<sup>[24]</sup>. Despite the benefits of a preoperative CTA to assess vessel anatomy, currently, only 3% of surveyed microvascular surgeons obtain a CTA prior to surgery.

The quality of the donor vessels related to atherosclerosis presents an area of uncertainty in microvascular reconstruction, and here, the subscapular system demonstrates a relative advantage, especially compared to the fibula free flap. Histologic examination of flap-feeding vessels demonstrates less severe atherosclerotic changes to the circumflex scapular artery compared to the peroneal artery. Greater than 95% of the vessel wall changes observed in the circumflex scapular artery were Class II (thickened intima) and III (calcification and progressive plaque) compared to approximately 70% Class III and IV (florid plaques and necrosis) in the peroneal artery<sup>[27]</sup>. Notably, Barret *et al.* found no CTA evidence of atherosclerotic disease in their analysis of 200 subscapular arterial systems-even in patients with atherosclerotic disease affecting other vessels<sup>[24]</sup>. This contemporary finding corroborates the historical observation that atherosclerotic disease appears to spare the subscapular system<sup>[13]</sup>, providing an advantage to the use of the subscapular system in patients with a heavy burden of vascular disease.



**Figure 6.** Angular artery variants. (A) Harvest of a scapula tip and lateral border with three angular branches identified; (B) Harvest of a scapula tip and lateral border with two angular branches identified.

A strength of the scapula free flap is the versatility of the bone and soft tissue components that can be harvested as individual components or together into a chimeric free flap that can serve as an alternative to multiple free flaps in large defect cases<sup>[11,28,29]</sup>. As a result, the spectrum of complex head and neck surgical defects-including cutaneous, composite oral cavity, midface, and oropharynx-can be reconstructed with the subscapular system. In addition to bone grafts harvested based on either the circumflex scapular artery or the angular artery, there are diverse options related to the soft tissue component of the free flap. The circumflex scapular artery supplies scapular and parascapular fasciocutaneous flaps, while the TDA gives rise to myocutaneous perforators through the latissimus dorsi muscle. If desired, the thoracodorsal perforator can be dissected through the latissimus dorsi muscle to harvest a fasciocutaneous flap without muscle (TDAP). Interestingly, in the cohort of surveyed head and neck microvascular surgeons [Figure 1], relatively few harvested a TDAP fasciocutaneous skin paddle regardless of whether the reconstruction was osseous or soft tissue only. This may be due to the relatively thin latissimus dorsi muscle that does not significantly add flap bulk or concerns related to large skin paddle perfusion. In addition, relatively few surveyed surgeons harvested two separate skin paddles, possibly because multiple skin paddles are not frequently required or because of the limitations to simultaneous harvest when multiple skin paddles are desired. However, these practice trends need to be interpreted with caution due to the low survey response rate.

The original descriptions of subscapular system flaps and early application of these flaps in head and neck reconstruction utilized a lateral decubitus harvesting technique, which requires an intraoperative position change with redraping of the relevant surgical sites<sup>[7,22]</sup>. This has been a historic disadvantage of the subscapular system, given the additional time, resources, and challenges involved in intraoperative repositioning<sup>[22]</sup>. Subsequent modifications to this technique adopted a 45- or 30-degree supine semi-decubitus ("lazy lateral") position and later included the incorporation of limb retraction devices to eliminate the need for a second assistant for the sole purpose of limb retraction<sup>[11,30-32]</sup>. These modifications have allowed for flap harvest concurrent with either part of or the entirety of the extirpative portion of the operation without any increase in positioning-related complications<sup>[31]</sup>. A technique for harvest of the scapular flap in a fully supine position with concurrent partial ablation has also been described<sup>[33]</sup>. These refinements have resulted in the increased frequency of the parallel, two-team approach when utilizing the subscapular system for harvest<sup>[34,35]</sup>. Simultaneous tumor extirpation and scapula flap harvest results in a 37.9% reduction in operative time and no difference in positive margin rates, free flap compromise, or patient-reported outcomes<sup>[36]</sup>. A survey of operative preferences for head and neck microvascular surgeons reflects this innovation, as the majority have adopted a single prep and drape with the use of a 30-degree semi-decubitus position. A statistically significant reduction in operative time is also reported with the use of the spider limb positioner compared to the use of a second assistant for limb positioning<sup>[37]</sup>. Despite the



documented advantage in the literature, only 40.6% ( $n = 13$ ) of surveyed surgeons utilize a spider limb positioner, with one potential barrier being the cost of the device<sup>[31]</sup>. Finally, it is also reported that prior shoulder surgery should be considered a possible contraindication to the use of a scapula free flap, but 37.5% of surveyed surgeons feel comfortable harvesting in a previously operated field with no reports of aborted cases [Figure 1].

Decreased donor site morbidity, compared to a fibula flap, is a strength of the subscapular system<sup>[38,39]</sup>. Activities of daily living are not significantly impacted in patients undergoing scapula free flap reconstruction<sup>[29,40]</sup> (with the exception of physical quality of life impairments as measured by the UW-QoL physical domain)<sup>[38]</sup>. Disabilities of the arm, shoulder, and hand (DASH) questionnaires completed 10-14 months after surgery had a mean score of  $21.74 \pm 7.30$ , which is significantly higher than a normal population but still lies within the very mild to mild rating of donor site morbidity<sup>[41]</sup>. Patients mobilize earlier in the hospital, which may benefit elderly patients or those with baseline mobility issues<sup>[16,40,42]</sup>. Patients undergoing subscapular system reconstruction had similar decision regret compared to patients with fibula free flap reconstruction<sup>[38]</sup>. Patients are also more satisfied with the scar compared to other donor sites<sup>[13]</sup>. Suturing the remaining serratus anterior to teres muscles combined with physical therapy can minimize shoulder morbidity<sup>[13]</sup>. Despite the original recommendation for 4-10 days of shoulder immobilization<sup>[5,8]</sup>, postoperative immobilization of the shoulder is not needed, and a minority of surgeons have patients wear a sling for comfort in the postoperative period. here is a range of when mobility exercises are implemented in the postoperative period, and the impact of timing of mobilization on recovery remains an area of opportunity for further study. A perhaps underreported potential complication is an injury to the brachial plexus, either from positioning or arm retraction<sup>[13]</sup>. Cadaver studies demonstrate four different relationships between the subscapular artery and the brachial plexus with varying degrees of risk of injury with subscapular artery dissection<sup>[23]</sup>. Four surgeons (12.5%) reported having a brachial plexus injury, with a 75% recovery rate. Surgeons should consider discussing this potential complication during preoperative counseling.

VSP has impacted applications of the subscapular system and operative time. The percentage of simultaneous tumor resection and flap harvest increases with the use of VSP because there is a predetermined defect which decreases overall operative time<sup>[33]</sup>. VSP for scapula reconstruction of the mandible and midface has gained momentum, and VSP has been progressively applied to scapula reconstruction with increasing success<sup>[43,44]</sup>. Despite this, less than 40% of surveyed surgeons report utilizing VSP for scapular reconstruction. Again, this may be a result of the low response rate and should be interpreted within that context. Prior virtual analysis has examined the benefits of a horizontally vs. vertically positioned scapula for various mandibular defects<sup>[45]</sup>. One aspect where VSP can be particularly useful is determining which orientation of the scapula bone graft most closely matches the natural angles of the mandible. Based on comparisons between the mandibular ramus, body, and symphyseal angles and the scapular protuberance, body, and tip angles, a vertically positioned scapula is ideal for mandibular body and ramus defects, while a horizontally positioned scapula is better for anterolateral defects<sup>[45]</sup>. Similar advantages in terms of subunit reconstruction and ideal anatomic positioning have been demonstrated in the use of VSP for midface reconstruction<sup>[46]</sup>. Based on this study's survey results, the microvascular surgeon's preference for horizontal vs. vertical orientation of the scapula bone is relatively evenly divided (56.3% vs. 43.7% respectively), which is surprising since the literature indicates that a horizontal scapula is only ideal for reconstruction of the mandibular symphysis<sup>[45]</sup>. Studies examining nonunion and hardware exposure with or without VSP have not delineated between scapula orientation and would be an interesting future area of research.

The versatility of the scapula, combined with advances in VSP, provides opportunities for greater reconstructive applications. Here, the authors presented a rhinectomy reconstructed with the scapular tip preplanned with VSP. A limitation of VSP is that it does not account for the soft tissue component of a scapula free flap reconstruction. Soft tissue thickness on the bone graft may impact the fit of the scapula cutting guides and subsequently affect the degree of bony contact at osteotomy sites and how well the postoperative result matches the original VSP. In addition, the scapula bone graft is cut and removed from the back, followed by shaping and osteotomies with the scapula cutting guide on the back table *vs.* placing the guide on the scapula tip/lateral border while still in continuity in the back. These “real-life” scenarios pose the question of how similar the postoperative outcomes are to the original VSP. This was explored by looking at the concordance between three cases [Table 1]. The anterior osteotomy at the mandible body or parasymphysis demonstrated high concordance with VSP (70.6%-81.3%) and high bony contact (70%-101.3%) even in a case where significant deviation from the plan was necessary (patient 3). These findings are likely due in part to the increased bone thickness at the mandibular body/parasymphysis combined with the use of the lateral border of the scapula, which also has increased bone thickness, for the anterior apposition. There was decreased concordance (47.9%-74.8%) and bony contact (42.1%-100.4%) at the posterior osteotomy site at the mandibular angle/ramus. This was especially evident in the case of a plan deviation for patient 3. The posterior osteotomy is likely more sensitive to intraoperative plan adjustments because of the thinner bone at both the ramus and scapula tip. There were no gaps identified between bone appositions, which is important because gaps > 1 mm have been associated with higher rates of nonunion<sup>[47]</sup>. It would be interesting to study what the minimum amount of bony contact is for bony union to continue advancing the application and outcomes of VSP. Finally, two plans demonstrated minor gaps between the bone graft and pre-contoured plate, which were not seen on the postoperative scans. It has been previously shown that a plate-to-bone gap < 1 mm is associated with a reduced risk of plate exposure<sup>[48]</sup>. Nonlocking, bone screws were used to fixate the plate to the scapula bone graft, and the ability of the screws to bend the plate to the bone likely reduced the plate-to-bone gap to 0 mm compared to the plan. The cases included in this pilot study were all performed by the same surgeon within the first 5 years of their practice. Experience with mandible reconstruction and VSP could impact the results, and a large, multi-institutional study should be performed to assess the benefits and challenges of VSP with scapula free flap reconstruction.

A significant limitation to the scapula free flap is the low rates of dental rehabilitation with endosseous implants, and controversy surrounds this topic<sup>[35,49]</sup>. Prior to the popularization of shorter and narrower contemporary implants, 7-10 mm was considered the minimum bone height for implantation and cadaveric studies raised concern that certain patients-particularly females-would not have adequate scapula bone stock<sup>[50]</sup>. Indeed, it is reported that a subset of patients reconstructed with a scapular flap required additional bone grafting from the iliac crest at the time of dental implantation to achieve adequate bone stock<sup>[51]</sup>. In contrast, a number of retrospective reviews demonstrate that patients selected to receive osseointegrated dental implants into bony subscapular system free flaps (both tip and lateral border) have rates of success equal to other bony flaps more commonly rehabilitated with dental implantation<sup>[52-55]</sup>. The available data do not indicate whether a greater proportion of patients who undergo scapular reconstruction remain ineligible for dental implantation. This controversy and uncertainty is supported by our survey data, with less than 20% of microvascular surgeons placing endosseous implants into scapula bone flaps [Figure 1]. This is an area that demands further study as optimal speech, mastication, and swallowing rely on dental rehabilitation.

## CONCLUSION

Microvascular reconstruction based on the subscapular system is now a routine part of head and neck reconstruction. Addressing prior limitations to this flap, including positioning concerns and long OR times, has led to its increased utilization. Overall, employing the scapula for reconstruction offers numerous benefits and few drawbacks, primarily limited osteotomies and a lack of extensive experience with endosseous implants being the only major concerns. Progress in VSP has enhanced the precision of reconstruction and enabled novel applications. This review of the state of scapula reconstruction has identified key areas where additional research will help advance head and neck reconstruction involving the scapula free flap.

## DECLARATIONS

### Acknowledgments

We would like to acknowledge Kevin Lindsey, a biomedical engineer with 3D Systems, and Chase Shellman with Stryker for assistance in comparing the preplanned mandibular reconstruction with the postoperative reconstruction.

### Authors' contributions

Made substantial contributions to the conception and design of the study and performed data analysis and interpretation: Chowdhury F, Prisman E, Thomas CM

### Availability of data and materials

Not applicable.

### Financial support and sponsorship

None.

### Conflicts of interest

All authors declared that there are no conflicts of interest.

### Ethical approval and consent to participate

This study has IRB approval to study outcomes in reconstruction for head and neck cancer. (IRB-030716015). Written informed consent to participate was obtained.

### Consent for publication

Written informed consent for publication was obtained from the patients involved.

### Copyright

© The Author(s) 2023.

## REFERENCES

1. van Rooij JAF, Roubos J, Vrancken Peeters NJMC, Rijken BFM, Corten EML, Mureau MAM. Long-term patient-reported outcomes after reconstructive surgery for head and neck cancer: a systematic review. *Head Neck* 2023;45:2469-77. [DOI](#) [PubMed](#)
2. Smith RB, Henstrom DK, Karnell LH, Chang KC, Goldstein DP, Funk GF. Scapula osteocutaneous free flap reconstruction of the head and neck: impact of flap choice on surgical and medical complications. *Head Neck* 2007;29:446-52. [DOI](#) [PubMed](#)
3. Nassif TM, Vidal L, Bovet JL, Baudet J. The parascapular flap: a new cutaneous microsurgical free flap. *Plast Reconstr Surg* 1982;69:591-600. [DOI](#) [PubMed](#)
4. dos Santos LF. The vascular anatomy and dissection of the free scapular flap. *Plast Reconstr Surg* 1984;73:599-604. [DOI](#) [PubMed](#)
5. Swartz WM, Banis JC, Newton ED, Ramasastry SS, Jones NF, Acland R. The osteocutaneous scapular flap for mandibular and maxillary reconstruction. *Plast Reconstr Surg* 1986;77:530-45. [DOI](#) [PubMed](#)
6. Bansal AP, Buchakjian MR. Subscapular system free flaps for oromandibular reconstruction. *Plast Aesthet Res* 2021;8:59. [DOI](#)

7. Urken ML, Cheney ML, Blackwell KE, Harris JR, Hadlock TA, Futran N. Atlas of regional and free flaps for head and neck reconstruction: flap harvest and inseting. Baltimore, MD: Lippincott Williams & Wilkins; 2012. Available from: <http://solution.lww.com/urkenatlas> [Last accessed on 11 Dec 2023]
8. Sullivan MJ, Carroll WR, Baker SR, Crompton R, Smith-wheelock M. The free scapular flap for head and neck reconstruction. *Am J Otolaryng* 1990;11:318-27. [DOI](#)
9. Coleman JJ 3rd, Sultan MR. The bipedicle osteocutaneous scapula flap: a new subscapular system free flap. *Plast Reconstr Surg* 1991;87:682-92. [DOI](#) [PubMed](#)
10. Uglesić V, Virag M, Varga S, Knezević P, Milenović A. Reconstruction following radical maxillectomy with flaps supplied by the subscapular artery. *J Craniomaxillofac Surg* 2000;28:153-60. [DOI](#) [PubMed](#)
11. Chepeha DB, Khariwala SS, Chanowski EJ, et al. Thoracodorsal artery scapular tip autogenous transplant: vascularized bone with a long pedicle and flexible soft tissue. *Arch Otolaryngol Head Neck Surg* 2010;136:958-64. [DOI](#)
12. Urken ML, Bridger AG, Zur KB, Genden EM. The scapular osteofasciocutaneous flap: a 12-year experience. *Arch Otolaryngol Head Neck Surg* 2001;127:862-9. [PubMed](#)
13. O'Connell JE, Bajwa MS, Schache AG, Shaw RJ. Head and neck reconstruction with free flaps based on the thoracodorsal system. *Oral Oncol* 2017;75:46-53. [DOI](#) [PubMed](#)
14. Yoo J, Dowthwaite SA, Fung K, Franklin J, Nichols A. A new angle to mandibular reconstruction: the scapular tip free flap. *Head Neck* 2013;35:980-6. [DOI](#)
15. Seneviratne S, Duong C, Taylor GI. The angular branch of the thoracodorsal artery and its blood supply to the inferior angle of the scapula: an anatomical study. *Plast Reconstr Surg* 1999;104:85-8. [DOI](#)
16. Dowthwaite SA, Theurer J, Belzile M, et al. Comparison of fibular and scapular osseous free flaps for oromandibular reconstruction: a patient-centered approach to flap selection. *JAMA Otolaryngol Head Neck Surg* 2013;139:285-92. [DOI](#)
17. Kumar N, Aithal AP, Nayak SB, Bhaskar R. A rare case of atypical thoracodorsal artery: a challenge for flap reconstruction. *Surg Radiol Anat* 2018;40:899-902. [DOI](#)
18. Lee J, Kim D. Bilateral variations in the origin and branches of the subscapular artery. *Clin Anat* 2008;21:783-5. [DOI](#)
19. Khaki AA, Shoja MA, Khaki A. A rare case report of subscapular artery. *Ital J Anat Embryol* 2011;116:56-9. [PubMed](#)
20. Jesus RC, Lopes MCH, Demarchi GTS, Ruiz CR, Wafae N, Wafae GC. The subscapular artery and the thoracodorsal branch: an anatomical study. *Folia Morphol* 2008;67:58-62. [PubMed](#)
21. Kawamura K, Yajima H, Kobata Y, Shigematsu K, Takakura Y. Anatomy of Y-shaped configurations in the subscapular arterial system and clinical application to harvesting flow-through flaps. *Plast Reconstr Surg* 2005;116:1082-9. [DOI](#) [PubMed](#)
22. Chim H, Cohen-Shohet RN, Chopan M, Oberhofer HM, Buchanan PJ. Supine harvest of vascularised scapular bone grafts-Anatomical study and clinical application. *Injury* 2022;53:1038-43. [DOI](#) [PubMed](#)
23. Imaue S, Osada R, Heshiki W, et al. Presurgical imaging of the subscapular artery with three-dimensional-computed tomography angiography: application to harvesting subscapular system free-flaps. *Clin Anat* 2023:online ahead of print. [DOI](#) [PubMed](#)
24. Barrett TF, Orłowski H, Rich J, Jackson RS, Pipkorn P, Puram SV. Anatomic variants of the subscapular-thoracodorsal arterial system: a radiologic analysis of 200 arterial systems. *Oral Oncol* 2022;125:105682. [DOI](#) [PubMed](#) [PMC](#)
25. Seitz A, Papp S, Papp C, Maurer H. The anatomy of the angular branch of the thoracodorsal artery. *Cells Tissues Organs* 1999;164:227-36. [DOI](#) [PubMed](#)
26. Sahovaler A, Low H, Laxague F, et al. Variations of the thoracodorsal axis: application for scapular tip free flap harvesting. *Oral Maxillofac Surg* 2022;26:619-23. [DOI](#)
27. Ghassemi A, Köhlen D, Braunschweig T, Modabber A, Prescher A, Nanhekan L. Histopathological differences of the pedicle artery in commonly used free flaps: the influence of age, gender, and side. *J Oral Maxillofac Surg* 2016;74:836-43. [DOI](#) [PubMed](#)
28. Gibber MJ, Clain JB, Jacobson AS, et al. Subscapular system of flaps: an 8-year experience with 105 patients. *Head Neck* 2015;37:1200-6. [DOI](#)
29. Etyreddy AR, Chen CL, Zenga J, Simon LE, Pipkorn P. Complications and outcomes of chimeric free flaps: a systematic review. *Otolaryngol Head Neck Surg* 2019;161:568-75. [DOI](#) [PubMed](#)
30. Clark JR, Vesely M, Gilbert R. Scapular angle osteomyogenous flap in postmaxillectomy reconstruction: defect, reconstruction, shoulder function, and harvest technique. *Head Neck* 2008;30:10-20. [DOI](#) [PubMed](#)
31. Stevens JR, Rosko AJ, Marchiano E, et al. The Spider limb positioner in subscapular system free flaps. *Oral Oncol* 2018;85:24-8. [DOI](#)
32. Nishimura T, Furukawa M, Koshima I. Scapular bone flap harvests of patients in a supine position. *Laryngoscope* 2004;114:1130-2. [DOI](#)
33. Eskander A, Kang SY, Ozer E, et al. Supine positioning for the subscapular system of flaps: a pictorial essay. *Head Neck* 2018;40:1068-72. [DOI](#)
34. Feng AL, Nasser HB, Casper KA, et al. Lateral border and scapular tip free flaps: old school versus new school. *Head Neck* 2022;44:576-81. [DOI](#)
35. Deganello A, Rampinelli V, Gualtieri T, Piazza C. Versatility of the subscapular system of flaps in head and neck oncologic reconstruction. *Curr Opin Otolaryngol Head Neck Surg* 2022;30:161-7. [DOI](#) [PubMed](#) [PMC](#)
36. Deane EC, Liu AQ, Nguyen S, Anderson DW, Durham JS, Prisman E. Synchrony in head and neck surgery: feasibility and outcomes of simultaneous scapular free flap reconstruction. *Head Neck* 2022;44:760-9. [DOI](#) [PubMed](#)



37. Bender-Heine A, Young G, Moy J, Weedman S, Wax MK. Application of the spider limb positioner to subscapular system free flaps. *Laryngoscope* 2021;131:525-8. [DOI](#) [PubMed](#)
38. Liu AQ, Deane EC, Heffernan A, Ji Y, Durham JS, Prisman E. Patient-reported outcomes and morbidity after head and neck reconstructions: an evaluation of fibular and scapular free flaps. *Oral Oncol* 2022;132:106019. [DOI](#) [PubMed](#)
39. Wolter GL, Swendseid BP, Sethuraman S, et al. Advantages of the scapular system in mandibular reconstruction. *Head Neck* 2023;45:307-15. [DOI](#)
40. Ferrari S, Ferri A, Bianchi B, Varazzani A, Perlangeli G, Sesenna E. Donor site morbidity after scapular tip free flaps in head-and-neck reconstruction. *Microsurg* 2015;35:447-50. [DOI](#) [PubMed](#)
41. Wallner J, Rieder M, Schwaiger M, Remschmidt B, Zemann W, Pau M. Donor site morbidity and quality of life after microvascular head and neck reconstruction with a chimeric, thoracodorsal, perforator-scapular flap based on the angular artery (TDAP-Scap-aa flap). *J Clin Med* 2022;11:4876. [DOI](#) [PubMed](#) [PMC](#)
42. Rubin SJ, Sayre KS, Kovatch KJ, Ali SA, Hanks JE. Segmental mandibular reconstruction in patients with poor lower extremity perfusion, vessel-depleted necks and/or profound medical frailty. *Curr Opin Otolaryngol Head Neck Surg* 2021;29:407-18. [DOI](#) [PubMed](#)
43. Hernando J, Aguilar-Salvatierra A, Leizaola-Cardesa IO, et al. Reconstruction of a compound oromandibular defect by means of chimeric scapular-parascapular free flap assisted by virtual surgical planning. *J Craniofac Surg* 2018;29:e248-50. [DOI](#)
44. Kass JI, Prisman E, Miles BA. Guide design in virtual planning for scapular tip free flap reconstruction. *Laryngoscope Investig Otolaryngol* 2018;3:162-8. [DOI](#) [PubMed](#) [PMC](#)
45. Tran KL, Wang E, Fels S, Hodgson A, Prisman E. Versatility of a single piece scapular tip and lateral border free flap for mandibular reconstruction: a virtual study on angle correspondence. *Oral Oncol* 2021;121:105379. [DOI](#)
46. Swendseid BP, Roden DF, Vimawala S, et al. Virtual surgical planning in subscapular system free flap reconstruction of midface defects. *Oral Oncol* 2020;101:104508. [DOI](#)
47. Swendseid B, Kumar A, Sweeny L, et al. Natural history and consequences of nonunion in mandibular and maxillary free flaps. *Otolaryngol Head Neck Surg* 2020;163:956-62. [DOI](#)
48. Davies JC, Chan HHL, Yao CMKL, et al. Association of plate contouring with hardware complications following mandibular reconstruction. *Laryngoscope* 2022;132:61-6. [DOI](#)
49. Zrnc TA, Tomic J, Tomazic PV, et al. Complex mandibular reconstruction for head and neck squamous cell carcinoma-the ongoing challenge in reconstruction and rehabilitation. *Cancers* 2020;12:3198. [DOI](#) [PubMed](#) [PMC](#)
50. Frodel JL Jr, Funk GF, Capper DT, Fridrich KL, Blumer JR, Haller JR, Hoffman HT. Osseointegrated implants: a comparative study of bone thickness in four vascularized bone flaps. *Plast Reconstr Surg* 1993;92:449-55; discussion 456-8. [DOI](#) [PubMed](#)
51. Harada H, Shimamoto H, Oikawa Y, et al. Mandibular reconstruction with scapular systems: a single-center case series involving 208 flaps. *Plast Reconstr Surg* 2021;148:625-34. [DOI](#)
52. Burgess M, Leung M, Chellapah A, Clark JR, Batstone MD. Osseointegrated implants into a variety of composite free flaps: a comparative analysis. *Head Neck* 2017;39:443-7. [DOI](#) [PubMed](#)
53. Khadembaschi D, Russell P, Beech N, Batstone MD. Osseointegrated implant survival, success and prosthodontic outcomes in composite free flaps: a 10-year retrospective cohort study. *Clin Oral Implants Res* 2021;32:1251-61. [DOI](#) [PubMed](#)
54. Laverty DP, Addison O, Wubie BA, et al. Outcomes of implant-based oral rehabilitation in head and neck oncology patients-a retrospective evaluation of a large, single regional service cohort. *Int J Implant Dent* 2019;5:8. [DOI](#) [PubMed](#) [PMC](#)
55. Tang AL, Bearely S, Mannion K. The expanding role of scapular free-flaps. *Curr Opin Otolaryngol Head Neck Surg* 2017;25:411-5. [DOI](#) [PubMed](#)