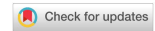

Technical Note

Open Access



Laparoscopic liver ALPPS - How I do it

Rubén Ciria^{1,2} , Manuel Durán^{1,2} , Rafael Calleja^{1,2} , José Manuel Pérez-de-Villar¹, Javier Briceño^{1,2}

¹Unit of Hepatobiliary Surgery and Liver Transplantation, Reina Sofia University Hospital, Cordoba 14004, Spain.

²Maimonides Biomedical Research Institute of Cordoba (IMIBIC), Reina Sofia University Hospital, Cordoba 14004, Spain.

Correspondence to: Dr. Rubén Ciria, Unit of Hepatobiliary Surgery and Liver Transplantation, Reina Sofia University Hospital, Avenida Menendez Pidal s/n, Cordoba 14004, Spain. E-mail: rubenciria@gmail.com

How to cite this article: Ciria R, Durán M, Calleja R, Pérez-de-Villar JM, Briceño J. Laparoscopic liver ALPPS - How I do it. *Mini-invasive Surg* 2024;8:10. <https://dx.doi.org/10.20517/2574-1225.2023.126>

Received: 7 Nov 2023 **First Decision:** 21 Feb 2024 **Revised:** 24 Jun 2024 **Accepted:** 28 Jun 2024 **Published:** 10 Jul 2024

Academic Editor: Giulio Belli **Copy Editor:** Pei-Yun Wang **Production Editor:** Pei-Yun Wang

Abstract

In complex oncological liver resections, insufficient future liver remnant (FLR) volume may become the most challenging problem to deal with in the postoperative setting. The Associating Liver Partition and Portal Vein Ligation for Staged Hepatectomy (ALPPS) is one of the techniques described for inducing hepatic hypertrophy and achieving an adequate FLR. The technique initially described is performed by a complete bipartition of the liver in the first operation and a portal vein ligation to achieve occlusion of the intrahepatic circulation followed by a major hepatectomy in the second operation once an adequate FLR has been reached. With the introduction of minimally invasive liver surgery, these procedures can be performed by laparoscopic or robotic approach. We aim to provide a comprehensive overview of ALPPS, highlighting key technical aspects. Furthermore, the main aspects of this technique based on current evidence, such as indications, outcomes, strengths, limitations and potential complications, will be analyzed.

Keywords: Minimally invasive, ALPPS, two-stage hepatectomy, surgical oncology, surgical technique, liver hypertrophy, future liver remnant (FLR)

INTRODUCTION

Despite the extraordinary progress made in liver surgery in recent years, insufficient liver volume after hepatectomy still represents an important clinical challenge and precludes patients from upfront major liver resection, as it predisposes them to high rates of morbidity and mortality^[1,2]. For years, preoperative portal vein embolization (PVE) has been the standard approach for patients undergoing major hepatectomy with



© The Author(s) 2024. **Open Access** This article is licensed under a Creative Commons Attribution 4.0 International License (<https://creativecommons.org/licenses/by/4.0/>), which permits unrestricted use, sharing, adaptation, distribution and reproduction in any medium or format, for any purpose, even commercially, as long as you give appropriate credit to the original author(s) and the source, provide a link to the Creative Commons license, and indicate if changes were made.



expected insufficient future liver remnant (FLR)^[3]. In patients with colorectal liver metastases (CRLM) with extensive bilobar disease not amenable to curative one-stage resection due to insufficient FLR, neoadjuvant chemotherapy followed by two-stage hepatectomy (TSH) was described as a potential curative option^[4-6]. In 2012, Schnitzbauer *et al.* first introduced the procedure of associating liver partition and portal vein ligation for staged hepatectomy (ALPPS) as an alternative for FLR augmentation^[7].

ALPPS is a two-stage procedure that first combines portal vein occlusion with (partial/complete) parenchymal transection to induce rapid growth of the FLR; in the second stage, usually within 7-14 days after the first stage, and when adequate FLR hypertrophy has been obtained, hepatectomy is completed^[7]. It was introduced as the potential surgical response to the high dropout rates seen in other bridging strategies^[8]. Most of the accumulated experience with ALPPS is described in bilobar colorectal metastases; however, some other series have shown its potential in less frequent hepatic tumors or even in hepatitis-related hepatocellular carcinoma (HCC)^[9-11].

ALPPS has been described as a high-risk operation due to the high interstage morbidity, including bile leak, septicaemia and liver failure^[12-14]. Initial series of ALPPS reported mortality rates of up to 25%^[15]. These initial problems were the main pitfall of a technique that, conversely, eliminates the main reason for the failure of two-stage classical hepatectomies, which is disease progression during the waiting period of FLR hypertrophy. Compared to other staged approaches, ALPPS induces rapid liver hypertrophy that reduces stage intervals. In addition, it may also be an effective alternative as a rescue after PVE failure^[16]. Outcomes of ALPPS have significantly improved over recent years due to meticulous patient selection, procedure technical refinements and introduction of several modifications, such as partial-ALPPS, hybrid-ALPPS, mini-ALPPS, ablation-assisted ALPPS, tourniquet-ALPPS and/or minimally invasive approaches^[17-24]. More recent analyses have demonstrated that continual research, improved understanding of the physiopathology of the procedure, and technical refinements have resulted in evident benefits, with a drop in 90-day mortality from 17% to 4% and major interstage complications from 10% to 3%^[25]. The achievement of satisfactory long-term results relies on a careful patient selection and attempt to reduce perioperative complications. However, in the context of ALPPS, achieving this balance can be challenging. In this regard, a prediction model identifying predisposing risk factors to futile outcomes in ALPPS has been reported^[26].

MINIMALLY INVASIVE ALPPS

Minimally invasive liver surgery (MILS) is one of the most important advances in liver surgery in recent years. The first laparoscopic liver resections (LLRs) were reported 30 years ago^[27,28]. Since the first Louisville Consensus, laparoscopic liver surgery has been recognized as a safe and effective approach to perform liver resections by trained surgeons. Large meta-analyses reported better results in both short- and long-term outcomes for laparoscopic and robotic approaches^[29,30-34]. The progressive dissemination of MILS has led liver surgeons to perform complex liver resections with adequate results^[35]. In this regard, ALPPS is not an exception. In addition to the inherent advantages of MILS, such as reduced blood loss, faster recovery and shorter hospital stay, there are specific benefits, including a diminished formation of adhesions between stages, thereby facilitating the subsequent stage of the procedure. Nonetheless, it is essential to acknowledge that this approach involves technical complexity and a challenging learning curve, and may lead to longer operative times^[36].

Table 1 summarizes the outcomes from the most relevant series related to minimally invasive ALPPS (MI-ALPPS), excluding case reports. Only two of these series included robotic approaches^[39,40], and only one included a minimally invasive surgery (MIS) approach in both stages^[39]. Two important observations should be noted from these studies: (a) Morbidity rate reported is heterogeneous, ranging between 0%-24% for

Table 1. Summary of studies performing minimally invasive ALPPS

Author	Year	ALPPS technique		Full MIS	EBL (mL)		FLVR hypertrophy (%)	Length of hospital stay (days)		Major complications (%)		90-day mortality (%)
		Stage 1	Stage 2		Stage 1	Stage 2		Stage 1	Stage 2	Stage 1	Stage 2	
Gall et al. ^[37]	2015	L-RALPPS (n = 4)	O-RH (n = 4)	N	NR	NR	62	NR	NR	20	NR	0
Truant et al. ^[38]	2018	L-partial ALPPS (n = 5)	O-REH (n = 5)	N	250	550	60	7	12	0	40	0
Jiao et al. ^[39]	2019	L-RALPPS (n = 24) R-RALPPS (n = 2)	O-RH (n = 14) L-RH (n = 4) R-RH (n = 1) O-REH (n = 4) L-REH (n = 1)	N	310	300	80.7	9.5	8	3.85	15.3	3.8
Machado et al. ^[20]	2017	L-ALPPS (n = 10)	L-RH (n = 3) L-REH (n = 7)	Y	200	320	118	NR	NR	0	0	0
Serenari et al. ^[40]	2020	L-ALPPS (n = 7) L-mini-ALPPS (n = 6) R-ALPPS (n = 1)	L-RH (n = 2) L-REH (n = 5)	Y	NR	NR	62	6.5	12	14.2	8.3	0
Li et al. ^[41]	2021	L-RALPPS (n = 60)	O-RH (n = 32) O-REH (n = 28)	N	165	628	45.7	NR	23.4	13.3	53.3	0

Major complications were defined as Clavien–Dindo classification \geq IIIA grade. ALPPS: Associated liver partition with portal vein ligation for staged hepatectomy; MIS: minimally invasive surgery; EBL: estimated blood loss; FLRV: future liver remnant volume; RALPPS: radiofrequency-assisted ALPPS; RH: right hepatectomy; REH: right extended hepatectomy; NR: Not Reported; N: not; Y: yes.

Clavien–Dindo \geq IIIA grade complications in stage 1 and 0%-53% in stage 2; and (b) the highest 90-day mortality rate reported was 3.8%. Case selection and indications (HCC vs. CRLM) may influence these outcomes. Moreover, the approach performed during stages is biased. Only the full MIS procedure was performed in two studies^[20,40]. These studies reported a 90-day mortality rate of 0% and a Clavien–Dindo \geq IIIA grade complication rate of approximately 0%-14.2% in stage 1 and 0%-8.3% in stage 2. Therefore, the evidence supporting minimal invasiveness is weak and mainly supported by case reports or case series, which is a major limitation^[42]. Additionally, the heterogeneity among the series concerning the ALPPS techniques performed, indications or approaches in different stages makes it challenging to properly evaluate postoperative clinical outcomes. Evidence about open versus modified MI-ALPPS is lacking, making the assessment of the MIS role difficult. Moreover, reports about the robotic approach are limited. Considering these issues, the influence of MIS in ALPPS procedures is still uncertain.

HOW I DO A LAPAROSCOPIC ALPPS

The ALPPS technique and technical modifications described can be mostly performed by a minimally invasive approach, always in experienced hands. A step-

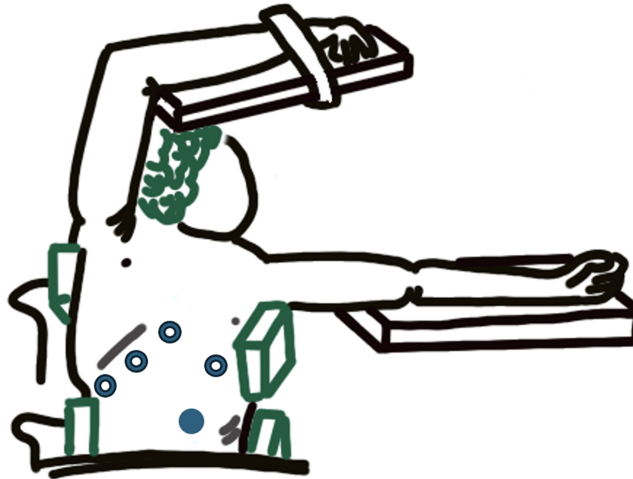


Figure 1. Patient and trocar positioning scheme.

by-step description of how different fully laparoscopic ALPPS techniques are performed is provided. Most of the modifications reported in current literature are based on full or partial parenchymal partitioning and in different vascular occlusion techniques.

Laparoscopic classic ALPPS

First stage

The patient is positioned in a 30° left decubitus tilt and in an anti-Trendelenburg position. Five access trocars are used for the procedure, keeping intraabdominal pressure around 12-14 mmHg [Figure 1]. Trocars are placed in the following locations: at the umbilical region (12 mm), subxiphoid region (5 mm), below the costal margin on the right midclavicular line (12 mm), below the costal margin on the right axillary line (5 mm), and one more trocar is inserted between the last two (5 mm).

- Similar to open ALPPS, the initial step is to explore the entire abdominal cavity. A meticulous intraoperative ultrasound (IOUS) examination of the FLR is mandatory. If there were lesions in the FLR, they must be resected. The gallbladder is removed. Liver is not mobilized and only falciform ligament is sectioned.
- The right portal vein is identified and transected extrahepatic hilar approach [Figure 2A]. This is usually performed using an endostapler. Parenchymal transection is performed by a caudal approach [Figure 2B].
- After completing the liver transection and portal vein ligation, confirming the complete deportalization of the tumor-bearing liver using IOUS is crucial.
- Since liver atrophy and contralateral hypertrophy may frequently alter the porta hepatis anatomy after stage 1, it is strongly recommended to mark the vasculobiliary structures of the tumor-bearing liver with vessel loops to facilitate their identification during stage 2 [Figure 2C and D]. It is also advisable but not mandatory to place vessel loops surrounding the right and middle hepatic veins.
- A hemostatic patch is placed on the transection surface to minimize adhesion between the divided sections of the liver and a Jackson-Pratt drain is placed between partitioned livers. Hemostasis control must be rigorous.

Second stage

Although variable, it is our routine practice to perform a computed tomography (CT) scan on days 10-14 after the first procedures to check volumetric status. If adequate growth is observed, the patient undergoes

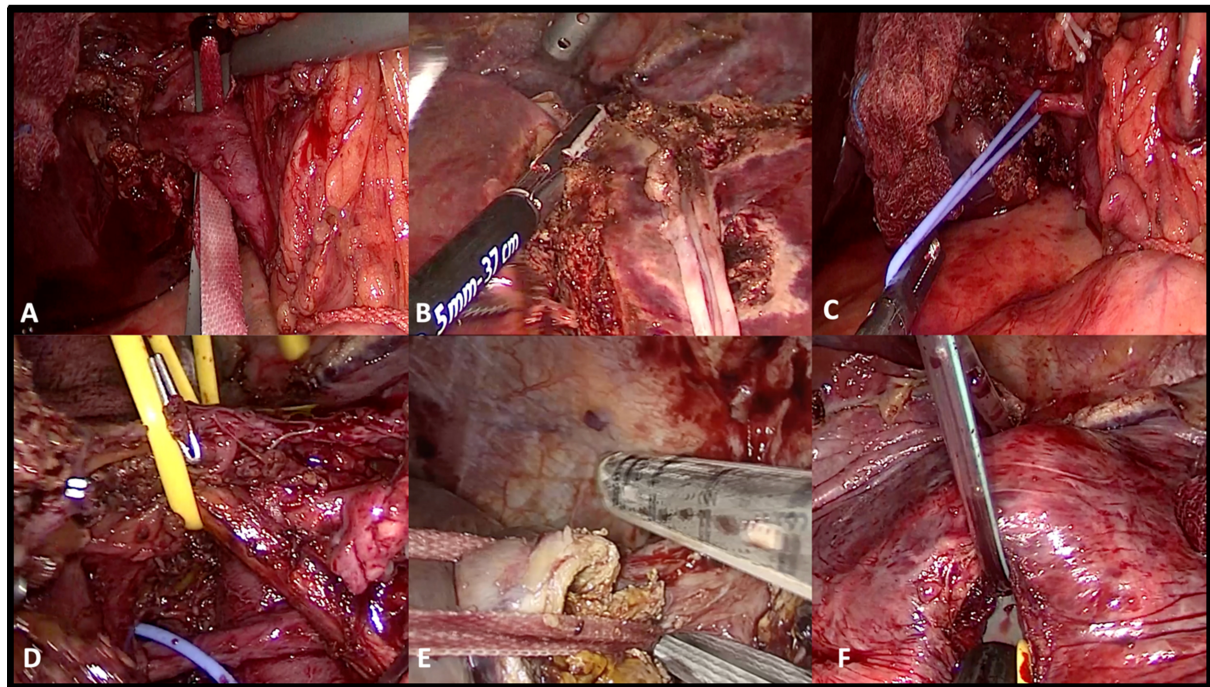


Figure 2. Different steps of the classic laparoscopic ALPPS; some of them are common with the ALPPS tourniquet. (A) Dissection of the right portal pedicle through Sugioka Gates; (B) Transection of liver parenchyma; (C) Right hepatic artery identification and referral; (D) Identification of right bile duct; (E) Right hepatic vein section with endostapler; (F) Hanging manoeuvre. ALPPS: Associating liver partition and portal vein ligation for staged hepatectomy.

the second stage of ALPPS. Usually, area surrounding parenchymal transection is affected by adhesions and clots which can be dissected. Vascular structures at the hilum of the affected hemiliver are identified by locating the vessel loops surrounding them. Subsequently, endostaplers are employed to transect the right hepatic vein and the middle hepatic vein if indicated [Figure 2E]. Ultrasonography (US) is used to assess liver perfusion and discard lesions in the future liver parenchyma.

Laparoscopic tourniquet ALPPS

First stage

This technique was initially described by Robles *et al.*^[43]. In contrast to classical ALPPS, there is no bipartition of the parenchyma. A refined and updated version of this technique has been reported recently by our group including advanced laparoscopic techniques such as pure hanging maneuver and access throughout the liver gates reported by Sugioka *et al.*^[17,44-46]. Figure 3 illustrates the first part of the ALPPS tourniquet procedure. In addition, our group published this technique in a step-by-step video to help the understanding of the technique due to its complexity^[45].

Tourniquet ALPPS avoids liver splitting in the initial stage, resulting in a more conservative intervention. This leads to avoiding potential complications such as blood loss and bile leak associated with the initial stage of classic ALPPS. Moreover, segment IV remains connected to the hilar bifurcation, preventing ischemic necrosis. Patients undergoing laparoscopic Tourniquet ALPPS may benefit from early discharge after the first stage. In the second stage, minimal adhesions are observed, facilitating the liver transection along the tourniquet-induced ischemic line, with limited bleeding^[18,45].

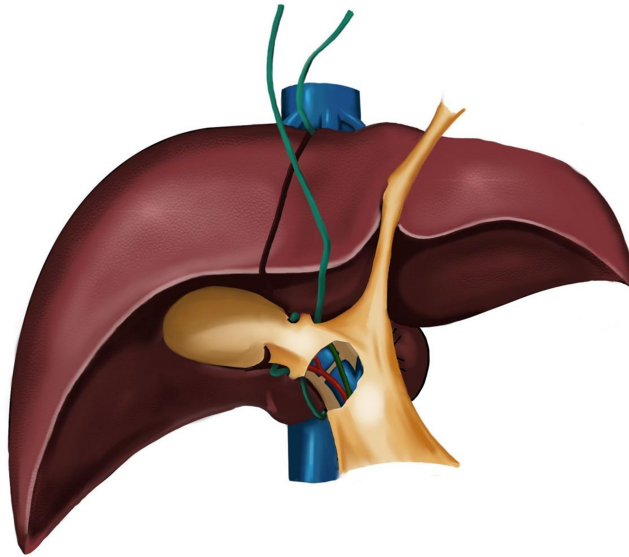


Figure 3. First part of ALPPS tourniquet procedure. The green tape shows the position of the tourniquet; after placement, it is tightened along the marked transection line, approximately 1 cm deep. It can be seen how it should pass between the right and middle suprahepatic vein and the passages made through Sugioka's gates. The section of the right portal vein is also shown. ALPPS: Associating liver partition and portal vein ligation for staged hepatectomy.

The patient is placed in the 30° semi-left lateral decubitus and reverse Trendelenburg position. Five trocars are placed. Pneumoperitoneum pressure is set at 12–14 mmHg. Trocars are placed in the following locations: at the umbilical region (12 mm), subxiphoid region (5 mm), below the costal margin on the right midclavicular line (12 mm), below the costal margin on the right axillary line (5 mm), and one more trocar is inserted between the last two (5 mm). Resection of the lesions located in the FLR is guided by ultrasound, if necessary, without mobilizing the liver. Cholecystectomy is performed.

- Similar to classic ALPPS, the right portal vein is identified and transected by extrahepatic hilar approach, as previously described.
- In our technique, a careful dissection of the retrohepatic tunnel is conducted to finally perform a hanging maneuver [Figure 2F]^[47]. In the case of a right hepatectomy in the second stage, the tourniquet is placed in the main portal fissure between the right and middle hepatic suprahepatic vein (Cantlie's line) using the hanging maneuver. Then, the tape is passed posterior to the right portal pedicle using extraglissonian approach to prevent occlusion of the right artery and right bile duct. In the case of a right trisectionectomy in the second stage, the tourniquet is placed in the umbilical fissure, passed between the left and middle suprahepatic veins, passed through Rex's recess and continued posterior to left portal pedicle. The left portal pedicle is identified and encircled by an extraglissonian approach to prevent an occlusion of the left artery and left bile duct.
- We have described a technical variant in case of ALPPS through the Cantlie's line. The Sugioka Gates G4, G5 and G6 are identified. The hanging tape is passed from G6 to G5 and then throughout G4 in case of a right hepatectomy. The Sugioka gates approach avoids uncontrolled damage, especially on the bile duct bifurcation, and facilitates subsequent second stage right hemihepatectomy.
- A 1–2 cm deep liver parenchyma transection is performed using bipolar and sealing devices combined with an ultrasonic dissector. Exhaustive hemostasis is mandatory.
- The tape is then tightened firmly. We strongly recommend to check with doppler IOUS that collaterals from MHV in the case of a right hepatectomy are collapsed and that main trunk of the MHV is kept intact to avoid congestion in the remnant.

Second stage

Similarly to classic ALPPS, a CT scan on days 10-14 after the first procedure to check volumetric status is performed. If adequate remnant volume is achieved, the procedure is finalized by a laparoscopic right hepatectomy or right trisectionectomy. In case of insufficient liver hypertrophy, the embolization of right hepatic vein or both middle and right hepatic vein to obtain a complete Liver venous deprivation (or “double vein embolization”) may be performed to increase FLR. In case of insufficient liver hypertrophy or disease progression, the tourniquet should ideally be removed by a minimally invasive approach. Blunt dissection and the use of saline irrigation may facilitate removal of adhesions during tourniquet removal. However, this procedure should not be underestimated as iatrogenic injury may occur during surgery. In our experience, we only had to remove one tourniquet and there were no incidences.

The positioning and access trocars are the same as those used in the first stage. In the liver surface, the tape and the knot will be observed. By releasing the knot, an ischemic line is observed and transection in this area becomes easier. The tape is employed to perform a hanging maneuver that facilitates the transection plane. By pulling up the tape, access to the transection plane is easily gained towards the anterior surface of the inferior vena cava (IVC). However, it should be noted that the tape may cause tight adhesions in the anterior surface of IVC that might be dissected with caution. The last step includes hepatic veins and Glissonean pedicles section using endostaplers.

CONCLUSION

MI-ALPPS is a technique with a high degree of complexity and must be performed by surgeons with expertise in MILS. The preliminary evidence suggests that it may be safe with a lower morbidity and mortality rate relative to open series. However, the number of series is limited, and caution should be taken to get powerful conclusions regarding the application of this technique.

DECLARATIONS

Authors' contributions

Conception and design of the study: Ciria R

Data review: Durán M, Calleja R, Pérez-de-Villar JM

Draft manuscript preparation: Durán M, Calleja R, Pérez-de-Villar JM

Critical review: Ciria R, Briceño J

All authors reviewed the results and approved the final version of the manuscript.

Availability of data and materials

Not applicable.

Financial support and sponsorship

None.

Conflicts of interest

All authors declared that there are no conflicts of interest.

Ethical approval and consent to participate

As this is a technical review article and no patient data is presented, it did not need to be submitted to an ethics committee. Informed consent was obtained from the patient for the publication of the images.

Consent for publication

Not applicable.

Copyright

© The Author(s) 2024.

REFERENCES

- Shindoh J, Tzeng CW, Aloia TA, et al. Optimal future liver remnant in patients treated with extensive preoperative chemotherapy for colorectal liver metastases. *Ann Surg Oncol* 2013;20:2493-500. DOI PubMed PMC
- Narita M, Oussoultzoglou E, Fuchshuber P, et al. What is a safe future liver remnant size in patients undergoing major hepatectomy for colorectal liver metastases and treated by intensive preoperative chemotherapy? *Ann Surg Oncol* 2012;19:2526-38. DOI PubMed
- Narula N, Aloia TA. Portal vein embolization in extended liver resection. *Langenbecks Arch Surg* 2017;402:727-35. DOI PubMed
- Adam R, Laurent A, Azoulay D, Castaing D, Bismuth H. Two-stage hepatectomy: a planned strategy to treat irresectable liver tumors. *Ann Surg* 2000;232:777-85. DOI PubMed PMC
- Kianmanesh R, Sauvanet A, Hentic O, et al. Two-step surgery for synchronous bilobar liver metastases from digestive endocrine tumors: a safe approach for radical resection. *Ann Surg* 2008;247:659-65. DOI PubMed
- Jaeck D, Oussoultzoglou E, Rosso E, Greget M, Weber JC, Bachellier P. A two-stage hepatectomy procedure combined with portal vein embolization to achieve curative resection for initially unresectable multiple and bilobar colorectal liver metastases. *Ann Surg* 2004;240:1037-51. DOI PubMed PMC
- Schnitzbauer AA, Lang SA, Goessmann H, et al. Right portal vein ligation combined with in situ splitting induces rapid left lateral liver lobe hypertrophy enabling 2-staged extended right hepatic resection in small-for-size settings. *Ann Surg* 2012;255:405-14. DOI PubMed
- Narita M, Oussoultzoglou E, Ikai I, Bachellier P, Jaeck D. Right portal vein ligation combined with in situ splitting induces rapid left lateral liver lobe hypertrophy enabling 2-staged extended right hepatic resection in small-for-size settings. *Ann Surg* 2012;256:e7-8. DOI PubMed
- Chan A, Zhang WY, Chok K, et al. ALPPS versus portal vein embolization for hepatitis-related hepatocellular carcinoma: a changing paradigm in modulation of future liver remnant before major hepatectomy. *Ann Surg* 2021;273:957-65. DOI PubMed
- Petrowsky H, Linecker M, Raptis DA, et al. First long-term oncologic results of the ALPPS procedure in a large cohort of patients with colorectal liver metastases. *Ann Surg* 2020;272:793-800. DOI PubMed
- Lai Q, Mennini G, Larghi Laureiro Z, Rossi M. Uncommon indications for associating liver partition and portal vein ligation for staged hepatectomy: a systematic review. *Hepatobiliary Surg Nutr* 2021;10:210-25. DOI PubMed PMC
- Sandström P, Røsek BI, Sparrelid E, et al. ALPPS improves resectability compared with conventional two-stage hepatectomy in patients with advanced colorectal liver metastasis: results from a scandinavian multicenter randomized controlled trial (LIGRO trial). *Ann Surg* 2018;267:833-40. DOI PubMed PMC
- Schadde E, Ardiles V, Robles-Campos R, et al; ALPPS Registry Group. Early survival and safety of ALPPS: first report of the International ALPPS Registry. *Ann Surg* 2014;260:829-38. DOI PubMed
- Schlegel A, Lesurtel M, Melloul E, et al. ALPPS: from human to mice highlighting accelerated and novel mechanisms of liver regeneration. *Ann Surg* 2014;260:839-47. DOI PubMed
- Belli A, Fantini C, Cioffi L, D'Agostino A, Belli G. Mils for HCC: the state of art. *Updates Surg* 2015;67:105-9. DOI PubMed
- Sparrelid E, Hasselgren K, Røsek BI, et al. How should liver hypertrophy be stimulated? A comparison of upfront associating liver partition and portal vein ligation for staged hepatectomy (ALPPS) and portal vein embolization (PVE) with rescue possibility. *Hepatobiliary Surg Nutr* 2021;10:1-8. DOI PubMed PMC
- Ciria R, Briceño J. The ALPPS procedure - As limited procedures as possible, leads to improved survival. *Hepatobiliary Surg Nutr* 2022;11:636-9. DOI PubMed PMC
- Robles-Campos R, Brusadin R, López-López V, et al. A new surgical technique variant of partial ALPPS (tourniquet partial-ALPPS). *Ann Surg* 2021;273:e22-4. DOI PubMed
- Petrowsky H, Györi G, de Oliveira M, Lesurtel M, Clavien PA. Is partial-ALPPS safer than ALPPS? A single-center experience. *Ann Surg* 2015;261:e90-2. DOI PubMed
- Machado MA, Makdissi FF, Surjan RC, Basseres T, Schadde E. Transition from open to laparoscopic ALPPS for patients with very small FLR: the initial experience. *HPB* 2017;19:59-66. DOI PubMed
- Li J, Kantas A, Ittrich H, et al. Avoid "all-touch" by hybrid ALPPS to achieve oncological efficacy. *Ann Surg* 2016;263:e6-7. DOI PubMed
- Cillo U, Gringeri E, Feltracco P, et al. Totally laparoscopic microwave ablation and portal vein ligation for staged hepatectomy : a new minimally invasive two-stage hepatectomy. *Ann Surg Oncol* 2015;22:2787-8. DOI PubMed
- de Santibañes E, Alvarez FA, Ardiles V, Pekolj J, de Santibañes M. Inverting the ALPPS paradigm by minimizing first stage impact: the Mini-ALPPS technique. *Langenbecks Arch Surg* 2016;401:557-63. DOI PubMed
- Vicente E, Quijano Y, Ielpo B, Fabra I. First ALPPS procedure using a total robotic approach. *Surg Oncol* 2016;25:457. DOI PubMed
- Linecker M, Björnsson B, Stavrou GA, et al. Risk adjustment in ALPPS is associated with a dramatic decrease in early mortality and morbidity. *Ann Surg* 2017;266:779-86. DOI PubMed
- Linecker M, Stavrou GA, Oldhafer KJ, et al. The ALPPS risk score: avoiding futile use of ALPPS. *Ann Surg* 2016;264:763-71. DOI PubMed

27. Azagra JS, Goergen M, Gilbert E, Jacobs D. Laparoscopic anatomical (hepatic) left lateral segmentectomy-technical aspects. *Surg Endosc* 1996;10:758-61. DOI PubMed
28. Reich H, McGlynn F, DeCaprio J, Budin R. Laparoscopic excision of benign liver lesions. *Obstet Gynecol* 1991;78:956-8. PubMed
29. Ciria R, Cherqui D, Geller DA, Briceno J, Wakabayashi G. Comparative short-term benefits of laparoscopic liver resection: 9000 cases and climbing. *Ann Surg* 2016;263:761-77. DOI PubMed
30. Guan R, Chen Y, Yang K, et al. Clinical efficacy of robot-assisted versus laparoscopic liver resection: a meta analysis. *Asian J Surg* 2019;42:19-31. DOI PubMed
31. Montalti R, Berardi G, Patrii A, Vivarelli M, Troisi RI. Outcomes of robotic vs laparoscopic hepatectomy: a systematic review and meta-analysis. *World J Gastroenterol* 2015;21:8441-51. DOI PubMed PMC
32. Hu L, Yao L, Li X, Jin P, Yang K, Guo T. Effectiveness and safety of robotic-assisted versus laparoscopic hepatectomy for liver neoplasms: a meta-analysis of retrospective studies. *Asian J Surg* 2018;41:401-16. DOI PubMed
33. Zhang L, Yuan Q, Xu Y, Wang W. Comparative clinical outcomes of robot-assisted liver resection versus laparoscopic liver resection: a meta-analysis. *PLoS One* 2020;15:e0240593. DOI PubMed PMC
34. Ziogas IA, Kakos CD, Moris DP, et al. Systematic review and meta-analysis of open versus laparoscopy-assisted versus pure laparoscopic versus robotic living donor hepatectomy. *Liver Transpl* 2023;29:1063-78. DOI PubMed
35. Ciria R, Berardi G, Alconchel F, et al. The impact of robotics in liver surgery: a worldwide systematic review and short-term outcomes meta-analysis on 2,728 cases. *J Hepatobiliary Pancreat Sci* 2022;29:181-97. DOI PubMed
36. Cioffi L, Belli G, Izzo F, et al. Minimally invasive ALPPS procedure: a review of feasibility and short-term outcomes. *Cancers* 2023;15:1700. DOI PubMed PMC
37. Gall TMH, Sodergren MH, Frampton AE, et al. Radio-frequency-assisted liver partition with portal vein ligation (RALPP) for liver regeneration. *Ann Surg* 2015;261:e45-6. DOI PubMed
38. Truant S, El Amrani M, Baillet C, et al. Laparoscopic partial ALPPS: much better than ALPPS! *Ann Hepatol* 2019;18:269-73. DOI PubMed
39. Jiao LR, Fajardo Puerta AB, Gall TMH, et al. Rapid induction of liver regeneration for major hepatectomy (REBIRTH): a randomized controlled trial of portal vein embolisation versus ALPPS assisted with radiofrequency. *Cancers* 2019;11:302. DOI PubMed PMC
40. Serenari M, Ratti F, Zanello M, et al. Minimally invasive stage 1 to protect against the risk of liver failure: results from the hepatocellular carcinoma series of the associating liver partition and portal vein ligation for staged hepatectomy Italian registry. *J Laparoendosc Adv Surg Tech A* 2020;30:1082-9. DOI PubMed
41. Li J, Yang GS, Sun KJ, Ma Y, Bi XW, Han X. Clinical evaluation of modified ALPPS procedures based on risk-reduced strategy for staged hepatectomy. *Ann Hepatol* 2021;20:100245. DOI PubMed
42. Melandro F, Giovanardi F, Hassan R, et al. Minimally invasive approach in the setting of ALPPS procedure: a systematic review of the literature. *J Gastrointest Surg* 2019;23:1917-24. DOI PubMed
43. Robles R, Parrilla P, López-Conesa A, et al. Tourniquet modification of the associating liver partition and portal ligation for staged hepatectomy procedure. *Br J Surg* 2014;101:1129-34. DOI PubMed
44. Ciria R. ASO author reflections: technical steps for the standardization of laparoscopic liver tourniquet as a modified ALPPS procedure: a feasible option with equivalent results and reduced aggressiveness. *Ann Surg Oncol* 2022;29:2412-3. DOI PubMed
45. Ciria R, Ayllón MD, Padial A, et al. Totally laparoscopic tourniquet ALPPS: technical standardization by combining the pure hanging maneuver and the approach through the Sugioka gates. *Ann Surg Oncol* 2022;29:2410-1. DOI PubMed
46. Sugioka A, Kato Y, Tanahashi Y. Systematic extrahepatic Glissonean pedicle isolation for anatomical liver resection based on Laennec's capsule: proposal of a novel comprehensive surgical anatomy of the liver. *J Hepatobiliary Pancreat Sci* 2017;24:17-23. DOI PubMed PMC
47. Liddo G, Buc E, Nagarajan G, Hidaka M, Dokmak S, Belghiti J. The liver hanging manoeuvre. *HPB* 2009;11:296-305. DOI PubMed PMC