George *et al. Mini-invasive Surg* 2024;8:4
DOI: 10.20517/2574-1225.2023.102

Mini-invasive Surgery

Review

Open Access

Artificial intelligence in capsule endoscopy: development status and future expectations

Ashwin A. George[1], Jin Lin Tan[1,2], Joshua G. Kovoor[1,4], Alvin Lee[2], Brandon Stretton[1,2,4], Aashray K. Gupta[1], Stephen Bacchi[1,3], Biju George[1,2], Rajvinder Singh[1,2]

[1]Adelaide Medical School, University of Adelaide, Adelaide 5005, Australia.
[2]Department of Gastroenterology, Lyell McEwin Hospital, Adelaide 5112, Australia.
[3]Division of Medicine, Queen Elizabeth Hospital, Adelaide 5011, Australia.
[4]Department of Gastroenterology, Royal Adelaide Hospital, Adelaide 5000, Australia.

Correspondence to: Prof. Rajvinder Singh, Adelaide Medical School, University of Adelaide, 250 North Terrace, Adelaide 5005, Australia. E-mail: rajvinder.singh@sa.gov.au

How to cite this article: George AA, Tan JL, Kovoor JG, Lee A, Stretton B, Gupta AK, Bacchi S, George B, Singh R. Artificial intelligence in capsule endoscopy: development status and future expectations. *Mini-invasive Surg* 2024;8:4. https://dx.doi.org/10.20517/2574-1225.2023.102

Received: 23 Aug 2023 **First Decision:** 14 Dec 2023 **Revised:** 18 Feb 2024 **Accepted:** 28 Feb 2024 **Published:** 18 Mar 2024

Academic Editors: Jean François Rey, Giulio Belli, Michel Gagner **Copy Editor:** Pei-Yun Wang **Production Editor:** Pei-Yun Wang

Abstract

In this review, we aim to illustrate the state-of-the-art artificial intelligence (AI) applications in the field of capsule endoscopy. AI has made significant strides in gastrointestinal imaging, particularly in capsule endoscopy - a non-invasive procedure for capturing gastrointestinal tract images. However, manual analysis of capsule endoscopy videos is labour-intensive and error-prone, prompting the development of automated computational algorithms and AI models. While currently serving as a supplementary observer, AI has the capacity to evolve into an autonomous, integrated reading system, potentially significantly reducing capsule reading time while surpassing human accuracy. We searched Embase, Pubmed, Medline, and Cochrane databases from inception to 06 Jul 2023 for studies investigating the use of AI for capsule endoscopy and screened retrieved records for eligibility. Quantitative and qualitative data were extracted and synthesised to identify current themes. In the search, 824 articles were collected, and 291 duplicates and 31 abstracts were deleted. After a double-screening process and full-text review, 106 publications were included in the review. Themes pertaining to AI for capsule endoscopy included active gastrointestinal bleeding, erosions and ulcers, vascular lesions and angiodysplasias, polyps and tumours, inflammatory bowel disease, coeliac disease, hookworms, bowel prep assessment, and multiple lesion detection. This review provides current insights into the impact of AI on capsule endoscopy as of 2023. AI holds the potential for faster and precise readings and the prospect of autonomous image analysis. However, careful

© The Author(s) 2024. **Open Access** This article is licensed under a Creative Commons Attribution 4.0 International License (https://creativecommons.org/licenses/by/4.0/), which permits unrestricted use, sharing, adaptation, distribution and reproduction in any medium or format, for any purpose, even commercially, as long as you give appropriate credit to the original author(s) and the source, provide a link to the Creative Commons license, and indicate if changes were made.

consideration of diagnostic requirements and potential challenges is crucial. The untapped potential within vision transformer technology hints at further evolution and even greater patient benefit.

Keywords: Artificial intelligence, capsule endoscopy, computer-assisted diagnosis, computer-assisted detection, deep learning, vision transformer, review

INTRODUCTION

Since its inception in 2001, wireless capsule endoscopy (WCE) has revolutionised the investigation and diagnosis of gastrointestinal (GI) diseases[1]. However, the process of reading WCE images, along with interpreting and diagnosing, is highly labour-intensive and error-prone considering that it is reliant on the expertise of the reader and tens of thousands of video frames collected, of which potentially only a few contain the lesion or pathology to be found. Hence, it is understandable that readers, with their limited attention spans and concentration, may miss pathology or over/underdiagnose lesions which are detected[2]. This is why capsule endoscopy offers a "fertile" field for artificial intelligence (AI) algorithms to be implemented, where AI can significantly streamline the reading process. Several commercial AI systems are already available, such as Quick-View and Express-View, which can recognise potential lesions and remove insignificant video frames. By identifying and selecting images with potential pathology for review and removing those with no suspicion of pathology, these programs decrease the total amount of images the reader is required to view, hence reducing overall reading time. This narrative review aimed to assess and synthesise the current evidence on the AI applications in enhancing the capability and efficiency of capsule endoscopy for investigation of the GI tract and propose future directions for this technology.

METHODS

Methodology for this review was formulated prior to its conduct. Ovid Embase, PubMed (incorporating MEDLINE), and Cochrane databases were searched from database inception to 06 July 2023, with a mixture of Medical Subject Headings (MESH) and free text terms including capsule endoscopy keywords such as "Capsul*", "Endoscop*", and "Gastroscop*", AI-related keywords such as "Artificial Intelligence", "AI", "Convolutional Neural Network", "Deep Learning", "Computer-Assisted Diagnosis", "Computer-Assisted Detection", "Transformer", and "Vision Transformer", and common capsule endoscopy findings such as "Ulcer", "Erosion", "Vascular Lesion", "Lesion", "Gastrointestinal Bleed", "Dieulafoy", "Arteriovenous Malformation", "Inflammatory Bowel Disease", "Crohn's Disease", "Ulcerative Colitis", "Coeliac Disease", "Coeliac Sprue", "Gluten-Sensitive Enteropathy", "Neoplasm", "Polyp", "Cancer", "Tumour", and "Bowel Prep".

Study screening was conducted by three reviewers (A.G., J.K., and J.T.), with disagreements resolved through consensus. Selection criteria were based on their relevance to the research topic of AI for capsule endoscopy. Articles were screened for AI applications, ensuring they focused on one of the sub-categories that were planned a priori: "Active GI Bleeding", "Erosion and Ulcers", "Angiodysplasia", "Polyps and Tumours", "Inflammatory Bowel Disease", "Coeliac Disease", "Hookworm", and "Other Applications". Furthermore, they were required to have constructed their own AI tool, including modalities such as support vector machines (SVMs), Multilayer Perceptrons, and convolutional neural networks (CNNs). Furthermore, they were screened for relevance to the field of capsule endoscopy, including domains such as Colon Capsule Endoscopy and Small-Bowel Capsule Endoscopy. Studies were excluded if they were not in English, were conference abstracts, did not report observational data (e.g., review articles), or did not conform to the inclusion criteria listed above.

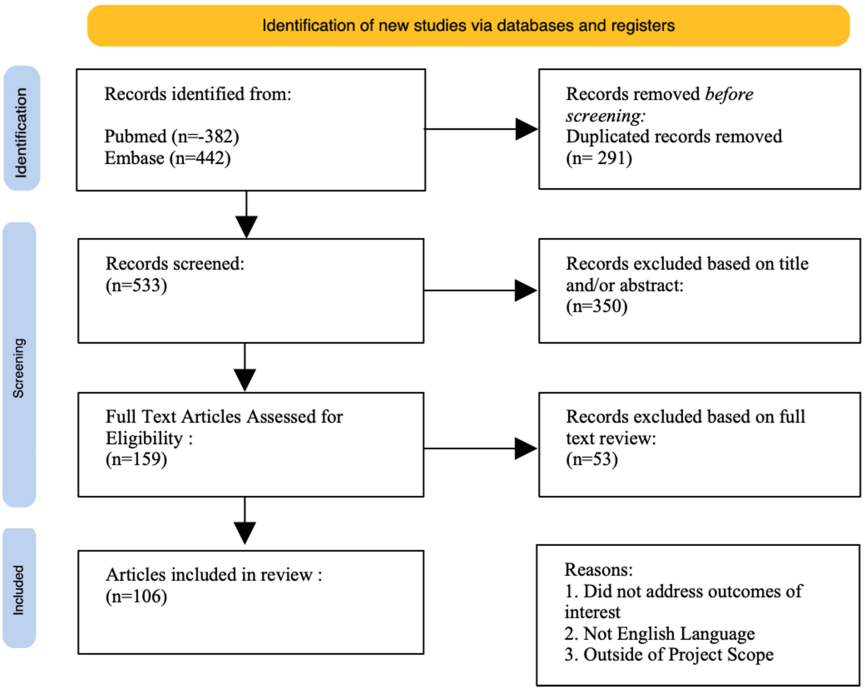

Figure 1. Modified PRISMA flow diagram of search strategy and study selection process.

SEARCH RESULTS

In our search, 824 articles were retrieved, of which 291 duplicates and 31 abstracts were removed. After study screening and full-text review, 106 articles were included for analysis in the present review. Data was synthesised into tabular and narrative formats. For studies with multiple trials, the best result achieved by the models was used.

Additionally, we have designed a modified PRISMA flow-chart [Figure 1].

RESULTS

Active GI bleeding

Automatic haemorrhage detection is one of the largest researched applications of AI for capsule endoscopy. From machine learning models such as the SVM and probabilistic neural network (PNN) methods[3-7], the field has progressed into deep learning models with enhanced efficacy and accuracy. Other models utilising multi-layer perceptrons (MLP)[8] and back-propagation neural networks[4] have also been replaced with deep learning, with this shift appearing to primarily have occurred post-2016. Only four SVM-based models[9-12] were constructed following 2016, compared with eight CNN models[13-20] and two Kernel Neural Networks[21,22]. For example, in 2021, Ghosh *et al.* constructed a CNN-based deep learning framework via the CNN architecture AlexNet, achieving a sensitivity of 97.51% and specificity of 99.88%, significantly enhanced from the sensitivity of approximately 80% previously mentioned by Girithiran *et al.*[3,17]. However, SVM models such as that of Rathnamala *et al.* in 2021 also produced excellent results, with a sensitivity of 99.83% and specificity of 100% reported[12]. More recently, in 2022, Mascarenhas Saraiva *et al.* constructed a CNN detecting blood and haematic residues in the small blood lumen with a sensitivity and specificity of 98.6% and 98.9%, respectively, with an impressive speed of around 184 frames/s[19]. Based on the current literature for gastrointestinal haemorrhage, incorporating AI significantly improves investigative capability. However, further implementation work is necessary to optimise its accuracy [Table 1].

George *et al. Mini-invasive Surg* 2024;8:4 | https://dx.doi.org/10.20517/2574-1225.2023.102

Table 1. Table of AI applications in capsule endoscopy for active GI bleeding

Ref.	Application	Year of publication	Study design	Study location	Aim	Training/Validation dataset	AI type	Results
Giritharan *et al.*[3]	Active GI bleeding	2008	Retrospective	America	Develop a method to re-balance training images	550 bleeding images	SVM	Sensitivity of 80%
Li and Meng[8]	Active GI bleeding	2009	Retrospective	China	Develop new CAD system utilising colour-texture features and neural network classifier	Training: 1,800 bleeding patches and 1,800 normal patches Testing: 1,800 bleeding patches and 1,800 normal patches	MLP	Sensitivity of 92.6%, specificity of 91%
Pan *et al.*[4]	Active GI bleeding	2009	Retrospective	China	Use colour-texture features in RGB and HSI as input in BP neural network	Training: 10,000 pixels Testing: 3,172 bleeding images and 11,458 non-bleeding images	BP neural network	Sensitivity of 93%, specificity of 96%
Pan *et al.*[7]	Active GI bleeding	2011	Retrospective	China	Use colour-texture features in RGB and HSI as input in PNN	Training: 50,000 pairs Testing: 3,172 bleeding images and 11,458 non-bleeding images	PNN	Sensitivity of 93.1%, specificity of 85.8%
Ghosh *et al.*[5]	Active GI bleeding	2014	Retrospective	Bangladesh	Use RGB colour-texture feature in SVM	Training: 50 bleeding images and 200 non-bleeding images Testing: 400 bleeding and 1,600 non-bleeding images	SVM	Sensitivity of 93.00%, specificity of 94.88%
Hassan and Haque[6]	Active GI bleeding	2015	Retrospective	Bangladesh	Utilise characteristic patterns in frequency spectrum of WCE images	Training: 600 bleeding and 600 non-bleeding frames Testing: 860 bleeding and 860 non-bleeding images	SVM	Sensitivity of 99.41%, specificity of 98.95%
Yuan *et al.*[9]	Active GI bleeding	2016	Retrospective	China	Construct two-fold system for detection and localisation of bleeding regions	Testing: 400 bleeding frames and 2,000 normal frames	SVM and KNN	Sensitivity of 92%, specificity of 96.5%
Jia and Meng[13]	Active GI bleeding	2016	Retrospective	China	Develop deep neural network that can automatically and hierarchically learn high-level features	Training: 2,050 bleeding and 6,150 non-bleeding images Testing: 800 bleeding, 1,000 non-bleeding	CNN	Sensitivity of 99.20%*
Jia and Meng[14]	Active GI bleeding	2017	Retrospective	China	Combine handcrafted and CNN features for characterisation	Training: 200 bleeding frames and 800 normal frames Testing: 100 bleeding frames and 400 normal frames	CNN	Sensitivity of 91%
Kundu *et al.*[21]	Active GI bleeding	2018	Retrospective	Bangladesh	Detecting bleeding images based on precise ROI detection in normalised RGB colour plane	Testing: 5 videos, with 100 image frames each	KNN	Sensitivity of 85.7%, specificity of 69.6%
Ghosh *et al.*[10]	Active GI bleeding	2018	Retrospective	Bangladesh/ Canada	Utilising cluster-based statistical feature extraction for global feature vector construction	Testing: 5 WCE videos	SVM	Sensitivity of 96.5%, specificity of 94.6%
Xing *et al.*[22]	Active GI bleeding	2018	Retrospective	China	Using SPCH feature based on the principal colour spectrum to discriminate bleeding frames	Training: 340 bleeding frames and 340 normal ones Testing: 160 bleeding frames and	KNN	Sensitivity of 98.5%, specificity of 99.5%

						160 normal ones		
Pogorelov *et al.*[11]	Active GI bleeding	2019	Retrospective	Malaysia/ Norway	Combining colour features in RGB and texture features for bleeding detection	Training: 300 bleeding frames and 200 non-bleeding Testing: 500 bleeding and 200 non-bleeding frames	SVM	Sensitivity of 97.6%, specificity of 95.9%
Hajabdollahi *et al.*[15]	Active GI bleeding	2019	Retrospective	Iran	Developing a low-complexity CNN method	Training and testing on KID[110]	CNN	Sensitivity of 94.8%, specificity of 99.1%
Kanakatte and Ghose[16]	Active GI bleeding	2021	Prospective	India	Proposing compact U-Net model	Training: 700 bleeding and 700 non-bleeding Testing: 50 capsule endoscopy images	CNN	Sensitivity of 99.57%, specificity of 91%
Rathnamala and Jenicka[12]	Active GI bleeding	2021	Retrospective	India	Utilising gaussian mixture model superpixels for bleeding detection	Training: 686 bleeding and 961 non-bleeding images Testing: 487 bleeding images and 1,160 non-bleeding images	SVM	Sensitivity of 99.83%, specificity of 100%
Ghosh and Chakareski[17]	Active GI bleeding	2021	Retrospective	America	Develop CNN-based framework for bleeding identification	Alex-Net training: 1,410 Alex-Net testing: 940 SegNet training: 201 SegNet testing: 134	CNN	Sensitivity of 97.51%, specificity of 99.88%
Ribeiro *et al.*[18]	Active GI bleeding	2021	Retrospective	Portugal	Automatic detection and differentiation of vascular lesions	Training: 820 images with red spots, 830 images with angiodysplasia/varices, 7,620 images with normal mucosa Testing: 206 images with red spots, 207 images with angiodysplasia/varices, 1,905 images with normal mucosa	CNN	Sensitivity of 91.8%, specificity of 95.9%
Mascarenhas Saraiva *et al.*[19]	Active GI bleeding	2022	Retrospective	Portugal	Create CNN-based system for automatic detection of blood or haematic traces in small bowel lumen	Training: 10,808 images containing blood, 6,868 with normal mucosa or other distinct pathological findings Testing; 2,702 images containing blood, 1,717 with normal mucosa or other distinct pathological findings	CNN	Sensitivity of 98.6%, specificity of 98.9%
Muruganantham and Balakrishnan[20]	Active GI bleeding	2022	Retrospective	India	Construct dual branch CNN model with a novel lesion attention map estimator model	Training and testing conducted on bleeding[111] and Kvasir-Capsule dataset[112] Training: 3,430 images Testing: 1,470 images	CNN	No sensitivity and specificity could be found Accuracy of 94.40% for bleeding detection on bleeding dataset Accuracy of 93.18% for ulcer, 93.89% for bleeding, 97.73% for polyp, 96.67% for normal on Kvasir-Capsule dataset

*An inconsistency was noted in publications from the same group. Jia *et al.*'s 2017 later work referenced the prior 2016 work but reports an inconsistent recall/sensitivity[13,14]. AI: Artificial intelligence; GI: gastrointestinal; SVM: support vector machine; CAD: computer aided design; MLP: multilayer perceptron; RGB: red, green blue; HSI: hue, saturation, intensity; BP: back propagation; PNN: probabilistic neural network; WCE: wireless capsule endoscopy; KNN: K-nearest neighbour; CNN: convolutional neural network; ROI: region of interest; SPCH: superpixel-colour histogram; KID: koulaouzidis-iakovidis database.

Erosion and ulcers

Erosions and ulcers are among the most common findings on WCE. These lesions have reduced visual features compared to visibly haemorrhagic lesions, as seen above, and hence, their characterisation is more difficult. Earlier work, as demonstrated by Charisis *et al.*, utilising Bi-dimensional Ensemble Empirical Mode Decomposition and SVMs to identify ulcers obtained a sensitivity and specificity of around 95%[23]. While other MLP and SVM models were created prior to 2014 with similar accuracies[24-26], the earliest study utilising a deep learning framework for the detection of ulcers and erosions is believed to be the work by Fan *et al.* in 2018, which employed a CNN achieving a sensitivity of 96.80% and 94.79% and specificity of 94.79% and 95.98%, respectively[27]. Since 2018, only two non-deep learning models were retrieved[28,29] in comparison to 14 deep learning models[30-42]. Most recently, in 2023, Nakada *et al.* published their use of the RetinaNet model to diagnose multiple types of lesions including erosions, ulcers, vascular lesions, and tumours[43]. This study obtained a sensitivity of 91.9% and specificity of 93.6% in the detection of erosions and ulcers [Table 2].

Vascular lesions and angiodysplasias

Angiodysplasias, defined as accumulations of dilated, tortuous, and dilated blood vessels in the mucosa and submucosa of the intestinal wall, are common pathologies that can cause small intestinal bleeding. The first record of a software tool for the diagnosis of enteric lesions, including angiodysplasias, was the work by Gan *et al.* in 2008, which used Image Processing Software to obtain a median sensitivity of 74.2%[44]. Only two non-deep learning models were retrieved in the search: a study by Arieira *et al.* on evaluating the accuracy of the TOP 100 feature of Rapid Reader™[45] and a 2019 investigation by Vieira *et al.* on MLP and SVMs which obtained sensitivities above 96%[46]. Since 2019, only deep learning models have been employed in this field[47-53]. In 2018, Leenhardt *et al.* published their CNN model for detecting gastrointestinal angiodysplasias[54]. An exceptional sensitivity of 100% and specificity of 95.8% were obtained. Moreover, they assisted in constructing a French national database (CAD-CAP) to collect and maintain high-quality capsule endoscopy images for the training and validation of AI assistive tools. Recently, in 2023, Chu *et al.* published their CNN constructed on Resnet-50 architecture, which obtained a positive predictive value of 94% and negative predictive value of 98%, in addition to the capability of segmenting and recognising an image in 0.6 s[53] [Table 3].

Polyps and tumours

The significance of detecting polyps and tumours stems from their potential to cause significant morbidity and mortality. A substantial body of research has been devoted to exploring AI-assisted capsule endoscopy for accurate identification and detection of these lesions. Early research in AI-assisted capsule endoscopy for this application includes a study by Li *et al.* in 2011, which utilised colour texture features to differentiate between normal and tumour-containing images with a sensitivity of 92.33% and a specificity of 88.67%[55]. Multiple other machine learning models utilising Binary Classifiers, SVMs, and MLPs have been utilised to varying accuracies and efficacies[56-61]. Deep learning was integrated into the field with the study by Yuan and Meng in 2017[62], where they utilised a stacked sparse autoencoder method to categorise images into polyps, bubbles, turbid images, and clear images with an overall accuracy of 98.00%. Since then, 12 deep learning applications were used for polyp and tumour detection[63-74]. More recently, a study by Lafraxo *et al.* in 2023 proposed an innovative model using CNN (Resnet50), where they achieved an accuracy of 99.16% on the MICCAI 2017 WCE dataset[73]. In 2022, the research conducted by Piccirelli *et al.* investigating the diagnostic accuracy of Express View of IntroMedic achieved a 97% sensitivity and 100% specificity[75]. As AI polyp detection tools are commercially available for colonoscopy, such as FujiFilm's CADeye[76] and EndoBRAIN (Olympus), the imminent release and usage of AI tools for capsule endoscopy is expected with these promising results, which will likely only be further supported by future research such as the planned multi-centre CESCAIL study[77] [Table 4].

Table 2. Table of AI applications in capsule endoscopy for erosions and ulcers

Ref.	Application	Year of publication	Study design	Study location	Aim and goals	Training/Validation dataset	AI type	Results
Li and Meng[24]	Erosions and ulcers	2009	Retrospective	China	Utilising chromaticity moment to discriminate normal regions and abnormal region	Training: 1,350 normal samples and 1,350 abnormal samples Testing: 450 normal samples and 450 abnormal samples	MLP	Bleeding: sensitivity of 87.81%, specificity of 88.62% Ulcer: sensitivity of 84.68%, specificity of 92.97%
Charisis *et al.*[23]	Erosions and ulcers	2010	Retrospective	Greece	Using BEEMD to extract intrinsic mode functions	Dataset: 40 normal and 40 ulcerous images 90% for training, 10% for testing	SVM	Sensitivity of 95%, specificity of 96.5%
Charisis *et al.*[25]	Erosions and ulcers	2012	Retrospective	Greece	Associate colour with structure information in order to discriminate between healthy and ulcerous tissue	87 normal images, 50 "easy ulcer case" images, 37 "hard ulcer case" images 90% was used for training, 10% for testing	MLP and SVM	SVM: sensitivity of 98.9%, specificity of 96.9%, for "easy ulcer"; sensitivity of 95.2%, specificity of 88.9%, for "hard ulcer" MLP: sensitivity of 94.6%, specificity of 98.2%, for "easy ulcer"; sensitivity of 82%, specificity of 95.1%, for "hard ulcer"
Iakovidis and Koulaouzidis[26]	Erosions and ulcers	2014	Retrospective	Greece/ United Kingdom	Derive colour feature-based pattern recognition method	Training: 1,233 images Testing: 137 images	SVM	Sensitivity of 95.4%, specificity of 82.9%
Fan *et al.*[27]	Erosions and ulcers	2018	Retrospective	China	Automatic erosion detection via deep neural network	Ulcer training: 2,000 ulcer images, 2,400 normal images Ulcer testing: 500 ulcer images, 600 normal images Erosion training: 2,720 ulcer images, 3,200 normal images Erosion testing: 690 ulcer images, 800 normal images	CNN	Ulcers: sensitivity of 96.8%, specificity of 94.79% Erosions: sensitivity of 93.67%, specificity of 95.98%
Khan *et al.*[28]	Erosions and ulcers	2019	Retrospective	Pakistan	Utilising DenseNet CNN for stomach abnormality classification	Training: 2,800 ulcers, 2,800 bleeding, and 2,800 healthy regions Testing: 1,200 ulcers, 1,200 bleeding, and 1,200 healthy regions	MLP	Sensitivity of 99.40%, specificity of 99.20%
Wang *et al.*[30]	Erosions and ulcers	2019	Retrospective	China	Use deep convolutional neural networks to provide classification confidence score and bounding box marking area of suspected lesion	Training: 15,781 ulcer frames and 17,138 normal frames Testing: 4,917 ulcer frames and 5,007 normal frames	CNN	Sensitivity of 89.71%, specificity of 90.48%
Aoki *et al.*[31]	Erosions and ulcers	2019	Retrospective	Japan	Develop CNN system based on a single shot multibox detector	Training: 5,360 ulcer and erosion images Testing: 440 ulcer and erosion images, 10,000 normal images	CNN	Sensitivity of 88.2%, specificity of 90.9%
Ding *et al.*[32]	Erosions and ulcers	2019	Retrospective	China	Characterise SB-CE images as multiple lesion types	Training: 158,235 images from 1,970 patients Testing: 113, 268, 334 images from	CNN	Sensitivity of 99.90%, specificity of 100%

						5,000 patients		
Majid *et al.*[33]	Erosions and ulcers	2020	Retrospective	Pakistan	Using multi-type features extraction, fusion, and features selection to detect ulcer, polyp, esophagitis, and bleeding	Training: 6,922 images of bleeding, oesophagitis, polyp, and ulcerative colitis Testing: 2,967 images of bleeding, oesophagitis, polyp, and ulcerative colitis	CNN	Sensitivity of 96.5%
Kundu *et al.*[29]	Erosions and ulcers	2020	Retrospective	Bangladesh	Employing LDA for ROI separation	Training: 65 bleeding, 31 ulcers, and 30 tumour images Testing: 15 continuous video clips	SVM	Sensitivity of 85.96%, specificity of 92.24%
Otani *et al.*[34]	Erosions and ulcers	2020	Retrospective	Japan	Multiple lesion detection using RetinaNet	Database of 398 images of erosions and ulcers, 538 images of angiodysplasias, 4,590 images of tumours, and 34,437 normal images for training and testing	Deep neural network	No sensitivity and specificity reported
Xia *et al.*[35]	Erosions and ulcers	2021	Retrospective	China	Novel CNN and RCNN system to detect 7 types of lesions in MCE imaging	Training: 822,590 images Testing: 201,365 images	CNN, RCNN	Sensitivity of 96.2%, specificity of 76.2%
Afonso *et al.*[36]	Erosions and ulcers	2021	Retrospective	Portugal	Identify but also differentiate ulcers and erosions based on haemorrhagic potential	Training: 18,976 images Testing: 4,744 images	CNN	Sensitivity of 86.6%, specificity of 95.9%
Mascarenhas Saraiva *et al.*[37]	Erosions and ulcers	2021	Retrospective	Portugal	Identify various lesions on CE images and differentiate using Saurin's classification	Training: 42,844 images Testing: 10,711 images	CNN	Sensitivity of 88%, specificity of 99%
Afonso *et al.*[38]	Erosions and ulcers	2022	Retrospective	Portugal	Identify but also differentiate ulcers and erosions based on haemorrhagic potential	Training: 4,904 images Testing: 379 normal images, 266 erosion, 286 P1 Ulcer images, 295 P2 Ulcer images	CNN	Sensitivity of 90.8%, specificity of 97.1%
Mascarenhas *et al.*[39]	Erosions and ulcers	2022	Retrospective	Portugal	Develop CNN-based method to detect and distinguish colonic mucosal lesions and luminal blood in CCE imaging	Training: 7,204 images Testing: 1,801	CNN	Sensitivity of 96.3%, specificity of 98.2%
Xiao *et al.*[40]	Erosions and ulcers	2022	Retrospective sensitivity of 96.9% and a specificity of 99.9% specific	China	Classify capsule gastroscope images into normal, chronic erosive gastritis, and gastric ulcer categories	Training: 228 images Testing: 912 images	CNN	No sensitivity and specificity, accuracy of 94.81%
Ribeiro *et al.*[41]	Erosions and ulcers	2022	Retrospective	Portugal	Accurately detect ulcers and erosions in CCE images	Training: 26,869 images Testing: 3,375 normal images, 357 images with ulcers or colonic erosions	CNN	Sensitivity of 96.9%, specificity of 99.9%
Nakada *et al.*[43]	Erosions and ulcers	2023	Retrospective	Japan	Utilise RetinaNet to diagnose erosions and ulcers, vascular lesions, and tumours in WCE imaging	Training: 6,476 erosion and ulcer images, 1,916 angiodysplasias images, 7,127 tumour images, 14,014,149 normal images Testing: images from 217 patients	Deep neural network	Erosions and ulcers: sensitivity of 91.9%, specificity of 93.6% Vascular lesions: sensitivity of 87.8%, specificity of 96.9% Tumours: sensitivity of 87.6%, specificity of 93.7%
Raut *et al.*[42]	Erosions and	2023	Retrospective	India	Use various feature extraction	Training and testing on KID dataset[110]	Deep	Sensitivity of 97.23%,

ulcers	methods in the classification of WCE images as inflammatory, polypoid and ulcer	neural network	specificity of 52.00%

AI: Artificial intelligence; MLP: multilayer perceptron; BEEMD: bidimensional ensemble empirical mode decomposition; SVM: support vector machine; CNN: convolutional neural network; SBCE: small bowel capsule endoscopy; LDA: linear discriminant analysis; ROI: region of interest; RCNN: region-based convolutional neural network; MCE: magnetically controlled capsule endoscopy; CCE: colon capsule endoscopy; WCE: wireless capsule endoscopy; KID: koulaouzidis-iakovidis database.

Inflammatory bowel disease

Potential AI tools to improve the detection and assessment of ulcers and mucosal inflammation caused by Crohn's disease have been researched for over a decade. In 2012, Kumar *et al.* published their work using a cascade for classifying CD lesions and quantitatively assessing their severity[78]. The severity assessment given (normal, mild, and severe) by the model was shown to correlate well with those manually assigned by experts. While multiple machine learning models have achieved reasonable sensitivities and specificities in this field[79-81], since 2018, deep learning systems have predominated research[81-92]. In 2022, Ferreira *et al.* developed a CNN using a total of 8,085 images to detect ulcers and erosions in images from the PillCam™ Crohn's Capsule, with an overall sensitivity of 90% and specificity of 96%[89]. Higuchi *et al.* published their work using CNN-based models to automatically classify ulcerative colitis lesion severity based on the Mayo Endoscopic Subscore, achieving an accuracy of 98.3%[90]. While reasonable results have been achieved, ulcers and erosions typically have fewer colour features compared to active bleeding lesions, making their detection and classification generally more difficult [Table 5].

Coeliac disease

Currently, there is a comparatively smaller body of research on AI detection and analysis of capsule endoscopy video for coeliac disease. Given the recency of the field, all retrieved articles utilised deep learning in their systems[93-96]. In 2017, Zhou *et al.* developed a deep learning method using the GoogLeNet model[93]. Impressively, a 100% sensitivity and specificity were found on testing, although only a small number of video clips were used for the study. More recently, in 2021, Li *et al.* employed principal component analysis (PCA) for feature extraction, including the novel strip PCA (SPCA) method[95]. Using a small database of 460 images, their process was found to have an average accuracy of 93.9% on testing. The small number of studies performed has resulted in a paucity of evidence on the utility of AI tools for this condition [Table 6].

Hookworm detection

Among the various pathological conditions that AI diagnostic techniques can identify, research into detecting parasitic infestations such as Hookworms has very little published data available. In 2016, Wu *et al.* proposed a new method that includes a multi-scale dual matched filter to locate the tubular structure of hookworms and a piecewise parallel region detection method to identify regions potentially containing hookworm bodies on WCE imaging[97]. Testing on a large dataset of 440,000 WCE images demonstrated accuracy, sensitivity, and specificity rates of around 78%. In 2018, He *et al.* furthered this work by integrating two CNN systems to model the visual appearances and tubular patterns of hookworms concurrently[98]. Testing and validating showcased an impressive accuracy of 88.5%. More recently, in 2021, Gan *et al.* utilised a deep CNN trained using 11,236 capsule endoscopy images of hookworms[99]. The trained CNN system took 403 s to evaluate 10,529 test images, with sensitivity, specificity, and accuracy of 92.2%, 91.1%, and 91.2%, respectively [Table 7].

George *et al. Mini-invasive Surg* 2024;8:4 | https://dx.doi.org/10.20517/2574-1225.2023.102

Table 3. Table of AI applications in capsule endoscopy for vascular lesions and angiodysplasias

Ref.	Application	Year of publication	Study design	Study location	Aim and goals	Training/Validation dataset	AI type	Results
Gan *et al.*[44]	Vascular lesions and angiodysplasias	2008	Retrospective	China	Develop computer-aided screening and diagnosis for enteric lesions in CE	Dataset of 236 patients with lesion, and 86 without lesion for training and validation	IPS	Median sensitivity of 74.2%
Leenhardt *et al.*[54]	Vascular lesions and angiodysplasias	2018	Retrospective	France	Utilise CNN for detection of AGD in SB-CE images	Training: 300 normal frames, 300 AGD frames Testing: 300 normal frames, 300 AGD frames	CNN	Sensitivity of 100%, specificity of 96%
Arieira *et al.*[45]	Vascular lesions and angiodysplasias	2019	Retrospective	Portugal	Evaluate accuracy and efficacy of "TOP 100" feature	Testing: 97 patients	TOP 100	No sensitivity or specificity. Accuracy of 83.5% for P2 lesions, 95.5% for AGD, 56.7% for ulcers, 100% for active bleeding sites
Vieira *et al.*[46]	Vascular lesions and angiodysplasias	2019	Retrospective	Portugal	Automatic detection of AGD in WCE videos	Dataset: 27 images from KID database[110], additional 248 AGD images, 550 normal images	MLP and SVM	MLP: sensitivity of 96.60%, specificity of 94.08% SVM: sensitivity of 96.58%, specificity of 92.24%
Vezakis *et al.*[47]	Vascular lesions and angiodysplasias	2019	Retrospective	Greece	Combining of low-level image analysis, feature detection, and machine learning for AGD detection in WCE images	Training: 350 normal images, 196 bubble images, 75 blood vessel images, 104 AGD images Testing: 3 full-length WCE	CNN	Sensitivity of 92.7%, specificity of 99.5%
Leenhardt *et al.*[48]	Vascular lesions and angiodysplasias	2019	Retrospective	France	Develop CNN methodology to detect GIA in SB-CE	Training: 300 normal frames, 300 GIA frames GIA Testing: 300 normal frames, 300 GIA frames	CNN	Sensitivity of 100%, specificity of 96%
Tsuboi *et al.*[49]	Vascular lesions and angiodysplasias	2020	Retrospective	Japan	Development of CNN system based on SSMB for small bowel AGD detection	Training: 2,237 angiodysplasia images Testing: 488 AGD images, 10,000 normal images	CNN	Sensitivity of 98.8%, specificity of 98.4%
Aoki *et al.*[50]	Vascular lesions and angiodysplasias	2021	Retrospective	Japan	Construct CNN based system for various abnormality detection	Training: 44,684 images of abnormalities and 21,344 normal images Testing: 379 full small-bowel CE videos	CNN	No sensitivity or specificity reported. Accuracy of 100% for mucosal breaks, 97% for AGD, 99% for protruding lesions, and 100% for blood content
Hwang *et al.*[51]	Vascular lesions and angiodysplasias	2021	Retrospective	Korea	Develop CNN algorithm for categorisation of SBCE videos into haemorrhagic lesions and ulcerative lesions	Training: 11,776 haemorrhagic lesions, 18,448 ulcerative lesions, 30,224 normal images Testing: 5,760 images	CNN	Sensitivity of 97.61%, specificity of 96.04%
Hosoe *et al.*[52]	Vascular lesions and angiodysplasias	2022	Retrospective	Japan	Detect common findings on SBCE images using CNN framework with aim to reduce false-	Training: 33 SBCE cases Testing: 35 SBCE cases	CNN	Sensitivity of 93.4%, specificity of 97.8%

					positive rate			
Chu *et al.*[53]	Vascular lesions and angiodysplasias	2023	Retrospective	China	Utilise CNN segmentation method for AGD detection	Training: 178 cases Testing: 200 cases	CNN	No sensitivity or specificity given. Pixel accuracy of 99%

AI: Artificial intelligence; CE: capsule endoscopy; IPS: image-processed software; CNN: convolutional neural network; AGD: angiodysplasias; SBCE: small bowel capsule endoscopy; WCE: wireless capsule endoscopy; KID: koulaouzidis-iakovidis database; MLP: multilayer perceptron; SVM: support vector machine; GIA: gastrointestinal angiodysplasia; SSMB: single shot multibox detector.

Other applications of AI in capsule endoscopy.

Automated calculation of bowel preparation quality

Effective and thorough bowel cleansing is essential for high quality images of the GI tract through capsule endoscopy. The diagnostic potential is reduced when bowel preparation is inadequately performed. Nam *et al.* created an automated calculation software for small bowel cleansing scores using deep learning algorithms. A five-step scoring system was developed based on mucosal visibility, which was then used to train the deep learning algorithm. The system assigned an average cleansing score (ranging from 1 to 5), which was compared with gradings (A to C) assessed by clinicians. The software was able to provide objective, automated cleansing scores for small bowel preparation, thus potentially allowing its use in the assessment of whether or not appropriate bowel preparation has been achieved for small bowel pathology detection[100] [Table 8].

Multiple lesion characterisation

A functioning, highly accurate method to detect and characterise a wide range of lesions through the same tool in real time would be the ultimate goal in the foreseeable future for AI research. Various models have so far attempted to achieve this goal[101-107]. Recently, in 2023, Yokote *et al.* constructed an object detection AI model from a dataset of 18,481 images to detect and characterise into the categories of Angiodysplasia, Erosion, Stenosis, Lymphangiectasis, Lymph follicle, Submucosal tumour, Polyp-like, Bleeding, Diverticula, Redness, Foreign body, and Venous. The overall sensitivity was 91%[106].

Also, in 2023, Ding *et al.* developed an AI model to detect various abnormalities on capsule endoscopy imaging, trained on 280,426 images. The AI model showed high sensitivity in detecting various abnormalities: red spots (97.8%), inflammation (96.1%), blood content (96.1%), vascular lesions (94.7%), protruding lesions (95.6%), parasites (100%), diverticulum (100%), and normal variants (96.4%). Furthermore, when junior doctors used the AI model, their overall accuracy increased from 85.5% to 97.9% and became comparable to that of experts who had an accuracy rate of 96.6%[107]. AI tools, which are multi-faceted and have the ability to detect and characterise a variety of common findings, will no doubt revolutionise capsule endoscopy diagnosis [Table 9].

DISCUSSION

The shifting of utilised AI types over time from traditional machine learning features such as SVMs to deep learning, including CNNs, is associated with an increase in accuracy, sensitivity and specificity of diagnostic results.

George *et al. Mini-invasive Surg* 2024;8:4 | https://dx.doi.org/10.20517/2574-1225.2023.102

Table 4. Table of AI applications in capsule endoscopy for polyps and tumours

Ref.	Application	Year of publication	Study design	Study location	Aim and goals	Training/Validation dataset	AI type	Results
Li *et al.*[55]	Polyps and tumours	2011	Retrospective	China	Utilise textural feature based on multi-scale local binary pattern for tumour detection	Training: 450 normal samples, 450 tumour samples Testing: 150 normal samples, 150 tumour samples	KNN MLP SVM	Best Results: sensitivity of 92.33%, specificity of 88.67%
Karargyris and Bourbakis[56]	Polyps and tumours	2011	Retrospective	America	Utilising log Gabor filters for feature extraction to detect polyps and ulcers	Polyps testing: 10 frames with polyps, 40 normal frames Ulcer testing: 20 ulcer frames, 30 non-ulcer frames	SVM	Ulcer detection: sensitivity of 75.0%, specificity of 73.3% Polyp detection: sensitivity of 100%, specificity of 67.5%
Barbosa *et al.*[57]	Polyps and tumours	2012	Retrospective	Portugal	Extracting textural features to detect polyps and tumours	Dataset for training and testing: 700 tumour images, 2,300 normal images	MLP	Sensitivity of 93.9%, specificity of 93.1%
Mamonov *et al.*[58]	Polyps and tumours	2014	Retrospective	USA/Portugal	Development of binary classifier for tumour detection geometrical analysis and texture content	Dataset for training and testing: 230 tumour images, 18,738 normal images	BC	Per frame: sensitivity of 47.4%, specificity of 90.2% Per polyp: sensitivity of 81.25%, specificity of 93.47%
Liu *et al.*[59]	Polyps and tumours	2016	Retrospective	China	Integrating multi-scale curvelet and fractal technology into textural features for polyp detection	Training: WCE videos of 15 patients Testing: 900 normal frames, 900 tumour frames	SVM	Sensitivity of 97.8%, specificity of 96.7%
Yuan and Meng[62]	Polyps and tumours	2017	Retrospective	China	Construction of SSAEIM for polyp detection	Testing: 1,000 bubble images, 1,000 TIs, 1,000 CIs, 1,000 polyp images	SSAEIM	Polyps: sensitivity of 98%, specificity of 99% Bubbles: sensitivity of 99.5%, specificity of 99.17% TIs: sensitivity of 99%, specificity of 100% CIs: sensitivity of 95.5%, specificity of 99.17%
Blanes-Vidal *et al.*[74]	Polyps and tumours	2019	Retrospective	Denmark	Developed algorithm to match CCE and colonoscopy polyps and construct CNN for polyp detection	Training: 39,550 images Testing: 8,476 images	CNN	Sensitivity of 97.1%, specificity of 93.3%
Saito *et al.*[63]	Polyps and tumours	2020	Retrospective	Japan	Constructing CNN model for protruding lesion detection	Training: 30,584 protruding lesion images Testing: 7,507 protruding lesion images, 10,000 normal images	CNN	Sensitivity of 90.7%, specificity of 79.8%
Yang *et al.*[60]	Polyps and	2020	Retrospective	China	Development of algorithm	Testing: 500 normal, 500 polyp images	SVM	Sensitivity of 95.80%,

	tumours				based on LCDH for polyp detection			specificity of 96.20%
Vieira *et al.*[61]	Polyps and tumours	2020	Retrospective	Portugal	Construction of GMM and ensemble system for tumour detection	Database of 936 tumour images, 3,000 normal images for training and testing	SVM MLP	Best result: sensitivity of 96.1%, specificity of 98.3%
Yamada *et al.*[64]	Polyps and tumours	2021	Retrospective	Japan	Construction of CNN based on SSMD for colorectal neoplasm detection	Training: 15,933 colorectal neoplasm images Testing: 1,850 colorectal neoplasm images, 2,934 normal colon images	CNN	Sensitivity of 79.0%, specificity of 87%
Saraiva *et al.*[65]	Polyps and tumours	2021	Retrospective	Portugal	Development of CNN for protruding lesion detection on CCE imaging	Database: 860 protruding lesions images, 2,780 normal mucosa images Training: 2,912 images of database Testing: 728 images of database	CNN	Sensitivity of 90.7%, specificity of 92.6%
Jain *et al.*[66]	Polyps and tumours	2021	Retrospective	India	Creation of deep CNN based WCENet model for anomaly detection in WCE images	Training and testing on KID database[110] and CVC-clinic database[113]	CNN	Sensitivity of 98%
Zhou *et al.*[67]	Polyps and tumours	2022	Retrospective	China	Utilising neural network ensembles to improve polyp segmentation	Training: 195 images Testing: 41 images	CNN	No sensitivity and specificity reported
Mascarenhas *et al.*[68]	Polyps and tumours	2022	Retrospective	Portugal	Construction of CNN for protruding lesion detection on CCE	Training: 1,928 protruding lesion images, 2,644 normal/other finding imagesTesting: 482 protruding lesion images, 661 normal/other finding images	CNN	Sensitivity of 90.0%, specificity of 99.1%
Gilabert *et al.*[69]	Polyps and tumours	2022	Retrospective	Spain	Comparing AI tool to RAPID Reader Software v9.0 (Medtronic)	Testing: 18 videos	CNN	Sensitivity of 87.8%
Piccirelli *et al.*[75]	Polyps and tumours	2022	Retrospective	Italy	Testing the diagnostic accuracy of Express View (IntroMedic)	Testing: 126 patients	Express view	Sensitivity of 97%, specificity of 100%
Liu *et al.*[70]	Polyps and tumours	2022	Retrospective	China	Constructing DBMF fusion network with CNN and transformer for polyp segmentation	Training: 1,450 images Testing: 636 images	DBMF	No sensitivity and specificity given
Souaidi *et al.*[71]	Polyps and tumours	2023	Retrospective	Morocco	Modifying existing SSMD models for polyp detection	Training: 2,745 images Testing: 784 images	SSMD	No sensitivity and specificity given
Mascarenhas Saraiva *et al.*[72]	Polyps and tumours	2023	Retrospective	Portugal	Developing CNN for automatic detection of small bowel protruding lesions	Training: 14,900 images Testing: 3,725 images	CNN	Sensitivity of 96.8%, specificity of 96.5%
Lafraxo *et al.*[73]	Polyps and tumours	2023	Retrospective	Morocco	Proposing novel CNN-based architecture for GI image segmentation	MICCAI2017[114]: training: 2,796 images Testing: 652 images Kvasir-SEG dataset [115]: Training: 800 images Testing: 200 images CVC-ClinicDB dataset[116]: Training: 490 images	CNN	No sensitivity or specificity given. Accuracy of 99.16% on MICCAI2017 reported, 97.55% on Kvasir-SEG,

						Testing: 122 images		and 97.58% on CVC-ClinicDB databases respectively
Lei *et al.*[77]	Polyps and tumours	2023	Combined prospective/retrospective	United Kingdom	Study is proposed to determine efficacy of AI tools for polyp detection in capsule endoscopy	Study is incomplete	CNN	Study is incomplete

AI: Artificial intelligence; KNN: K nearest neighbour; MLP: multilayer perceptron; SVM: support vector machine; BC: binary classifier; WCE: wireless capsule endoscopy; SSAEIM: stacked sparse autoencoder with image manifold constraint; TI: turbid image; CI: clear image; CCE: colon capsule endoscopy; CNN: convolutional neural network; LCDH: local colour difference; GMM: gaussian mixture model; SSMD: single shot multibox detector; KID: koulaouzidis-iakovidis database; DBMF: dual branch multiscale feature fusion network; GI: gastrointestinal.

Current commercial endoscopes have some algorithm built to assist with interpretation. However, the training of such algorithms are based on traditional supervised learning methods. Given the rise in higher resolution and increase the amount of training images and videos, unsupervised methods will be more efficient and accurate.

Deep learning has shown significant promise in the field of diagnostic capsule endoscopy due to its ability to learn from large volumes of data and make accurate predictions. Current commercial capsule endoscopes have algorithms available to assist with interpretation such as the TOP 100 feature of Rapid Reader[45]. However, the training of these algorithms is based on traditional supervised learning methods. Unlike traditional machine learning algorithms, which require manual feature extraction and selection, deep learning ones can automatically learn and extract features from raw data[108]. CNNs, in particular, are designed to automatically and adaptively learn spatial hierarchies of features from raw data, which makes them well-suited for image classification tasks in capsule endoscopy, as evidenced in the studies above. Given the rise in image resolution and amount of training images and video, unsupervised methods capitalising on these AI systems will become even more efficient and accurate in future.

Despite the advantages of deep learning, it is not without its pitfalls. One of its main criticisms is the "black box" problem. Due to the complexity and depth of these models, it can be challenging to understand and interpret how they make their predictions. This lack of transparency and interpretability can be problematic in medical applications, where understanding the reasoning behind a diagnosis is crucial for patient care and trust[109]. The "black box" problem also raises concerns about the reliability and fairness of deep learning models. If the reasoning behind a model's prediction is not clear, determining whether the model is making decisions based on relevant features or whether it is being influenced by irrelevant or biased data can be difficult[109]. This is an intrinsic issue with deep learning, and hence, images must be validated prospectively prior to usage in clinical settings. Currently, AI researchers are exploring a concept known as Explainable AI to help understand the logic and decision-making process within a black box.

When training WCE with AI, "images" obtained may not be histologically verified due to an inability to obtain biopsies without invasive enteroscopy. This issue undoubtedly has implications for the reliability of the AI algorithms due to the potential inaccuracy of the training dataset used. This may adversely affect the diagnostic accuracy, causing either false-positive or false-negative results, both of which have significant clinical implications. The issue of data quality can

Table 5. Table of AI applications in capsule endoscopy for inflammatory bowel disease

Ref.	Application	Year of publication	Study design	Study location	Aim and goals	Training/Validation dataset	AI type	Results
Haji-Maghsoudi *et al.*[79]	Inflammatory bowel disease	2012	Retrospective	Iran	Develop method for the detection of lymphangiodysplasia, xanthoma, CD, and stenosis in WCE image	Stenosis: 45 images CD: 74 images Lymphangiectasia: 32 images Lymphoid hyperplasia: 27 images Xanthoma: 28 images	CED	Crohn's: sensitivity of 89.32%, specificity of 65.37% Stenosis: sensitivity of 91.27%, specificity of 87.27% Lymphangiectasia: sensitivity of 95.45%, specificity of 94.1% Lymphoid: sensitivity of 87.01%, specificity of 79.71% Xanthoma: sensitivity of 97%, specificity of 97.13%
Kumar *et al.*[78]	Inflammatory bowel disease	2012	Retrospective	United States of America	Constructing classifier cascade for classifying CD lesions into normal, mild, and severe	Training: 355 images Testing: 212 normal images, 213 mild, 108 severe images	SVM	Sensitivity over 90% was found
Charisis and Hadjileontiadis[80]	Inflammatory bowel disease	2016	Retrospective	Greece	Utilise novel feature extraction method for detecting CD lesions	Database of 466 normal images and 436 CD images	SVM	Sensitivity of 95.2%, specificity of 92.4%
de Maissin *et al.*[82]	Inflammatory bowel disease	2018	Retrospective	France	Develop CNN for automatic detection of SB CD lesions	Training: 589 images Testing: 73 images	CNN	Sensitivity of 62.18%, specificity of 66.81%
Klang *et al.*[83]	Inflammatory bowel disease	2019	Retrospective	Israel	Utilise CNN for CD monitoring and diagnosis by SB ulcer detection	Training: 1,090 images Testing: 273 images	CNN	Sensitivity of 96.9%, specificity of 96.6%
Barash *et al.*[81]	Inflammatory bowel disease	2020	Retrospective	Israel	Automatic severity grading of CD ulcers into grades 1 to 3	Training: 1,242 images Testing: 248 images	CNN	Sensitivity of 71%, specificity of 34%
Klang *et al.*[84]	Inflammatory bowel disease	2020	Retrospective	Israel	Construction of CNN to differentiate normal and ulcerated mucosa	Training: 14,112 images Testing: 3,528 images	CNN	Sensitivity of 97.1%, specificity of 96%
de Maissin *et al.*[85]	Inflammatory bowel disease	2021	Retrospective	France	Assessing importance of annotation quality on CNN	Database of 3,498 images was annotated by different readers for different trials	RANN	Sensitivity of 93%, specificity of 95%
Klang *et al.*[86]	Inflammatory bowel disease	2021	Retrospective	Israel	Identify intestinal strictures on CE images from CD patients	Database of 1,942 stricture images, 14,266 normal mucosa images, 7,075 mild ulcer images, 2,386 moderate ulcer images, 2,223 severe ulcer images used for training and testing	CNN	Sensitivity of 92%, specificity of 89%
Klang *et al.*[87]	Inflammatory bowel disease	2021	Retrospective	Israel	Identify NSAID ulcers, which are common differentials for CD ulcers on CE images	Training: 7,391 CD mucosal ulcer images, 10,249 normal mucosa Testing: 980 NSAIDs ulcer images,	CNN	Sensitivity of 92%, specificity of 95%

						625 normal mucosa images		
Majtner *et al.*[88]	Inflammatory bowel disease	2021	Retrospective	Denmark	Detection and classifying CD lesions based on severity	Training: 5,419 images Testing: 1,558 images	CNN	Sensitivity of 96.2%, specificity of 100%
Ferreira *et al.*[89]	Inflammatory bowel disease	2022	Retrospective	Portugal	Automatically detecting ulcers and erosions in the small intestine and colon	Training: 19,740 images Testing: 4,935 images	CNN	Sensitivity of 90%, specificity of 96%
Higuchi *et al.*[90]	Inflammatory bowel disease	2022	Retrospective	Japan	Classifying ulcerative colitis lesions using MES criteria	Training: 483,644 images Testing: 255,377 images	CNN	No Sensitivity or specificity given. Accuracy of 98.3% on validation
Kratter *et al.*[91]	Inflammatory bowel disease	2022	Retrospective	Israel	Accurately identify ulcers on capsule endoscopy by combining algorithm viable for two models of capsule endoscope	Database of 15,684 normal mucosa images, 17,416 ulcerated mucosa images used for training and validation	CNN	No Sensitivity or specificity given. Accuracy of 97.4% on validation
Mascerenhas *et al.*[92]	Inflammatory bowel disease	2023	Retrospective	Portugal	Construct CNN for automatic classification of various types of pleomorphic gastric lesions	Database of 6,844 normal mucosa images, 1,407 protruding lesion images, 994 ulcer and erosion images, 822 vascular lesion images, 2,851 haematic residue images used for training and validation	CNN	Sensitivity of 97.4%, specificity of 95.9%

AI: Artificial intelligence; WCE: wireless capsule endoscopy; CED: canny edge detector; SVM: support vector machine; SB: small bowel; CNN: convolutional neural network; RANN: recurrent attention neural network; CE: capsule endoscopy; NSAID: non-steroidal anti-inflammatory drugs; MES: mayo endoscopic subscore.

be mitigated by ensuring that the AI models are trained on high-quality, histologically proven images, such as the French-created CAD-CAP. This could involve collaborations with medical institutions and experts to curate and verify the training datasets.

The current AI models used in capsule endoscopy also do not appear to harness the potential of vision transformers (ViTs), a state-of-the-art AI model adapted from natural language processing, which utilises self-attention methods for training. ViTs offer a far superior capacity for data handling compared to other deep learning models, with approximately four times as much capacity as that of traditional CNNs. Moreover, their ability to combine spatial analysis with temporal analysis allows them to demonstrate a much superior performance in image-based tasks. Their employment in capsule endoscopy could open the door to more precise lesion characterisation, thereby enhancing the diagnostic potential of this technology. The lack of current models using ViTs presents a notable gap in the field. However, this is primarily due to the recency of the technology in the medical imaging world. The use of ViT in endoscopy has only been explored very recently in research settings, and more applications are expected in the near future.

However, the potential of AI-assisted capsule endoscopy, particularly for colonoscopy for polyp detection and characterisation, is notable. While capsule endoscopy is quite costly compared to the Faecal Occult Blood Test (FOBT), it could serve as an alternative for patients where FOBT may yield high false

Table 6. Table of AI applications in capsule endoscopy for coeliac disease

Ref.	Application	Year of publication	Study design	Study location	Aim and goals	Training/Validation dataset	AI type	Results
Zhou *et al.*[93]	Coeliac disease	2017	Retrospective	China	Develop CNN-based methodology for coeliac disease identification	Training: 6 coeliac disease patient CE videos, 5 control patient CE videos Testing: 5 coeliac disease patient CE videos, 5 control patient CE videos	CNN	Sensitivity of 100%, specificity of 100%
Wang *et al.*[94]	Coeliac disease	2020	Retrospective	China	Construct novel deep learning recalibration module for the diagnosis of coeliac disease on VCE images	Database of 1,100 normal mucosa images, 1,040 CD mucosa images used for training and testing	CNN SVM KNN LDA	Sensitivity of 97.20%, specificity of 95.63%
Li *et al.*[95]	Coeliac disease	2021	Retrospective	China	Utilise novel SPCA method for image processing to detect coeliac disease	Training: 184 images Testing: 276 images	KNN SVMCNN	No Sensitivity or specificity given, accuracy of 93.9%
Chetcuti Zammit *et al.*[96]	Coeliac disease	2023	Retrospective	United Kingdom/ United States of America	Evaluate and compare coeliac disease severity assessment of AI tool and human readers	Training: 444,659 images Testing: 63 VCE videos	MLA	No Sensitivity or specificity given

AI: Artificial intelligence; CNN: convolutional neural network; CE: capsule endoscopy; VCE: video capsule endoscopy; SVM: support vector machine; KNN: K nearest neighbour; LDA: linear discriminant analysis; SPCA: strip principal component analysis; MLA: machine learning algorithm.

Table 7. Table of AI applications in capsule endoscopy for hookworm detection

Ref.	Application	Year of publication	Study design	Study location	Aim and goals	Training/Validation dataset	AI type	Results
Wu *et al.*[97]	Hookworm detection	2016	Retrospective	China	Automatically detect hookworm on WCE images	440,000 images from 11 patients used for training and testing	MLA	Sensitivity of 77.3%, specificity of 77.9%
He *et al.*[98]	Hookworm detection	2018	Retrospective	China	Utilise deep learning for automatic hookworm detection	440,000 images from 11 patients used for training and testing	CNN	Sensitivity of 84.6%, specificity of 88.6%
Gan *et al.*[99]	Hookworm detection	2021	Retrospective	China	Construct CNN for the automatic detection of hookworm on CE images	Training: 11,236 images of hookworm Testing: 531 hookworm images, 9,998 normal images	CNN	Sensitivity of 92.2%, specificity of 91.1%

AI: Artificial intelligence; WCE: wireless capsule endoscopy; MLA: machine learning algorithm; CNN: convolutional neural network; CE: capsule endoscopy.

positives such as in those with haemorrhoids or who do not wish to partake in FOBT-based screening programs. Furthermore, the non-invasiveness and cost-effectiveness of AI Capsule colonoscopy offer advantages over traditional procedures, making it a promising option for mass screening in the near future. It is expected that AI tools will replace parts of the endoscopy procedure after undergoing further clinical evaluation, especially with examples such as AnX Robotica's ProScan receiving FDA approval in 2024.

Table 8. Table of AI application in capsule endoscopy for bowel prep scoring

Ref.	Application	Year of publication	Study design	Study location	Aim and goals	Training/Validation dataset	AI type	Results
Nam *et al.*[100]	Bowel prep scoring	2021	Retrospective	Korea	Automatically detect and score bowel prep quality on CE images	Training: 500 images for each score (1-5), totalling 2,500 Testing: 96 CE cases	CNN	Sensitivity of 93%, specificity of 100% At cleansing cut-off value of 3.25

AI: Artificial intelligence; CE: capsule endoscopy; CNN: convolutional neural network.

Table 9. Table of AI applications in capsule endoscopy for multiple lesion detection

Ref.	Application	Year of publication	Study design	Study location	Aim and goals	Training/Validation dataset	AI type	Results
Park *et al.*[101]	Multiple lesion detection	2020	Retrospective	Korea	Develop CNN model to identify multiple lesions on CE and classify images based on significance	Training: 60,000 significant, 60,000 insignificant Testing: 20 CE videos	CNN	No sensitivity or specificity given; overall detection rate of 81.6%
Xing *et al.*[102]	Multiple lesion detection	2020	Retrospective	China	Develop AGDN model for WCE image classification	CAD-CAP[54] and KID[110] databases used for training and testing	CNN	Sensitivity of 95.72% for normal, 90.7% for vascular images, 87.44% for inflammatory images
Zhu *et al.*[103]	Multiple lesion detection	2021	Retrospective	China	Construct new deep learning model for classification and segmentation of WCE images	CAD-CAP[54] and KID[110] databases used for training and testing	Deep neural network	Sensitivity of 97% for normal, 94.17% for vascular images, 92.71% for inflammatory images
Guo *et al.*[104]	Multiple lesion detection	2021	Retrospective	China	Utilise CNN models for the automatic detection of vascular and inflammatory lesions	Training: 1,440 images Testing: 360 images	CNN	Sensitivity of 96.67% for vascular lesions, sensitivity of 93.33% for inflammatory lesions
Goel *et al.*[105]	Multiple lesion detection	2022	Retrospective	India	Develop CNN framework to test importance of colour features for lesion detection	Trained and tested on collected 7,259 normal images and 1,683 abnormal images Also trained and tested on KID[110] database	CNN	Sensitivity of 98.06% on collected database, sensitivity of 97% on KID
Yokote *et al.*[106]	Multiple lesion detection	2023	Retrospective	Japan	Construction of objection detection AI model for classification of 12 types of lesions from CE images	Training: 17,085 images Testing: 1,396 images	CNN	Sensitivity of 91%
Ding *et al.*[107]	Multiple lesion detection	2023	Retrospective	China	Development of AI tool to detect multiple lesion types on CE	Training: 280,426 images Testing: 240 videos	CNN	Median sensitivity of 96.25%, median specificity of 83.65%

AI: Artificial intelligence; CNN: convolutional neural network; CE: capsule endoscopy; AGDN: attention guided deformation network; WCE: wireless capsule endoscopy; CAD-CAP: computer-assisted diagnosis for capsule endoscopy; KID: koulaouzidis-iakovidis database; SVM: support vector machine.

While AI shows high overall accuracy across many studies, it is important to note that overall accuracy

alone does not paint a comprehensive picture of model performance in medical applications. For diagnostic models, maintaining a low rate of false negatives is crucial to ensure no diagnoses are missed. While false positives may cause unnecessary worry and additional testing, false negatives can lead to delayed treatment with potentially severe consequences. Additionally, the current body of research is primarily conducted retrospectively, introducing the risk of investigator bias. Hence, future prospective multicentre research on this topic is required.

CONCLUSION AND FUTURE DIRECTIONS

This narrative review provides a comprehensive synthesis on the literature relating to AI in WCE. While integrating AI into capsule endoscopy shows immense promise in reading time reduction and accuracy improvement, there is a potential possibility that the system could independently read images in the future. This path, though, must be navigated carefully, bearing in mind the unique challenges associated with medical data and the specific requirements of diagnostic models. The potential of ViTs is yet to be fully exploited in this field. We anticipate an exciting progression in the coming years as more refined and accurate models are developed.

DECLARATIONS

Authors' contributions

Study conception and design: Singh R
Data collection: George AA, Tan JL, Kovoor JG, Singh R
Analysis and interpretation of results: George AA, Tan JL, Kovoor JG, George B, Lee A, Stretton B, Gupta AK, Bacchi S, Singh R
Draft manuscript preparation: George AA, Tan JL, Kovoor JG, Singh R

Availability of data and materials

Not applicable.

Financial support and sponsorship

None.

Conflicts of interest

All authors declared that there are no conflicts of interest.

Ethical approval and consent to participate

Not applicable.

Consent for publication

Not applicable.

Copyright

© The Author(s) 2024.

REFERENCES

1. Muñoz-Navas M. Capsule endoscopy. *World J Gastroenterol* 2009;15:1584-6. DOI PubMed PMC
2. Beg S, Card T, Sidhu R, Wronska E, Ragunath K; UK capsule endoscopy users' group. The impact of reader fatigue on the accuracy of capsule endoscopy interpretation. *Dig Liver Dis* 2021;53:1028-33. DOI PubMed
3. Giritharan B, Yuan X, Liu J, Buckles B, Oh JH, Tang SJ. Bleeding detection from capsule endoscopy videos. *Annu Int Conf IEEE Eng Med Biol Soc* 2008;2008:4780-3. DOI PubMed
4. Pan G, Yan G, Song X, Qiu X. BP neural network classification for bleeding detection in wireless capsule endoscopy. *J Med Eng*

Technol 2009;33:575-81. DOI PubMed
5. Ghosh T, Fattah SA, Shahnaz C, Wahid KA. An automatic bleeding detection scheme in wireless capsule endoscopy based on histogram of an RGB-indexed image. *Annu Int Conf IEEE Eng Med Biol Soc* 2014;2014:4683-6. DOI PubMed
6. Hassan AR, Haque MA. Computer-aided gastrointestinal hemorrhage detection in wireless capsule endoscopy videos. *Comput Methods Programs Biomed* 2015;122:341-53. DOI PubMed
7. Pan G, Yan G, Qiu X, Cui J. Bleeding detection in wireless capsule endoscopy based on probabilistic neural network. *J Med Syst* 2011;35:1477-84. DOI PubMed
8. Li B, Meng MQH. Computer-aided detection of bleeding regions for capsule endoscopy images. *IEEE Trans Biomed Eng* 2009;56:1032-9. DOI PubMed
9. Yuan Y, Li B, Meng MQH. Bleeding frame and region detection in the wireless capsule endoscopy video. *IEEE J Biomed Health Inform* 2016;20:624-30. DOI PubMed
10. Ghosh T, Fattah SA, Wahid KA, Zhu WP, Ahmad MO. Cluster based statistical feature extraction method for automatic bleeding detection in wireless capsule endoscopy video. *Comput Biol Med* 2018;94:41-54. DOI PubMed
11. Pogorelov K, Suman S, Azmadi Hussin F, et al. Bleeding detection in wireless capsule endoscopy videos - Color versus texture features. *J Appl Clin Med Phys* 2019;20:141-54. DOI PubMed PMC
12. Rathnamala S, Jenicka S. Automated bleeding detection in wireless capsule endoscopy images based on color feature extraction from Gaussian mixture model superpixels. *Med Biol Eng Comput* 2021;59:969-87. DOI PubMed
13. Jia X, Meng MQH. A deep convolutional neural network for bleeding detection in wireless capsule endoscopy images. *Annu Int Conf IEEE Eng Med Biol Soc* 2016;2016:639-42. DOI PubMed
14. Jia X, Meng MQH. Gastrointestinal bleeding detection in wireless capsule endoscopy images using handcrafted and CNN features. *Annu Int Conf IEEE Eng Med Biol Soc* 2017;2017:3154-7. DOI PubMed
15. Hajabdollahi M, Esfandiarpoor R, Najarian K, Karimi N, Samavi S, Reza Soroushmehr SM. Low complexity CNN structure for automatic bleeding zone detection in wireless capsule endoscopy imaging. *Annu Int Conf IEEE Eng Med Biol Soc* 2019;2019:7227-30. DOI PubMed
16. Kanakatte A, Ghose A. Precise bleeding and red lesions localization from capsule endoscopy using compact U-net. *Annu Int Conf IEEE Eng Med Biol Soc* 2021;2021:3089-92. DOI PubMed
17. Ghosh T, Chakareski J. Deep transfer learning for automated intestinal bleeding detection in capsule endoscopy imaging. *J Digit Imaging* 2021;34:404-17. DOI PubMed PMC
18. Ribeiro T, Saraiva MM, Ferreira JPS, et al. Artificial intelligence and capsule endoscopy: automatic detection of vascular lesions using a convolutional neural network. *Ann Gastroenterol* 2021;34:820-8. DOI PubMed PMC
19. Mascarenhas Saraiva M, Ribeiro T, Afonso J, et al. Artificial intelligence and capsule endoscopy: automatic detection of small bowel blood content using a convolutional neural network. *GE Port J Gastroenterol* 2022;29:331-8. DOI PubMed PMC
20. Muruganantham P, Balakrishnan SM. Attention aware deep learning model for wireless capsule endoscopy lesion classification and localization. *J Med Biol Eng* 2022;42:157-68. DOI
21. Kundu AK, Fattah SA, Rizve MN. An automatic bleeding frame and region detection scheme for wireless capsule endoscopy videos based on interplane intensity variation profile in normalized RGB color space. *J Healthc Eng* 2018;2018:9423062. DOI PubMed PMC
22. Xing X, Jia X, Meng MQH. Bleeding detection in wireless capsule endoscopy image video using superpixel-color histogram and a subspace KNN classifier. *Annu Int Conf IEEE Eng Med Biol Soc* 2018;2018:1-4. DOI PubMed
23. Charisis V, Hadjileontiadis LJ, Liatsos CN, Mavrogiannis CC, Sergiadis GD. Abnormal pattern detection in wireless capsule endoscopy images using nonlinear analysis in RGB color space. In: 2010 Annual International Conference of the IEEE Engineering in Medicine and Biology; 2010 Aug 31 - Sep 04; Buenos Aires, Argentina. IEEE; 2010. pp. 3674-7. DOI
24. Li B, Meng MQH. Computer-based detection of bleeding and ulcer in wireless capsule endoscopy images by chromaticity moments. *Comput Biol Med* 2009;39:141-7. DOI PubMed
25. Charisis VS, Hadjileontiadis LJ, Liatsos CN, Mavrogiannis CC, Sergiadis GD. Capsule endoscopy image analysis using texture information from various colour models. *Comput Methods Programs Biomed* 2012;107:61-74. DOI PubMed
26. Iakovidis DK, Koulaouzidis A. Automatic lesion detection in capsule endoscopy based on color saliency: closer to an essential adjunct for reviewing software. *Gastrointest Endosc* 2014;80:877-83. DOI PubMed
27. Fan S, Xu L, Fan Y, Wei K, Li L. Computer-aided detection of small intestinal ulcer and erosion in wireless capsule endoscopy images. *Phys Med Biol* 2018;63:165001. DOI PubMed
28. Khan MA, Sharif M, Akram T, Yasmin M, Nayak RS. Stomach deformities recognition using rank-based deep features selection. *J Med Syst* 2019;43:329. DOI PubMed
29. Kundu AK, Fattah SA, Wahid KA. Multiple linear discriminant models for extracting salient characteristic patterns in capsule endoscopy images for multi-disease detection. *IEEE J Transl Eng Health Med* 2020;8:3300111. DOI PubMed PMC
30. Wang S, Xing Y, Zhang L, Gao H, Zhang H. A systematic evaluation and optimization of automatic detection of ulcers in wireless capsule endoscopy on a large dataset using deep convolutional neural networks. *Phys Med Biol* 2019;64:235014. DOI PubMed
31. Aoki T, Yamada A, Aoyama K, et al. Automatic detection of erosions and ulcerations in wireless capsule endoscopy images based on a deep convolutional neural network. *Gastrointest Endosc* 2019;89:357-63.e2. DOI PubMed
32. Ding Z, Shi H, Zhang H, et al. Gastroenterologist-level identification of small-bowel diseases and normal variants by capsule

endoscopy using a deep-learning model. *Gastroenterology* 2019;157:1044-54.e5. DOI PubMed
33. Majid A, Khan MA, Yasmin M, Rehman A, Yousafzai A, Tariq U. Classification of stomach infections: a paradigm of convolutional neural network along with classical features fusion and selection. *Microsc Res Tech* 2020;83:562-76. DOI PubMed
34. Otani K, Nakada A, Kurose Y, et al. Automatic detection of different types of small-bowel lesions on capsule endoscopy images using a newly developed deep convolutional neural network. *Endoscopy* 2020;52:786-91. DOI PubMed
35. Xia J, Xia T, Pan J, et al. Use of artificial intelligence for detection of gastric lesions by magnetically controlled capsule endoscopy. *Gastrointest Endosc* 2021;93:133-9.e4. DOI PubMed
36. Afonso J, Saraiva MJM, Ferreira JPS, et al. Development of a convolutional neural network for detection of erosions and ulcers with distinct bleeding potential in capsule endoscopy. *Tech Innov Gastrointest Endosc* 2021;23:291-6. DOI
37. Mascarenhas Saraiva MJ, Afonso J, Ribeiro T, et al. Deep learning and capsule endoscopy: automatic identification and differentiation of small bowel lesions with distinct haemorrhagic potential using a convolutional neural network. *BMJ Open Gastroenterol* 2021;8:e000753. DOI PubMed PMC
38. Afonso J, Saraiva MM, Ferreira JPS, et al. Automated detection of ulcers and erosions in capsule endoscopy images using a convolutional neural network. *Med Biol Eng Comput* 2022;60:719-25. DOI PubMed
39. Mascarenhas M, Ribeiro T, Afonso J, et al. Deep learning and colon capsule endoscopy: automatic detection of blood and colonic mucosal lesions using a convolutional neural network. *Endosc Int Open* 2022;10:E171-7. DOI PubMed PMC
40. Xiao P, Pan Y, Cai F, et al. A deep learning based framework for the classification of multi- class capsule gastroscope image in gastroenterologic diagnosis. *Front Physiol* 2022;13:1060591. DOI PubMed PMC
41. Ribeiro T, Mascarenhas M, Afonso J, et al. Artificial intelligence and colon capsule endoscopy: automatic detection of ulcers and erosions using a convolutional neural network. *J Gastroenterol Hepatol* 2022;37:2282-8. DOI PubMed
42. Raut V, Gunjan R, Shete VV, Eknath UD. Gastrointestinal tract disease segmentation and classification in wireless capsule endoscopy using intelligent deep learning model. *Comput Method Biomech Biomed Eng Imaging Vis* 2023;11:606-22. DOI
43. Nakada A, Niikura R, Otani K, et al. Improved object detection artificial intelligence using the revised RetinaNet model for the automatic detection of ulcerations, vascular lesions, and tumors in wireless capsule endoscopy. *Biomedicines* 2023;11:942. DOI PubMed PMC
44. Gan T, Wu JC, Rao NN, Chen T, Liu B. A feasibility trial of computer-aided diagnosis for enteric lesions in capsule endoscopy. *World J Gastroenterol* 2008;14:6929-35. DOI PubMed PMC
45. Arieira C, Monteiro S, de Castro FD, et al. Capsule endoscopy: is the software TOP 100 a reliable tool in suspected small bowel bleeding? *Dig Liver Dis* 2019;51:1661-4. DOI PubMed
46. Vieira PM, Silva CP, Costa D, Vaz IF, Rolanda C, Lima CS. Automatic segmentation and detection of small bowel angioectasias in WCE images. *Ann Biomed Eng* 2019;47:1446-62. DOI PubMed
47. Vezakis IA, Toumpaniaris P, Polydorou AA, Koutsouris D. A novel real-time automatic angioectasia detection method in wireless capsule endoscopy video feed. *Annu Int Conf IEEE Eng Med Biol Soc* 2019;2019:4072-5. DOI PubMed
48. Leenhardt R, Vasseur P, Li C, et al; The CAD-CAP Database Working Group. A neural network algorithm for detection of GI angiectasia during small-bowel capsule endoscopy. *Gastrointest Endosc* 2019;89:189-94. DOI PubMed
49. Tsuboi A, Oka S, Aoyama K, et al. Artificial intelligence using a convolutional neural network for automatic detection of small-bowel angioectasia in capsule endoscopy images. *Dig Endosc* 2020;32:382-90. DOI PubMed
50. Aoki T, Yamada A, Kato Y, et al. Automatic detection of various abnormalities in capsule endoscopy videos by a deep learning-based system: a multicenter study. *Gastrointest Endosc* 2021;93:165-73.e1. DOI PubMed
51. Hwang Y, Lee HH, Park C, et al. Improved classification and localization approach to small bowel capsule endoscopy using convolutional neural network. *Dig Endosc* 2021;33:598-607. DOI PubMed
52. Hosoe N, Horie T, Tojo A, et al. Development of a deep-learning algorithm for small bowel-lesion detection and a study of the improvement in the false-positive rate. *J Clin Med* 2022;11:3682. DOI PubMed PMC
53. Chu Y, Huang F, Gao M, et al. Convolutional neural network-based segmentation network applied to image recognition of angiodysplasias lesion under capsule endoscopy. *World J Gastroenterol* 2023;29:879-89. DOI PubMed PMC
54. Leenhardt R, Vasseur P, Li Cynthia, et al. 403 A highly sensitive and highly specific convolutional neural network-based algorithm for automated diagnosis of angiodysplasia in small bowel capsule endoscopy. *Gastrointest Endosc* 2018;87:AB78. DOI
55. Li B, Meng MQH, Lau JYW. Computer-aided small bowel tumor detection for capsule endoscopy. *Artif Intell Med* 2011;52:11-6. DOI PubMed
56. Karargyris A, Bourbakis N. Detection of small bowel polyps and ulcers in wireless capsule endoscopy videos. *IEEE Trans Biomed Eng* 2011;58:2777-86. DOI PubMed
57. Barbosa DC, Roupar DB, Ramos JC, Tavares AC, Lima CS. Automatic small bowel tumor diagnosis by using multi-scale wavelet-based analysis in wireless capsule endoscopy images. *Biomed Eng Online* 2012;11:3. DOI PubMed PMC
58. Mamonov AV, Figueiredo IN, Figueiredo PN, Tsai YHR. Automated polyp detection in colon capsule endoscopy. *IEEE Trans Med Imaging* 2014;33:1488-502. DOI PubMed
59. Liu G, Yan G, Kuang S, Wang Y. Detection of small bowel tumor based on multi-scale curvelet analysis and fractal technology in capsule endoscopy. *Comput Biol Med* 2016;70:131-8. DOI PubMed
60. Yang J, Chang L, Li S, He X, Zhu T. WCE polyp detection based on novel feature descriptor with normalized variance locality-constrained linear coding. *Int J Comput Assist Radiol Surg* 2020;15:1291-302. DOI PubMed

61. Vieira PM, Freitas NR, Valente J, Vaz IF, Rolanda C, Lima CS. Automatic detection of small bowel tumors in wireless capsule endoscopy images using ensemble learning. *Med Phys* 2020;47:52-63. DOI PubMed
62. Yuan Y, Meng MQH. Deep learning for polyp recognition in wireless capsule endoscopy images. *Med Phys* 2017;44:1379-89. DOI PubMed
63. Saito H, Aoki T, Aoyama K, et al. Automatic detection and classification of protruding lesions in wireless capsule endoscopy images based on a deep convolutional neural network. *Gastrointest Endosc* 2020;92:144-51.e1. DOI PubMed
64. Yamada A, Niikura R, Otani K, Aoki T, Koike K. Automatic detection of colorectal neoplasia in wireless colon capsule endoscopic images using a deep convolutional neural network. *Endoscopy* 2021;53:832-6. DOI PubMed
65. Saraiva MM, Ferreira JPS, Cardoso H, et al. Artificial intelligence and colon capsule endoscopy: development of an automated diagnostic system of protruding lesions in colon capsule endoscopy. *Tech Coloproctol* 2021;25:1243-8. DOI PubMed
66. Jain S, Seal A, Ojha A, et al. A deep CNN model for anomaly detection and localization in wireless capsule endoscopy images. *Comput Biol Med* 2021;137:104789. DOI PubMed
67. Zhou JX, Yang Z, Xi DH, et al. Enhanced segmentation of gastrointestinal polyps from capsule endoscopy images with artifacts using ensemble learning. *World J Gastroenterol* 2022;28:5931-43. DOI PubMed PMC
68. Mascarenhas M, Afonso J, Ribeiro T, et al. Performance of a deep learning system for automatic diagnosis of protruding lesions in colon capsule endoscopy. *Diagnostics* 2022;12:1445. DOI PubMed PMC
69. Gilabert P, Vitrià J, Laiz P, et al. Artificial intelligence to improve polyp detection and screening time in colon capsule endoscopy. *Front Med* 2022;9:1000726. DOI PubMed PMC
70. Liu F, Hua Z, Li J, Fan L. DBMF: dual branch multiscale feature fusion network for polyp segmentation. *Comput Biol Med* 2022;151:106304. DOI PubMed
71. Souaidi M, Lafraxo S, Kerkaou Z, El Ansari M, Koutti L. A multiscale polyp detection approach for GI tract images based on improved DenseNet and single-shot multibox detector. *Diagnostics* 2023;13:733. DOI PubMed PMC
72. Mascarenhas Saraiva M, Afonso J, Ribeiro T, et al. Artificial intelligence and capsule endoscopy: automatic detection of enteric protruding lesions using a convolutional neural network. *Rev Esp Enferm Dig* 2023;115:75-9. DOI PubMed
73. Lafraxo S, Souaidi M, El Ansari M, Koutti L. Semantic segmentation of digestive abnormalities from WCE images by using AttResU-Net architecture. *Life* 2023;13:719. DOI PubMed PMC
74. Blanes-Vidal V, Baatrup G, Nadimi ES. Addressing priority challenges in the detection and assessment of colorectal polyps from capsule endoscopy and colonoscopy in colorectal cancer screening using machine learning. *Acta Oncol* 2019;58:S29-36. DOI PubMed
75. Piccirelli S, Mussetto A, Bellumat A, et al. New generation express view: an artificial intelligence software effectively reduces capsule endoscopy reading times. *Diagnostics* 2022;12:1783. DOI PubMed PMC
76. Eluxeo meets artificial intelligence. Available from: https://asset.fujifilm.com/www/uk/files/2021-05/8fbe51b9718df4e16e3e3a545fa5593a/ELUXEO_CADEYE_Brochure.pdf. [Last accessed on 11 Mar 2024].
77. Lei II, Tompkins K, White E, et al. Study of capsule endoscopy delivery at scale through enhanced artificial intelligence-enabled analysis (the CESCAIL study). *Colorectal Dis* 2023;25:1498-505. DOI PubMed
78. Kumar R, Zhao Q, Seshamani S, Mullin G, Hager G, Dassopoulos T. Assessment of Crohn's disease lesions in wireless capsule endoscopy images. *IEEE Trans Biomed Eng* 2012;59:355-62. DOI PubMed
79. Haji-Maghsoudi O, Talebpour A, Soltanian-Zadeh H, Haji-Maghsoodi N. Segmentation of Crohn, lymphangiectasia, xanthoma, lymphoid hyperplasia and stenosis diseases in WCE. *Stud Health Technol Inform* 2012;180:143-7. PubMed
80. Charisis VS, Hadjileontiadis LJ. Potential of hybrid adaptive filtering in inflammatory lesion detection from capsule endoscopy images. *World J Gastroenterol* 2016;22:8641-57. DOI PubMed PMC
81. Barash Y, Azaria L, Soffer S, et al. Ulcer severity grading in video capsule images of patients with Crohn's disease: an ordinal neural network solution. *Gastrointest Endosc* 2021;93:187-92. DOI PubMed
82. de Maissin A, Gomez T, Le Berre C, et al. P161 Computer aided detection of Crohn's disease small bowel lesions in wireless capsule endoscopy. *J Crohns Colitis* 2018;12:S178-9. DOI
83. Klang E, Barash Y, Margalit R, et al. P285 Deep learning for automated detection of mucosal inflammation by capsule endoscopy in Crohn's disease. *J Crohns Colitis* 2019;13:S242. DOI
84. Klang E, Barash Y, Margalit RY, et al. Deep learning algorithms for automated detection of Crohn's disease ulcers by video capsule endoscopy. *Gastrointest Endosc* 2020;91:606-13.e2. DOI PubMed
85. de Maissin A, Vallée R, Flamant M, et al. Multi-expert annotation of Crohn's disease images of the small bowel for automatic detection using a convolutional recurrent attention neural network. *Endosc Int Open* 2021;9:E1136-44. DOI PubMed PMC
86. Klang E, Grinman A, Soffer S, et al. Automated detection of Crohn's disease intestinal strictures on capsule endoscopy images using deep neural networks. *J Crohns Colitis* 2021;15:749-56. DOI PubMed
87. Klang E, Kopylov U, Mortensen B, et al. A convolutional neural network deep learning model trained on CD ulcers images accurately identifies NSAID ulcers. *Front Med* 2021;8:656493. DOI PubMed PMC
88. Majtner T, Brodersen JB, Herp J, Kjeldsen J, Halling ML, Jensen MD. A deep learning framework for autonomous detection and classification of Crohn's disease lesions in the small bowel and colon with capsule endoscopy. *Endosc Int Open* 2021;9:E1361-70. DOI PubMed PMC
89. Ferreira JPS, de Mascarenhas Saraiva MJQEC, Afonso JPL, et al. Identification of ulcers and erosions by the novel *pillcam*™

Crohn's capsule using a convolutional neural network: a multicentre pilot study. *J Crohns Colitis* 2022;16:169-72. DOI PubMed

90. Higuchi N, Hiraga H, Sasaki Y, et al. Automated evaluation of colon capsule endoscopic severity of ulcerative colitis using ResNet50. *PLoS One* 2022;17:e0269728. DOI PubMed PMC
91. Kratter T, Shapira N, Lev Y, et al. Deep learning multi-domain model provides accurate detection and grading of mucosal ulcers in different capsule endoscopy types. *Diagnostics* 2022;12:2490. DOI PubMed PMC
92. Mascarenhas M, Mendes F, Ribeiro T, et al. Deep learning and minimally invasive endoscopy: automatic classification of pleomorphic gastric lesions in capsule endoscopy. *Clin Transl Gastroenterol* 2023;14:e00609. DOI PubMed PMC
93. Zhou T, Han G, Li BN, et al. Quantitative analysis of patients with celiac disease by video capsule endoscopy: a deep learning method. *Comput Biol Med* 2017;85:1-6. DOI PubMed
94. Wang X, Qian H, Ciaccio EJ, et al. Celiac disease diagnosis from videocapsule endoscopy images with residual learning and deep feature extraction. *Comput Methods Programs Biomed* 2020;187:105236. DOI PubMed
95. Li BN, Wang X, Wang R, et al. Celiac disease detection from videocapsule endoscopy images using strip principal component analysis. *IEEE/ACM Trans Comput Biol Bioinform* 2021;18:1396-404. DOI PubMed
96. Chetcuti Zammit S, McAlindon ME, Greenblatt E, et al. Quantification of celiac disease severity using video capsule endoscopy: a comparison of human experts and machine learning algorithms. *Curr Med Imaging* 2023;19:1455-662. DOI PubMed PMC
97. Wu X, Chen H, Gan T, Chen J, Ngo CW, Peng Q. Automatic hookworm detection in wireless capsule endoscopy images. *IEEE Trans Med Imaging* 2016;35:1741-52. DOI PubMed
98. He JY, Wu X, Jiang YG, Peng Q, Jain R. Hookworm detection in wireless capsule endoscopy images with deep learning. *IEEE Trans Image Process* 2018;27:2379-92. DOI PubMed
99. Gan T, Yang Y, Liu S, et al. Automatic detection of small intestinal hookworms in capsule endoscopy images based on a convolutional neural network. *Gastroenterol Res Pract* 2021;2021:5682288. DOI PubMed PMC
100. Nam JH, Hwang Y, Oh DJ, et al. Development of a deep learning-based software for calculating cleansing score in small bowel capsule endoscopy. *Sci Rep* 2021;11:4417. DOI PubMed PMC
101. Park J, Hwang Y, Nam JH, et al. Artificial intelligence that determines the clinical significance of capsule endoscopy images can increase the efficiency of reading. *PLoS One* 2020;15:e0241474. DOI PubMed PMC
102. Xing X, Yuan Y, Meng MQH. Zoom in lesions for better diagnosis: attention guided deformation network for WCE image classification. *IEEE Trans Med Imaging* 2020;39:4047-59. DOI PubMed
103. Zhu M, Chen Z, Yuan Y. DSI-Net: deep synergistic interaction network for joint classification and segmentation with endoscope images. *IEEE Trans Med Imaging* 2021;40:3315-25. DOI PubMed
104. Guo X, Zhang L, Hao Y, Zhang L, Liu Z, Liu J. Multiple abnormality classification in wireless capsule endoscopy images based on EfficientNet using attention mechanism. *Rev Sci Instrum* 2021;92:094102. DOI PubMed
105. Goel N, Kaur S, Gunjan D, Mahapatra SJ. Investigating the significance of color space for abnormality detection in wireless capsule endoscopy images. *Biomed Signal Proces* 2022;75:103624. DOI
106. Yokote A, Umeno J, Kawasaki K, et al. Small bowel capsule endoscopy examination and open access database with artificial intelligence: the SEE-artificial intelligence project. *DEN Open* 2024;4:e258. DOI PubMed PMC
107. Ding Z, Shi H, Zhang H, et al. Artificial intelligence-based diagnosis of abnormalities in small-bowel capsule endoscopy. *Endoscopy* 2023;55:44-51. DOI PubMed
108. LeCun Y, Bengio Y, Hinton G. Deep learning. *Nature* 2015;521:436-44. DOI PubMed
109. Rudin C. Stop explaining black box machine learning models for high stakes decisions and use interpretable models instead. *Nat Mach Intell* 2019;1:206-15. DOI PubMed PMC
110. Koulaouzidis A, Iakovidis DK, Yung DE, et al. KID project: an internet-based digital video atlas of capsule endoscopy for research purposes. *Endosc Int Open* 2017;5:E477-83. DOI PubMed PMC
111. Deeba F, Islam M, Bui FM, Wahid KA. Performance assessment of a bleeding detection algorithm for endoscopic video based on classifier fusion method and exhaustive feature selection. *Biomed Signal Proces* 2018;40:415-24. DOI
112. Smedsrud PH, Thambawita V, Hicks SA, et al. *Kvasir-capsule*, a video capsule endoscopy dataset. *Sci Data* 2021;8:142. DOI
113. Bernal J, Sánchez FJ, Fernández-Esparrach G, Gil D, Rodríguez C, Vilariño F. WM-DOVA maps for accurate polyp highlighting in colonoscopy: validation vs. saliency maps from physicians. *Comput Med Imaging Graph* 2015;43:99-111. DOI PubMed
114. Coelho P, Pereira A, Leite A, Salgado M, Cunha A. A deep learning approach for red lesions detection in video capsule endoscopies. In: Campilho A, Karray F, ter Haar Romeny B, editors. ICIAR 2018: Image analysis and recognition. Springer, Cham; 2018. pp. 553-61. DOI
115. Jha D, Smedsrud PH, Riegler MA, et al. Kvasir-SEG: a segmented polyp dataset. In: MMM 2020: MultiMedia modeling. Springer, Cham; 2020. pp. 451-62. DOI
116. Bernal J, Sánchez J, Vilariño F. Towards automatic polyp detection with a polyp appearance model. *Pattern Recogn* 2012;45:3166-82. DOI